SECTION EDITOR: GRACE S. ROZYCKI, MD

Image of the Month

MAJ Evan M. Renz, MC, USA; MAJ Theodore J. Kanne, MC, USA

If such a dreamy touch should fall,
O turn thee round, resolve the doubt;
My guardian angel will speak out
In that high place, and tell thee all.
Alfred Lord Tennyson[1]

A 13-MONTH-OLD boy was brought to the emergency department by his parents within 1 hour of an acute choking episode at home. He was suspected of having swallowed a small guardian angel pin now missing from his mother's clothing. The otherwise healthy child was crying, drooling, and appeared to be in mild discomfort. He demonstrated clear breath sounds bilaterally without wheezing or stridor. His oxygen saturation remained 98% on room air. Posteroanterior (**Figure**) and lateral radiographs were obtained.

From the Department of Surgery, William Beaumont Army Medical Center, El Paso, Tex.

What Is the Most Appropriate Management for This Patient?

A. Urgent endotracheal intubation in the emergency department
B. Retrieval of the foreign body using a Foley catheter with fluoroscopic guidance
C. Direct laryngoscopy, endotracheal intubation, and rigid esophagoscopy with foreign body removal in the operating room
D. Endoscopic removal of the object using intravenous sedation

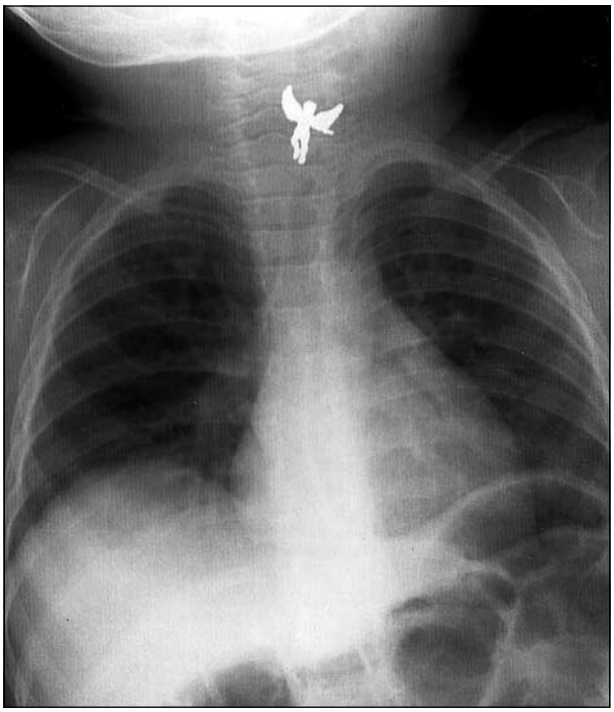

©2001 American Medical Association. All rights reserved.
Downloaded From: http://archsurg.jamanetwork.com/ on 05/04/2015

Answer

Direct Laryngoscopy, Endotracheal Intubation, and Rigid Esophagoscopy With Foreign Body Removal in the Operating Room

Figure. Posteroanterior radiograph revealing a foreign body in the cricopharyngeal region.

The posteroanterior chest x-ray film confirmed the offending object to be resting in the cricopharyngeal region. The lateral x-ray film suggested the pin was in the esophagus, not the trachea. The patient was taken to the operating room without delay, where general anesthesia was induced and intravenous access was established. Endotracheal intubation was performed after direct laryngoscopy confirmed the upper airway was clear. With the airway protected, a laryngoscope was used to visualize the pin trapped at the level of the cricopharyngeus muscle. Because it was clearly visible, the object was retrieved using a small McGill forceps. Subsequent inspection of the cervical esophagus using rigid esophagoscopy revealed normal mucosa except for scant bleeding where the pin had been stuck. Rigid bronchoscopy also revealed no evidence of bronchial injury or other foreign body. The patient recovered uneventfully. He was admitted to the hospital for observation and discharged the next morning without any appreciable sequelae.

Ingested and aspirated foreign bodies are precarious and all too common in the pediatric population. Peak incidence occurs between 9 and 24 months of age.[2] Ingested foreign bodies are most commonly found in the upper third of the esophagus, specifically at the level of the cricopharyngeus.[3,4] The cricopharyngeal region within the cervical esophagus represents the most superior of the esophageal narrowings and is the single most common site for foreign body impaction related to ingestion.[5,6]

The extent of damage from esophageal foreign bodies can range from abrasions and lacerations to perforation. Esophageal impaction can also lead to tracheal compression. Perforation may occur at any level; however, the region near the cricopharyngeus is among the most vulnerable.[6] A foreign body with sharp or protruding edges, such as the angel pin described herein, may become impaled in the mucosa. Such objects must be disengaged from the mucosa before withdrawal is attempted to minimize the risk of perforation.[6,7]

A reliable history of the events surrounding any suspected aspiration or ingestion of a foreign body is important, particularly with respect to identifying the foreign body and the patient's symptoms following the acute event.[8] A classic history of ingestion may include an acute choking episode, followed by coughing, drooling, or pain. Drooling is an important finding suggestive of serious compromise within the aerodigestive tract.[2,3]

Without debate, patients with airway compromise require immediate interventions to establish a protected airway. Because this child was crying, with a patent airway, no such intervention was immediately necessary, although continuous observation for any sign of deterioration was essential. In this setting, confirmation of the presence and location of an ingested foreign body relies on radiographic evidence. Ingested foreign bodies are generally radiopaque. Their size, shape, and location can usually be identified in posteroanterior and lateral plain x-ray films of the upper aerodigestive tract. An incomplete history and clinical suspicion or a report of choking mandates radiologic assessment of the chest and abdomen in posteroanterior and lateral views.[1]

These patients should be treated by a physician experienced in foreign body removal.[1] Although there are several techniques described for the removal of foreign bodies impacted in the cervical esophagus, the safest and most efficient method is rigid esophagoscopy, performed under general endotracheal anesthesia, with the airway protected.[2,5]

We thank Raul L. Hernandez for his technical expertise in preparing the image for this article.

The views expressed in this article are those of the authors and do not reflect the official policy or position of the US Army, the Department of Defense, or the US government.

Corresponding author and reprints: MAJ Evan M. Renz, MC, USA, Department of Surgery, William Beaumont Army Medical Center, 5005 N Piedras St, El Paso, TX 79920-5001 (e-mail: evan.renz@cen.amedd.army.mil).

REFERENCES

1. Tennyson A. In Memoriam. In: Quiller-Couch AT, ed. *The Oxford Book of English Verse*. Oxford, England: Clarendon; 1919. Available at: http://www.Bartleby.com. Accessed March 1, 2001.
2. Reilly JS, Cook SP, Stool D, Rider G. Prevention and management of aerodigestive foreign body injuries in childhood. *Pediatr Clin North Am*. 1996;43:1403-1411.
3. Blair SR, Graeber GM, Cruzzavala JL, et al. Current management of esophageal impactions. *Chest*. 1993;104:1205-1209.
4. Stack LB, Munter DW. Foreign bodies in the gastrointestinal tract. *Emerg Med Clin North Am*. 1996;14:493-521.
5. Skandalakis JE, Ellis H. Embryologic and anatomic basis of esophageal surgery. *Surg Clin North Am*. 2000;80:85-155.
6. Schild JA, Snow JB. Esophagology. In: Ballenger JJ, Snow JB, eds. *Otorhinolaryngology*. Baltimore, Md: Williams & Wilkins; 1996:1231-1233.
7. Gustafson LM, Tami TA. Flexible versus rigid esophagoscopy: a practical comparison for otolaryngologists. *Curr Opin Otolaryngol Head Neck Surg*. 2000;8:227-231.
8. Rovin JD, Rodgers BM. Pediatric foreign body aspiration. *Pediatr Rev*. 2000;21:86-90.

Submissions

The Editor welcomes contributions to the *Image of the Month*. Send manuscripts to Grace S. Rozycki, MD, Department of Surgery, Emory University School of Medicine, 69 Butler St SE, Atlanta, GA 30303; (404) 616-3553; fax (404) 616-7333 (e-mail: grozyck@emory.edu). Articles and photographs accepted will bear the contributor's name. Manuscript criteria and information are per the Instructions for Authors for *Archives of Surgery*. No abstract is needed, and the manuscript should be no more than 3 typewritten pages. There should be a brief introduction, 1 multiple-choice question with 4 possible answers, and the main text. No more than 2 photographs should be submitted. There is no charge for reproduction and printing of color illustrations.

©2001 American Medical Association. All rights reserved.
Downloaded From: http://archsurg.jamanetwork.com/ on 05/04/2015