SECTION EDITOR: GRACE S. ROZYCKI, MD

Image of the Month

Ioannis Raftopoulos, MD, PhD; Theresa Lee, MD; Mitchel P. Byrne, MD

A 62-YEAR-OLD otherwise healthy man was seen for persistent right flank pain of 2 years' duration. Physical examination findings revealed fullness of his right lower quadrant and anterior thigh without any tenderness. A contrast-enhanced computed tomography (CT) scan of the abdomen, pelvis, and thigh demonstrated a large, well-circumscribed, homogeneous mass anterior to the right iliopsoas muscle that was extending from the inferior pole of the right kidney to the anterior midthigh. The right colon and small bowel were displaced medially (**Figure 1**).

The patient underwent exploration through a right flank incision that was extended vertically to the right groin and proximal thigh. The mass was encapsulated and found to be loosely adherent to the right iliopsoas muscle and femoral nerve. The tumor was removed en bloc. It weighed 790 g and measured 20 × 15 × 10 cm (**Figure 2**). Microscopic examination of the mass showed mature adipocytes without any mitoses or invasion. The patient had an uneventful recovery.

From the Metropolitan Group Hospitals General Surgery Residency Program, Chicago, Ill (Drs Raftopoulos and Lee); the Department of General Surgery, St Francis Hospital at Evanston, Evanston, Ill (Dr Byrne); and the General Surgery Program, University of Illinois at Chicago (Dr Byrne).

What Is the Diagnosis?

A. Retroperitoneal liposarcoma
B. Retroperitoneal lipoblastoma
C. Retroperitoneal lipoma
D. Retroperitoneal hibernoma

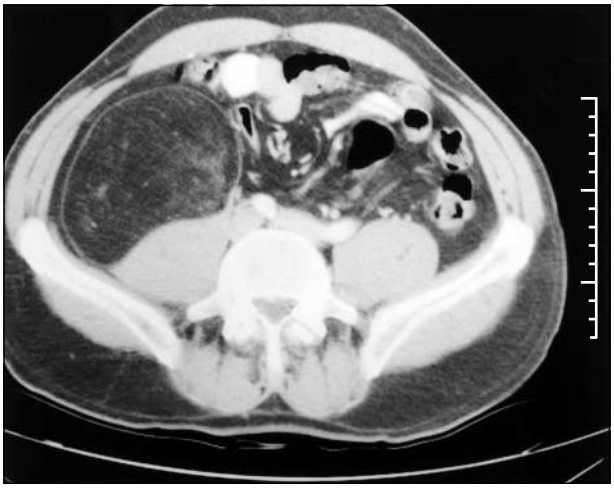

Figure 1.

Figure 2.

©2002 American Medical Association. All rights reserved.
Downloaded From: http://archsurg.jamanetwork.com/ on 05/04/2015

Answer

Retroperitoneal Lipoma

Figure 1. Contrast-enhanced computed tomographic scan of the abdomen and pelvis demonstrating a large, well-circumscribed, homogeneous mass anterior to the right iliopsoas muscle with medial displacement of the right colon and the small bowel. Scale is in centimeters.

Figure 2. Intraoperative photograph demonstrating the intra-abdominal component of the mass with lateral displacement of the iliofemoral neurovascular bundle.

The preoperative diagnosis of a retroperitoneal tumor of adipose tissue may represent a particularly challenging endeavor. Primary retroperitoneal lipomas are rare benign tumors that usually present as an abdominal mass or with patient complaints of pressure symptoms on adjacent organs. Histologically, they originate from mature adipose tissue of the retroperitoneum, mesentery, or the Gerota fascia.[1] Although they are relatively more common in adults, they can occur in infants and small children.[2] Retroperitoneal lipomas may also undergo malignant transformation to sarcomas.[1] Classic lipomas have CT and magnetic resonance imaging (MRI) signal characteristics similar to subcutaneous fat (between −65 and −120 Hounsfield units).[3] Resection is the treatment of choice.

Liposarcoma is the most common soft tissue sarcoma of the retroperitoneum that accounts for most retroperitoneal fatty tumors. The usual presentation is that of a nontender palpable mass. A low grade liposarcoma is difficult to differentiate from a benign lipoma based solely on CT scan or MRI findings, but heterogeneity, areas of enhancement or necrosis, and irregular margins are often seen on the CT scan of a liposarcoma.[3] Pathologic examination for mitotic activity, cellular atypia, necrosis, and invasion allows for a definitive diagnosis. Aggressive excision with clear margins remains the only effective treatment.[4]

A retroperitoneal lipoblastoma is a rare benign neoplasm of infancy and early childhood that usually manifests as a slowly growing asymptomatic mass. The characteristic microscopic appearance includes variable amounts of mature lipocytes, lipoblasts, and poorly differentiated mesenchymal cells in a myxoid stroma. Complete excision is the treatment of choice, although there is a reported 25% recurrence rate.[5]

Retroperitoneal hibernomas are extremely rare, slowly growing benign tumors of brown fat. Microscopically, hibernomas consist of multivacuolated cells, small eosinophilic cells, and univacuolated adipocytes.[6] Although the CT scan and MRI findings cannot always differentiate a hibernoma from other adipose tissue tumors, increased vascularity (enhancement) and higher attenuation numbers similar to muscle (brown fat) may be suggestive of the diagnosis.[3] Total excision is the treatment of choice.[7]

Corresponding author and reprints: Ioannis Raftopoulos, MD, PhD, 856 W Nelson St, Apt 1002, Chicago, IL 60657 (e-mail: iraftopoulos@hotmail.com).

REFERENCES

1. McCarthy MP, Frogge JD, Delgado R, Mac P. A large retroperitoneal lipoma. *J Urol.* 1977;118:478-479.
2. Weitzner S, Blumenthal BI, Moynihan PC. Retroperitoneal lipoma in children. *J Pediatr Surg.* 1979;14:88-90.
3. Munk PL, Lee MJ, Janzen DL, et al. Lipoma and liposarcoma: evaluation using CT and MR imaging. *AJR Am J Roentgenol.* 1997;169:589-594.
4. Lewis JJ, Brennan MF. The management of retroperitoneal soft tissue sarcoma. *Adv Surg.* 1999 ;33:329-344.
5. Chun YS, Kim WK, Park KW, Lee SC, Jung SE. Lipoblastoma. *J Pediatr Surg.* 2001;36:905-907.
6. Sansom HE, Blunt DM, Moskovic EC. Large retroperitoneal hibernoma: CT findings with pathologic correlation. *Clin Radiol.* 1999;54:625-627.
7. Rigor VU, Goldstone SE, Jones J, Bernstein R, Gold MS, Weiner S. Hibernoma: a case report and discussion of a rare tumor. *Cancer.* 1986; 57:2207-2211.

Submissions

The Editor welcomes contributions to the "Image of the Month." Send manuscripts to Grace S. Rozycki, MD, Department of Surgery, Emory University School of Medicine, 69 Butler St SE, Atlanta, GA 30303; (404) 616-3553; fax (404) 616-7333 (e-mail: grozyck@emory.edu). Articles and photographs accepted will bear the contributor's name. Manuscript criteria and information are per the "Instructions for Authors" for *Archives of Surgery*. No abstract is needed, and the manuscript should be no more than 3 typewritten pages. There should be a brief introduction, 1 multiple-choice question with 4 possible answers, and the main text. No more than 2 photographs should be submitted. There is no charge for reproduction and printing of color illustrations.

©2002 American Medical Association. All rights reserved.
Downloaded From: http://archsurg.jamanetwork.com/ on 05/04/2015