ORIGINAL ARTICLE

Diagnostic Applicability of Dipeptidyl Aminopeptidase IV Activity in Cytological Samples for Differentiating Follicular Thyroid Carcinoma From Follicular Adenoma

Junko Maruta, CT, IAC, BSc; Hironobu Hashimoto, CT, IAC; Hiroto Yamashita, MD, PhD; Hiroyuki Yamashita, MD, PhD; Shiro Noguchi, MD, PhD

Hypothesis: Dipeptidyl aminopeptidase IV (DPP IV) activity in cytological samples from a follicular thyroid tumor is the most sensitive and specific indicator for the detection of follicular carcinoma of the thyroid gland. Dipeptidyl aminopeptidase IV activity is independent of cytological characteristics and superior to other clinical findings.

Design and Patient Selection: Among the patients surgically treated for follicular thyroid tumors, we recruited approximately equal numbers of those with true-positive (n=19), true-negative (n=26), false-negative (n=16), and false-positive (n=18) cytological characteristics.

Main Outcome Measures: We examined DPP IV activity using cytological specimens obtained from 35 patients with follicular thyroid carcinomas and 44 patients with follicular adenomas. Tumor size, patient age, serum thyroglobulin level, and ultrasonographic findings were also analyzed.

Results: The positive rate of DPP IV activity was 97% in 35 patients with follicular thyroid carcinomas and 5% in 44 patients with follicular adenomas, resulting in a sensitivity of 97%, a specificity of 95%, and an overall accuracy of 96%. This discriminating ability of DPP IV activity was far higher than that of tumor size, patient age, serum thyroglobulin level, or ultrasonographic findings.

Conclusions: Positive DPP IV activity in cytological samples is the best discriminatory marker between follicular thyroid carcinoma and follicular adenoma. Its application could alter the clinical management of patients with follicular thyroid tumors.

Arch Surg. 2004;139:83-88

From the Departments of Pathology (Messrs Maruta and Hashimoto and Dr Hiroto Yamashita) and Surgery (Drs Hiroyuki Yamashita, and Noguchi), Noguchi Thyroid Clinical and Hospital Foundation, Beppu, Japan.

FINE-NEEDLE ASPIRATION (FNA) biopsy is the most effective and reliable diagnostic tool for detecting malignancies in the thyroid nodules. Through the use of FNA biopsy, the percentage of patients who underwent thyroidectomy decreased, whereas the yield of thyroid carcinomas increased.[1,2] We recently reported that thyroid malignancies can be diagnosed with high accuracy by combining ultrasonography with FNA biopsy except in cases of follicular thyroid carcinoma.[3] For the diagnosis of follicular thyroid carcinoma, it is necessary to use histologic examination to document vascular or capsular invasion or metastasis. Conventional cytologic examination mainly uses cellular morphological atypia to distinguish malignant lesions from benign lesions. At our institution, suspicion of follicular thyroid carcinoma was diagnosed by malignant morphological features of tumor cells obtained by FNA biopsy; however, its diagnostic accuracy was not satisfactory, mainly because malignant morphological features were not always seen in cytological samples from patients with follicular thyroid carcinomas. Accurate diagnostic techniques are in great demand for the preoperative diagnosis of follicular thyroid carcinoma to determine whether a follicular tumor thyroidectomy should be recommended for the patient. Avoidance of unnecessary thyroidectomy can reduce patient discomfort and medical costs.

Dipeptidyl aminopeptidase IV (DPP IV), a membrane-bound enzyme, is expressed strongly by papillary carcinomas of the thyroid and follicular thyroid carcinomas, and therefore, several studies[4-6] have reported that DPP IV activity might be a useful adjunct for the diagnosis of thyroid nodules. Kotani et al,[4] Aratake et al,[5] and Iwabuchi et al[6] studied a variety of thyroid nodules; however, the number of follicular thyroid tumors (carcinoma and adenoma) examined was very small. Therefore, interpretation of their results concerning the diagnostic efficacy of DPP IV activity for follicular thyroid carcinoma may be limited.

©2004 American Medical Association. All rights reserved.
Downloaded From: http://archsurg.jamanetwork.com/ on 12/21/2014

The aim of this study was to test DPP IV activity using imprint cytological smears obtained from a large number of follicular thyroid tumors to assess its clinical applicability in the differentiation between follicular thyroid carcinoma and follicular adenoma. We also examined other clinical findings that may be relevant in predicting malignancy of thyroid nodules and compared their diagnostic sensitivity and specificity with a DPP IV activity test.

METHODS

PATIENT SELECTION

This study was approved by a staff meeting at Noguchi Thyroid Clinical and Hospital Foundation, Beppu, Japan. To focus on follicular thyroid carcinoma and follicular adenoma and to maximize study efficacy, we retrospectively recruited approximately equal numbers of patients with true-positive, true-negative, false-negative, and false-positive cytological characteristics. All patients had been surgically treated for follicular thyroid tumors and had their DPP IV activities examined between 1999 and 2000. Based on the results of preoperative FNA biopsy and the pathologic reports, patients were divided into 4 categories of true positive (n=19), true negative (n=26), false negative (n=16), and false positive (n=18). Recruitment continued until the required number of patients in the rarest category, false negative, was achieved. Patients in the other categories were randomly selected to have a similar number of cases.

FNA BIOPSIES

All patients underwent FNA biopsies. The specimens were processed with Papanicolaou stain. A cytological diagnosis of suspected follicular thyroid carcinoma was made when the specimen had several or more of the following characteristics: a small follicular pattern that was very irregular and sparse, very crowded and overlapped nuclei with nucleoli, increased nuclear size, round to oval or pleomorphic nuclear features, coarsely granular chromatin contrasting with the dusty chromatin of papillary carcinoma cells, and parachromatin clearing. These characteristics generally indicate malignancy but are known to be poor in discriminating follicular thyroid carcinoma from follicular adenoma.

DPP IV ACTIVITY STAINING

Staining of DPP IV activity was evaluated according to the methods of Lojda[7] and Aratake et al.[5] After imprint smears of surgically removed thyroid lesions obtained for pathologic examination were dried at room temperature for 10 minutes, they were fixed for 1 minute in a mixture of formalin, cold acetone (4°C), and phosphate-buffered saline at a volume ratio of 1:40:10, respectively. After being washed in water, the smears were immersed for 30 minutes in a room-temperature solution prepared by dissolving 3 mg of glycylproline 4-methoxy β-naphthylamide (Sigma Chemical Company, St Louis, Mo) in 0.25 mL of *N*,*N*-dimethylformamide (Nakarai Chemical Ltd, Kyoto, Japan) and 5 mg of Fast Blue B salt (Sigma Chemical Company) in 4.6 mL of 0.1 mol/L sodium phosphate buffer (pH 7.2). Then the nuclei were stained with Mayer hematoxylin for 3 minutes and mounted in glycerol gelatin.

We evaluated DPP IV activity in terms of both stain intensity and percentage of positively stained cells in at least 20 fields per patient. Stain intensity was divided into 3 categories: strongly positive, positive, and negative. The percentage of positively stained cells was classified into 2 groups: less than 70% and 70% and higher. A specimen was defined as positive DPP IV activity when it showed both strongly positive or positive stain intensity and a percentage of positively stained cells 70% or higher.

ULTRASONOGRAPHY

Ultrasonographic examination was performed in all patients with a Logiq TM500MD (GE Yokogawa Medical Systems, Tokyo, Japan) equipped with a LA39 linear probe (6-13 MHz) with spatial resolution of about 2 mm. To determine whether the ultrasonogram showed malignant or benign tumors, we assessed tumor margin (well-defined or ill-defined), shape (regular or irregular), halo sign (present or absent),[3] echo structure (solid, mixed, or cystic), internal echo (homogeneous or heterogeneous), echogenicity (hyperechoic/isoechoic, hypoechoic, or hypoisoechoic), calcification (fine, others, or absent), and invasion to the adjacent organs (present or absent). Preoperatively, we defined malignant nodules as ill-defined or irregular nodules with heterogeneous internal echogenicity or hypoechogenicity. Any sign of invasion to the adjacent organs was considered malignant.

PATHOLOGIC DIAGNOSIS

The final pathologic diagnosis was determined by a single pathologist (Hiroto Yamashita). In follicular thyroid carcinomas, capsular invasion was categorized as negative, minimally invasive, or widely invasive, and vascular invasion was categorized as negative or invasive.

STATISTICAL ANALYSIS

Data were analyzed with the Student *t* test or Fisher exact test depending on data type (continuous or categorical, respectively), using a JMP 4.0.5J statistical package (SAS Institute Inc, Cary, NC). Sensitivity was calculated as number of true-positive diagnoses/number of follicular thyroid carcinomas and specificity was calculated as number of true-negative diagnoses/number of follicular adenomas.

RESULTS

The male-female ratios for patients with follicular thyroid carcinomas and with follicular adenomas were 1.0:3.4 and 1.0:4.5, respectively, ($P=.60$ using the Fisher exact test) and the mean±SD ages were 55.6±12.8 years and 54.4±16.1 years, respectively ($P=.70$ using the *t* test). The mean±SD maximum tumor diameters were 32.4±20.2 mm for patients with follicular thyroid carcinomas and 24.5±13.1 mm for patients with follicular adenomas ($P=.02$ using the *t* test).

The percentage of malignancy in 79 patients with follicular thyroid tumors is shown by tumor size, patient age, or serum thyroglobulin level in **Figures 1**, **2**, and **3**. Although larger tumor size and higher level of serum thyroglobulin are more frequently observed in patients with follicular thyroid carcinomas than patients with follicular adenomas, their sensitivity and specificity are lower than DPP IV activity (**Table 1**).

During preoperative ultrasonography, 13 of the 35 patients with follicular thyroid carcinomas were diagnosed as having malignant tumors and 36 of the 44 patients with follicular adenomas were diagnosed as having benign tumors. Therefore, the sensitivity and

©2004 American Medical Association. All rights reserved.
Downloaded From: http://archsurg.jamanetwork.com/ on 12/21/2014

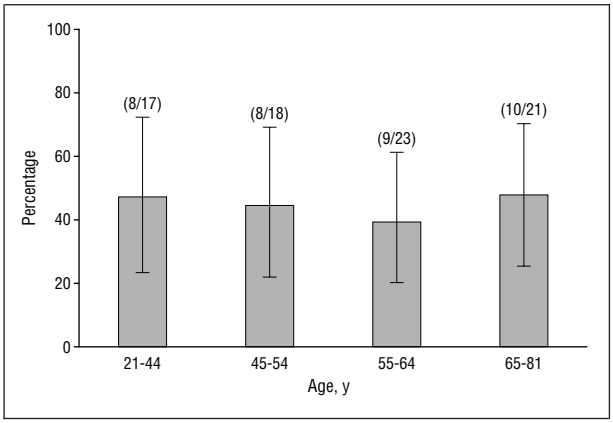

Figure 1. Percentage of malignancy in 79 patients with follicular thyroid tumors (35 carcinomas and 44 adenomas) by age groups. Numbers in parentheses represent the number of patients with follicular thyroid cancer/total number of patients in each age group. Error bars indicate 95% confidence intervals.

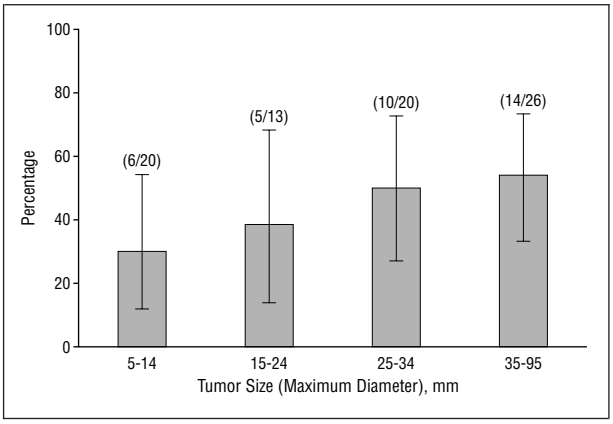

Figure 2. Percentage of malignancy in 79 patients with follicular thyroid tumors (35 carcinomas and 44 adenomas) by tumor size. Numbers in parentheses represent the number of patients with follicular thyroid cancer/total number of patients in each tumor-size group. Error bars indicate 95% confidence intervals.

specificity were 37% and 82%, respectively, for 79 follicular thyroid tumors (Table 1).

Frozen-section examination was performed in 18 patients (Table 1 and **Table 2**). Five of these patients, who were later confirmed as having follicular thyroid carcinomas by permanent histologic examination, were diagnosed by frozen-section examination as having follicular thyroid carcinoma (n=1), papillary carcinoma of the thyroid gland (n=1), and follicular thyroid tumor (n=3). All of them showed positive DPP IV activities. The frozen sections of 13 follicular adenomas were diagnosed as undetermined follicular thyroid tumor (n=2), follicular adenoma (n=5), adenomatous goiter (n=3), and benign (n=3). All of them showed negative DPP IV activity.

Thirty-four (97%) of 35 patients with follicular thyroid carcinomas were positive for DPP IV activity (**Figure 4**) (Table 1 and **Table 3**). One patient with follicular thyroid carcinoma and negative DPP IV activity was also negative in cytological features and poorly differentiated with capsular and vascular invasions in histologic features. Forty-two (95%) of 44 patients with follicular adenomas had negative DPP IV activity (**Figure 5**). The remaining 2 patients with follicular adenomas and positive DPP IV activity were negative in cytological features. These patients had a capsular invasion–like structure that resembled but was different from capsular invasion in follicular thyroid carcinoma. Their histologic diagnosis was trabecular adenoma of the microfollicular type. Both individual tumor cells and follicular lumina were positively stained, and macrophages, histiocytes, inflammatory cells, and fibrous cells showed positive activity to DPP IV.

Distant metastases were found in 6 patients with follicular thyroid carcinomas during the follow-up period: 4 at the bone, 1 at the lungs, and 1 at the distant lymph node. The DPP IV activities of these 6 patients were all positive.

COMMENT

Follicular carcinoma of the thyroid gland has no cytomorphological characteristics distinct from follicular adenoma and must be diagnosed by histologic identification of capsular or vascular invasion, which cannot be found in cytological examination with Papanicolaou stain, resulting in low preoperative diagnostic accuracy.

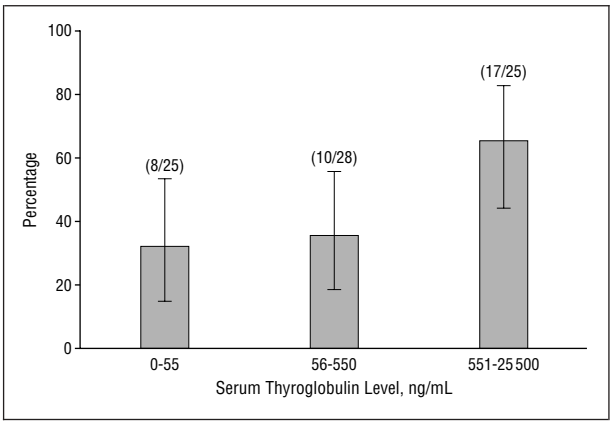

Figure 3. Percentage of malignancy in 79 patients with follicular thyroid tumors (35 carcinomas and 44 adenomas) by serum thyroglobulin level. Numbers in parentheses represent the number of patients with follicular thyroid cancer/total number of patients in each group by preoperative serum thyroglobulin level. Error bars indicate 95% confidence intervals.

Several investigators reported that the expression of DPP IV activity is useful in the diagnosis of malignant thyroid tumors.[5,6] Reported positive rates ranged from 90% to 100% in patients with follicular thyroid carcinomas and 0% to 16% in patients with follicular adenomas.[4-8] Our study of a large number of patients with follicular thyroid tumors confirmed the usefulness of DPP IV activity for the differentiation of follicular thyroid carcinoma from follicular adenoma; the positive rate was as high as 97% in patients with follicular thyroid carcinomas and as low as 5% in patients with follicular adenomas. Of the 16 patients with follicular carcinomas that showed no morphological evidence of malignancy by conventional cytological examination, 15 (94%) had DPP IV activity. On the other hand, in 18 patients with follicular adenomas that showed some morphological characteristics of malignancy by conventional cytological examination, no patient had positive DPP IV activity. Thus,

©2004 American Medical Association. All rights reserved.
Downloaded From: http://archsurg.jamanetwork.com/ on 12/21/2014

Table 1. Diagnostic Reliability in Follicular Thyroid Tumors*

	Sensitivity	*P* Value†	Specificity	*P* Value†
Tumor size‡	63 (22/35)	.001	52 (23/44)	<.001
Serum thyroglobulin level§	49 (17/35)	<.001	80 (35/44)	.049
Ultrasonography	37 (13/35)	<.001	82 (36/44)	.09
Frozen-section pathologic findings‖	40 (2/5)	.004	85 (11/13)	.22
Dipeptidyl aminopeptidase IV activity	97 (34/35)		95 (42/44)	

*Values are presented as percentage (number/total number).
†Sensitivity and specificity were compared with dipeptidyl aminopeptidase IV activity using the Fisher exact test.
‡Positive if maximum diameter greater than 25 mm.
§Positive if serum thyroglobulin level greater than 550 ng/mL.
‖Sensitivity is the number of malignant diagnoses in frozen section/number of follicular thyroid carcinomas; specificity, the number of benign diagnoses in frozen section/number of follicular adenomas.

Table 2. Frozen-Section Results in Follicular Thyroid Tumors

	Frozen-Section Diagnosis, No. of Patients	DPP IV Activity, No. (%)
Follicular thyroid carcinoma with true-positive cytological characteristics (n = 4)	Follicular thyroid carcinoma, 1 Papillary carcinoma of thyroid gland, 1 Follicular thyroid tumor, 2	4 (100)
Follicular thyroid carcinoma with false-negative cytological characteristics (n = 1)	Follicular thyroid tumor, 1	1 (100)
Follicular adenoma with true-negative cytological characteristics (n = 7)	Follicular thyroid tumor, 1 Follicular adenoma, 3 Adenomatous goiter, 2 Benign, 1	0
Follicular adenoma with false-positive cytological characteristics (n = 6)	Follicular thyroid tumor, 1 Follicular adenoma, 2 Adenomatous goiter, 1 Benign, 2	0

Abbreviation: DPP, dipeptidyl aminopeptidase.

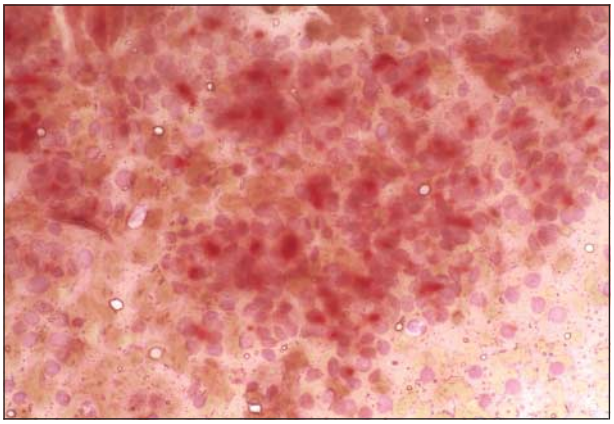

Figure 4. Positive dipeptidyl aminopeptidase IV activity in a cytological specimen from a patient with follicular thyroid carcinoma. Most of the thyrocytes show a strongly positive stain intensity.

Table 3. Dipeptidyl Aminopeptidase (DPP) IV Activity in Follicular Thyroid Tumors

	No. (%) of Patients Positive for DPP IV Activity
Follicular thyroid carcinoma with true-positive cytological characteristics (n = 19)	19 (100)
Follicular thyroid carcinoma with false-negative cytological characteristics (n = 16)	15 (94)
Follicular adenoma with true-negative cytological characteristics (n = 26)	2 (8)
Follicular adenoma with false-positive cytological characteristics (n = 18)	0

complementary DPP IV activity with conventional cytological examination will improve the preoperative diagnostic accuracy in follicular thyroid tumors.

Evaluation of DPP IV activity is simple and does not require any special technical skill because of the distinct difference between positive and negative staining. This makes it more feasible for clinical use. However, it is recommended that the specimen be simultaneously processed with Papanicolaou stain because histiocytes also show DPP IV activity.

In our study, only 2 (5%) of 44 patients with follicular adenomas had DPP IV activity. Although Hürthle cell adenomas were reported to show positive staining,[5-9] both tumors with positive DDP IV activity in our study consisted of a trabecular meshwork and microfollicles without Hürthle cells. They were revealed to have a capsular invasion–like structure by making a critical examination of many blocks and serial sections after ob-

©2004 American Medical Association. All rights reserved.
Downloaded From: http://archsurg.jamanetwork.com/ on 12/21/2014

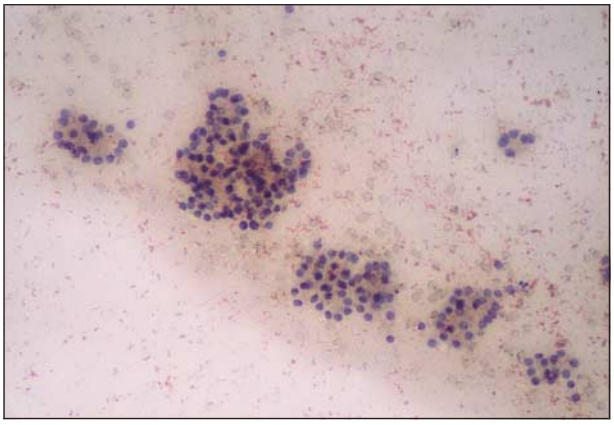

Figure 5. Negative dipeptidyl aminopeptidase IV activity in a cytological specimen from a patient with follicular thyroid adenoma. Most of the thyrocytes are negatively stained.

taining positive results of DPP IV activity. The morphological characteristics were, however, not clear enough to make a pathologic diagnosis of minimally invasive follicular thyroid carcinomas. Similar and noteworthy examples have been previously observed. Hirai et al[10] reported patients who were initially diagnosed with follicular adenomas and who had positive DPP IV expression were later correctly diagnosed with follicular thyroid carcinoma after the appearance of distant metastases to the lungs or bone.[10] This suggests that malignant potentiality may be considered if the patient with follicular adenoma has positive DPP IV activity. Therefore, surgical excision should be recommended for follicular thyroid tumors with positive DPP IV activity.

This study confirmed the previous studies[11-13] in which the incidence of malignancy of follicular thyroid tumors increased according to patient age, tumor size, or serum thyroglobulin level. However, its sensitivity and specificity for follicular thyroid carcinoma are not satisfactory for selection of patients for thyroid surgery.

Frozen-section examinations play an important role in determining additional thyroidectomy or lymph node excision. Frozen-section examination sometimes results in an undetermined diagnosis without a thorough examination of capsular and vascular invasion, as far as follicular thyroid tumors are concerned. In our study, 3 (60%) of 5 patients with follicular thyroid carcinomas and 2 (15%) of 13 patients with follicular adenomas were found to have undetermined follicular thyroid tumors by frozen-section examination, whereas all of the patients with follicular thyroid carcinomas had positive DPP IV activity and all of the patients with follicular adenomas had negative DPP IV activity. These results suggest that DPP IV activity has a stronger discriminating power than frozen-section examination.

Umbricht et al[14] reported that telomerase activity was found in all of 11 patients with follicular thyroid carcinomas and in 8 of 33 patients with follicular adenomas. Although their number of patients was small, the specificity of the DPP IV activity test in our study was significantly higher. Other techniques such as flow cytometric nuclear DNA analysis,[15-18] silver staining of nuclear organizer regions,[19-22] proton magnetic resonance,[23-26] antiperoxidase and JT-95 antibodies,[27] and galectine-3 expression[28-31] have been assessed for their ability to discriminate follicular thyroid carcinoma from adenoma; however, these have not been applied clinically.

Positive DPP IV activity in thyroid FNA biopsy samples is the best discriminatory marker between follicular thyroid carcinoma and follicular adenoma of all the other laboratory tests and clinical findings. We recommend the DPP IV activity test as well as FNA biopsy if a thyroid nodule is suspected of being a follicular tumor by ultrasonography. Surgery is indicated for suspected follicular thyroid tumors with positive DPP IV activity, and frozen-section examination is rarely necessary in such cases. Application of the DPP IV activity test can alter the clinical management of patients with follicular thyroid tumors.

Accepted for publication June 29, 2003.

Corresponding author: Junko Maruta, CT, IAC, Department of Pathology, Noguchi Thyroid Clinical and Hospital Foundation, 6-33 Noguchinakamachi, Beppu, Oita 874-0932, Japan (e-mail: junko@noguchi-med.or.jp).

REFERENCES

1. Herrera MF, Lopez CM, Saldana J, et al. Trends in thyroid surgery at the Instituto Nacional de la Nutricion Salvador Zubiran. *Rev Invest Clin.* 1995;47:13-19.
2. Galloway JW, Sardi A, DeConti RW, Mitchell WT Jr, Bolton JS. Changing trends in thyroid surgery: 38 years' experience. *Am Surg.* 1991;57:18-20.
3. Koike E, Yamashita H, Noguchi S, et al. Effect of combining ultrasonography and ultrasound-guided fine-needle aspiration biopsy findings for the diagnosis of thyroid nodules. *Eur J Surg.* 2001;167:656-661.
4. Kotani T, Aratake Y, Ogata Y, et al. Expression of dipeptidyl aminopeptidase IV activity in thyroid carcinoma. *Cancer Lett.* 1991;57:203-208.
5. Aratake Y, Kotani T, Tamura K, et al. Dipeptidyl aminopeptidase IV staining of cytological preparations to distinguish benign from malignant thyroid diseases. *Am J Clin Pathol.* 1991;96:306-310.
6. Iwabuchi H, Toriya K, Mimura T, Tamai S, Ito K, Kato H. Staining for dipeptidyl aminopeptidase IV activity in nodular thyroid disease. *Acta Cytol.* 1996;40:158-163.
7. Lojda Z. Studies on glycyl-proline naphthylamidase, I: lymphocytes. *Histochemistry.* 1977;54:299-309.
8. Umeki K, Tanaka T, Yamamoto I, et al. Differential expression of dipeptidyl peptidase IV (CD26) and thyroid peroxidase in neoplastic thyroid tissues. *Endocr J.* 1996;43:53-60.
9. Kotani T, Asada Y, Aratake Y, et al. Diagnostic usefulness of dipeptidyl aminopeptidase IV monoclonal antibody in paraffin-embedded thyroid follicular tumors. *J Pathol.* 1992;168:41-45.
10. Hirai K, Kotani T, Aratake Y, Ohtaki S, Kuma K. Dipeptidyl peptidase IV (DPP IV/CD26) staining predicts distant metastasis of "benign" thyroid tumor. *Pathology International.* 1999;49:264-265.
11. Yamashita H. Evaluation of thyroid nodules. In: Clark OH, Noguchi S, eds. *Thyroid Cancer—Diagnosis and Treatment.* St Louis, Mo: Quality Medical Publishing Inc; 2000:21-37.
12. Baloch ZW, Fleisher S, LiVolsi VA, Gupta PK. Diagnosis of "follicular neoplasm": a gray zone in thyroid fine-needle aspiration cytology. *Diagn Cytopathol.* 2002;26:41-44.
13. Miltenburg DM, Prost HM, Graviss EA, Arem R. The role of frozen section, gender, age, and tumor size in the differentiation of follicular adenoma from carcinoma: a meta-analysis. *Surgery.* 2000;128:1075-1081.
14. Umbricht CB, Saji M, Westra WH, Udelsman R, Zeiger MA, Sukumar S. Telomerase activity: a marker to distinguish follicular thyroid adenoma from carcinoma. *Cancer Res.* 1997;57:2144-2147.
15. Camargo RS, Scafuri AG, de Tolosa EM, Ferreira EA. DNA image cytometric analysis of differentiated thyroid adenocarcinoma specimens. *Am J Surg.* 1992;164:640-645.
16. Cusick EL, Ewen SWB, Krukowski ZH, Matheson NA. DNA aneuploidy in follicular thyroid neoplasia. *Br J Surg.* 1991;78:94-96.

©2004 American Medical Association. All rights reserved.
Downloaded From: http://archsurg.jamanetwork.com/ on 12/21/2014

17. Grant CS, Hay ID, Ryan JJ, Bergstralh EJ, Rainwater LM, Goellner JR. Diagnostic and prognostic utility of flow cytometric DNA measurements in follicular thyroid tumors. *World J Surg.* 1990;14:283-290.
18. Joensuu H, Klemi PJ, Eerola E. Diagnostic value of flow cytometric DNA determination combined with fine needle aspiration biopsy in thyroid tumors. *Anal Quant Cytol Histol.* 1987;9:328-334.
19. Shechtman L, Koren R, Horowitz A, Shechtman I, Halpern M, Gal R. Diagnostic value of AgNOR staining in thyroid cytology. *Anal Quant Cytol Histol.* 1998;20:187-191.
20. Zaczek M, Szot W, Chlap Z. Argyrophilic nucleolar organizer regions in proliferative lesions of the thyroid gland. *Anal Quant Cytol Histol.* 1996;18:1-8.
21. Karmakar T, Dey P. Role of AgNOR in diagnosis of thyroid follicular neoplasms on fine-needle aspiration smears. *Diagn Cytopathol.* 1995;12:148-151.
22. Ruschoff J, Prasser C, Cortez T, Hohne HM, Hohenberger W, Hofstadter F. Diagnostic value of AgNOR staining in follicular cell neoplasms of the thyroid: comparison of evaluation methods and nucleolar features. *Am J Surg Pathol.* 1993;17:1281-1288.
23. Lean CL, Delbridge L, Russell P, et al. Diagnosis of follicular thyroid lesions by proton magnetic resonance on fine needle biopsy. *J Clin Endocrinol Metab.* 1995;80:1306-1311.
24. Somorjai RL, Nikulin AE, Pizzi N, et al. Computerized consensus diagnosis: a classification strategy for the robust analysis of MR spectra, I: application to 1H spectra of thyroid neoplasms. *Magn Reson Med.* 1995;33:257-263.
25. Delbridge L, Lean CL, Russell P, et al. Proton magnetic resonance and human thyroid neoplasia, II: potential avoidance of surgery for benign follicular neoplasms. *World J Surg.* 1994;18:512-517.
26. Russell P, Lean CL, Delbridge L, May GL, Dowd S, Mountford CE. Proton magnetic resonance and human thyroid neoplasia, I: discrimination between benign and malignant neoplasms. *Am J Med.* 1994;96:383-388.
27. Yamashita H, Noguchi S, Murakami N, Adachi M, Maruta J. Immunohistological differentiation of benign thyroid follicular cell tumors from malignant ones: usefulness of anti-peroxidase and JT-95 antibodies. *Acta Pathol Jpn.* 1993;43:670-673.
28. Kawachi K, Matsushita Y, Yonezawa S, et al. Galectin-3 expression in various thyroid neoplasms and its possible role in metastasis formation. *Hum Pathol.* 2000;31:428-433.
29. Orlandi F, Saggiorato E, Pivano G, et al. Galection-3 is a presurgical marker of human thyroid carcinoma. *Cancer Res.* 1998;58:3015-3020.
30. Fernandez PL, Merino MJ, Gomez M, et al. Galectin-3 and laminin expression in neoplastic and non-neoplastic thyroid tissue. *J Pathol.* 1997;181:80-86.
31. Cvejic D, Savin S, Panuovic I, Tatic S, Havelka M, Sinadinovic J. Immnohistochemical localization of galectin-3 in malignant and benign human thyroid tissue. *Anticancer Res.* 1998;18:2637-2641.

IN OTHER AMA JOURNALS

ARCHIVES OF INTERNAL MEDICINE

Hormone Replacement Therapy and Associated Risk of Stroke in Postmenopausal Women

Rozenn N. Lemaitre, PhD, MPH; Susan R. Heckbert, MD, PhD; Bruce M. Psaty, MD, PhD; Nicholas L. Smith, PhD; Robert C. Kaplan, PhD; W. T. Longstreth, Jr, MD, MPH

Background: There is little information about the risk of stroke in relation to time since initiation of hormone therapy and in relation to estrogen dose.
Methods: We conducted a population-based case-control study at Group Health Cooperative (GHC), a health maintenance organization in the greater Seattle (Wash) area, to assess the association of hormone replacement therapy with the risks of incident ischemic and hemorrhagic stroke. Cases were all postmenopausal women with incident stroke at GHC during July 1989 through December 1998 (726 ischemic strokes and 213 hemorrhagic strokes). Controls were randomly selected from GHC enrollees and frequency matched to cases on age and calendar year (n=2525). Hormone use was assessed from computerized pharmacy data. We reviewed the medical record to confirm eligibility and assess other risk factors.
Results: After risk factor adjustment, ischemic stroke was not associated with current use of estrogen with progestin (odds ratio [95% confidence interval]: 0.97 [0.69-1.37]) or without (0.94 [0.72-1.23]) compared with never use. Similarly, hemorrhagic stroke was not associated with current use of estrogen with progestin (0.74 [0.43-1.28]) or without (1.06 [0.71-1.56]). However, the risks of ischemic stroke and hemorrhagic stroke were increased 2-fold during the first 6 months of hormone use (ischemic stroke: 2.16 [1.04-4.49], hemorrhagic stroke: 2.20 [0.83-5.81]). Risk of ischemic stroke also increased with estrogen dose (*P* for trend=.03).
Conclusion: The transitory increase in risks of ischemic stroke and hemorrhagic stroke associated with initiation of hormone replacement therapy merits further investigation. (*2002;162:1954-1960*)

Corresponding author and reprints: Rozenn N. Lemaitre, PhD, MPH, University of Washington, Cardiovascular Health Research Unit, Metropolitan Park, East Tower, Suite 1360, 1730 Minor Ave, Seattle, WA 98101 (e-mail: rozenl@u.washington.edu).

©2004 American Medical Association. All rights reserved.
Downloaded From: http://archsurg.jamanetwork.com/ on 12/21/2014