

SECTION EDITOR: GRACE S. ROZYCKI, MD

## Image of the Month

Patrick H. Hemmer, MD; Clark J. Zeebregts, MD; Joop van Baarlen, MD; Joost M. Klaase, MD, PhD

**A** 34-YEAR-OLD WOMAN WAS ADMITTED WITH abdominal pain predominantly at the right side and rectal bleeding of several days' duration. She had been diagnosed as having Gardner syndrome 2 years before. Among the manifestations of this disease were multiple osteomas and polyposis coli, for which a subtotal colectomy and ileorectal anastomosis had been performed. Physical examination findings revealed fullness of the abdomen with a nonmobile mass measuring approximately 30 cm in diameter. No source for the rectal bleeding could be detected at rectoscopy. Ultrasonography showed a very large, solid intra-abdominal tumor, which was confirmed by computed tomographic scanning. The tumor, measuring 23 × 15 cm, extended onto the left liver lobe and could not be distinguished from the abdominal wall (**Figure 1**). To obtain histologic characteristics, the abdomen was opened through a left pararectal incision. Immediately, it became clear that there was tumor infiltration into the left rectus muscle. A large biopsy specimen of this tissue was taken, as well as incisional biopsy specimens of tumor infiltrating the mesentery (**Figure 2**). The tumor was considered unresectable because of diffuse large- and small-bowel mesenteric invasion. The patient is currently being treated with tamoxifen citrate, 40 mg/d, and was responding well at this report, 7 months after the operation.

### What Is the Diagnosis?

- A. Gastrointestinal stromal tumor
- B. Fibrosarcoma
- C. Desmoid tumor
- D. Ovarian carcinoma

From the Department of Surgery, Medisch Spectrum Twente (Drs Hemmer, Zeebregts, and Klaase), and Pathology Laboratory "Twente-Achterhoek" (Dr van Baarlen), Enschede, the Netherlands.

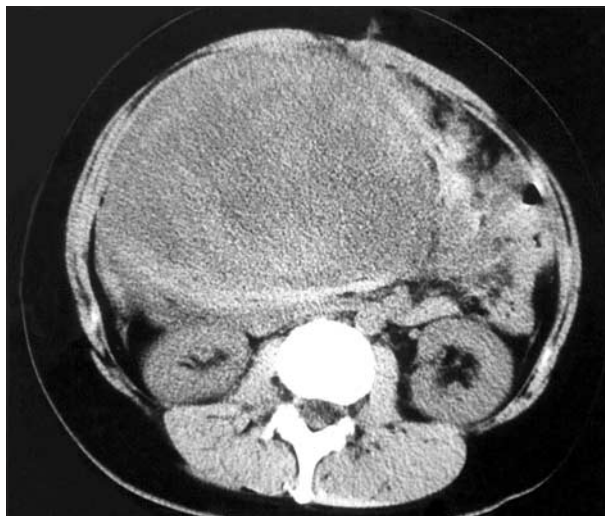


Figure 1.

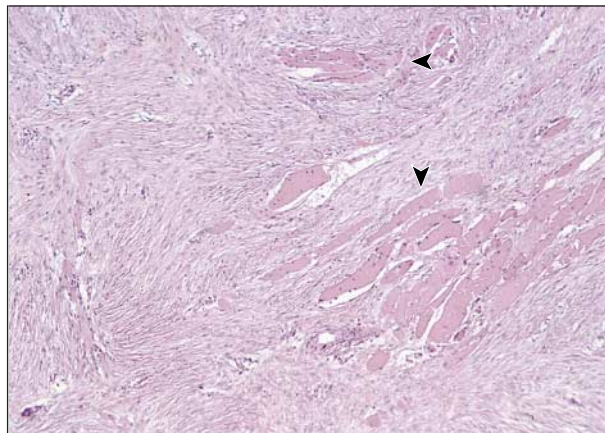


Figure 2.