POSTER SESSION

Pancreatic Head Excavation

A Variation on the Theme of Duodenum-Preserving Pancreatic Head Resection

Dana K. Andersen, MD; Mark D. Topazian, MD

Hypothesis: Despite the introduction of new methods for duodenum-preserving pancreatic head resection, such as the Beger and Frey procedures, the management of benign lesions of the proximal pancreas remains controversial. We developed a modification of the duodenum-preserving pancreatic head resection in which the proximal pancreatic duct or central core of the pancreatic head is excised by ultrasonic dissection and examined the feasibility, safety, and outcomes of this new procedure.

Design and Setting: Prospective cohort study in an academic tertiary care referral center.

Patients: From April 1, 2001, to September 8, 2003, 6 patients with either chronic pancreatitis (4) or benign tumors of the pancreatic head (2) underwent ultrasonic excavation of the pancreatic head, with reconstruction by a single longitudinal, Roux-en-Y pancreaticojejunostomy.

Main Outcome Measures: Safety and cost were assessed by measures of operative time, blood loss, nasogastric drainage, and length of stay. Any complications and the degree of full functional recovery were noted.

Results: The technique of ultrasonic excavation of the central pancreatic head is reviewed in detail. Operative time ranged from 344 to 427 minutes (average, 390 minutes); blood loss ranged from 200 to 1300 mL (average, 475 mL); nasogastric drainage ranged from 3 to 5 days; and length of stay ranged from 6 to 8 days. No major complications occurred. Two patients had transient, probable drug-related ileus after discharge. All patients had full functional recovery.

Conclusions: Our modification of the technique of duodenum-preserving pancreatic head resection using ultrasonic dissection and longitudinal reconstruction appears feasible, safe, and effective for benign disease of the proximal pancreas.

Arch Surg. 2004;139:375-379

From the Department of Surgery, University of Massachusetts Medical School and UMass Memorial Health Care Inc, Worcester (Dr Andersen); and Division of Digestive Diseases, Department of Medicine, Yale University School of Medicine and Yale-New Haven Hospital, New Haven, Conn (Dr Topazian). Dr Topazian is now with the Division of Digestive Diseases, Department of Medicine, Mayo Graduate School of Medicine, Rochester, Minn.

THE MANAGEMENT OF BENIGN and premalignant lesions of the head of the pancreas is controversial. Benign cystic and solid neoplasms and inflammatory masses of the proximal pancreas are frequently treated surgically by pancreaticoduodenectomy (Whipple procedure), although newer, more conservative operative methods have been introduced. The duodenum-preserving head resection described in 1980 by Beger and colleagues[1] from the University of Ulm (Ulm, Germany) and the extended pancreaticojejunostomy with conization of the pancreatic head described in 1987 by Frey and Smith[2] of the University of California at Davis comprise new approaches to proximal inflammatory lesions and benign tumors. Initial experience with these procedures, however, has suggested that the perioperative morbidity of the Beger procedure is similar to that of the Whipple procedure,[3-5] and the Frey procedure is not applicable to conditions other than chronic pancreatitis due to the minimal extent of pancreatic head removal.[6] Although the perioperative morbidity of the Frey procedure is less than that of the Beger or Whipple procedures,[6,7] due in part to the relative safety of its side-to-side Roux-en-Y pancreaticojejunostomy, its application to treat ductular or parenchymal lesions of the proximal pancreas is limited.

To achieve surgical removal of benign and premalignant lesions of the pancreatic head, with preservation of the duodenum and distal common bile duct and with reestablishment of pancreaticoenteric continuity by means of the safer side-to-side anastomosis, we have developed a technical variation on the method of duodenum-preserving pancreatic head resection. This method includes the true excavation of the central core of the proxi-

©2004 American Medical Association. All rights reserved.
Downloaded From: http://archsurg.jamanetwork.com/ on 05/03/2015

Demographics, Indications, and Outcomes of Duodenum-Preserving Pancreatic Head Excavation

Patient No./ Sex/Age, y	Preoperative Diagnosis	Operative Time, min*	Blood Loss, mL	Length of Nasogastric Intubation, d	Length of Hospital Stay, d	Morbidity	Functional Outcome
1/M/38	CP	415	500	5	8	None	Excellent
2/M/46	CP	380	1300	3	6	None	Excellent
3/M/56	BT-IPMT	382	350	3	7	Ileus, late	Excellent
4/F/32	CP	427	200	3	8	Ileus, late	Excellent
5/F/60	BT-C	344	200	3	8	None	Excellent
6/M/51	CP, PC	393	300	3	8	None	Excellent

Abbreviations: BT-C, benign tumor–cystadenoma; BT-IPMT, benign tumor–intraductal papillary mucinous tumor; CP, chronic pancreatitis; PC, pseudocyst.
*Includes intraoperative fiber optic pancreatoscopy in patients 1 and 3.

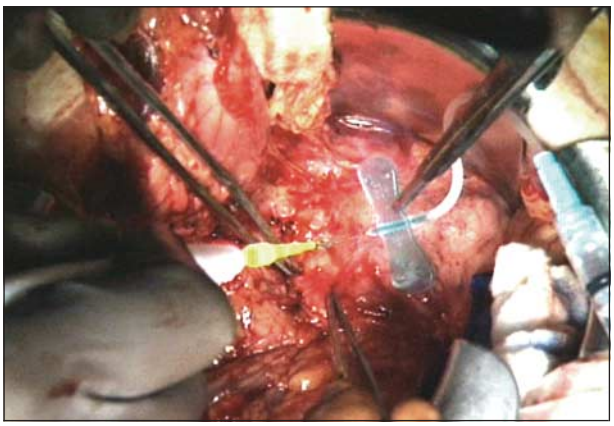

Figure 1. Localization and entry into the pancreatic duct. The pancreatic duct is punctured with a 21-gauge butterfly needle in the proximal body of the gland halfway between the superior and inferior margins of the pancreas. The needle guides cautery dissection down into the duct.

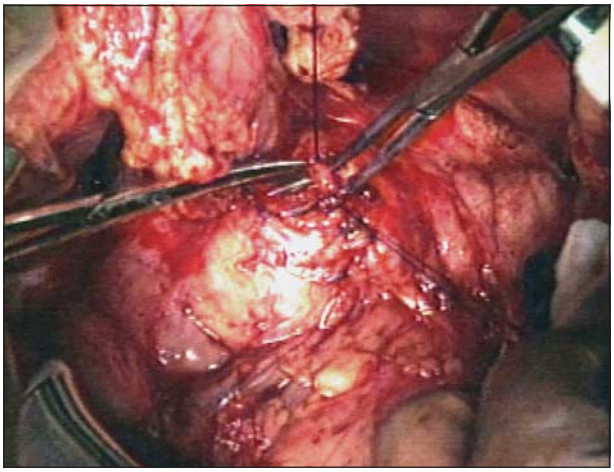

Figure 2. Division of the gastroduodenal artery overlying the anterior surface of the pancreas. Suture ligatures are placed before the artery is divided at the point along the proposed course of the pancreatic dochotomy.

mal pancreas, including the proximal pancreatic ductal system from the ampulla to the neck of the pancreas, with conservation of the superior, posterior, inferior, and lateral (periduodenal) margins of the pancreatic head. This excavation is performed with the use of an ultrasonic aspirator and dissector (Cavitron, System 200; Valley Lab Inc, Norwalk, Conn). The resulting cavity and any associated main pancreatic dochotomy are then drained into the jejunum by means of a single side-to-side, Roux-en-Y pancreaticojejunostomy. Herein, we report the technical details of this procedure and our clinical experience in an initial series of 6 patients.

METHODS

From April 1, 2001, to September 8, 2003, 4 patients with chronic pancreatitis and obstructive pancreatopathy, 1 patient with a proximal intraductal papillary mucin-secreting tumor (IPMT), and 1 patient with a pancreatic head cystadenoma were treated with central excavation of the pancreatic head and Roux-en-Y pancreaticojejunostomy (**Table**). With the exception of the patient with a 3-cm, incidentally discovered cystadenoma, all of the patients were symptomatic with recurrent acute pancreatitis or chronic relapsing pancreatitis. The frequency of attacks ranged from monthly (in patients with alcohol-associated chronic pancreatitis) to twice a year (in the patient with IPMT). Each patient had been hospitalized at least once with a severe attack of pain. All patients were abstinent from alcohol for at least 6 months before operation.

All patients were counseled preoperatively on the expectation that a version of the Beger or Frey procedure would be performed, with the understanding and consent that if malignancy or pancreaticoduodenal ischemia was encountered, a pancreaticoduodenectomy would be performed.

In patients with chronic pancreatitis or IPMTs, the procedure began with an upper midline incision, full dissection and exposure of the entire pancreas, and a generous Kocher maneuver. Needle localization of the pancreatic duct at the level of the neck or proximal body of the pancreas was performed, and pancreatic juice was aspirated (**Figure 1**). The anterior branch of the gastroduodenal artery was identified, divided, and ligated as it coursed over the anterior surface of the pancreatic head (**Figure 2**), and the duct was transected near the point of original entry. The proximal ductal system was then excavated circumferentially by means of the ultrasonic aspirator and dissector at a setting of 80% maximal amplitude. The excavation allowed the maintenance of a rim of parenchyma and pancreatic capsule that averaged 3 to 5 mm in thickness superiorly, inferiorly, and posteriorly. As the excavation proceeded toward the duodenum, the intrapancreatic portion of the distal common bile duct was identified (**Figure 3**) and preserved. The pancreatic duct was transected at the ampulla, and the proximal and distal margins of the duct were sent for frozen section analysis. As the excavation progressed, numerous small bleeding sites were controlled by electrocoagulation, and larger bleeding sites were controlled by suture ligatures of fine silk (**Figure 4**). Reconstruction was performed by a retrocolic side-to-side, Roux-en-Y pancreaticojejunostomy (**Figure 5**). A 2-layer anastomosis was performed with full-thickness figure-of-8 sutures of 3-0 absorbable suture on the inner layer and interrupted horizontal seromuscular-to-capsular sutures of fine silk on the outer layer. No stents were

©2004 American Medical Association. All rights reserved.
Downloaded From: http://archsurg.jamanetwork.com/ on 05/03/2015

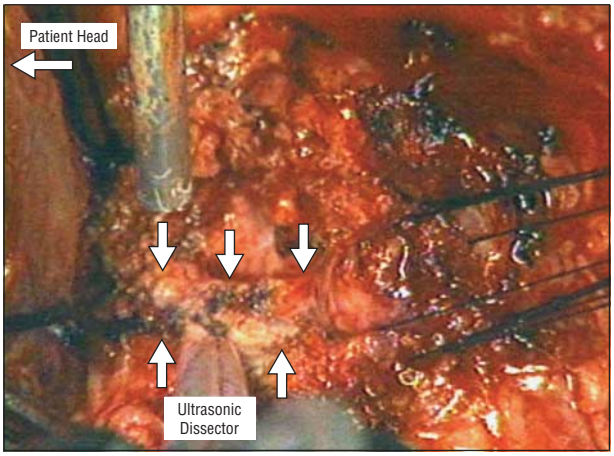

Figure 3. Identification of the distal common bile duct. The dissection is carried medially using an ultrasonic aspirator and dissector (Cavitron, System 200; Valley Lab Inc, Norwalk, Conn) until the tubular structure of the intrapancreatic common bile duct is encountered (arrows). This is carefully separated from the parenchyma for approximately one third to half of its circumference, and the common bile duct is followed inferiorly to the ampullary apparatus as the core of the pancreatic head is retracted with stay sutures. Care is taken not to injure the bile duct.

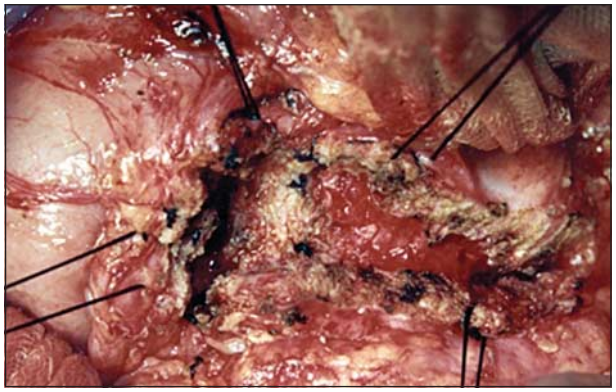

Figure 4. Completed pancreatic head excavation. The completed excavation is shown in a patient with chronic obstructive pancreatopathy. The dilated, inflamed pancreatic duct extends from the neck of the gland distally, and the central core of the pancreatic head has been resected.

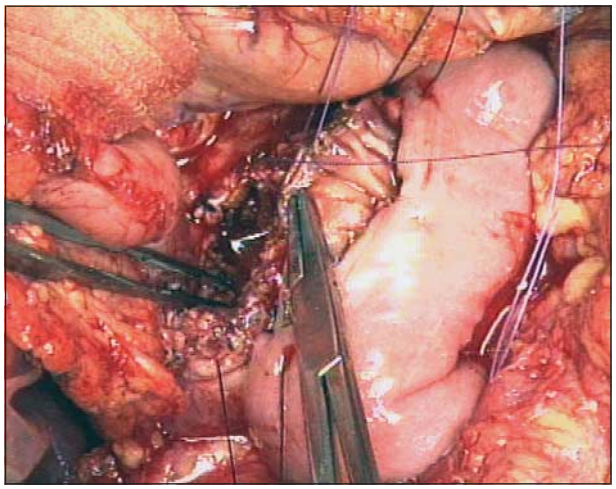

Figure 5. Pancreaticoenteric reconstruction. A retrocolic side-to-side, Roux-en-Y pancreaticojejunostomy is performed using a 2-layer technique. Careful hemostasis of the proximal pancreatic cavity is achieved with electrocoagulation and the liberal use of fine silk ligatures of bleeding sites.

used. (A videotape of this procedure is available from Ciné-Med, Inc, Woodbury, Conn, at http://cine-med.com, videotape No. ACS2242.)

In the patient with a 3-cm cystadenoma of the pancreatic head, the proximal pancreas was dissected and fully exposed from the head of the gland to the midbody, and a generous Kocher maneuver was performed. With verification that the lesion did not involve the posterior capsule but appeared completely confined within the parenchyma of the pancreatic head, a longitudinal pancreatotomy was performed overlying the lesion. Using the dissector, the lesion was excavated (or enucleated) with identification of the main pancreatic duct, which was adherent to the mass. The duct was transected proximally and distally and either ligated (proximally) or left in continuity with the resulting cavity. The lesion was completely excised with preservation of a margin of parenchyma and capsule posteriorly and medially. Bleeding sites were controlled by electrocoagulation or fine silk sutures. The excised lesion was evaluated histologically by frozen section analysis and was confirmed to be benign. A retrocolic side-to-side, Roux-en-Y pancreaticojejunostomy was again used.

In all cases, 2 closed system drains were placed, and octreotide acetate, 100 µg, was administered subcutaneously every 8 hours beginning immediately postoperatively. The nasogastric tube was removed when bowel sounds were present, and clear liquids were advanced ad libidum beginning the following day. With the diet advanced to full liquids and no increase in peritoneal drainage observed, use of the octreotide was discontinued, the drains were removed, and the patients were discharged with instructions to follow a regular low-fiber, low-fat diet.

Postoperatively, the patients were seen biweekly for 4 to 6 weeks, then monthly for 2 to 3 months, then semiannually. In addition to routine postoperative evaluations, signs and symptoms of exocrine and endocrine insufficiency were evaluated, as was the degree of relief of preoperative symptoms.

RESULTS

PATHOLOGICAL FINDINGS

Final histologic analysis of all resected specimens revealed benign disease with negative (normal or PanIN 1A) margins of parenchyma and pancreatic ducts. Evaluations of the parenchymal margins were facilitated by the absence of char artifact due to the restricted use of the electrocautery during dissection.

POSTOPERATIVE COURSE

The length of nasogastric decompression and hospital stay averaged 3.3 and 7.5 days, respectively (Table). No patient required intraoperative transfusion or postoperative intensive care unit care. All patients were discharged with a prescription for oral pain medication, which varied depending on their preoperative analgesic requirements. All patients were discharged within 8 days of operation, tolerating a regular diet (low fiber, low fat).

COMPLICATIONS

No major complications were encountered. Two patients required readmission at 2 and 4 weeks postoperatively, respectively, for nausea and/or vomiting. These symptoms resolved spontaneously, and abdominal ra-

©2004 American Medical Association. All rights reserved.
Downloaded From: http://archsurg.jamanetwork.com/ on 05/03/2015

diographs revealed multiple air-filled loops of bowel consistent with ileus. Both patients were consuming oral narcotic analgesics, and their symptoms responded to conversion to nonnarcotic analgesics.

OUTCOMES

No patient has had any further abdominal or gastrointestinal complaints. No further symptoms of pancreatitis have occurred in any patient, and no new exocrine or endocrine insufficiency has occurred at 0.3 to 2.7 years postoperatively.

COMMENT

Although the Whipple procedure remains the surgical gold standard for malignant lesions of the head of the pancreas, ampulla, and distal common bile duct, its use for benign and premalignant lesions is questioned based on cost and safety. Even in expert hands, the morbidity (perioperative complication) and mortality risks of the Whipple procedure range from 25% to 50% and 1% to 5%, respectively.[8,9]

Preservation of the duodenum, distal common bile duct, and a portion of the ventral region of the pancreas are attractive advantages of the Beger procedure and are thought to contribute to its reduced incidence of long-term metabolic deficiency.[3,4,10,11] The perioperative complication rate of the Beger procedure is similar to that of the Whipple procedure, however, due in part to the requirement of an end-to-end pancreaticojejunal anastomosis, with or without an additional side-to-side anastomosis to the same jejunal limb.[3,4] In addition, the requirements to identify the posterior branch of the gastroduodenal artery and to preserve the intrapancreatic choledochal and ampullary structures are technically challenging as well.

The Frey procedure is easier to perform because it is essentially a decompressive procedure rather than a resectional operation. As originally described by Frey and Smith,[2] the conization of the pancreatic head permits a wide longitudinal anastomosis but still leaves the posterior wall of the duct in place. The extensive decompression of the entire gland seems to account for the improved long-term pain relief associated with the Frey procedure compared with the more commonly performed modified Puestow procedure,[6,7,12,13] but, to our knowledge, no prospective, randomized comparison of these procedures has been published. Furthermore, a persistent incidence of recurrent symptoms in 10% to 20% of patients has been cited for both the Frey and modified Puestow operations.[8,12,13]

The reduced perioperative complication rate associated with the Frey procedure seems to be due in part to the reduced risk of leak from the longitudinal pancreaticojejunal anastomosis. This reduced leak rate may well be owing to the increased prevalence of chronic pancreatitis in patients undergoing decompressive procedures or may represent an inherent advantage of the side-to-side anastomotic technique.

Because of the morbidity risk and shortcomings of both the Beger and Frey procedures, we sought a better method to remove ductular or parenchymal lesions of the proximal pancreas, to preserve the duodenum, distal common bile duct, and pancreatic head capsule, and to allow a side-to-side pancreaticoenteric reconstruction. Two patients with idiopathic chronic pancreatitis (patients 1 and 2) were encountered in whom an IPMT was suspected but not confirmed preoperatively. A modification of the Frey procedure was performed in both patients in which the ultrasonic aspirator and dissector was used to remove the entire proximal ductal system. The procedures were uncomplicated in both patients and were accompanied by completely benign postoperative recoveries. Subsequently, a patient had a benign IPMT of the proximal duct that was diagnosed by intraoperative pancreatoscopy, and the proximal ductular system was also excised uneventfully using the ultrasonic dissection method. Two subsequent patients with chronic obstructive pancreatitis associated with either an adjacent cystic lesion (pseudocyst) or severe duct distortion were similarly treated. A sixth patient with an asymptomatic, incidentally discovered cystadenoma of the head of the pancreas was also treated. In all patients, a perimeter or shell of pancreatic capsule and parenchyma was preserved, and a side-to-side reconstruction was easily performed. All patients had an uncomplicated intraoperative course and required no transfusions or intensive care. The benign postoperative course of each patient, albeit with relatively short follow-up, suggests that this method of excision and reconstruction may have distinct advantages over other methods of duodenum-preserving pancreatic head resection.

Our method of excavation of the pancreatic head allows the preservation of the entire posterior capsule and the neck of the pancreas, which is similar to the technique of the Frey procedure and differs from the technique of the Beger procedure in which the neck is transected. The excavation procedure completely removes the proximal main pancreatic (Wirsung) duct, similar to the Beger procedure, but differs from the Frey procedure in which the proximal pancreatic duct is widely opened but not completely removed.

We propose this excavation method for removal of benign lesions or the diseased central ductal system of the proximal pancreas. We would not propose to use the method for removal of a lesion that is seen to extend to or through the posterior capsule of the pancreatic head on preoperative imaging studies. In the event of a breach of the capsule during the excavation procedure, reapproximation of the capsule with interrupted sutures would seem prudent. The advisable thickness of the posterior pancreatic margin is conjectural. Because no anastomosis is being performed to the posterior margin of the head, the capsule itself may be sufficient as a posterior partition. Anteriorly, where the anastomosis is performed, a margin sufficient to anchor a 2-layer anastomosis is needed.

The use of the ultrasonic aspirator and dissector allows a better visualized plane of dissection than can be achieved with electrocautery and avoids the char artifact of extensive cautery dissection. We use the ultrasonic aspirator and dissector for all Beger procedures, central pancreatectomies, and enucleation procedures, as

©2004 American Medical Association. All rights reserved.
Downloaded From: http://archsurg.jamanetwork.com/ on 05/03/2015

originally suggested by Carey.[14] Ultrasonic dissection is more tedious than cautery dissection, but the improved visibility of the tissue planes and the ease with which the intrapancreatic bile duct is identified appear to justify the additional length of time required for the ultrasonic dissection.

The use of our technique for the treatment of chronic pancreatitis provides a combined resection-and-decompression strategy to the patient with ductular and parenchymal disease. Because recurrent symptoms are often related to recurrent inflammation in the proximal gland,[15] the excisional component of our technique may provide improved long-term pain relief. Outcome studies with prolonged periods of follow-up are necessary to establish this effect, but our initial experience provides the rationale for further studies.

The treatment of benign and premalignant tumors requires that adequate removal of all pathologic tissue is accomplished. For a discrete lesion, such as an islet cell tumor or a cystadenoma, our technique provides for a generous enucleation of the lesion, provided that the lesion is small or localized so that a posterior margin can be preserved. For a ductular lesion such as an IPMT, the necessary extent of resection is controversial. Currently, there is no consensus on the extent of resection necessary for the proper management of an IPMT, and this controversy is related to the range of biological behavior of this lesion.[12] An IPMT may be multicentric and metachronous. It may develop in unresected pancreas, as it has in 1 of our patients, who developed a focally dilated ductal side branch in the pancreatic body 2 years after pancreatic head excavation. Although some have advocated total pancreatectomy for IPMTs, we have favored partial pancreatic resection with either the Whipple procedure (when extensive uncinate disease is present or the lesion extends into the ampulla) or pancreatic head excavation (when the lesion appears small and is confined to the central core of the gland on imaging studies). This approach preserves pancreatic endocrine function but requires careful follow-up imaging of the remaining pancreas over time. The remaining rim of pancreatic head must also be imaged and is readily apparent during endoscopic ultrasound. The confirmation of normal ductal epithelial findings at the margins of the resection is therefore a requirement for the excavation technique. A failure to obtain confirmation of satisfactorily benign duct margins intraoperatively would be an indication to abandon the excavation approach and convert to a full resectional (eg, Whipple) procedure.

Our innovation is a modification or hybrid procedure of both the Beger and Frey procedures. The care of our patient with IPMT was reviewed by both Drs Beger and Frey, and each surgeon declared that the technique was a modification of their own technique. We agree, and we suspect that the method that we have described may offer advantages over either technique in patients with benign disease of the pancreatic head. We therefore confirm that the use of the ultrasonic aspirator and dissector to achieve a subtotal pancreatic head resection is technically feasible, safe, and cost-effective. More experience and prospective trials that compare the outcomes of these techniques are warranted.

Accepted for publication November 17, 2003.

This paper was presented at the 84th Annual Meeting of the New England Surgical Society; September 19, 2003; Newport, RI; and is published after peer review and revision.

Corresponding author and reprints: Dana K. Andersen, MD, Department of Surgery S3-810, University of Massachusetts Medical School, 55 Lake Ave N, Worcester, MA 01655 (e-mail: dana.andersen@umassmed.edu).

REFERENCES

1. Beger HG, Witte C, Kraas E, Bittner R. Erfahrung mit einer das Duodenum erhaltenden Pankreaskopfresektion bei chronisher Pankreatitis. *Chirurg.* 1980;51:303-309.
2. Frey CF, Smith GJ. Description and rationale of a new operation for chronic pancreatitis. *Pancreas.* 1987;2:701-707.
3. Beger HG, Krautzberger W, Bittner R, Buchler M, Limmer J. Duodenum-preserving resection of the head of the pancreas in patients with severe chronic pancreatitis. *Surgery.* 1985;97:467-473.
4. Buchler M, Friess H, Muller MW, Wheatley AM, Beger HG. Randomized trial of duodenum-preserving pancreatic head resection versus pylorus-preserving Whipple in chronic pancreatitis. *Am J Surg.* 1995;169:65-70.
5. Aspelund G, Topazian MD, Andersen DK. "Beger" versus [abstract] "Frey": a comparison of limited pancreatic head resections for benign disease. *HPB.* 2000;2:203.
6. Frey CF, Amikura K. Local resection of the head of the pancreas combined with longitudinal pancreaticojejunostomy in the management of patients with chronic pancreatitis. *Ann Surg.* 1994;220:492-507.
7. Izbicki JR, Bloechle C, Broering DC, Knoefel WT, Kuechler T, Broelsch CE. Extended drainage versus resection in surgery for chronic pancreatitis: a prospective randomized trial comparing the longitudinal pancreaticojejunostomy combined with local pancreatic head excision with the pylorus-preserving pancreatoduodenectomy. *Ann Surg.* 1998;228:771-779.
8. Yeo CJ, Cameron JL, Sohn TA, et al. Six hundred fifty consecutive pancreaticoduodenectomies in the 1990s: pathology, complications and outcomes. *Ann Surg.* 1997;226:248-257.
9. Strasberg SM, Drebin JA, Soper NJ. Evolution and current status of the Whipple procedure: an update for gastroenterologists. *Gastroenterology.* 1997;113:983-994.
10. Eddes EH, Masclee AAM, Gooszen HG, Frolich M, Lamers CBHW. Effect of duodenum-preserving resection of the head of the pancreas on endocrine and exocrine pancreatic function in patients with chronic pancreatitis. *Am J Surg.* 1997;174:387-392.
11. Slezak LA, Andersen DK. Pancreatic resection: effects on glucose metabolism. *World J Surg.* 2001;25:452-460.
12. Izbicki JR, Bloechle C, Broering DC, et al. Duodenum-preserving resection of the head of the pancreas in chronic pancreatitis: a prospective randomized trial. *Ann Surg.* 1995;221:350-358.
13. Conley CR, Scheithauer BW, Weiland LH, van Heerden JA. Diffuse intraductal papillary adenocarcinoma of the pancreas. *Ann Surg.* 1987;205:246-249.
14. Carey LC. Discussion of "islet cell tumors": postgraduate course on hepatobiliary and pancreatic disease. Presented at: American College of Surgeons Clinical Congress; October 22-27, 1995; New Orleans, La.
15. Ihse I, Borch K, Larsson J. Chronic pancreatitis: results of operations for relief of pain. *World J Surg.* 1990;14:53-59.

©2004 American Medical Association. All rights reserved.
Downloaded From: http://archsurg.jamanetwork.com/ on 05/03/2015