ORIGINAL ARTICLE

Role of a Minimally Invasive Approach in the Management of Laparoscopic Adjustable Gastric Banding Postoperative Complications

Gianfranco Silecchia, MD, PhD; Nicola Perrotta, MD; Cristian Boru, MD; Alessandro Pecchia, MD; Mario Rizzello, MD; Francesco Greco, MD; Alfredo Genco, MD; Vincenzo Bacci, MD; Nicola Basso, MD

Hypothesis: Complications after laparoscopic adjustable gastric banding as treatment for morbid obesity may require a major reintervention. A minimally invasive approach represents an attractive management alternative for such complications.

Design: Prospective case series.

Setting: Major academic medical and surgical center.

Patients: From January 1996 to July 2003, 47 patients who had undergone laparoscopic adjustable gastric banding were operated on again. Considering the causes for reoperation, the patients were divided into 4 groups: group A had major complications (n=26); group B, minor complications (n=11); group C, psychological problems (n=6); and group D, insufficient weight loss (n=4).

Interventions: Forty-three procedures, 38 using general anesthesia (groups A, C, and D) and 5 using local anesthesia (group B), were performed.

Main Outcome Measures: Feasibility, safety, and effectiveness of a minimally invasive approach in the treatment of laparoscopic adjustable gastric banding complications.

Results: In group A, 9 of 10 patients with irreversible gastric pouch dilatation and 15 of 16 with intragastric band migrations were treated laparoscopically. In group B, 5 ports were substituted and 2 reconnections of the catheter-port system were performed. In group C, 6 laparoscopic band removals were carried out. In group D, 4 laparoscopic revision procedures for insufficient weight loss were performed. The operative mortality was nil. The most frequent cause of reoperation was intragastric migration (37.2%). A minimally invasive approach was adopted in 94.7% of cases.

Conclusion: Laparoscopy is safe and effective, even as a second operative procedure.

Arch Surg. 2004;139:1225-1230

Obesity represents one of the major public health problems in Western as well as in developing countries, and it may be defined as a "new global epidemic."[1-6] In the United States, the incidence of obesity is around 25% (morbid obesity is more than 5%), while in Italy there are about 4 million obese patients (9.1% of total population). Morbid obesity is a chronic disease, characterized by a body mass index (BMI) (weight in kilograms divided by height in meters squared) greater than 40 or greater than 35 when serious comorbidities are present.

Morbid obesity is often associated with diabetes, cardiovascular diseases, osteoarthropathies,[7] and different types of neoplasm. Unfortunately, medical treatment has been shown to be effective in fewer than 5% of cases. At present, the surgical treatment of morbid obesity, bariatric surgery, represents the only long-term effective treatment. The therapeutic goal is to achieve a significant and stable weight loss with a BMI less than 35 or an excess weight loss of 50%.

Laparoscopic adjustable gastric banding (LAGB) using the Kuzmak silicone ring (BioEnterics LAP-BAND System; INAMED, Santa Barbara, Calif) or the Swedish Adjustable Gastric Band (Ethicon Endo-Surgery, Inc, Cincinnati, Ohio),[8] proposed by Halberg et al,[9] has become in the last decade the most popular procedure in Europe and Australia (more than 120 000 LAP-BAND systems have been positioned). In Italy, according to the data supplied by GILB (an Italian group for LAP-BAND use), from January 1996 until present, about 3600 LAP-BAND systems have been positioned. The reasons are the relative simplicity of the laparoscopic procedure without visceral sections or anastomoses, the adjustability of the band, the almost complete reversibil-

Author Affiliations:
Departments of Surgery "Paride Stefanini" (Drs Silecchia, Perrotta, Boru, Pecchia, Rizzello, Greco, Genco, and Basso) and Clinical and Applied Medical Therapy (Dr Bacci), Policlinico Umberto I, Università "La Sapienza" Roma, Rome, Italy.

©2004 American Medical Association. All rights reserved.
Downloaded From: http://archsurg.jamanetwork.com/ on 04/26/2015

Table 1. Causes of Reoperation After Laparoscopic Adjustable Gastric Banding

Causes of Reoperation	No. of Patients
Major complications	26
Acute slippage of the stomach	2
Irreversible pouch dilatation	8
Intragastric band migration	16*
Minor complications	7
Infections	1
Disconnections	4
Twists	2
Psychological problems	6
Insufficient weight loss	4
Total	**43**

*In 5 cases, "spy" port infection was present.

ity, and the rapid hospital discharge of the patient.[10-12] The therapeutic success of LAGB is strictly related to careful patient selection, the surgeon's experience, and the overall management by a multidisciplinary team (surgeon, nutritionist, endocrinologist, and psychiatrist).[13]

The international literature reports specific postoperative complications after LAGB as major complications (early and late: acute slippage of the gastric wall, irreversible pouch dilatation, esophageal dilatation with dysphagia, and intragastric band migration) and minor complications (subcutaneous port infections, leaks, disconnections of the port-catheter system, and port twist). The incidence of these complications ranges between 0% and 31%, leading to a mean reoperative rate of 7.4%,[14,15] which can increase to a maximum of 58% in some series.[13,16-34]

The aim of this prospective study was to evaluate the incidence of postoperative complications after LAGB and possible causes and management with a minimally invasive approach.

METHODS

Between January 1996 and July 2003, 313 consecutive morbidly obese patients underwent LAGB, according to the perigastric technique described by Cadiere et al[10] or the approach "through pars flaccida" in the last 72 patients. Forty-seven patients (39 women and 8 men; mean age, 41.6 years), who developed post-LAGB complications, were the subjects of the study. The mean BMI pre-LAGB was 46.1 (range, 36-59). Forty-one patients had major or minor complications, and 6 had psychological problems and requested the removal of the band in absence of any surgical complication. At reoperation, the mean BMI of the patients with major complications was 35.5. Causes of reoperation are reported in **Table 1**.

A total of 43 reoperations were performed. Thirty-eight reoperations were performed using general anesthesia; of these, 36 were performed laparoscopically. Five reoperations were performed using local anesthesia, in ambulatory or in "1-day surgery" settings. Intraoperative upper gastrointestinal endoscopy was performed during 12 reoperations.

The incidence of major complications was 8.3%, and all but 1 occurred during the learning-curve period (1-50 patients). The multidisciplinary selection allowed earlier detection of band-related complications and improved patients' compliance.

Figure 1. Gastric pouch dilatation (megulmine diatrizoate swallow radiograph).

RESULTS

MAJOR COMPLICATIONS (GROUP A)

Irreversible Gastric Pouch Dilatation

The diagnosis was suspected on the basis of symptoms (vomiting, food intolerance) and confirmed by radiological examination in 10 patients (**Figure 1**). Mean BMI was 50.9 before surgery and 36.9 at the moment of diagnosis. All cases were initially treated conservatively with a nasogastric tube, intravenous proton pump inhibitors (40 mg of omeprazol), and metoclopramide hydrochloride (30 mg intravenously 3 times a day). After 2 to 21 days, reoperation was performed.

Two acute slippages (postoperative day 2 and 8) and 8 long-term dilatations (up to 12 months postoperative) occurred. In 9 cases, the band was removed laparoscopically (1 conversion) (mean operative time, 70 minutes); in 1 case, the band was repositioned but eventually removed after 12 months because of irreversible pouch dilatation (BMI, 29).

Intragastric Band Migration

Diagnosis was established by routine endoscopic examination an average of 26.4 months after surgery. The barium swallow radiography results were positive only when more than 50% of the prosthesis migrated into the gastric cavity, creating the "double lumen effect"

©2004 American Medical Association. All rights reserved.
Downloaded From: http://archsurg.jamanetwork.com/ on 04/26/2015

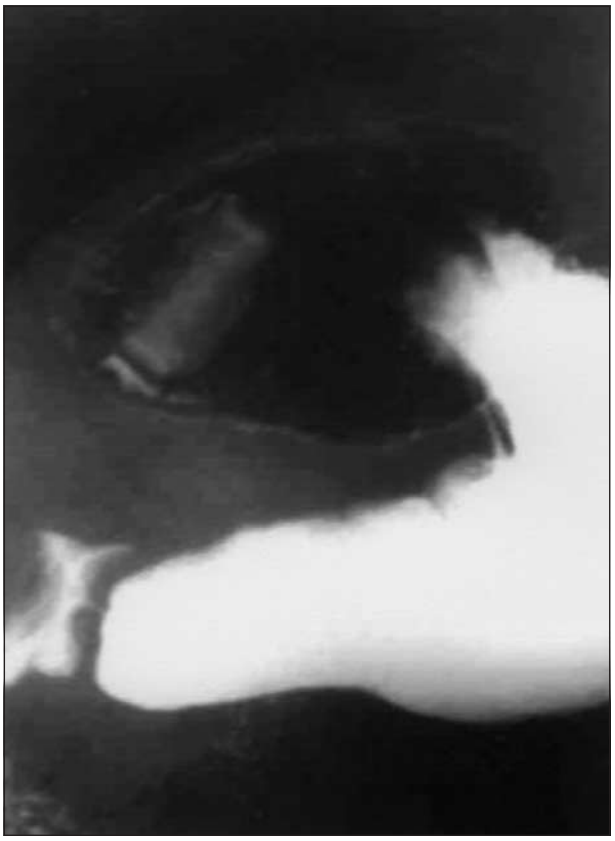

Figure 2. Intragastric migration (megulmine diatrizoate swallow radiograph).

(**Figure 2**). Ten patients were symptom free; 5 of them had a "spy" port infection, and only 1 had melena. The concomitant 5 "spontaneous" late port infections appeared 5 to 40 months after surgery.

Sixteen reoperations, after a mean interval of 11.4 months (range, 1-32) since diagnosis, were carried out. The mean BMI of these patients was 48.2 before surgery, 35.5 at the endoscopic diagnosis of erosion, and 35.1 when the prosthesis was removed. Body mass index evolution in these patients is shown in **Figure 3**.

The prosthesis removal was performed with 4 different modalities:

(1) Open surgery (1 case).

(2) Intragastric approach with flexible endoscope assistance (2 steps) (4 cases). To promote complete intragastric migration, the gastric wall covering the ring was cut during 2 endoscopic outpatient sessions, using monopolar electrocautery or an argon plasma scalpel. Then, the surgical procedure (after a mean observation interval of 6.5 months) was initiated with intraoperative upper gastrointestinal endoscopy to complete the cutting of the gastric wall covering the ring. Afterward, a minilaparotomy (5 cm) was performed at the level of the access port, and the reservoir was removed. A 1.5-cm anterior wall gastrotomy was performed to remove the band, using flexible endoscopy assistance. The gastrotomy was sutured and checked endoscopically. The mean operative time was 82 minutes; the postoperative course was complicated by 1 colonic fistula, successfully managed with drainage, antibiotics, and total parenteral nutrition in 4 weeks.

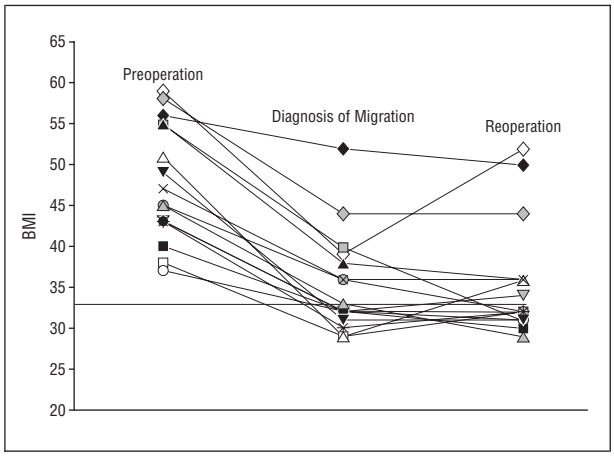

Figure 3. Body mass index (BMI) evolution in patients with intragastric migration, from gastric banding to reoperation. The symbols differentiate each BMI curve.

(3) Intragastric approach with flexible endoscopy assistance (1 step) (4 cases). The anterior abdominal wall was incised (5 cm) in the left subcostal area, and the reservoir was exposed and removed. Through the same incision, the anterior gastric wall was exposed. Two 5-mm trocars were introduced into the gastric lumen, using endoscopic assistance. The prosthesis was cut using an ultrasound scalpel or scissors and gently pulled into the gastric cavity and then out through a 1.5-cm gastrotomy. The gastrotomy was sutured and checked endoscopically. In 1 case, the "hand-assisted" technique was used. The patient was discharged from the hospital after 12 days.

There were 2 wound infections. The mean operative time in this group was 88 minutes, with a mean hospital stay of 5 days.

(4) Laparoscopic approach (7 cases). Using 3 trocars, a gastrotomy was created where the prosthesis eroded the gastric wall, followed by section and removal of the band. Mean operative time was 52 minutes, with a hospital stay of 2 days. After band removal, 6 patients received an intragastric balloon (BIB; BioEnterics) (mean BMI, 31.5). The other patients refused further surgical treatment.

MINOR COMPLICATIONS (GROUP B)

There were 5 port infections; 4 of them were successfully treated conservatively. In 1 case, the port was removed and substituted 6 months later.

In 6 cases, there were problems with the catheter-port system: 4 disconnections and 2 twists. In 4 cases, the port was substituted using local anesthesia (**Figure 4**); in 2 cases with intraperitoneal disconnection (**Figure 5**), the tube was reconnected laparoscopically.

PSYCHOLOGICAL PROBLEMS (GROUP C)

The psychiatric diagnosis of "psychological discomfort" related to the prosthesis led to laparoscopic band removal after a mean period of 27.8 months. All 6 patients had had a preoperative psychological evaluation, without any evidence of major psychiatric disorders. All patients were dis-

©2004 American Medical Association. All rights reserved.
Downloaded From: http://archsurg.jamanetwork.com/ on 04/26/2015

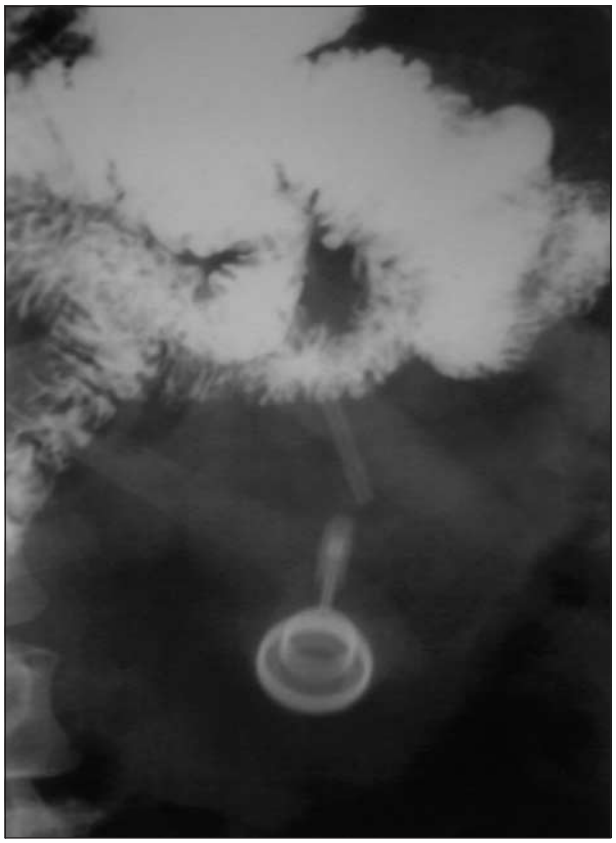

Figure 4. Subcutaneous tube disconnection (radiograph).

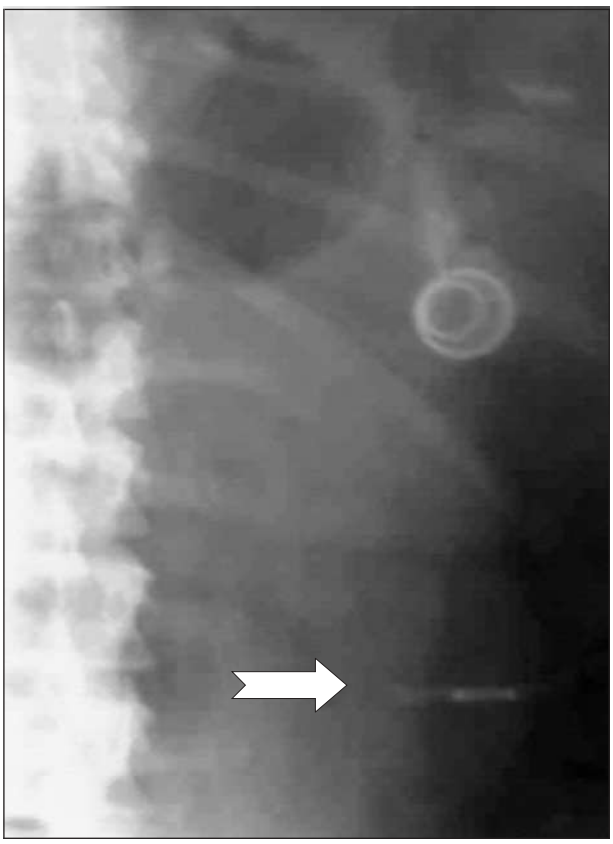

Figure 5. Intraperitoneal tube disconnection (arrow) (radiograph).

charged from the hospital after 2 days. None of them had any further treatment for their morbid obesity.

INSUFFICIENT WEIGHT LOSS (GROUP D)

Four patients, who had undergone previous LAGB, underwent surgical revision for insufficient weight loss and/or failure to maintain an initially satisfactory loss. All cases were revised laparoscopically, 3 of them with a subsequent laparoscopic Roux-en-Y gastric bypass. One patient, with a pre-LAGB BMI of 40, at routine follow-up had upper gastrointestinal endoscopy intragastric band migration. The band was removed, and after 1 year (BMI, 30.5), the patient was rebanded.

Our results are summarized in **Table 2** for each group of patients. The overall conversion rate was 5.2% (2/38). The perioperative mortality was 0%. The overall 30-day morbidity was 7.9%: 2 wound infections and 1 colonic fistula (3/38). The mean hospital stay of the patients treated by laparoscopy was 3.7 days.

COMMENT

The incidence of postoperative complications after LAGB ranges between 0% and 31%. These complications can lead to a mean reoperation rate of 2.0% to 40.0%.[12] Cottam et al[12] reported an overall band removal, due to different causes, of 11%.

The evolution of the laparoscopic techniques permitted a significant reduction of specific complications. The incidence of gastric dilatation has been significantly reduced by confectioning the retrogastric tunnel over the bursa omentalis, the prosthesis fixation, with 3 to 4 gastrogastric stitches and the reduction of the gastric pouch volume (15-20 cm^3).[19,22,29,31,35] The problems related to the subcutaneous reservoir were minimized by the new port system (low profile) and by following the technique suggested by Furbetta and coli.[36] Early postoperative band filling might be associated with an increase of postoperative complications (stoma stenosis, pouch and/or esophageal dilatation), according to a recent Italian study.[37] The intragastric band migration needs a more appropriate evaluation. The absence of specific clinical signs may explain the low incidence reported in the literature (0.5%[36] to 10.5%[35]). Routine upper gastrointestinal endoscopy in the follow-up permitted the diagnosis in the symptom-free cases and explains the higher incidence of this complication in the present series (5.1%).

From January 1996 to July 2003, we performed 313 LAGBs, always with the same surgical team. The incidence of major complications during the reoperations was 8.3% and minor complications, 2.2%.

The international literature does not suggest guidelines for the management of postoperative complications that require a reoperation, nor for the early diagnosis, timing, and/or safest and most effective approach. Furthermore, it has been reported that the rate of complications in reoperations is high.[26] The results of the present study show that laparoscopy is safe and effective in the management of specific LAGB complications, and some recommendations can be addressed.

©2004 American Medical Association. All rights reserved.
Downloaded From: http://archsurg.jamanetwork.com/ on 04/26/2015

Table 2. Management of Postoperative Complications

Causes of Reoperation	No. of Cases	Approach	Treatment	Postoperative Complications
Acute slippage	2	Laparoscopy	1 Band removal; 1 reposition	Irreversible pouch dilatation after reposition
Irreversible pouch dilatation	8	Laparoscopy (1 conversion)	Band removal	None
Intragastric band migration	16	1 Open; 8 intragastric approaches; 7 laparoscopies	Band removal	None after open approach or laparoscopy; 1 colonic fistula and 2 wound infections after intragastric approach
Intraperitoneal port-catheter disconnection	2	Laparoscopy	Reconnection	None
Insufficient weight loss	4	Laparoscopy	3 Laparoscopic Roux-en-Y gastric bypasses; 1 rebanding	None
Psychological	6	Laparoscopy	Band removal	None
Subcutaneous port infection	1	Local anesthesia	Substitution	None
Subcutaneous port-catheter disconnection	2	Local anesthesia	Reconnection	None
Port twist	2	Local anesthesia	Substitution	None

In the case of irreversible gastric pouch dilatation, the reintervention is mandatory. Furbetta and Coli[36] and Peterli et al[27] reported the conditions for a successful removal/repositioning of the band. Laparoscopy performed after 2 to 7 days is effective in 90% of the cases; repositioning or removing the band is related to the conditions of the gastric wall, the dimensions and type of dilatation (anterior or posterior), and the patient's request. Repositioning the band in a second intervention may be an alternative by creating a retrogastric tunnel through the pars flaccida. Delaying reoperation more than 7 days after onset of the pouch dilatation may cause gastric wall necrosis.

The interval between surgery and the diagnosis of intragastric prosthesis migration ranges between 12 and 36 months. Early diagnosis is established only by endoscopy; therefore, a regular follow-up schedule (routine endoscopy every 12 months) is extremely important. Prosthesis migration does not represent a surgical emergency, and it is therefore very important to plan the best strategy to achieve a minimally invasive treatment.[38-40] We suggest that the best time for removal is when 50% of the prosthesis has migrated intragastrically (including the closure system). Intraoperative cooperation with the endoscopist may be very useful. Following these guidelines, this minimally invasive approach was successful in 90% of the cases.

Minor complications were managed in the hospital's outpatient clinic or in the 1-day surgery setting; in the case of late port infection, upper gastrointestinal endoscopy is mandatory. Early diagnosis of subcutaneous connecting tube leakage may prevent dislocation in the peritoneal cavity, avoiding reoperation using general anesthesia.

When psychological problems are present, patients may ask for band removal, even in the absence of any surgical complication. A psychiatrist's evaluation and extensive discussion with the patient is mandatory. A more discriminatory preoperative selection of patients decreases the incidence of these problems. All of our cases occurred during the learning-curve period (first 50 cases).

Gagner et al[41] and Weiner et al[42] reported favorable results of the laparoscopic "redo" surgery. All our reoperations for insufficient weight loss were successfully performed laparoscopically.

CONCLUSIONS

The results of this study demonstrate that the multidisciplinary team's experience in patient selection and follow-up, combined with the standardization of the laparoscopic procedure, play a major role in prevention, early diagnosis, and treatment of the specific postoperative complications after LAGB. A minimally invasive approach (laparoscopy and/or endoscopy) seemed to be safe and effective in the treatment of more than 90% of the postoperative complications requiring a reintervention.

Accepted for Publication: June 1, 2004.
Correspondence: Gianfranco Silecchia, MD, PhD, Department of Surgery "Paride Stefanini," Seventh Surgical Clinic, Policlinico Umberto I, Università "La Sapienza" Roma, Viale Policlinico 155, 00161 Rome, Italy (gianfranco.silecchia@uniroma1.it).
Previous Presentation: This study was presented at the Ninth National and First International Congress of SICE (Italian Society of Endoscopic Surgery and New Technologies); September 22, 2003; Sorrento, Italy.

REFERENCES

1. World Health Organization. *World Health Report. Life in the 21st Century: A Vision for All.* Geneva, Switzerland: World Health Organization; 1998.
2. World Health Organization. *World Health Report. Health System: Improving Performance.* Geneva, Switzerland: World Health Organization; 2000.
3. World Health Organization. *Obesity: Preventing and Managing the Global Epidemic. Report of a WHO Consultation on Obesity, Geneva 3-5 June 1997.* Geneva, Switzerland: World Health Organization; 1998.
4. Bjorntorp P. Obesity. *Lancet.* 1997;350:423-426.
5. National Heart Lung and Blood Institute, NHLBI Obesity Education Initiative Expert Panel. *Clinical Guidelines on Identification, Evaluation and Treatment of Over-*

©2004 American Medical Association. All rights reserved.
Downloaded From: http://archsurg.jamanetwork.com/ on 04/26/2015

weight and Obesity in Adults: The Evidence Report. Bethesda, Md: National Heart, Lung and Blood Institute, NHLBI Obesity Education Initiative Expert Panel; 1998: 228.
6. Hell E, Miller KA. Comparison of vertical banded gastroplasty and adjustable silicone gastric banding. In: Deitel M, Cowan GSM, eds. *Update: Surgery for the Morbid Obese Patient.* Toronto, Ontario: FD-Communication Inc; 2000:379-386.
7. Grundy SM. Multifactor causation of obesity: implication for prevention. *Am J Clin Nutr*. 1998;67(suppl 3):563S-572S.
8. Ceelen W, Walzer J, Cardon A, et al. Surgical treatment of severe obesity with a low-pressure adjustable gastric band: experimental data and clinical results in 625 patients. *Ann Surg*. 2003;237:10-16.
9. Forsell P, Hallberg D, Hellers G. Gastric banding for morbid obesity: initial experience with a new adjustable band. *Obes Surg*. 1993;3:369-374.
10. Cadiere GB, Bruyns J, Himpens J, Favretti F. Laparoscopic gastroplasty for morbid obesity. *Br J Surg*. 1994;81:1524.
11. Belachew M, Legrand MJ, Defeschereux TH, et al. Laparoscopic adjustable silicone gastric banding in the treatment of morbid obesity. *Surg Endosc*. 1994; 8:1354-1356.
12. Cottam DR, Mattar SG, Schauer PR. Laparoscopic era of operations for morbid obesity. *Arch Surg*. 2003;138:367-375.
13. American Society for Bariatric Surgery. Guidelines for laparoscopic and open surgical treatment of morbid obesity. *Obes Surg*. 2000;10:378-379.
14. Oelschlager B, Pellegrini C. Advances in the surgical treatment of obesity: Society of American Gastrointestinal Endoscopical Surgeons (SAGES) Annual Scientific Session and Postgraduate Course, March 2003, Los Angeles, USA. [Medscape Gastroenterology Web site] Available at: http://www.medscape.com/viewarticle/451082?src=search.
15. Vertruyen M. Repositioning the lap band for proximal pouch dilatation. *Obes Surg*. 2003;13:285-288.
16. Miller K, Hell E. Laparoscopic adjustable gastric banding: a prospective 4-year follow-up study. *Obes Surg*. 1999;9:183-187.
17. Abu-Abeid S, Szold A. Results and complications of laparoscopic adjustable gastric banding: an early and intermediate experience. *Obes Surg*. 1999;9:188-190.
18. Westling A, Bjurling K, Ohrvall M, et al. Silicone adjustable gastric banding: disappointing results. *Obes Surg*. 1998;8:467-474.
19. Dargent J. Laparoscopic adjustable gastric banding: lessons from the first 500 patients in a single institution. *Obes Surg*. 1999;9:446-452.
20. Doldi SB, Micheletto G, Lattuada E, et al. Adjustable gastric banding: 5-year experience. *Obes Surg*. 2000;10:171-173.
21. Oria HE. Silicone gastric banding for morbid obesity: a systematic review [abstract]. *Eur J Gastroenterol Hepatol*. 1999;11:105-114.
22. Favretti F, Cadiere GB, Segato G, et al. Laparoscopic adjustable silicone gastric banding (LAP-BAND): how to avoid complications. *Obes Surg*. 1997;7:352-358.
23. Silecchia G, Restuccia A, Elmore U, et al. Laparoscopic adjustable silicone gastric banding: prospective evaluation of intragastric migration of the LAP-BAND. *Surg Laparosc Endosc Percutan Tech*. 2001;11:229-234.
24. Morino M, Toppino M, Garrone G. Disappointing long-term results of laparoscopic adjustable silicone gastric banding. *Br J Surg*. 1997;84:868-869.
25. Chelala E, Cadiere GB, Favretti F, et al. Conversion and complications in 185 laparoscopic adjustable silicone gastric banding. *Surg Endosc*. 1997;11:268-271.
26. Gustavsson S, Westling A. Laparoscopic adjustable gastric banding: complications and side effects for the poor long-term outcome. *Semin Laparosc Surg*. 2002;9:115-124.
27. Peterli R, Donadini A, Peters T, et al. Reoperations following laparoscopical adjustable gastric banding. *Obes Surg*. 2002;12:851-856.
28. Zinzindohoue F, Chevalier JM, Douard R, et al. Laparoscopic gastric banding: a minimal invasive surgical treatment of morbid obesity. *Ann Surg*. 2003;237: 1-9.
29. O'Brien PE, Dixon JB. Laparoscopic adjustable gastric banding in the treatment of morbid obesity. *Arch Surg*. 2003;138:376-382.
30. Doherty C, Maher JW, Heitshusen DS. Long-term data indicate a progressive loss in efficacy of adjustable silicone gastric banding for the surgical treatment of morbid obesity. *Surgery*. 2002;132:724-727.
31. Steffen R, Biertho L, Ricklin T, et al. Laparoscopic Swedish adjustable gastric banding: a five-year prospective study. *Obes Surg*. 2003;13:404-411.
32. Nehoda H, Weiss H, Labeck B, et al. Results and complications after adjustable gastric banding in a series of 250 patients. *Am J Surg*. 2001;181:12-15.
33. Ponson AE, Janssen IM, Klinkenbijl JH. Laparoscopic adjustable gastric banding: a prospective comparison of two commonly used bands. *Obes Surg*. 2002; 12:579-582.
34. Mittermair RP, Weiss H, Nehoda H, et al. Laparoscopic Swedish adjustable gastric banding: 6-year follow-up and comparison to other laparoscopic bariatric procedures. *Obes Surg*. 2003;13:412-417.
35. Suter M, Giusti V, Héraief E, et al. Laparoscopic gastric banding: beyond the learning curve. *Surg Endosc*. 2003;17:1418-1425.
36. Furbetta F, Coli E. Codification of techniques for reoperation after LAP-BAND. *Obes Surg*. 2003;13:289-293.
37. Busetto L, Segato G, DeMarchi F, et al. Postoperative management of laparoscopical gastric banding. *Obes Surg*. 2003;13:121-127.
38. Biagini J. Intragastric band erosion. *Obes Surg*. 2001;11:100.
39. Mittermair RP, Weiss H, Nehoda H, Aigner F. Uncommon intragastric migration of the Swedish adjustable gastric band. *Obes Surg*. 2002;12:372-375.
40. Niville E, Dams A, Vlasselaers J. LAP-BAND erosion: incidence and treatment. *Obes Surg*. 2001;11:744-747.
41. Gagner M, Gentileschi P, de Csepel J, et al. Laparoscopic reoperative bariatric surgery: experience from 27 consecutive patients. *Obes Surg*. 2002;12:254-260.
42. Weiner R, Blanco-Engert R, Weiner S, Matkowitz R, Schaefer L, Pomhoff L. Outcome after laparoscopic adjustable gastric banding: 8 years experience. *Obes Surg*. 2003;13:427-434.

©2004 American Medical Association. All rights reserved.
Downloaded From: http://archsurg.jamanetwork.com/ on 04/26/2015