

Diagnosis and Therapeutic Strategy for Papillary Thyroid Microcarcinoma

Jen-Der Lin, MD; Szu-Tah Chen, MD; Tzu-Chieh Chao, MD, PhD;
Chuen Hsueh, MD; Hsiao-Fen Weng, MS

Hypothesis: Total thyroidectomy followed by radioactive iodine I 131 treatment is effective in papillary thyroid microcarcinoma (PTM) with lymph node or extrathyroid invasion.

Design: Retrospective study.

Setting: Chang Gung Medical Center, Linkou, Taiwan.

Patients: A total of 227 patients with PTM, categorized into high-risk (n=12) and low-risk (n=215) groups according to age, metastases, extent, and size criteria.

Interventions: Diagnosis and treatment of PTM.

Main Outcome Measures: Time and method of diagnosis, operative method, metastases, and survival.

Results: In 51 patients, PTM was identified on preoperative fine-needle aspiration cytology; in 75 patients, diagnosed in frozen sections during operation; and in 101 patients, diagnosed incidentally in the final histopatho-

logical examination. Among these 3 groups, 18% (9/51), 17% (13/75), and 78% (79/101), respectively, underwent subtotal thyroidectomy or lobectomy for tumors. Four cases (1.8%) displayed distant metastases at diagnosis. Only 0.9% of patients with PTM (2 of 227) died of thyroid cancer. One hundred eighty-nine cases of PTM were confined to the thyroid, 22 had lymph node metastases, and 16 showed extrathyroid extension, including soft-tissue invasion and distant metastases. Sex, operative methods, follow-up status, and mortality showed differences in these groups. Five of 227 patients remained in non-disease-free status at follow-up.

Conclusions: Approximately 10% of PTMs exhibited progressive clinical courses, while less than 1% resulted in mortality. Age, sex, and postoperative thyroglobulin level were the main prognostic factors in the high-risk group of patients with PTM. Conservative treatment of the incidental finding of PTM after suitable postoperative assessment is justified.

Arch Surg. 2005;140:940-945

WIDE VARIATIONS exist in surgical methods as well as use of postoperative radioactive iodine I 131 (¹³¹I) treatment and follow-up in papillary thyroid microcarcinoma (PTM). Before consensus is attained in treating this indolent disease, specific facts concerning clinical presentation, diagnosis, long-term follow-up, and PTM treatment results in different populations are needed.¹ Autopsy findings have shown prevalence rates of thyroid microcarcinoma ranging from 5.6% to 35.6%.²⁻⁴ Although most patients with thyroid microcarcinoma were reported to have displayed a benign clinical course, PTM with an invasive course was also demonstrated.^{5,6} The clinical behaviors of papillary and follicular thyroid carcinoma are different. The present study retrospectively evaluated 1516 cases of

papillary thyroid carcinomas, including 227 patients with PTM who were treated at Chang Gung Memorial Hospital in Linkou, Taiwan. The goals of this retrospective investigation included assessing therapeutic strategies for PTM, including operation and use of ¹³¹I treatment in the high-risk group. The study was also aimed at elucidating clinical manifestations of PTM along with the prognostic factors linked to PTM by comparison with larger thyroid carcinomas.

METHODS

During 25 years, from January 1, 1977, to December 31, 2002, a total of 2003 patients with thyroid carcinoma, including 1516 with papillary thyroid carcinoma, underwent treatment and were followed up at Chang Gung Medical Center. Among them, 1370 had recorded tumor measurements. This study ex-

Author Affiliations: Division of Endocrinology and Metabolism, Department of Internal Medicine (Drs Lin, Chen, and Ms Weng), Department of General Surgery (Dr Chao), and Department of Pathology (Dr Hsueh), Chang Gung Memorial Hospital, Chang Gung University, Linkou, Taiwan.

cluded the other 146 cases with unknown tumor size. Of the recorded tumors, 227 (16.6%) were PTM, defined as papillary thyroid cancer not larger than 1.0 cm (**Figure 1**).

Of the 227 patients with PTM, 168 underwent preoperative thyroid ultrasonography with fine-needle aspiration cytology (FNAC) examinations (**Figure 2**). In Chang Gung Medical Center, most patients diagnosed as having well-differentiated thyroid cancer before or during operation received nearly total thyroidectomy. Otherwise, subtotal thyroidectomy or lobectomy was performed for benign thyroid disorders. During the operation, frozen sections were taken in 159 patients with PTM. Figure 2 illustrates distribution of the 227 patients with PTM diagnosed through FNAC, frozen section during the surgery, or final histopathological examination.

The 227 cases were categorized into 3 patient groups. Group 1 (51 cases) comprised cases of PTM diagnosed on preoperative FNAC as papillary carcinoma or follicular neoplasm. Group 2 (75 cases) represented PTM diagnosed in frozen sections during operation. Group 3 (101 cases) included incidental findings diagnosed on final histopathological examination. An incidental finding of PTM was defined as the finding of PTM during surgery for benign thyroid disorders and preoperative FNAC or frozen section during operation for benign lesions. Group 3 contained 37 patients not undergoing FNAC or frozen section. Most of these patients received consistent follow-up in the Division of Endocrinology and Metabolism.

All patients were also categorized into high- and low-risk groups according to age, metastases, extent, and size criteria.⁷ After the operation, most patients underwent long-term thyroid hormone replacement or suppressive treatment. Cancer assessments involved a 2- to 5-mCi (74- to 185-MBq) ¹³¹I whole-body scan and chest radiography. Serum thyroglobulin (Tg) levels were assessed every 6 to 12 months. Postoperative serum Tg levels were detected by an immunoradiometric assay kit (CIS Bio International, Bagnols-sur-Ceze, France). Once the metastatic or recurrent lesions were detected, surgery, external radiotherapy, or ¹³¹I therapy was recommended.

Admission records were surveyed and the following data were stored in the computer: age, sex, primary tumor size, ultrasonographic findings, FNAC results, thyroid function before operation, operative methods, histopathological findings, TNM staging, 1-month postoperative serum Tg levels, results of diagnostic and therapeutic ¹³¹I scans, postoperative chest radiography findings, clinical status for analysis of distant metastases by noninvasive examinations, treatment results, causes of death, and survival status. Statistical significance corresponded to $P \leq .05$. Actuarial survival rates were calculated by the Kaplan-Meier method, and differences in survival rates were examined with the Breslow and Mantel-Cox tests.

RESULTS

Most patients in the 3 groups received nearly total thyroidectomy after diagnosis of PTM before or during the operation (**Figure 3**). In contrast to groups 1 and 2, most group 3 cases received subtotal thyroidectomy because PTM was identified incidentally on final histopathological examination. Twenty-two of the 101 patients in group 3 underwent nearly total thyroidectomy, including those who underwent secondary operation for total thyroidectomy. In this study, the mean \pm SD age of the 227 patients with PTM (40.6 ± 12.4 years) paralleled that of patients with larger tumors (40.4 ± 14.7 years) ($P = .99$). No difference in age and sex distribution of patients with PTM was apparent when compared with 1143 patients with

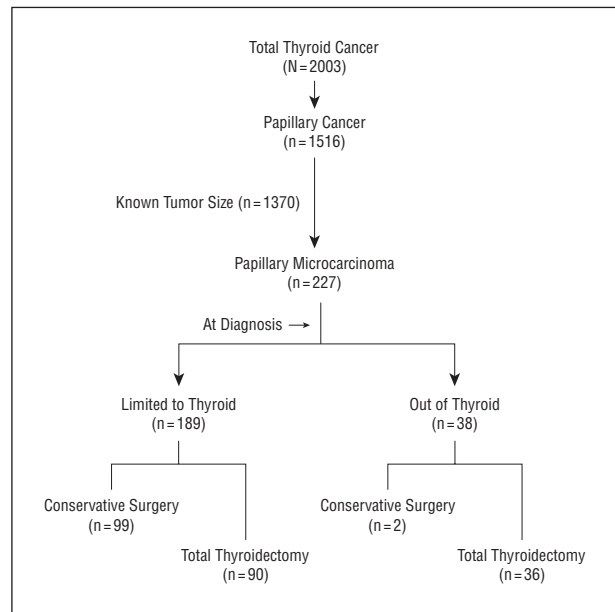


Figure 1. Treatment and histologic findings in 227 patients with papillary thyroid microcarcinoma.

larger tumors. Pathological review showed 20 patients with multicentric PTM, 3 with lymphocytic thyroiditis, 2 with a follicular variant of papillary thyroid carcinoma, and 1 with an insular pattern. Among these patients, 1 displayed a multicentric, follicular variant and poorly differentiated patterns simultaneously. Clinical variables were compared between the 207 nonmulticentric and 20 multicentric cases of PTM. The results indicated higher ratios of multicentric PTM in male patients (6 of 31 men vs 14 of 196 women; $P = .03$). Otherwise, age, tumor size, follow-up status, and TNM staging showed no statistical difference between the 2 groups.

In the present study, after 9.6 years of follow-up, 6 patients had died. Only 0.9% of the patients with PTM (2 of 227) died of thyroid cancer. One patient who died of thyroid cancer was a 74-year-old woman who appeared with skull metastases and microcarcinoma measuring 1 cm in her thyroid. The patient underwent nearly total thyroidectomy, removal of the skull tumor, and external radiation to the skull and brain. She died 1 year 10 months after the thyroidectomy. The other case was a 43-year-old man diagnosed as having a follicular variant of PTM with vertebral metastases. Multicentric and poorly differentiated patterns were found in the histopathologic findings. After surgical treatment with a total of 500 mCi (18 500 MBq) of ¹³¹I treatments, the patient died 5 years later. Of 227 patients with PTM, 4 (1.8%) displayed distant metastases at surgery. Among these patients, 3 had bone metastases. Lung metastases were indicated by ¹³¹I scanning and elevated Tg levels in 1 of the patients with PTM.

Table 1 gives the characteristics of the 227 patients with PTM, categorized according to histopathological findings. There were 189 cases of microcarcinoma restricted to the thyroid, 22 of lymph node metastases, and 16 of extrathyroid extension, including soft-tissue invasion and distant metastases. Patients with extrathyroid involvement were demonstrably older. Sex, surgical meth-

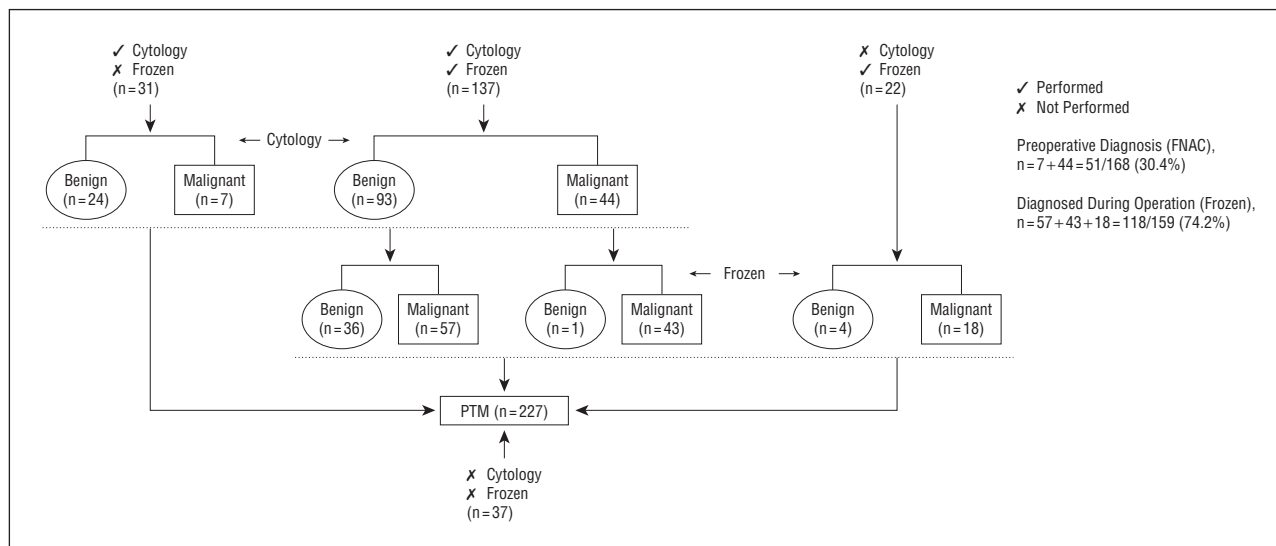


Figure 2. Distribution of 227 patients with papillary thyroid microcarcinoma (PTM) at the time of diagnosis across 3 groups. FNAC indicates fine-needle aspiration cytology.

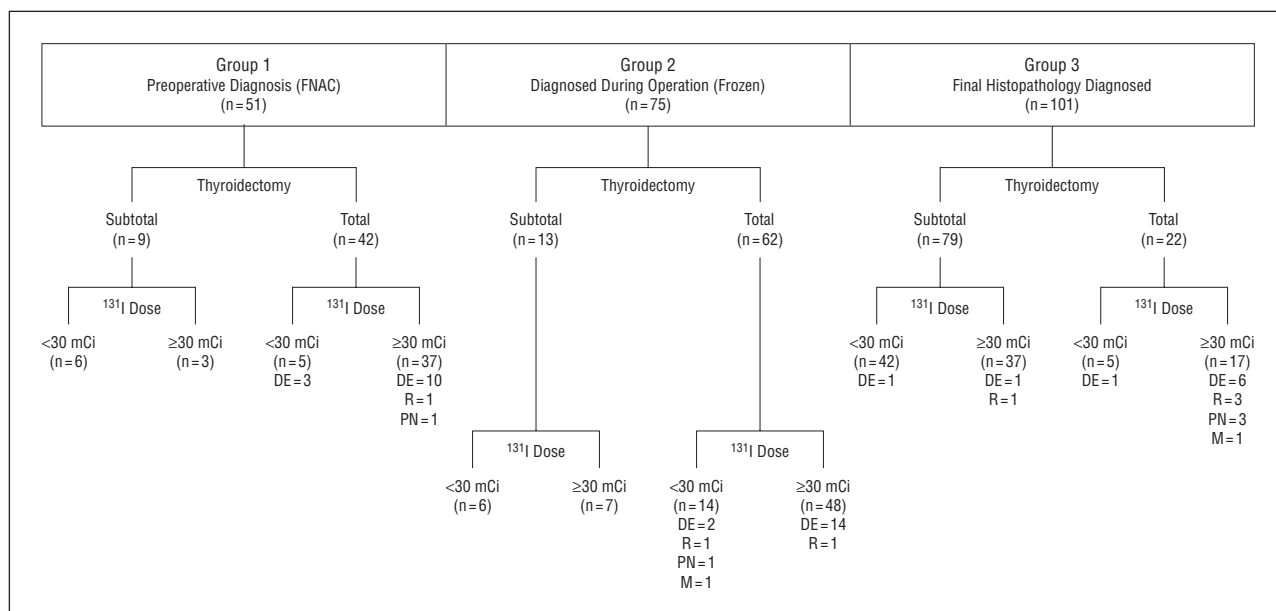


Figure 3. Treatment results for 227 patients with papillary thyroid microcarcinoma in 3 groups. FNAC indicates fine-needle aspiration cytology; ¹³¹I, iodine I 131; DE, number of patients with extrathyroid findings at diagnosis; R, number of patients with clinical relapse; PN, number of patients whose present status was non-disease free; and M, number of patients who died. To convert ¹³¹I doses to megabecquerels, multiply by 37.

ods, follow-up status, and mortality due to thyroid cancer did show differences between these groups.

Clinical assessment was compared among the 3 groups diagnosed at different periods (**Table 2**). Of the 227 patients, 193 received serum Tg examinations, with a mean \pm SD Tg level of 21.0 \pm 4.8 ng/mL. Although postoperative ¹³¹I uptake was higher in group 3 because of less aggressive surgical procedures, Tg levels otherwise lacked statistically significant differences among the 3 groups. Comparison of mean postoperative Tg levels of patients with tumors restricted to the thyroid and the group with lymph node metastases illustrated a statistically significant difference (Table 1).

Among groups 1, 2, and 3, 18% (9/51), 17% (13/75), and 78% (79/101) of patients, respectively, underwent

subtotal thyroidectomy or lobectomy for tumors. The accuracy of preoperative aspiration cytology was only 30.4% (51/168 cases). One hundred seventeen cases were unable to be diagnosed by preoperative ultrasonography and FNAC. Patients who had frozen sections taken during surgery received the correct diagnosis in 74.2% (118/159) of cases (Figure 2). Of the 227 patients, 37 received neither FNAC nor frozen section during surgery.

Table 3 illustrates clinical characteristics of PTM categorized into high-risk (12 patients) and low-risk (215 patients) groups. Age, sex, operative methods, Tg level, follow-up status, and survival differed significantly between the 2 groups. Mean \pm SD tumor sizes of the low- and high-risk groups were 0.64 \pm 0.02 cm and 0.77 \pm 0.06 cm, respectively ($P = .12$). After treatment, no patients in the low-

Table 1. Clinical Characteristics of PTM Not Confined to Thyroid

	Intrathyroid Microcarcinoma at Diagnosis (n = 189)	Lymph Node Metastases at Diagnosis (n = 22)	Extrathyroid Invasion at Diagnosis (n = 16)	P Value*
Age at diagnosis, mean ± SD, y	40.3 ± 12.2	35.6 ± 10.8	49.3 ± 13.4	B, C
Sex, No. F/M (ratio)	168/21 (8.0:1)	16/6 (2.7:1)	12/4 (3.0:1)	.04
Operative method, No. subtotal/nearly total thyroidectomy (ratio)	99/90 (1.1:1)	0/22 (0)	2/14 (0.1:1)	<.001
Tumor size, mean ± SD, cm	0.61 ± 0.02	0.79 ± 0.05	0.84 ± 0.05	A, B
¹³¹ I uptake 1 mo after operation, mean ± SD, %	14.5 ± 1.6	5.7 ± 2.5	5.2 ± 1.4	.049
Tg 1 mo after operation, mean ± SD, ng/mL	16.9 ± 3.9	56.0 ± 145.2	18.8 ± 9.3	A
Present status, No. disease free/non-disease free (ratio)	189/0 (NA)	21/1 (21:1)	12/4 (3.0:1)	<.001
Survival, No. yes/no (ratio)	185/4 (46.3:1)†	22/0 (NA)	14/2 (7.0:1)	<.001

Abbreviations: ¹³¹I, iodine I 131; NA, not applicable; PTM, papillary thyroid microcarcinoma; Tg, thyroglobulin.

*A indicates *P*<.001 for intrathyroid vs lymph node groups; B, *P*<.001 for intrathyroid vs extrathyroid groups; and C, *P*<.001 for lymph node vs extrathyroid groups.

†All patients died of causes other than thyroid cancer.

Table 2. Classification of PTM Before, During, and After Operation

	Time of PTM Finding (n = 227)			P Value*
	Preoperative Diagnosis (FNAC) (n = 51)	Diagnosed During Operation (Frozen) (n = 75)	Final Histopathological Diagnosis (n = 101)	
Age, mean ± SD, y	40.5 ± 10.7	42.0 ± 14.1	39.3 ± 12	.34
Operative method, No. subtotal/nearly total thyroidectomy (ratio)	9/42 (0.2:1)	13/62 (0.2:1)	79/22 (3.6:1)	<.001
Tumor size, mean ± SD, cm	0.82 ± 0.03	0.69 ± 0.03	0.53 ± 0.03	A, B, C
¹³¹ I uptake 1 mo after operation, mean ± SD, %	8.7 ± 2.6	8.3 ± 1.5	20.1 ± 2.5	B, C
Tg 1 mo after operation, mean ± SD, ng/mL	10.9 ± 3.9	22.0 ± 10.4	25.7 ± 7.2	.50
TNM stage, No. stage 1/stages 2-4 (ratio)	45/6 (7.5:1)	71/4 (17.8:1)	97/4 (24.3:1)	.16
Present status, No. disease free/non-disease free (ratio)	50/1 (50:1)	74/1 (74:1)	98/3 (32.7:1)	.76

Abbreviations: FNAC, fine-needle aspiration cytology; ¹³¹I, iodine I 131; PTM, papillary thyroid microcarcinoma; Tg, thyroglobulin.

*A indicates *P*<.001 for FNAC vs diagnosis during operation; B, *P*<.001 for FNAC vs final histopathological diagnosis; and C, *P*<.001 for diagnosis during operation vs final histopathological diagnosis.

risk group died of thyroid cancer. **Figure 4** demonstrates the Kaplan-Meier survival curves of these 2 groups. Two patients in the high-risk group died of thyroid cancer. Eight of the 12 patients in the high-risk group were in disease-free survival during the follow-up period.

Among the 227 cases, 149 received a higher dose of ¹³¹I therapy for ablation of the remnant or treatment for distant metastases (¹³¹I dose ≥30 mCi [≥1110 MBq] in Figure 3). One hundred twenty-six patients received nearly total thyroidectomy followed by thyroid remnant ablation with ¹³¹I treatment. Thirty of the 102 patients showed lymph node or extrathyroid involvement in the histologic finding. Five of the 102 patients showed evidence of not being disease free during the follow-up period, and 2 cases resulted in mortality from thyroid cancer. Fifty-four patients received subtotal thyroidectomy without ¹³¹I ablation treatment. No recurrence or mortality due to thyroid cancer occurred.

COMMENT

Without any prospective study of treatment of PTM, achieving consensus on standard operating methods for

surgeons has proved difficult. Although aggressive surgical procedures were conducted in cases diagnosed preoperatively or during surgery, 22 (17.5%) of the 126 patients in groups 1 and 2 received subtotal thyroidectomy in this study. Among the 22 patients, 3 showed tumor recurrence in the neck lymph nodes. After surgical and ¹³¹I treatments, these 22 cases were in disease-free status. In contrast to groups 1 and 2, of 79 patients in group 3 who received subtotal thyroidectomy, 3 had recurrences and 1 patient was not disease free. However, a high PTM ratio was recorded in the autopsy cases.²⁻⁴ It would have been inappropriate to observe cases without surgical intervention for PTM diagnosed on ultrasonography with FNAC. Of 101 cases with an incidental finding of PTM (group 3), 4 had recurrences, 4 were not disease free, and 1 resulted in mortality after surgical treatment during the follow-up period. Most incidental PTMs are indolent, but approximately 9% (9/101 cases) were progressive. Thyroid ultrasonography with FNAC cannot at present detect microscopic metastases of cancer cells.

Of the PTM cases, 16.7% (38/227) experienced a more aggressive pattern with extrathyroid involvement. A recent study speculated that, while iodine intake plays a

Table 3. Clinical Characteristics of PTM Categorized Into High- or Low-Risk Group

	Low Risk (n = 215)	High Risk (n = 12)	P Value
Age at diagnosis, mean ± SD, y	39.6 ± 11.9	56.5 ± 10.5	<.001
Sex, No. F/M (ratio)	189/26 (7.3:1)	7/5 (1.4:1)	.004
Operative method, No. subtotal/nearly total thyroidectomy (ratio)	100/115 (0.9:1)	1/11 (0.1:1)	.01
¹³¹ I uptake 1 mo after operation, mean ± SD, %	13.4 ± 1.4	4.8 ± 1.7	.16
Tg 1 mo after operation, mean ± SD, ng/mL	17.4 ± 3.6	87.5 ± 63.7	.04
Present status, No. disease free/non-disease free (ratio)	214/1 (214.0:1)	8/4 (2.0:1)	<.001
Survival, No. yes/no (ratio)	211/4 (52.8:1)*	10/2 (5.0:1)	.003†

Abbreviations: ¹³¹I, iodine I 131; PTM, papillary thyroid microcarcinoma; Tg, thyroglobulin.

*All patients died of causes other than thyroid cancer.

†Only compared patients who died of thyroid cancer and patients who survived (215/0 vs 10/2).

minor role in early-phase carcinogenesis of papillary thyroid carcinoma, it may be important in progression of latent papillary carcinoma to clinically evident papillary thyroid carcinoma.² No evidence occurred in the study of iodine uptake influencing the progression of PTM. There is controversy about postoperative PTM treatment with ¹³¹I, particularly after reviewing the data of autopsy studies.⁸⁻¹⁰ After aggressive treatment consisting of nearly total thyroidectomy with ¹³¹I, 5 cases still remained in non-disease-free status. We believe that ¹³¹I treatment is indicated for high-risk patients with PTM.

Size of the thyroid tumor is important in different prognostic scoring systems, including the European Organization for Research and Treatment of Cancer¹¹; the Age, Grade, Extent, and Size system¹²; the Age, Metastases, Extent, and Size system⁷; and the Metastases, Age, Completeness of Resection, Invasion, and Size system.¹³ In this study, age, sex, and postoperative Tg level were demonstrated to be prognostic factors in the Age, Metastases, Extent, and Size system. Aggressive surgical treatment with postoperative ¹³¹I ablation and treatment for older male patients with PTM seems indicated. About 8.8% (20 of 227 cases) were histologically proved with multifocal PTM. Familial PTM has been mentioned as a new clinical entity,^{14,15} but in the present study, only 1 case entailed family history of thyroid cancer. As in earlier studies, patients with PTM had a rather benign clinical course.^{16,17} Less than 1% died of PTM, and 5 of 227 were non-disease free.

The male-female distribution of thyroid cancer was 1:6.3, a ratio higher than in previous studies.^{14,18,19} It has been reported that females have a superior survival rate.^{20,21} In a study by Schindler et al,²² univariate analysis showed that, although men had a higher recurrence rate of papillary thyroid carcinoma, sex was not significant in multivariate analysis. In the current study, of male subjects with more aggressive PTM patterns, one third showed

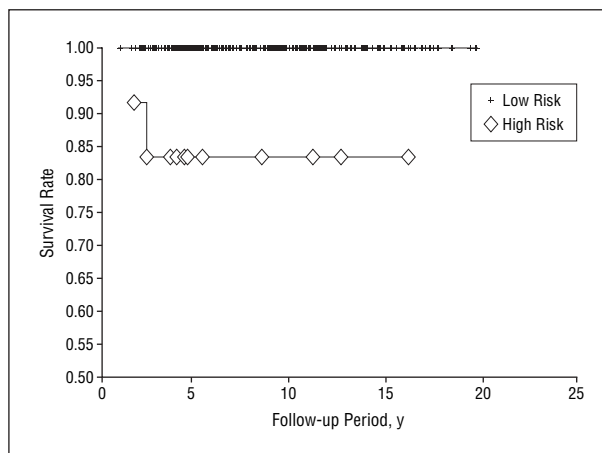


Figure 4. Disease-specific survival curves of the low- and high-risk patients with papillary thyroid microcarcinoma.

extrathyroid involvement at presentation and there was a greater percentage of male patients in the high-risk group. Only 2 cases resulted in mortality. More cases and long-term follow-up are required to realize the influence of sex on the prognosis of papillary thyroid carcinoma. Most reports in the literature have shown that older patients with well-differentiated thyroid carcinomas had a worse prognosis.^{8,14,20} As in this study, mean age was greater in the high-risk group; otherwise, age did not significantly affect aggressiveness or metastases of PTM.²³

An earlier work reported that Tg level could be used as a tumor marker for follow-up of patients with well-differentiated thyroid cancer.²⁴ Although tumor recurrence has been detected by elevation of serum Tg level after surgery,^{25,26} there was limited information about serum Tg level as a prognostic factor in patients with PTM. Although 1-month postoperative serum Tg levels showed no difference between patients with papillary microcarcinoma and those with larger tumors, there was a significant difference between groups with tumor localized in the thyroid and extrathyroid invasion. Earlier investigation confirmed that serum Tg levels below 2 ng/mL in patients receiving thyroid hormone replacement, or 3 ng/mL in those without replacement therapy, were infrequently associated with tumor recurrence.²⁶ Thyroglobulin remains an important postoperative tumor marker in patients with PTM.

Among the 227 patients with PTM, 117 (51.5%) were inaccurately diagnosed on the basis of clinical features. The preoperative diagnostic rate of PTM by FNAC was lower than that for larger tumors because microcarcinoma tumors are much smaller. However, there remained 51 patients with PTM who were accurately diagnosed by ultrasonography and FNAC. In this study, 41 of 159 cases were diagnosed as benign lesions on frozen sections. This result is better than that for FNAC. Otherwise, in most investigations, as in our study, there were no significant differences between the sensitivity, specificity, and diagnostic accuracy of frozen section and FNAC.²⁷

Use of radioactive iodine treatment in PTM has not been reported previously, to our knowledge. In this study, 5 of 227 patients were still not disease free even after ¹³¹I

treatment. Until now, no consensus existed for aggressive treatment including ^{131}I , reoperation, or external radiotherapy if extrathyroid invasion of PTM was found in the first operation. From a clinical practice viewpoint, after appropriate preoperative evaluation, subtotal thyroidectomy may be performed in PTM localized in the thyroid and total thyroidectomy performed in cases with extrathyroid invasion. In this study, about 45% (101/227) of cases of PTM were diagnosed after operation. Around 9% (9 of the 101 cases) were proved to have extrathyroid involvement on final histopathologic examination. In a recent study by Ito et al,²⁸ an observation trial of 162 cases of PTM showed that 70% of them were unaltered in tumor size. It is difficult to find a midpoint between too aggressive and too conservative a treatment of this disorder. In a detailed analysis of 7 clinically relapsed cases, none met the criteria of being disease free with Tg level less than 1.5 ng/mL and negative ^{131}I scans.¹⁸ Of these cases, residual cancer cells after operation or recurrence were difficult to define. It is inappropriate to include all patients with PTM who received total thyroidectomy followed by ^{131}I for remnant ablation.

CONCLUSIONS

In this study, 16.6% of cases of papillary thyroid cancer were PTM. Although most patients with PTM had a benign clinical course, distant metastases causing mortality were occasionally observed. Age, sex, and postoperative Tg level were the main prognostic factors in the high-risk group of patients with PTM. Earlier diagnosis with timely surgical removal of high-risk tumors before distant metastasis develops may help improve the prognosis in these patients.

Accepted for Publication: November 2, 2004.

Correspondence: Jen-Der Lin, MD, Division of Endocrinology and Metabolism, Chang Gung Memorial Hospital, 5, Fu-Shin St Kweishan County, Taoyuan Hsien, Taiwan (einjd@adm.cgmh.org.tw).

REFERENCES

- Piersanti M, Ezzat S, Asa SL. Controversies in papillary microcarcinoma of the thyroid. *Endocr Pathol*. 2003;14:183-191.
- Neuhold N, Kaiser H, Kaserer K. Latent carcinoma of the thyroid in Austria: a systemic autopsy study. *Endocr Pathol*. 2001;12:23-31.
- Ottino A, Pianzola HM, Castelletto RH. Occult papillary thyroid carcinoma at autopsy in La Plata, Argentina. *Cancer*. 1989;64:547-551.
- Yamamoto Y, Maeda T, Izumi K, Otsuka H. Occult papillary carcinoma of the thyroid: a study of 408 autopsy cases. *Cancer*. 1990;65:1173-1179.
- Lin KD, Lin JD, Huang HS, Jeng LB, Ho YS. Skull metastasis with brain invasion from thyroid papillary microcarcinoma: report of a case. *J Formos Med Assoc*. 1997;96:280-282.
- Strate SM, Lee EL, Childer JH. Occult papillary carcinoma of the thyroid with distant metastases. *Cancer*. 1984;54:1093-1100.
- Cady B, Rossi R. An expanded view of risk-group definition in differentiated thyroid carcinoma. *Surgery*. 1988;104:947-953.
- Sugino K, Ito K Jr, Ozaki O, Mimura T, Iwasaki H, Ito K. Papillary microcarcinoma of the thyroid. *J Endocrinol Invest*. 1998;21:445-448.
- Harach HR, Fransilla KO, Wasenius VM. Occult papillary carcinoma of the thyroid: a "normal" finding in Finland: a systematic autopsy study. *Cancer*. 1985;56:531-538.
- Lang W, Borrusch H, Bauer L. Occult carcinomas of the thyroid: evaluation of 1,020 sequential autopsies. *Am J Clin Pathol*. 1988;90:72-76.
- Byar DP, Green SB, Dor P, et al. A prognostic index for thyroid carcinoma: a study of the E.O.R.T.C. Thyroid Cancer Cooperative Group. *Eur J Cancer*. 1979;15:1033-1041.
- Hay ID, Grant CS, Taylor WF, McConahey WM. Ipsilateral lobectomy versus bilateral lobar resection in papillary thyroid carcinoma: a retrospective analysis of surgical outcome using a novel prognostic scoring system. *Surgery*. 1987;102:1088-1095.
- Hay ID, Bergstralh EJ, Geollner JR, Ebersold JR, Grant CS. Predicting outcome in papillary thyroid carcinoma: development of a reliable prognostic scoring system in a cohort of 1779 patients surgically treated at one institution during 1940 through 1989. *Surgery*. 1993;114:1050-1058.
- Lupoli G, Vitale G, Caraglia M, et al. Familial papillary thyroid microcarcinoma: a new clinical entity. *Lancet*. 1999;353:637-639.
- Kwok CG, McDougall IR. Familial differentiated carcinoma of the thyroid: report of five pairs of siblings. *Thyroid*. 1995;5:395-397.
- Hay ID, Grant CS, van Heerden JA, Ebersold JR, Bergstralh EJ. Papillary thyroid microcarcinoma: a study of 535 cases observed in a 50-year period. *Surgery*. 1992;112:1139-1147.
- van Heerden JA, Hay ID, Goellner JR, et al. Follicular thyroid carcinoma with capsular invasion alone: a nonthreatening malignancy. *Surgery*. 1992;112:1130-1138.
- DeGroot LJ, Kaplan EL, McCormick M, Straus FH. Nature history, treatment, and course of papillary thyroid carcinoma. *J Clin Endocrinol Metab*. 1990;71:414-424.
- Carcangiu ML, Zampi G, Pupi A, Castagnoli A, Rosai J. Papillary carcinoma of the thyroid: a clinicopathologic study of 241 cases treated at the University of Florence, Italy. *Cancer*. 1985;55:805-828.
- Tubiana M, Schlumberger M, Rougier P, et al. Long-term results and prognostic factors in patients with differentiated thyroid carcinoma. *Cancer*. 1985;55:794-804.
- Woolner LB. Thyroid carcinoma: pathologic classification with data on prognosis. *Semin Nucl Med*. 1971;1:481-502.
- Schindler AM, van Melle G, Evequoz B, Scazziga B. Prognostic factors in papillary carcinoma of the thyroid. *Cancer*. 1991;68:324-330.
- Chow SM, Law SC, Chan JK, Au SK, Yau S, Lau WH. Papillary microcarcinoma of the thyroid: prognostic significance of lymph node metastasis and multifocality. *Cancer*. 2003;98:31-40.
- Ashcraft MW, van Herle AJ. The comparative value of serum thyroglobulin measurements and iodine 131 total body scans in the follow-up study of patients with treated differentiated thyroid cancer. *Am J Med*. 1981;71:806-814.
- Lin JD, Huang MJ, Hsu BR, et al. Significance of postoperative serum thyroglobulin levels in patients with papillary and follicular thyroid carcinomas. *J Surg Oncol*. 2002;80:45-51.
- Ozata M, Suzuki S, Miyamoto T, Liu RT, Fierro-Renoy F, DeGroot LJ. Serum thyroglobulin in the follow-up of patients with treated differentiated thyroid cancer. *J Clin Endocrinol Metab*. 1994;79:98-105.
- Rios Zambudio A, Rodriguez Gonzalez JM, Sola Perez J, Soria Cogollos T, Galindo Fernandez PJ, Parilla Paricio P. Utility of frozen-section examination for diagnosis of malignancy associated with multinodular goiter. *Thyroid*. 2004;14:600-604.
- Ito Y, Uruno T, Nakano K, et al. An observation trial without surgical treatment in patients with papillary microcarcinoma of the thyroid. *Thyroid*. 2003;13:381-387.