

Primary Hyperaldosteronism

Effect of Adrenal Vein Sampling on Surgical Outcome

Fiemu E. Nwariaku, MD; Barbra S. Miller, MD; Richard Auchus, MD, PhD; Shelby Holt, MD; Lori Watumull, MD; Bart Dolmatch, MD; Shawna Nesbitt, MD; Wanpen Vongpatanasin, MD; Ronald Victor, MD; Frank Wians, PhD; Edward Livingston, MD; William H. Snyder III, MD

Hypothesis: Adrenal vein sampling is superior to computed tomography for subtype differentiation of primary hyperaldosteronism.

Design: Retrospective review.

Setting: University medical center.

Patients: Forty-eight patients (32 men and 16 women) with biochemically confirmed primary hyperaldosteronism.

Main Outcome Measures: We compared demographic factors, results of biochemical and imaging studies (computed tomography and adrenal vein sampling), therapy, and patient outcomes.

Results: Mean \pm SEM adrenal nodule size was 1.54 ± 0.2 cm. Adrenal vein sampling was performed in 41 (85%) of 48 patients, and it was successful in 39 (95%) of those 41 patients. Concordance between computed tomography and adrenal vein sampling was observed in 22 (54%) of the 41 patients. Thirty-two patients underwent successful laparoscopic adrenalectomy. There was 1 complication and no deaths. All 32 patients were cured of hypokalemia.

Conclusion: Adrenal vein sampling is superior to image-based techniques for subtype differentiation of primary hyperaldosteronism.

Arch Surg. 2006;141:497-503

Author Affiliations:

Departments of Surgery (Drs Nwariaku, Miller, Holt, Livingston, and Snyder), Medicine (Drs Auchus, Nesbitt, Vongpatanasin, and Victor), Radiology (Drs Watumull and Dolmatch), and Pathology (Dr Wians), University of Texas Southwestern Medical Center, Dallas.

PRIMARY HYPERALDOSTERONISM (PH) is a common cause of secondary hypertension, and recent evidence suggests that the prevalence of PH may be increasing.¹⁻³ Although assays needed to establish the biochemical diagnosis have become routinely available, subtype differentiation is particularly challenging. Aldosterone-producing adenomas (APAs), bilateral hyperplasia (BH), primary unilateral hyperplasia, and familial hyperaldosteronism comprise the major subtypes, but APA and BH represent most cases of PH.⁴ Subtype differentiation is particularly important because surgical therapy for APA is curative, whereas the other subtypes are better managed with potassium-sparing diuretics or aldosterone receptor antagonists. Early studies⁵ suggested that the use of imaging studies to identify unilateral adrenal enlargement in patients with PH was sufficient to make this distinction. However, modern computed tomographic (CT) scanners detect incidental adrenal nodules (incidentalomas) in 0.35% to 5% of CT scans and contribute to the diagnostic dilemma.⁶⁻⁸ Many of these are nonfunctioning incidental nod-

ules found at the time of evaluation for symptoms unrelated to adrenal origin.⁷⁻¹⁰

The diagnosis of APA and its localization in patients with PH can be attempted using a variety of techniques, including saline suppression, captopril stimulation, adrenal scintigraphy 6- β -[¹³¹I]iodomethyl-19-norcholesterol, and adrenal vein sampling (AVS). However, the accuracy of these techniques is variable, with the best results being those for AVS.¹¹ Scintigraphy is of limited utility in PH because of the poor image resolution in nodules smaller than 1.5 cm,¹² and most APAs are smaller than 15 mm.^{13,14} Enthusiasm for AVS has been dampened by the relative dearth of technical expertise required and the invasiveness of the technique. However, improved experience with interventional radiologic procedures and catheter-based vascular therapy has caused a resurgence of interest in AVS.

Few large studies^{13,15-17} have examined the accuracy of image-based diagnosis of APA using AVS. Some of these studies report an advantage of AVS over image-guided diagnosis; however, the variability in patient selection,¹⁵ limits on nodule size,¹⁶ and AVS technique (use of cor-

ticotropin and cutoff values for positive test results)¹⁷ limit conclusions. Furthermore, few of these studies focus on surgical therapy and outcomes of patients with APA.

We examined the utility of CT and AVS in all patients with biochemically confirmed PH seen at the affiliated hospitals and clinics of the University of Texas Southwestern Medical Center between February 1, 2001, and September 30, 2005. Specifically, we determined the accuracy of AVS compared with CT, examined the predictive value of AVS-derived biochemical ratios, and assessed the outcomes for surgically and nonsurgically managed patients.

METHODS

We retrospectively reviewed the medical records of patients who underwent AVS for PH during a 4-year period (2000-2004). Demographic data, such as patient age, sex, and blood pressure (BP), were examined, as were the use of antihypertensive medications, potassium supplementation, results of biochemical and imaging studies (CT and AVS), and therapy. The biochemical diagnosis of PH was made by using plasma aldosterone concentration–plasma renin activity (PAC/PRA) screening test ratios and was confirmed by saline suppression. Screening test results were considered positive if there was a failure to suppress PAC in the presence of suppressed PRA, as described by other researchers.¹⁵⁻¹⁹ Patients with positive screening results underwent confirmation by measurement of 24-hour urinary aldosterone levels ($>14.0 \mu\text{g}/24 \text{ h}$ [$>39 \text{ nmol}/\text{d}$]) after saline suppression.

ADRENAL CT

Most patients underwent abdominal CT at the University of Texas Southwestern Medical Center by a single radiologist (L.W.) using an Aquilon Super 4 (Toshiba Corp, Tokyo, Japan). Our protocol for adrenal CT is as follows. Scan mode is helical from the diaphragm through the middle of the kidneys. The patient undergoes initial noncontrast CT with 2×2 -mm sections followed by injection of 100 mL of Omnipaque 300 (Sanofi Winthrop Markham, Ontario) at 3 mL/s using 2×2 -mm sections with a 70-second delay and then 2×2 -mm sections with a 10- to 15-minute delay.

ADRENAL VEIN SAMPLING

Adrenal vein sampling was performed by 4 interventional radiologists using the same technique, but 1 of these radiologists (B.D.) performed most of the AVS procedures. Our AVS protocol is as follows. When the patient arrives in the radiology suite, a peripheral venous blood sample is obtained for a baseline cortisol level, and corticotropin stimulation is commenced by administration of 0.25 mg of corticotropin¹⁻²⁴ (Cortrosyn; Amphastar Pharmaceuticals Inc, Rancho Cucamonga, Calif) in 300 mL of 5% dextrose in water at a rate of 100 mL/h for the duration of the procedure. This infusion is started at least 20 minutes before obtaining samples.

Bilateral 5F sheaths are inserted into the common femoral veins. Through 1 of these sheaths, a Simmons-2 catheter with 2 small side holes is placed in the left renal vein. Then, a search for the right adrenal vein is performed using 5F catheters. Catheterization is confirmed by venography. A 10-mL blood sample is slowly obtained from the right adrenal vein. Immediately thereafter, the left renal vein catheter is repositioned into the left adrenal vein and confirmed by venography before slowly withdrawing a 10-mL

blood sample. Once adrenal vein specimens are obtained, either the left- or right-sided catheter is repositioned into the inferior vena cava (IVC) for a 10-mL IVC blood sample, and finally, both catheters are removed, and a 10-mL peripheral venous sample is obtained from 1 of the sheaths. Aldosterone and cortisol levels are measured by radioimmunoassay.

We consider adrenal vein cannulation to be successful when the cortisol levels in both adrenal veins are 3 times (or more) higher than the cortisol level in the IVA, whereas lateralization is considered positive when the adrenal vein aldosterone-cortisol (A/C) ratio in the dominant side is 4 times greater than the A/C ratio in the contralateral side.

STATISTICAL ANALYSIS

Results are expressed as mean \pm SEM. Comparisons between 2 groups were performed using the *t* test and among multiple groups using analysis of variance with post hoc analysis. We also compared the sensitivity and specificity of adrenal vein A/C ratios and the A/C ratio of the higher (dominant) vs lower (non-dominant) adrenal glands at various thresholds.

RESULTS

PATIENT CHARACTERISTICS AND PREOPERATIVE FACTORS

Forty-eight patients (32 men and 16 women) had biochemically confirmed PH. Forty-one patients (85%) underwent AVS for PH during the 56 months between February 1, 2001, and September 30, 2005. Mean patient age was 52 ± 2 years. All the patients were hypertensive and were being treated with an average of 3 antihypertensive medications. Their mean BP was 157/96 mm Hg. Furthermore, 79% of the patients required potassium supplementation for hypokalemia (mean serum potassium level, $3.5 \pm 1 \text{ mEq}/\text{L}$). The mean PAC was $52.4 \pm 15 \text{ ng}/\text{dL}$ ($1.4 \pm 0.4 \text{ nmol}/\text{L}$), and the mean PRA was $1.26 \pm 0.3 \text{ pg}/\text{mL}$ ($0.03 \pm 0.007 \text{ pmol}/\text{L}$) per hour. The mean aldosterone-renin ratio was 167 ± 61 . Patients with APAs had higher serum aldosterone levels and PRA than patients with bilateral aldosterone hypersecretion (58.0 vs $22.0 \text{ ng}/\text{dL}$ [1.6 vs $0.6 \text{ nmol}/\text{L}$] and 1.36 vs $0.7 \text{ pg}/\text{mL}$ [0.032 vs $0.016 \text{ pmol}/\text{L}$], respectively).

ADRENAL GLAND CT

Interpretable CT reports were available for 47 patients and revealed 10 right-sided abnormalities, 18 left-sided abnormalities, 14 bilateral abnormalities, and 5 normal adrenal glands. The mean size of the adrenal nodules in this study was $1.5 \pm 0.2 \text{ cm}$.

ADRENAL VEIN SAMPLING

Adrenal vein sampling was performed in 41 (85%) of 48 patients. Bilateral adrenal vein cannulation was successful in 39 (95%) of the 41 patients. The right adrenal vein was not cannulated initially in 6 patients but was successfully accessed in 4 patients who underwent another AVS procedure. Procedure-related adrenal hemorrhage occurred in 1 patient, and it resolved spontaneously, with no apparent adverse outcome. Overall, the mean adrenal vein–IVA A/C ratio was 20. The mean right adrenal

vein A/C ratio was 30 in patients with right-sided hypersecretion, and the mean left adrenal vein ratio was 14 in patients with left-sided hypersecretion.

Using the criteria mentioned previously herein (adrenal vein A/C ratio in the dominant side is 4 times greater than that in the contralateral side), unilateral aldosterone hypersecretion was identified in 29 (71%) of 41 patients. Fourteen patients lateralized to the right adrenal gland, and 15 lateralized to the left adrenal gland. Twelve patients had bilateral adrenal hyperaldosteronism. The A/C ratio in the unilateral hypersecreting adrenal gland was 34 times the ratio in the contralateral side. The mean dominant-nondominant A/C ratio in patients with BH was 1.9.

AVS RATIOS

We examined the predictive value of 3 biochemical ratios (adrenal vein A/C ratio, dominant-nondominant A/C ratio, and contralateral adrenal vein-IVA A/C ratio) for predicting the presence of unilateral aldosterone hypersecretion. The adrenal vein A/C ratio greater than 4 had the best predictive value. The mean dominant-nondominant A/C ratio was higher in patients who underwent surgery, but this difference did not achieve statistical significance (**Figure 1**).

PREDICTIVE VALUE OF CT VS AVS

Forty patients underwent both CT and AVS. The side of abnormality seen on CTs was compared with AVS results of hypersecretion to determine concordance between the 2 studies. Overall, 22 (55%) of 40 patients had concordance between CT and AVS. Twenty patients had unilateral CT abnormalities, and 14 (70%) of them lateralized to the same side (concordant). Of the remaining 6 patients with unilateral CT abnormalities (3 left and 3 right), 1 patient each lateralized to the opposite side and 2 patients each had bilateral hypersecretion. Only 5 of 15 patients (33%) with bilateral CT abnormalities showed concordant bilateral aldosterone hypersecretion. The other 10 patients (67%) demonstrated unilateral hypersecretion. Of the 5 patients with normal-appearing adrenal glands on CT, 1 patient each lateralized to 1 side, and the other 3 patients had bilateral hypersecretion. We found no significant difference between the CT/AVS concordance in patients with micronodules (<1 cm, 67% concordance) and macronodules (>1 cm, 60% concordance). However, the mean age of patients with bilateral CT abnormalities was significantly higher than that of patients with unilateral abnormalities (58 ± 14 vs 47 ± 10 years; *P* = .008).

Patients with BH diagnosed by AVS were compared with those with a unilateral APA. There was no significant difference in mean age (51.0 vs 51.7 years) or male-female ratio (2:1) between patients with BH and APA. However, the mean PAC/PRA ratio for those with BH vs APA was 50 vs 196.

THERAPY AND OUTCOME

Adrenalectomy

Thirty-two patients (21 men and 11 women; 14 right adenomas and 18 left adenomas) underwent laparoscopic

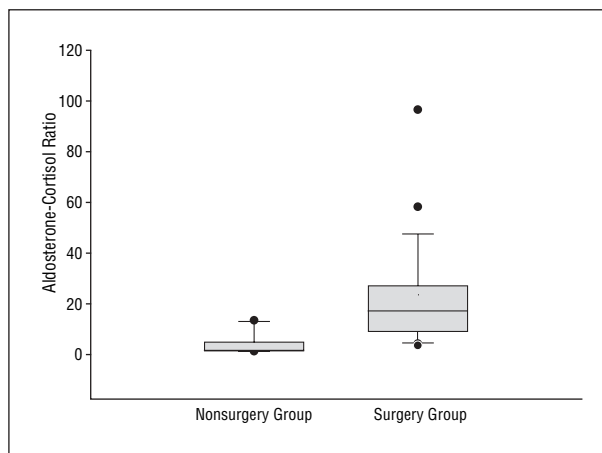


Figure 1. Box plots illustrating the dominant-nondominant aldosterone-cortisol ratios in patients who underwent surgery vs patients who were managed medically. The boundary of the box closest to zero indicates the 25th percentile, the line within the box marks the median, and the boundary of the box farthest from zero indicates the 75th percentile. Whiskers above and below the box indicate the 90th and 10th percentiles. Solid circles are outliers.

adrenalectomy for PH: 25 underwent AVS and localized to 1 side for excess aldosterone production and 7 underwent adrenalectomy without previous AVS. Mean operative time was 102 ± 55 minutes, and the mean hospital stay was 1.7 ± 1 days. Mean estimated blood loss was 46 ± 34 mL. All but 1 of the 32 patients were cured of hypokalemia (none required potassium supplements), 6 patients (19%) completely stopped using antihypertensive medication, whereas an additional 15 patients (47%) were normotensive (systolic BP <140 mm Hg) when taking a reduced dosage of antihypertensive medication. Compared with preoperative BPs, the mean postoperative BPs were significantly lower in surgical patients (157/96 vs 127/79 mm Hg; *P* = .007). Patients were taking an average of 1.8 antihypertensive medications after surgery compared with 3 medications before surgery. The mean potassium level was 4.3 mEq/L after surgery and 3.5 mEq/L before surgery. One patient developed a postoperative deep vein thrombosis that resolved without sequela after anticoagulation therapy. There were no intraoperative complications, conversions to open adrenalectomy, or perioperative deaths. Pathological examination findings revealed 13 adrenal adenomas that averaged 1.32 cm. Of the 2 patients with normal-appearing adrenal glands on CT who underwent adrenalectomy, 1 had a 0.9-cm cortical adenoma and the other had cortical nodular hyperplasia. Both patients had resolution of hypokalemia after surgery.

We compared 25 patients who underwent AVS before adrenalectomy with 7 patients who underwent adrenalectomy without AVS. In the former cohort, 4 patients stopped taking all antihypertensive medications (16%), and 2 (29%) of the 7 patients without AVS were cured of hypertension. Six of these 7 patients were cured of hypokalemia. These patients all had unilateral nodules seen on CT. The mean size of these nodules was 1.9 cm (vs 1.5 cm in the AVS group). One of these 7 patients did not improve after surgery. This patient experienced recurrent hypertension (BP, 194/120 mm Hg) and

Table. Comparison Between Surgical Patients and Medically Managed Patients

	Surgical Patients	Nonsurgical Patients
Age, mean ± SEM, y	52.0 ± 12.0	51.5 ± 15.0
Sex, No.		10:5
M	21	
F	11	
Nodule size, mean ± SEM, cm	1.7 ± 0.5	1.5 ± 0.4
Serum aldosterone, mean ± SEM, ng/mL	58 ± 104	21 ± 10
PAC/PRA ratio, mean ± SEM	196 ± 373	51 ± 58
Peripheral vein A/C ratio, mean ± SEM	44 ± 113	8 ± 12

Abbreviations: A/C, aldosterone-cortisol; PAC/PRA, plasma aldosterone concentration–plasma renin activity.

SI conversion factor: To convert serum aldosterone to nanomoles per liter, multiply by 0.0277.

hypokalemia several months after a laparoscopic adrenalectomy consistent with a wrong diagnosis of APA. This patient's CT initially demonstrated a 0.8-cm cortical nodule in the right adrenal gland, and she had an elevated PAC/PRA ratio of 55.6. Her hypertension is currently controlled with 3 antihypertensive drugs and potassium supplementation. Another patient in the non-AVS group required an increased dosage of antihypertensive medication after surgery. The mean preoperative serum potassium level was 3.4 mEq/L in the AVS group and 2.7 mEq/L in the non-AVS group.

Medical Therapy

Fifteen patients (12 with BH and 3 with APA) were treated medically (8 with spironolactone and 4 with eplerenone) because of AVS-diagnosed BH or refusal of surgery. Hypertension improved in 8 of these patients, whereas 2 patients developed worsening hypertension. There were no significant differences between the surgical and nonsurgical groups (**Table**).

Based on these findings, a CT-based approach to the evaluation of patients with PH would have led to inappropriate therapy in 45% of the patients. Specifically, 12 (60%) of 20 patients would have been incorrectly excluded from having surgery, whereas nonindicated surgery or wrong side surgery would have been performed in 6 (30%) of 20 patients (**Figure 2**).

COMMENT

This study demonstrates that AVS is markedly superior to abdominal CT in localizing APAs in patients with PH. Successful bilateral adrenal vein cannulation is feasible, and the procedure is associated with low morbidity. The sole use of image-based methods for diagnosing APA or BH would have resulted in inappropriate or suboptimal treatment in almost half of the patients in this study.

These findings are similar to those of previous studies,^{15,16} which confirm an important role for AVS in patients with PH. Rossi and colleagues¹⁶ found AVS to be highly diagnostic of APA in patients with equivocal CT or magnetic resonance imaging results. Although their

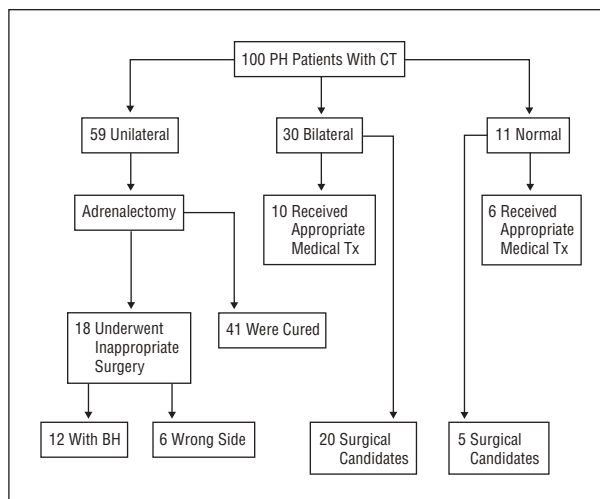


Figure 2. Projected effects of computed tomography (CT)-guided therapy. BH indicates bilateral hyperplasia; PH, primary hyperaldosteronism; and Tx, treatment.

results remain important, patients with “unequivocal” imaging studies were excluded, as were those with tumors larger than 1.8 cm. Outcomes in patients who underwent surgery are also lacking in their study. We believe that the inclusion of all patients with PH in the present study provides information that is easier to extrapolate to all patients with biochemically confirmed PH, regardless of CT findings. Young and associates¹⁵ imposed no CT-based restriction criteria in their study of 203 patients with PH, 92 of whom underwent adrenalectomy. They also noted a high rate of bilateral adrenal cannulation (95%) despite the relatively more stringent criteria used to document successful adrenal vein cannulation (>5 times the IVC cortisol level). They concluded that using CT alone would have led to unnecessary surgery in 24% of the patients and that another 22% of the patients would have been denied surgery inappropriately. We found similar discordant findings between CT and AVS in 30% of the patients with unilateral adrenal abnormalities and in 67% of those with bilateral abnormalities. The former group is of particular concern because of the potential for removal of the biochemically normal adrenal gland. We found no relationship between patient age and the prevalence of micronodules, perhaps because of the smaller sample size; however, the average age of patients with bilateral adrenal lesions was significantly higher than that of those with unilateral lesions, supporting the premise that older patients have a tendency to develop incidental adrenal abnormalities.

Adrenal vein sampling is accurate for predicting the side of aldosterone hypersecretion in APA, and it confirms BH; however, the biochemical ratio with the best predictive value is unclear. Adrenal vein aldosterone levels are unreliable; therefore, most studies suggest the use of A/C ratios, sometimes referred to as the *corrected aldosterone*.^{4,14,16,19,20} This ratio is necessary to account for fluctuations in aldosterone secretion due to the invasive procedure and to correct for “dilution” of the adrenal vein sample with blood aspirated from the IVC or left renal vein. However, whether one should use the raw cor-

rected aldosterone from the suspected adrenal gland, the A/C ratio of dominant-nondominant aldosterone, or the suppressed aldosterone from the contralateral adrenal gland is still debated.

Doppman et al^{18,21} found that after corticotropin infusion, most patients with APA or primary adrenal hyperplasia demonstrated a corrected aldosterone (A/C ratio) greater than 5:1 between the dominant and nondominant sides. However, more recently, Rossi et al¹⁶ found that the ratio of corrected aldosterone in the dominant compared with the nondominant adrenal gland provided the best sensitivity, and the threshold of greater than 2 had the best combination of sensitivity and false-positive rates. We noted a similar trend in the present study. The adrenal vein corrected aldosterone-IVC and the dominant-nondominant ratios performed well (at a threshold of >3 or 4) in predicting APA during this study. At these thresholds, both studies demonstrated high sensitivity and specificity. As expected, increasing the threshold beyond 4 reduced the sensitivity. Using these criteria, AVS and CT findings correlated in 22 of 41 patients, for a concordance rate of 54%. In those with APA, the concordance rate was 70%. This is similar to the 51% to 65% concordance rate in patients with APA described by Young et al.¹⁵ We identified a much lower concordance rate (33%) for patients with bilateral CT abnormalities. Specifically, two thirds of this group demonstrated unilateral hypersecretion, underscoring the importance of AVS in patients with any bilateral abnormalities. Finally, we noted a 60% concordance rate in 5 patients with normal findings on adrenal CT, that is, bilateral hypersecretion. This is similar to findings by Young et al,¹⁵ who noted a 41% unilateral hypersecretion rate in patients with normal findings on adrenal CT.

Laparoscopic adrenalectomy was associated with low morbidity rates and a short hospital stay in the present study. As with other studies,^{22,23} hypokalemia resolved in all the patients who underwent adrenalectomy; however, the effect of adrenalectomy on hypertension was variable.^{23,24} Although the mean postoperative BPs were significantly lower than the mean preoperative levels and the average number of antihypertensive drugs used was lower, individual responses varied. This is similar to findings by others and probably reflects the underlying prevalence of essential hypertension in these patients and the development of fixed hypertension in patients with a secondary cause. However, recent evidence suggests significant cardiovascular benefit by reducing circulating aldosterone levels despite persistent hypertension.²⁵⁻³⁰ Therefore, we believe that the advantage of reducing aldosterone levels in these patients goes beyond resolution of hypokalemia and hypertension.

A group of 7 highly selected patients seen early in our experience had good outcomes despite not undergoing AVS for localization. These patients had larger nodules and more severe hypokalemia, but 2 of them developed worsening hypertension. We would consider offering unilateral adrenalectomy to patients with large unilateral nodules and completely normal contralateral adrenal glands in the presence of severe PH.

This study did not address the additional cost of AVS, a factor that should be considered in evaluating

the approach to therapy. The recent availability of a selective aldosterone receptor antagonist, eplerenone, provides a safe and effective means of preventing the deleterious effects of excess circulating aldosterone. As the cost of such drugs decreases, and the safety profile improves, enthusiasm to treat patients with APA with these agents may ensue. In fact, studies^{31,32} have documented improvement in BP, and hypokalemia in patients with APA managed medically using aldosterone receptor antagonists. Although many researchers believe that the cost-benefit analysis favors adrenalectomy in patients who can withstand surgery, few direct comparisons exist. Sywak and Pasięka³³ suggested a cost-benefit advantage for adrenalectomy compared with life-long medical therapy in patients with PH; however, that study was underpowered.

The age of the patient, the severity of hypertension, and comorbidity must be considered in the therapeutic decision for individual patients. The lack of long-term surveillance of patients in this study is a limitation because the beneficial effects of therapy could occur long after surgery. However, we have used the resolution of hypokalemia as a surrogate for relief of hyperaldosteronism, understanding full well that we may have patients with persistent or recurrent hyperaldosteronism long after unilateral adrenalectomy, hence our ongoing follow-up of these patients.

Abdominal CT is unreliable in correctly identifying the abnormal adrenal gland in patients with PH due to APAs, particularly when both adrenal glands are abnormal. We believe that the liberal use of adjunctive diagnostic studies, such as AVS, is crucial for accurate subtype differentiation in patients with PH. Adrenal vein sampling is accurate and has a low morbidity rate. Laparoscopic adrenalectomy is associated with excellent outcomes in patients with APAs.

Accepted for Publication: December 18, 2005.

Correspondence: Fiemu E. Nwariaku, MD, Department of Surgery, University of Texas Southwestern Medical Center, 5323 Harry Hines Blvd, Dallas, TX 75390-9156 (fiemu.nwariaku@utsouthwestern.edu).

Previous Presentation: This paper was presented at the 113th Scientific Session of the Western Surgical Association; November 8, 2005; Rancho Mirage, Calif; and is published after peer review and revision. The discussions that follow this article are based on the originally submitted manuscript and not the revised manuscript.

REFERENCES

1. Loh KC, Koay ES, Khaw MC, Emmanuel SC, Young WF Jr. Prevalence of primary aldosteronism among Asian hypertensive patients in Singapore. *J Clin Endocrinol Metab.* 2000;85:2854-2859.
2. Rossi E, Regolisti G, Negro A, Sani C, Davoli S, Perazzoli F. High prevalence of primary aldosteronism using postcaptopril plasma aldosterone to renin ratio as a screening test among Italian hypertensives. *Am J Hypertens.* 2002;15:896-902.
3. Fardella CE, Mosso L, Gomez-Sanchez C, et al. Primary hyperaldosteronism in essential hypertensives: prevalence, biochemical profile, and molecular biology. *J Clin Endocrinol Metab.* 2000;85:1863-1867.
4. Young WF Jr. Minireview: primary aldosteronism—changing concepts in diagnosis and treatment. *Endocrinology.* 2003;144:2208-2213.
5. White EA, Schambelan M, Rost CR, Biglieri EG, Moss AA, Korobkin M. Use of

- computed tomography in diagnosing the cause of primary aldosteronism. *N Engl J Med*. 1980;303:1503-1507.
6. Nwariaku FE, Champine J, Kim LT, Burkey S, O'keefe G, Snyder WH III. Radiologic characterization of adrenal masses: the role of computed tomography-derived attenuation values. *Surgery*. 2001;130:1068-1071.
 7. Korobkin M. CT characterization of adrenal masses: the time has come. *Radiology*. 2000;217:629-632.
 8. Boland GW, Lee MJ, Gazelle GS, Halpern EF, McNicholas MM, Mueller PR. Characterization of adrenal masses using unenhanced CT: an analysis of the CT literature. *AJR Am J Roentgenol*. 1998;171:201-204.
 9. Francis IR, Korobkin M. Incidentally discovered adrenal masses. *Magn Reson Imaging Clin N Am*. 1997;5:147-164.
 10. Bastounis EA, Karayiannakis AJ, Anapliotou ML, Nakopoulou L, Makri GG, Papalambros EL. Incidentalomas of the adrenal gland: diagnostic and therapeutic implications. *Am Surg*. 1997;63:356-360.
 11. Ganguly A. Primary aldosteronism. *N Engl J Med*. 1998;339:1828-1834.
 12. Nomura K, Kusakabe K, Maki M, Ito Y, Aiba M, Demura H. Iodomethylnorcholesterol uptake in an aldosteronoma shown by dexamethasone-suppression scintigraphy: relationship to adenoma size and functional activity. *J Clin Endocrinol Metab*. 1990;71:825-830.
 13. Rossi GP, Chiesura-Corona M, Tregnaighi A, et al. Imaging of aldosterone-secreting adenomas: a prospective comparison of computed tomography and magnetic resonance imaging in 27 patients with suspected primary aldosteronism. *J Hum Hypertens*. 1993;7:357-363.
 14. Geisinger MA, Zelch MG, Bravo EL, Risiusi BF, O'Donovan PB, Borkowski GP. Primary hyperaldosteronism: comparison of CT, adrenal venography, and venous sampling. *AJR Am J Roentgenol*. 1983;141:299-302.
 15. Young WF, Stanson AW, Thompson GB, Grant CS, Farley DR, van Heerden JA. Role for adrenal venous sampling in primary aldosteronism. *Surgery*. 2004;136:1227-1235.
 16. Rossi GP, Sacchetto A, Chiesura-Corona M, et al. Identification of the etiology of primary aldosteronism with adrenal vein sampling in patients with equivocal computed tomography and magnetic resonance findings: results in 104 consecutive cases. *J Clin Endocrinol Metab*. 2001;86:1083-1090.
 17. Magill SB, Raff H, Shaker JL, et al. Comparison of adrenal vein sampling and computed tomography in the differentiation of primary aldosteronism. *J Clin Endocrinol Metab*. 2001;86:1066-1071.
 18. Doppman JL, Gill JR Jr, Miller DL, et al. Distinction between hyperaldosteronism due to bilateral hyperplasia and unilateral aldosteronoma: reliability of CT. *Radiology*. 1992;184:677-682.
 19. Young WF Jr, Klee GG. Primary aldosteronism: diagnostic evaluation. *Endocrinol Metab Clin North Am*. 1988;17:367-395.
 20. Young WF Jr, Stanson AW, Grant CS, Thompson GB, van Heerden JA. Primary aldosteronism: adrenal venous sampling. *Surgery*. 1996;120:913-919.
 21. Doppman JL, Gill JR Jr. Hyperaldosteronism: sampling the adrenal veins. *Radiology*. 1996;198:309-312.
 22. Rossi GP, Sacchetto A, Visentin P, et al. Changes in left ventricular anatomy and function in hypertension and primary aldosteronism. *Hypertension*. 1996;27:1039-1045.
 23. Sawka AM, Young WF, Thompson GB, et al. Primary aldosteronism: factors associated with normalization of blood pressure after surgery. *Ann Intern Med*. 2001;135:258-261.
 24. Celen O, O'Brien MJ, Melby JC, Beazley RM. Factors influencing outcome of surgery for primary aldosteronism. *Arch Surg*. 1996;131:646-650.
 25. Rocha R, Martin-Berger CL, Yang P, Scherrer R, Delyani J, McMahon E. Selective aldosterone blockade prevents angiotensin II/salt-induced vascular inflammation in the rat heart. *Endocrinology*. 2002;143:4828-4836.
 26. Rocha R, Rudolph AE, Friedrich GE, et al. Aldosterone induces a vascular inflammatory phenotype in the rat heart. *Am J Physiol Heart Circ Physiol*. 2002;283:H1802-H1810.
 27. Rocha R, Funder JW. The pathophysiology of aldosterone in the cardiovascular system. *Ann N Y Acad Sci*. 2002;970:89-100.
 28. Rocha R, Williams GH. Rationale for the use of aldosterone antagonists in congestive heart failure. *Drugs*. 2002;62:723-731.
 29. Stier CT Jr, Chander PN, Rocha R. Aldosterone as a mediator in cardiovascular injury. *Cardiol Rev*. 2002;10:97-107.
 30. Martinez DV, Rocha R, Matsumura M, et al. Cardiac damage prevention by eplerenone: comparison with low sodium diet or potassium loading. *Hypertension*. 2002;39:614-618.
 31. Ghose RP, Hall PM, Bravo EL. Medical management of aldosterone-producing adenomas. *Ann Intern Med*. 1999;131:105-108.
 32. Bravo EL. Medical management of primary hyperaldosteronism. *Curr Hypertens Rep*. 2001;3:406-409.
 33. Sywak M, Pasiaka JL. Long-term follow-up and cost benefit of adrenalectomy in patients with primary hyperaldosteronism. *Br J Surg*. 2002;89:1587-1593.

Melanie Richards, MD, San Antonio, Tex: The diagnosis and treatment of PH really has become quite a challenge and more complicated since Conn's initial description back in 1955. The multiple subtypes, as Dr Nwariaku had showed you, have really necessitated screening tests with aldosterone-renin ratios in conjunction with an aldosterone suppression test. Once confirmed, the patient is typically followed with an imaging study to localize the adenoma. The decision to proceed with AVS is controversial. Dr Nwariaku and his colleagues have done an excellent job presenting results that suggest that this study should be performed in all patients. Their manuscript differed slightly from their abstract by including 50% more patients who underwent adrenalectomy and excluding the patients who had aldosterone-renin ratios that were less than 20. It is from these data that I have a few questions.

My first question relates to the patient cohort that did not undergo AVS. In this study, 86% (6/7) of these patients who underwent adrenalectomy with CT imaging alone had improvement in the management of their hypertension. This compares with only 60% (15/25) of the patients who had improvement following AVS and subsequent adrenalectomy. The excellent results in the patients who had CT alone suggests that the 54% concordance rate in the patients with both CT and AVS did not apply to these patients. There appears to be a selection bias. How were the patients selected to undergo adrenalectomy with CT alone, and which factors may have contributed to the increased success rate in these patients? Could the specificity of the aldosterone-renin ratio elevated to amount "X" in conjunction with a dominant nodule on CT of greater than a size "Y" be high enough to proceed directly to surgery?

Second, the negative effects of hyperaldosteronism on the cardiovascular system have recently come to the forefront in the medical literature. As we know, adrenalectomy in PH is very successful in leading to the resolution of the hypokalemia, with 100% success rates in those studies. It now may have the added effect of improving cardiac morbidity. Do you have follow-up aldosterone levels in your patients?

My final question is really a difficult one to ask as an endocrine surgeon. Eplerenone, a selective aldosterone receptor antagonist, does not have the side effects that spironolactone did. In essence, the patients don't have the gynecostasia or the vaginal bleeding. It is well tolerated. It costs approximately \$100 a month. Comparing this to the cost of AVS in conjunction with laparoscopic adrenalectomy, at least in my institution, it is more expensive to get the venous sampling than to do the adrenalectomy. It would probably take about 12 to 15 years to break even. Do you think that PH will become a medical disease?

Dr Nwariaku: Thank you, Dr Richards, for your thoughtful questions. In response to the question about the outcomes of patients who underwent surgery without AVS, those patients were patients we enrolled early on, at the beginning of the study, and, interestingly, they demonstrated more severe hyperaldosteronism. Their nodule sizes were significantly larger, over 2 cm. They had more severe hypertension, profound hypokalemia, and required more antihypertensive drugs. So these patients were included in the surgical group but did not undergo AVS because of their unequivocal severe hyperaldosteronism.

In response to your question about eplerenone, there has been interest by some to treat patients with APAs medically, with good results. And now with eplerenone, which has a more favorable side effect profile, there is more enthusiasm to do that. The question becomes one of cost. And that is one of the limitations of our study. There are no data looking at the cost of long-term use of eplerenone compared with surgery. There is

a study I think by Dr Pasioka and colleagues from several years ago which examines the medical management with spironolactone vs surgery, and they demonstrated cost benefit for surgical patients who underwent adrenalectomy. This question probably needs to be examined in the future.

Clive S. Grant, MD, Rochester, Minn: We agree entirely that AVS is an excellent and vitally important technique, but not necessarily for every patient. Have you found a subgroup of patients for whom you might be able to rely on CT, for example, a younger patient with more severe disease, with a single nodule in 1 adrenal gland and the contralateral adrenal that is well visualized and normal? Second, if guided by AVS, how often have you identified unilateral hyperplasia as the pathology after adrenalectomy, and what has been the outcome of those patients?

Dr Nwariaku: The findings with AVS are similar to those presented by your group. Currently, we offer AVS to all our patients. Part of the reason is that we see patients with abdominal CT obtained from outside radiologists, and many of these are either inadequately performed or improperly interpreted. So we are either repeating them or sending them to AVS.

The subgroup of patients that I would anticipate would not require AVS would be patients such as those I just described, the patient with more severe hyperaldosteronism, more severe hypokalemia, and larger nodules. And if you examine the older data, when CT was used and found to be accurate, those nodules were usually 2 and 2.5 cm, and the other adrenal gland was normal. So such patients may benefit from adrenalectomy without AVS.

Quan-Yang Duh, MD, San Francisco, Calif: Of the 20 patients who had unilateral disease by CT scan, 14 had a concordant study and 6 had a discordant study. Were there any differences in the size of the tumors in the concordant vs the discordant ones? We all agree that if the CT scan shows bilateral normal or bilateral abnormal glands, you need venous sampling. But the discordant percentage of 30% seems high.

The second question is, after a positive venous sampling finding high secretion on one side only, have you ever had a failed operation? We have at least 1 failure after a positive venous sampling. You would expect selected venous catheterization to be 100% accurate, if positive, but it is not.

Dr Nwariaku: There were no differences in the sizes of the nodules in the concordant or discordant lesions. Part of that may just be that this subgroup is a highly selected group and has really small tumors, so I am not sure that we would find those differences.

Now, regarding the question of failed AVS, this is a small group of patients, but we haven't had that problem. Now, the Mayo Clinic reports about a 1% incidence of primary unilateral adrenal hyperplasia. Obviously, the long-term follow-up is where the answer to that question will lie. It is possible that there are patients who have bilateral hyperaldosteronism which starts off on one side and eventually develop hypersecretion on the other side, or this could be pure primary unilateral hyperplasia.

Samuel Snyder, MD, Temple, Tex: Here is not an uncommon clinical problem that we might face. Adrenal vein sampling (as you pointed out) of the right adrenal vein is difficult to sometimes access, but we get results from the left adrenal vein in the patient with bilateral adrenal nodules. The left adrenal vein aldosterone is increased, but we have no values from the right. How do you manage that patient?

Dr Nwariaku: I think there are 2 patients in this series where we had that problem. And we cheated a little bit. If we can demonstrate that the samples from the area of the right adrenal vein, even if we are not absolutely sure of right vein cannulation, are suppressed compared with the IVC samples, and if the ratio is high, that is, 10:1, for instance, instead of 4:1, we have considered that successful and operated on those 2 patients and they did just well. So that is one possibility. The other way would be to put the patient on eplerenone. Another option is to repeat the AVS procedure. As I showed, 2 patients required a repeat sampling study to obtain the correct numbers.

Cord Sturgeon, MD, Chicago, Ill: My comments are directed toward the data in your abstract. You stated in the abstract that 20 patients had undergone successful adrenalectomy. By looking at the data, I assume that this group of 20 is composed of 12 patients with unilateral CT scan findings and concordant lateralization with AVS and 8 patients with bilateral nodules which then lateralized on AVS, making the 20.

What about those 5 or 6 patients who had a unilateral nodule on the CT scan but discordant lateralization by AVS? Since we know that aldosteronomas are almost always very small, 0.5 to maybe 2 cm, and in many cases they are smaller than the limit of resolution of the imaging studies that are used, shouldn't we be resecting all of those adrenal glands that lateralized to even the normal-appearing side? What did you do in those cases?

Dr Nwariaku: My short answer would be, yes, if they have biochemically confirmed PH using fairly stringent criteria, then they have the disease. And if the lesion is not visible on CT scan but the adrenal venous sampling studies are clear, we would perform adrenalectomy on the localized side.

Dr Sturgeon: But nevertheless, if you had a nodule on one side and your AVS showed the secretion was contralateral, you would take out the normal-looking adrenal gland?

Dr Nwariaku: Yes, we would resect the normal-appearing gland.

Thomas Biehl, MD, Seattle, Wash: I know it wasn't part of your study, but I am curious to know if the norcholesterol analogue nuclear medicine study NP-59 [6-β-(¹³¹I)iodomethyl-19-norcholesterol] has been useful at all in your institution and in what setting.

Dr Nwariaku: We have not used the norcholesterol or NP-59. Actually, I don't think that this disease is one where it has much benefit, the reason being that about 20% of patients with PH have tumors that are usually less than 1.5 cm, which is below the limits of resolution for NP-59 scintigraphy. So we haven't used it. In addition to that, it is a 3- to 5-day test and you have to obtain the isotope from outside institutions.