PAPER

Laparoscopic-Assisted Pancreatic Necrosectomy

A New Surgical Option for Treatment of Severe Necrotizing Pancreatitis

Dilip Parekh, MD

Hypothesis: Open surgery for pancreatic debridement is often associated with major morbidity such as wound complications, fascial dehiscence, and intestinal fistulae. Hand-assisted laparoscopic surgery (HALS) is useful for complex abdominal procedures since the benefits of traditional laparoscopic surgery are retained. Published experience with HALS for pancreatic debridement is limited to anecdotal case reports.

Setting: University-affiliated private and public hospitals.

Patients: Twenty-three patients with necrotizing pancreatitis were evaluated and 19 patients underwent pancreatic debridement from 2001 to 2006. A GelPort (Applied Medical, Rancho Santa Margarita, Calif) was used to provide laparoscopic hand access. In the majority of the patients, an infracolic approach was used to access the pancreatic necrosis.

Results: Nineteen patients underwent laparoscopic evacuation of pancreatic necrosis, and in 18 patients, the procedure was completed. The mean age was 54 years; the mean ± SEM body mass index, calculated as weight in kilograms divided by height in meters squared, was 32.0 ± 2.6; the mean American Society of Anesthesiologists score was 3.4; and 7 of 19 patients had past history organ failure. The mean ± SEM operating time was 153 ± 10 minutes and mean ± SEM blood loss was 352.6 ± 103 mL. Four patients required reoperations, 2 using HALS and 2 open. There were no postoperative complications related to the HAL procedure itself, such as major wound infections, intestinal fistulae, or postoperative hemorrhage. Postoperative computed tomographic scans confirmed adequacy of debridement. The mean ± SEM length of hospital stay after surgery was 16.3 ± 3.8 days.

Conclusions: This is the largest reported study of laparoscopic debridement for pancreatic necrosis. The procedure is feasible and associated with a low morbidity and mortality. Pancreatic debridement with HALS may provide a new option for the surgical treatment of selected patients with severe necrotizing pancreatitis.

Arch Surg. 2006;141:895-903

Over the past 2 decades, a substantial improvement in outcome has been reported for critically ill patients with necrotizing pancreatitis. Mortality rates of more than 50% that were commonly reported in the 1970s have now dropped to less than 20% (and in single digits in many specialized pancreatic surgical units).[1-3]

Several factors have contributed to the substantial drop in mortality of acute necrotizing pancreatitis. The improvements in critical care and the widespread availability of critical care trained physicians have markedly diminished the early mortality from hemodynamic insufficiency and systemic inflammatory response syndrom (SIRS). Advances in interventional radiological procedures obviate the need for or allow for temporization of surgical intervention. A multidisciplinary team approach (surgery, radiology, gastroenterology, and critical care) has led to judicious use of surgical intervention. The surgical procedure for pancreatic necrosectomy has been standardized (removal of a sequestrum of clearly identifiable necrotic tissue that is easily separable from surrounding viable tissue during surgery). Furthermore, it is now established that optimal surgical timing should occur, at the minimum, 2 to 3 weeks after the onset of pancreatitis to allow a sequestrum to form, thereby preventing the substantial morbidity and mortality of early pancreatic resections.

Although the surgical mortality for acute necrotizing pancreatitis has been significantly reduced, the short and long morbidity and the economic impact of surgical treatment on the patient and medical resource usage is substantial.[4] Minimal access surgical approaches have been described in an attempt at reducing the mortality and substantial morbidity of open surgery for severe necrotizing pancreatitis.[5-11] These approaches use either an endoscopic[5,11,12] or a videoscopic[9,10] retro-

Author Affiliation: Department of Surgery, University of Southern California, Los Angeles.

©2006 American Medical Association. All rights reserved.
Downloaded From: http://archsurg.jamanetwork.com/ on 08/28/2016

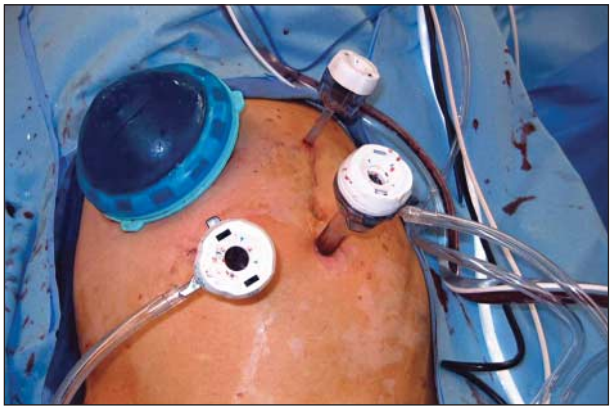

Figure 1. Port placement for hand-assisted laparoscopic pancreatic debridement. The use of a GelPort (Applied Medical, Rancho Santa Margarita, Calif) is demonstrated.

peritoneal approach for draining infected fluid. Because in the majority of the patients, the area of necrosis is limited to the lesser sac,[1] minimal access retroperitoneal techniques have significant limitations for primary debridement of the necrotic sequestrum. The reported experience of minimal access surgery using transperitoneal techniques similar to that used for open surgery for primary debridement of the necrotic pancreatic and peripancreatic material is limited to anecdotal reports.[6,13]

METHODS

PATIENT SELECTION AND METHODS

Patients who underwent a laparoscopic debridement of pancreatic necrosis during the period 2001 through 2006 at the University of Southern California (Los Angeles) were included in this study. All patients who are admitted to our service with a diagnosis of necrotizing pancreatitis undergo a computed tomographic (CT) scan prior to any interventional procedures. Our policy is to avoid surgery on patients emergently during the first 3 weeks of the illness, and we would aggressively use interventional radiological procedures in patients with ongoing progressive sepsis during this period. We use the CT scan to confirm the presence of fluid collections and/or pancreatic necrosis and also for targeted radiological intervention and surgical therapy: the surgical approach is dictated by and directed toward identifiable areas of necrosis on a preoperative CT scan.

The indications for surgery in the patients reported in this study include (1) progressive sepsis or patients who were clinically stable but experienced intermittent episodes of sepsis, particularly during attempts at introducing an oral diet; (2) patients who remained persistently symptomatic after the onset of severe pancreatitis (including persistent symptoms of nausea, episodic emesis, or significant abdominal pain); and (3) failure to tolerate an oral diet or a failure to thrive.

TECHNIQUE OF LAPAROSCOPIC PANCREATIC DEBRIDEMENT

Our technique for pancreatic debridement was as follows. Where the pancreatic necrosis or collection was predominantly in the lesser sac or the left paracolic gutter, the patient was placed in a left lateral position with the body tilted to 60° using a beanbag. If the necrotic areas were predominantly in the right paracolic gutter and retroduodenal area, then the patient was placed in a right lateral position using a beanbag. For the majority of the procedures, we used 3 ports: a hand access device (GelPort, Applied Medical, Rancho Santa Margarita, Calif, in the present study in all the cases) and two 10- to 12-mm standard laparoscopic ports (**Figure 1**).

In our initial experience, we used an infracolic approach to access the lesser sac through the transverse mesocolon.[3] Briefly, the omentum pad is swept into the upper abdomen together with the transverse colon. The area of the duodenojejunal flexure (DJ flexure) is identified, and a small incision is made in the transverse mesocolon just superior and lateral to the DJ flexure. We have found that this area is usually indurated and is often covered with small bowel adhesions. The small bowel adhesions are swept away and the transverse mesocolon is visualized. The transverse mesocolon in this area is often discolored and thinned out and bulges into the infracolic compartment because of pressure from accumulated fluid and/or necrotic tissue in the lesser sac. Gentle dissection into this transverse mesocolon with a 5-mm endodissector readily allows access to the lesser sac behind the stomach. Often a gush of dark grayish material that is typical of pancreatic necrosis is seen when access is secured to the lesser sac. Using the hand through the hand access port, the opening in the transverse mesocolon is digitally enlarged, and a finger introduced through this opening assists in extending the opening and preventing any injuries to the middle colic vessels. The opening is enlarged (**Figure 2**) to accommodate insertion of the palm into the lesser sac, and all the necrotic material that readily yields to gentle finger dissection is removed (Figure 2). Care is taken not to injure any vascular structures in the lesser sac by avoiding traction on tissues that do not readily yield to gentle finger dissection. Any intraoperative bleeding is readily controlled by digital pressure with the hand inserted through the GelPort. Visualization of bleeding in the lesser sac or during the retrocolic dissection was excellent. Bleeding from disrupted omental adhesions is occasionally difficult to visualize, and patients with a rigid, thickened, or engorged omental pad may not be suitable candidates for this technique. With this technique, we are able to debride all the necrotic areas in the lesser sac and often extensions to the left paracolic gutter and the head of the pancreas if these regions communicate with the lesser sac.

In the latter part of our experience, we have also used a direct approach to the lesser sac through the greater omentum between the stomach and the colon. For access to collections on the right side, a retroduodenal approach or dissection at the root of the mesocolon is often necessary to access the region of the head of the pancreas. After the debridement is completed, a triple lumen Abramson sump drain and a Jackson-Pratt suction drain are left behind for postoperative drainage.

DATA COLLECTION

This is a retrospective review of a prospective database of patients undergoing minimal access surgery for pancreatic diseases. The data on the postoperative hemodynamic measurements were obtained retrospectively from hospital electronic medical records or hospital paper charts from original intensive care charted material. Data were analyzed using the MedCalc statistical software and summary statistics were expressed as mean ± SEM or, where specified, as median (range).

RESULTS

PATIENT AND DISEASE CHARACTERISTICS

During the period 2001 to 2006, 23 patients referred to the Pancreas Service at the University of Southern Cali-

©2006 American Medical Association. All rights reserved.
Downloaded From: http://archsurg.jamanetwork.com/ on 08/28/2016

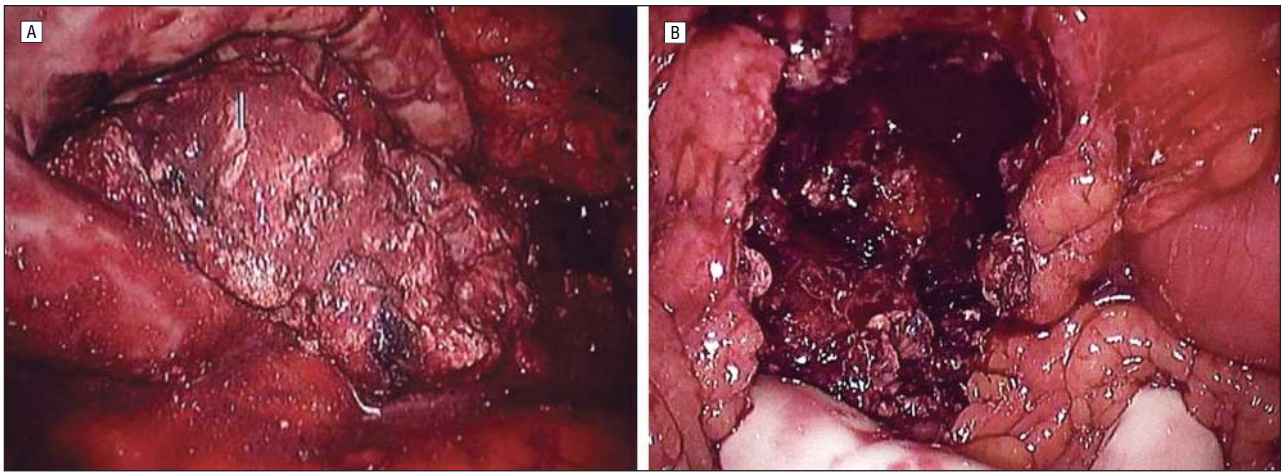

Figure 2. Laparoscopic-assisted pancreatic debridement. A, Debridement and removal of pancreatic necrosis from the lesser sac through an inframesenteric approach. B, Laparoscopic view of the debrided lesser sac cavity.

fornia requiring surgery for severe pancreatitis were evaluated for laparoscopic pancreatic debridement. The etiology of the pancreatitis was gallstones (13 patients), alcohol (5), hyperlipidemia (1), endoscopic retrograde cholangiopancreatography (2), or idiopathic (2). Four patients underwent open surgery: in 2 patients, the abdominal cavity was markedly distended because of a severe ileus and extensive anasarca and ascites, thus making development of an adequate pneumoperitoneum unfeasible, and 2 patients had localized gastric (2 patients) and colonic (1) perforation associated with a previous attempts at cystogastrostomy in the presence of extensive necrotizing pancreatitis at outside facilities. Nineteen patients underwent laparoscopic surgery for pancreatic debridement. In 18 patients, the debridement procedure was completed laparoscopically; 1 patient was converted to open surgery because of an intraoperative enteric injury.

Of the 18 patients who successfully underwent the initial laparoscopic pancreatic debridement, 4 patients required further surgical explorations: 2 were operated on during the early part of our experience and their subsequent procedures were performed by open surgery; the other 2 were re-explored laparoscopically. Thus, a total of 20 laparoscopic procedures were completed in 18 patients and 16 patients were managed only by the laparoscopic route.

Table 1 summarizes the profile in the 18 patients in whom pancreatic debridement was completed with minimal access techniques. Our patient population had a predisposition toward a middle-age male population with a significant incidence of morbid obesity: 7 of 18 patients had a body mass index, calculated as weight in kilograms divided by height in meters squared, greater than 30, (mean ± SEM, 32.0 ± 2.6) and comorbidities (12/18 patients had at least 1 comorbidity involving the cardiopulmonary system). The severity of the pancreatitis is reflected by the fact that the average preoperative American Society of Anesthesiologists score was 3.4. Seven (39%) of 18 patients had organ failure (kidney, respiratory, or cardiac) during the course of their pancreatitis with an average of 2 failed organs per patient among the 7 patients.

Fifteen of 18 patients were initially treated at an outside facility prior to referral to the University of Southern California with a median duration of treatment of 60 days and a median prior admission rate of 1.5 days (range, 1-5). The median duration of conservative treatment prior to surgery was 65 days (range, 22-154). The indications for surgery are described in **Table 2**. The majority of patients were operated on for recurrent non–life-threatening septic episodes or for intractable symptoms.

Table 1. Profile of Patients Who Underwent Laparoscopic Pancreatic Debridement

Characteristic	Value
Age, y (range)	54 (29-70)
Sex, M/F, No.	12/6
BMI, mean ± SEM	32.0 ± 2.6
Weight, mean ± SEM, lb	215.3 ± 21.2
ASA score, mean ± SEM	3.4 ± 0.1
Patients with comorbidities, No.	12/18
Initially treated at a different facility, No.	15/18
Duration of treatment at outside facility, d (median)	60 (8-150)
Duration of surgery after the onset of pancreatitis, d (median)	65 (22-154)
Patients with prior radiological drainage, No.	14/18
Prior admissions, No. admissions/patient (range)	1.5 (1-5)
Patients with history of organ failure, No. (No. failed organs/patient)	7/18 (2)

Abbreviations: ASA, American Society of Anesthesiologists; BMI, body mass index (calculated as weight in kilograms divided by height in meters squared).

Table 2. Indications for Surgery

Indication	No.*
Progressive sepsis with organ failure	3
Recurrent episodes of sepsis	13
Failure to wean off a ventilator	2
Persistent symptoms	6
Failure to tolerate a diet or failure to thrive	7

*More than 1 indication may be present in each patient.

©2006 American Medical Association. All rights reserved.
Downloaded From: http://archsurg.jamanetwork.com/ on 08/28/2016

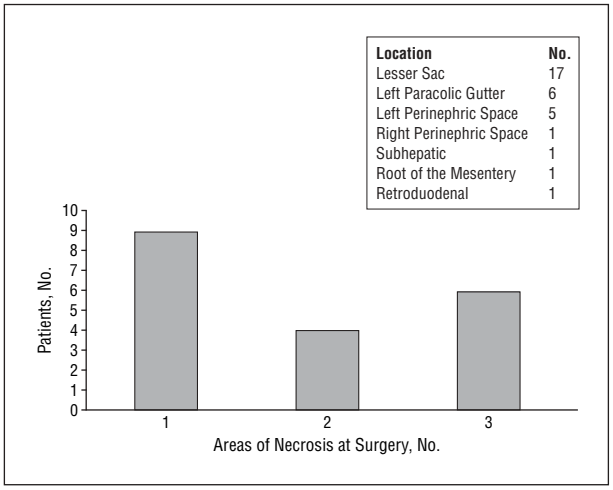

Figure 3. Number and distribution of areas of necrosis at surgery for hand-assisted pancreatic debridement.

Table 3. Outcomes for Patients Successfully Treated With Laparoscopic Techniques

Characteristic	Value
Required postoperative ventilation, No.	7
Duration of ventilation, mean ± SEM, d	7 ± 3.1
Admitted to ICU, No.	12
ICU length of stay, mean ± SEM, d	5.9 ± 1.8
Positive cultures from necrosis area, No.	9
Required postoperative TPN, No.	12
Tolerated a solid diet, No.	8
Tolerated a liquid diet, No.	10
Time to oral diet, mean ± SEM, d	6.2 ± 0.9
Experienced postoperative complications, No.	4
Length of stay after surgery, mean ± SEM, d	16.3 ± 3.8
Developed pancreatic fistula, No.	11
Average fistula volume, mean ± SEM, mL	155 ± 32

Abbreviations: ICU, intensive care unit; TPN, total parenteral nutrition.

OUTCOME OF THE SURGICAL PROCEDURE

Details of the Surgery

Twenty laparoscopic surgical procedures were performed in 18 patients. Seven patients (39%) had prior abdominal surgical procedures, including gastric bypass (2 patients), open cholecystectomy (1 patient), splenectomy (1 patient), and cystogastrostomy (1 patient). In the 2 patients with gastric bypass, the lesser sac was accessed medial to the Roux limb without significant difficulty.

The mean ± SEM duration of the laparoscopic surgical procedure was 153 ± 10 minutes and mean ± SEM blood loss was 352.6 ± 103 mL. Six of 18 patients required a blood transfusion with a median transfusion requirement for the group of 0 U (range, 0-8 U) and a mean ± SEM transfusion requirement of 1.0 ± 0.5 U for the group. In 8 patients, additional procedures were performed: cholecystectomy (4 patients) and jejunostomy feeding tube (4 patients). A cholecystectomy was simultaneously performed with the debridement only if this was readily accomplished without excessively prolonging the procedure and where the risk for bowel injury with an enterotomy was minimal. In 9 patients, there was extensive inflammation in the right upper quadrant that would have made the exposure of the gallbladder difficult with our approach; a cholecystectomy was not performed in this group of patients with gallstone pancreatitis. One significant intraoperative complication was encountered: mobilization of extensive adhesions in the area of the DJ flexure led to a significant enterotomy that required conversion to an open procedure.

Table 4. Microbial Analyses of Positive Cultures From Pancreatic Necrosis Tissue

Genus	No.
Enterococcus	5
Staphylococcus	5
Pseudomonas	2
Candida	3
Stenotrophomonas	1
Protenella	1
Citrobacter	1

Location of Necrotic Areas in the Abdomen

Figure 3 describes the location and incidence of necrosis in the abdominal cavity of 19 patients who were initially explored with laparoscopic techniques. In 47% of patients, the disease was confined to the lesser sac. Ten (53%) of 19 patients had more than 1 retroperitoneal space affected by pancreatic necrosis. In 33% of patients, there was additional disease in the left abdomen that required drainage, and in 17% of patients, there was disease in the right abdomen that required drainage.

Patient Outcome

Of the 18 patients initially explored with a laparoscopic approach, 16 patients were treated primarily by laparoscopic techniques (2 of 18 patients underwent subsequent open reoperations). There were 2 deaths in the 16 patients; therefore, 14 patients were successfully treated and discharged home primarily with laparoscopic techniques. **Table 3** summarizes the outcome in this group of 14 patients. Twelve of 14 patients were admitted to the intensive care unit after the surgery and 7 patients required postoperative ventilation for a mean duration of 7 days. Nine of 14 patients had positive cultures from the pancreatic necrosis tissue submitted for bacteriology during the surgery. **Table 4** summarizes the microbial analysis. The spectrum of microbial infections in these patients is similar to that previously reported.[14] Eight of 14 patients were able to tolerate a solid diet and 2 only a liquid diet prior to discharge; the remaining patients were discharged on jejunostomy feedings or parental nutrition. The length of stay in the hospital after completion of the surgical procedure was 16.3 ± 3.8 days. Postoperative CT scans were obtained in 17 patients within the first week of surgery to confirm the adequacy of the debridement (**Figure 4**).

Five patients developed reversible complications after the surgery: 2 patients developed central line–related com-

©2006 American Medical Association. All rights reserved.
Downloaded From: http://archsurg.jamanetwork.com/ on 08/28/2016

plications, 1 patient had a *Clostridium difficile* infection, 1 patient required reintubation for worsening pulmonary function, and 1 developed delirium tremens and pseudomonas pneumonia. All 5 patients were subsequently discharged from the hospital without any adverse events. The skin incisions for insertion of the GelPort was closed only in 2 patients. One of the 2 patients developed a minor wound infection requiring opening of the incision.

There were 2 deaths in the 16 patients primarily treated by laparoscopic surgery. The first patient had very complex management issues. This was a 49-year-old Jehovah's Witness who presented to us with infected pancreatic necrosis and a ventricular peritoneal shunt for hydrocephalus from a coccidioidomycosis infection 2 years prior to the development of his pancreatitis. He had multiple infective episodes related to the ventricular peritoneal shunt that was initially resited into the chest cavity and then removed. His abdominal CT scan showed multiple sites of intra-abdominal collections of necrotic material, including the lesser sac, left perinephric space, left paracolic gutters, right perinephric space, and right pericolic gutters. His right and left collections were drained by 2 separate laparoscopic surgical procedures to avoid excessive intraoperative stress and bleeding. The patient recovered from both his debridement procedures; however, 8 weeks after his second procedure, he occluded his external ventriculostomy, which had been created after the externalized ventricular peritoneal shunt had occluded. The patient subsequently developed significant neurological dysfunction followed by brainstem herniation. The second death was in a 54-year-old morbidly obese man with multiple organ failure (pulmonary and renal) who developed hemodynamic instability prior to and during the surgery and died within 24 hours after the surgery.

Pancreatic fistulae commonly develop after surgery for severe necrotizing pancreatitis[15] and are usually related to the severity and extent of the underlying necrosis. All 14 patients were studied prior to their discharge, and 11 were found to have a pancreatic fistula (based on elevated amylase levels in the draining fluid in the Jackson-Pratt drains). The mean ± SEM fistula volume as measured over 3 days prior to discharge was 155 ± 32 mL.

Postsurgical Sepsis Response

Preoperative heart rate, temperature, and blood pressure over a 72-hour (h) period was compared with a similar period starting 12 h after surgery. There were no significant differences between preoperative and postoperative measurements in the group as a whole and in the 9 patients with positive intraoperative pancreatic cultures (**Table 5**) ($P > .05$).

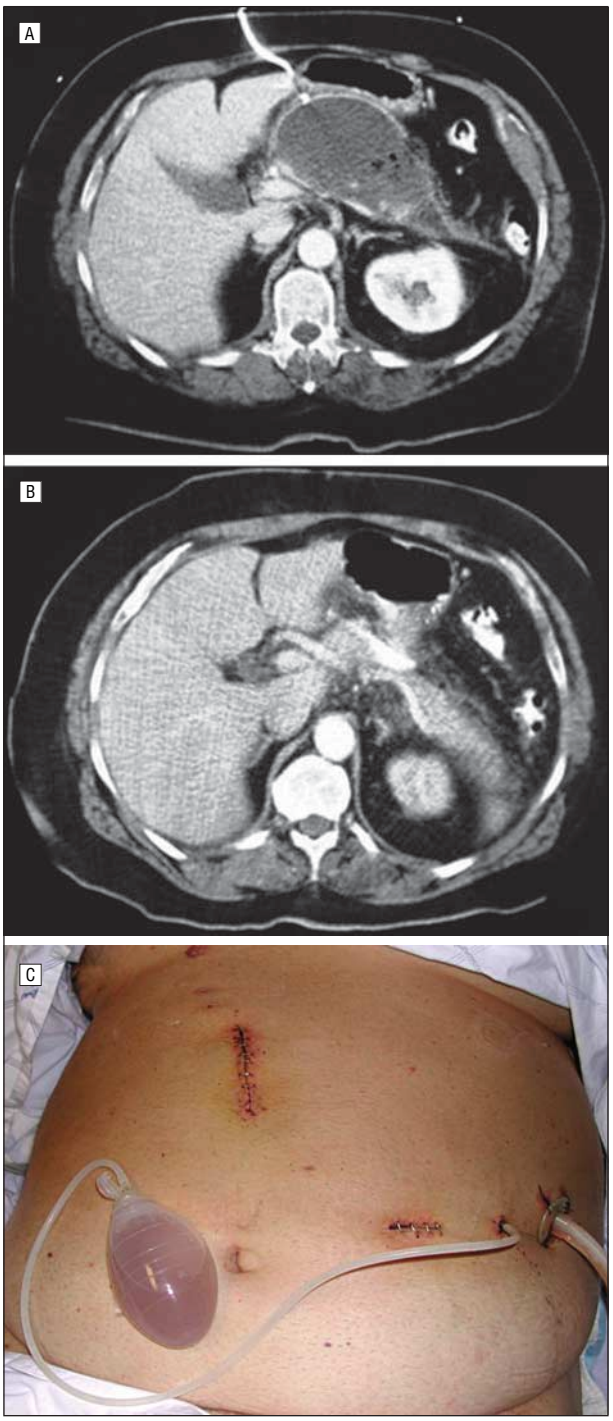

Figure 4. Laparoscopic-assisted pancreatic debridement. A, Computed tomographic (CT) scan showing infected pancreatic necrosis in the lesser sac. B, Postoperative CT scan demonstrating resolution of the necrotic cavity with a Jackson-Pratt drain in situ. C, Abdominal incision in a patient after laparoscopic-assisted pancreatic debridement.

COMMENT

The management of severe acute pancreatitis has undergone a significant evolution over the past 2 decades.[1,3,16-18] Aggressive conservative management with interventional radiological procedures has reduced the need for emergent surgery, and a significant number of patients requiring surgery have persistent non–life-threatening sepsis or failure to thrive.[1] The role of an underlying pancreatic fistula in patients requiring surgery for severe pancreatitis has been recently highlighted.[1,15] These changing trends in the management of acute pancreatitis are reflected in the profile of the patients in our study. Patients were treated aggressively with conservative radiological methods, usually outside our institution. Only 3 of 19 patients required surgery for emergent septic complications while in 16 of 19 patients the

©2006 American Medical Association. All rights reserved.
Downloaded From: http://archsurg.jamanetwork.com/ on 08/28/2016

Table 5. Comparisons of Heart Rate and Temperature Before and After Surgery

Time of Measurement	Heart Rate, Mean ± SEM	Temperature, Mean ± SEM, °F
Preoperative	105.5 ± 5.4	99.5 ± 0.4
Postoperative day 1	106.2 ± 4.6	99.3 ± 0.3
Postoperative day 2	106.0 ± 3.6	99.3 ± 0.2
Postoperative day 3	105.0 ± 4.5	99.2 ± 0.3

surgery was for non–life-threatening recurrent infections or intractable symptoms related to the persistence of pancreatic necrotic tissue in the retroperitoneum. More than two thirds of our patients had an underlying pancreatic fistula that probably contributed to the persistence of the symptoms.

As the need for emergent surgery for life-threatening sepsis in unstable patients has diminished, outcomes of surgery have improved in patients with localized pockets of unresolved necrosis (sequestrum).[1,3,19] Our study confirms this: there were only 2 mortalities in the study (overall mortality of 11%), of which 1 could be ascribed directly to the underlying pancreatitis. Given the more localized nature of disease now being treated,[1] our results suggest that minimal-access surgery may warrant wider application in the treatment of severe pancreatitis. It is unclear if the pneumoperitoneum established during laparoscopy has deleterious effects in critically ill hemodynamically unstable patients. The single death associated with pancreatitis in this study occurred in a patient who was unstable at the time of the surgery. We would urge caution with this procedure in critically ill hemodynamically unstable patients.

Although the mortality rates from surgery have diminished, a substantial morbidity is still reported in patients undergoing open pancreatic debridement. Major wound complications from an open abdomen, intestinal fistulae, wound dehiscence, and prolonged hospital stay remain significant considerations.[20] In our study with small surgical incisions to access the abdominal cavity, there were no major wound complications and no incidence of major wound dehiscence or external bowel fistulae. Only minor complications were noted in the 14 patients who were successfully treated by laparoscopic techniques alone. These results, if confirmed in a larger study, would suggest that laparoscopic-assisted surgery may be preferred to open surgery for selected patients with pancreatic necrosis.

Transperitoneal laparoscopic pancreatic debridement using traditional laparoscopic surgery or the first-generation hand-access devices through a retrocolic access to the lesser sac (an approach similar to that reported in our study) have been previously described in anecdotal case reports.[6] The perceived difficulty of the laparoscopic procedure for pancreatic debridement has led to exploration of alternative minimal access retroperitoneal approaches using videoscopic and endoscopic approaches.[5,9-11] Carter[5] initially reported on 10 patients in whom percutaneous access to the necrosis cavity was obtained; the cavity was dilated to a final size F30, allowing the insertion of an operating nephroscope to remove some of the necrotic material in a piecemeal fashion. Multiple procedures were required to adequately drain all the necrotic tissue with this technique.[5] Horvath and colleagues[9,10] have reported on a promising videoscopic-assisted retroperitoneal approach in which a small subcostal flank incision is used to access the retroperitoneal space through which a videoscope is inserted through a port; debridement is accomplished with hydrodissection and long laparoscopic spoon forceps inserted through a second port.

Persistence of the sequestrum often with an underlying pancreatic fistula (as shown in the majority of our patient population) is the usual cause of continuing sepsis and/or symptoms in patients with severe pancreatitis on conservative treatment.[1,21] Therefore, in our experience, complete removal of the sequestrum as demonstrated by CT evidence of resolution of the necrotic areas is usually necessary for good patient outcome. In our opinion, a major limitation of the retroperitoneal videoscopic and endoscopic techniques is the failure to completely remove the sequestrum to debride the necrotic cavity at the initial surgery. A recent review of the results of the endoscopic retroperitoneal debridement showed 88 procedures performed in 24 patients with a median postoperative stay of 51 days (range, 5-200) and 25% mortality rate.[11] Furthermore, because adequate access to the necrotic areas requires extension of the necrosis into the perinephric and/or the right and left paracolic gutters, only a subgroup of patients who require surgery may be candidates for minimally invasive retroperitoneal approaches. In the present study, through a transperitoneal approach access to the lesser sac, right and left paracolic cutters, perinephric space, retroduodenal space, and root of the mesentery was also readily accomplished as required for drainage. Each patient's treatment was individualized and the preoperative CT scan guided the intraoperative approach to pancreatic debridement.

Hand-assisted laparoscopic surgery has been shown to have a similar outcome as standard laparoscopic surgery with a shorter hospital stay, less pain and discomfort, earlier postoperative recovery, and earlier return to work compared with open surgery.[22-24] Hand-assisted laparoscopic surgery provides the option of performing complex intra-abdominal surgery by the minimal access route that would otherwise be limited because of the extreme complexity of the procedure and prolonged operating time.[22,25] The majority of patients with severe pancreatitis in a specialty referral practice are seen by pancreatic surgeons and not laparoscopic surgeons. Laparoscopic surgical techniques for pancreatic debridement would require a small learning curve for widespread acceptance. Our experiences suggest that hand-assisted laparoscopic debridement of pancreatic necrosis as described in this study is amenable to widespread application in the hands of pancreatic surgeons with good laparoscopic skills. In our hands, only 1 of 19 patients required conversion to an open procedure and the extent of debridement was similar to that during open surgery.

In patients with a severe acute pancreatitis, the attack appears to be initiated by activation of pancreatic enzymes, causing pancreatic autodigestion and a severe cytokine-mediated inflammatory response that often leads to SIRS, which is ultimately responsible for most of the morbidity and mortality in acute pancreatitis.[26-32] Elevated levels of inflammatory cytokines such as inter-

©2006 American Medical Association. All rights reserved.
Downloaded From: http://archsurg.jamanetwork.com/ on 08/28/2016

leukin 1, interleukin 6, and tumor necrosis factor α have been consistently demonstrated.[26-32] Trauma of open abdominal access has been also shown to trigger a deleterious intraperitoneal and a systemic cytokine-mediated immune response. It appears that this postsurgical response is related to the magnitude of the surgery and exposure of the peritoneal cavity to air and is markedly aggravated by the presence of peritonitis or multiple organ failure in patients undergoing open surgery.[33-36] Patients undergoing pancreatic debridement commonly develop a SIRS-like syndrome after the surgery. Although the deleterious role of cytokine release in severe acute pancreatitis and the associated SIRS is well documented, attenuation or aggravation of this cytokine response by surgical intervention for pancreatic debridement is poorly documented.

A surprising finding in our study was the absence of a significant SIRS-like response after laparoscopic debridement, including in patients with infected pancreatic necrotic tissue. A significantly reduced local peritoneal and systemic immune response has been demonstrated after laparoscopic compared with open surgery.[36-38] Furthermore, experimental studies have shown that peritoneal clearance of inoculated bacteria is more efficient after laparoscopy (when carbon dioxide is used to establish a pneumoperitoneum) then open laparotomy, suggesting that the peritoneal immunity is better preserved after minimally invasive surgery.[33-36] It is unclear whether these factors played a role in the observed responses in our patients after laparoscopic surgery. Future studies comparing the effect of open and laparoscopic surgery on cytokine inflammatory mediators and the SIRS response in patients with severe pancreatitis may answer this question.

The significant short- and long-term impact of severe pancreatitis has been documented.[4] The median duration of treatment in a community setting prior to referral to a tertiary center in our cohort of patients was 60 days with a range of 8 to 150 days. A third of the patients experienced multiple admissions for recurrent sepsis or intractable symptoms prior to referral to a tertiary center. The pendulum may have swung too far toward conservative management.[21] The need for treatment of patients with severe pancreatitis in a tertiary center equipped with a multidisciplinary team has been emphasized.[1] As new surgical and radiological technology develops, coordinated multidisciplinary care becomes even more important. Regionalization of complex liver and pancreatic procedures in experienced tertiary centers has been shown to improve outcomes.[39-41] The potential economic benefits and patient outcome improvements with regionalization of treatment of severe pancreatitis warrant further investigation.

Accepted for Publication: May 30, 2006.
Correspondence: Dilip Parekh, MD, 1510 San Pablo St, Los Angeles, CA 90033 (dparekh@surgery.usc.edu).
Previous Presentation: This paper was presented at the 77th Annual Meeting of the Pacific Coast Surgical Association; February 19, 2006; San Francisco, Calif; and is published after peer review and revision. The discussions that follow this article are based on the originally submitted manuscript and not the revised manuscript.

REFERENCES

1. Traverso LW, Kozarek RA. Pancreatic necrosectomy: definitions and technique. *J Gastrointest Surg*. 2005;9:436-439.
2. Ashley SW, Perez A, Pierce EA, et al. Necrotizing pancreatitis: contemporary analysis of 99 consecutive cases. *Ann Surg*. 2001;234:572-580.
3. Fernandez-del Castillo C, Rattner DW, Makary MA, Mostafavi A, McGrath D, Warshaw AL. Debridement and closed packing for the treatment of necrotizing pancreatitis. *Ann Surg*. 1998;228:676-684.
4. Connor S, Alexakis N, Raraty MGT, et al. Early and late complications after pancreatic necrosectomy. *Surgery*. 2005;137:499-505.
5. Carter R. Management of infected necrosis secondary to acute pancreatitis: a balanced role for minimal access techniques. *Pancreatology*. 2003;3:133-138.
6. Cuschieri A. Pancreatic necrosis: pathogenesis and endoscopic management. *Semin Laparosc Surg*. 2002;9:54-63.
7. Castellanos G, Serrano A, Pinero A, et al. Retroperitoneoscopy in the management of drained infected pancreatic necrosis. *Gastrointest Endosc*. 2001;53:514-515.
8. Hamad GG, Broderick TJ. Laparoscopic pancreatic necrosectomy. *J Laparoendosc Adv Surg Tech A*. 2000;10:115-118.
9. Horvath KD, Kao LS, Ali A, Wherry KL, Pellegrini CA, Sinanan MN. Laparoscopic assisted percutaneous drainage of infected pancreatic necrosis. *Surg Endosc*. 2001;15:677-682.
10. Horvath KD, Kao LS, Wherry KL, Pellegrini CA, Sinanan MN. A technique for laparoscopic-assisted percutaneous drainage of infected pancreatic necrosis and pancreatic abscess. *Surg Endosc*. 2001;15:1221-1225.
11. Connor S, Ghaneh P, Raraty M, et al. Minimally invasive retroperitoneal pancreatic necrosectomy. *Dig Surg*. 2003;20:270-277.
12. Connor S, Raraty MGT, Howes N, et al. Surgery in the treatment of acute pancreatitis: minimal access pancreatic necrosectomy. *Scand J Surg*. 2005;94:135-142.
13. Adamson GD, Cuschieri A. Multimedia article: laparoscopic infracolic necrosectomy for infected pancreatic necrosis. *Surg Endosc*. 2003;17:1675.
14. Baril NB, Ralls PW, Wren SM, et al. Does an infected peripancreatic fluid collection or abscess mandate operation? *Ann Surg*. 2000;231:361-367.
15. Lau ST, Simchuk EJ, Kozarek RA, Traverso LW. A pancreatic ductal leak should be sought to direct treatment in patients with acute pancreatitis. *Am J Surg*. 2001; 181:411-415.
16. Beger HG, Rau B, Isenmann R. Prevention of severe change in acute pancreatitis: prediction and prevention. *J Hepatobiliary Pancreat Surg*. 2001;8:140-147.
17. Buchler MW, Gloor B, Muller CA, Friess H, Seiler CA, Uhl W. Acute necrotizing pancreatitis: treatment strategy according to the status of infection. *Ann Surg*. 2000;232:619-626.
18. Clancy TE, Ashley SW. Current management of necrotizing pancreatitis. *Adv Surg*. 2002;36:103-121.
19. Connor S, Neoptolemos JP. Surgery for pancreatic necrosis: "whom, when and what." *World J Gastroenterol*. 2004;10:1697-1698.
20. Tzovaras G, Parks RW, Diamond T, Rowlands BJ. Early and long-term results of surgery for severe necrotising pancreatitis. *Dig Surg*. 2004;21:41-47.
21. Warshaw AL. Pancreatic necrosis: to debride or not to debride, that is the question. *Ann Surg*. 2000;232:627-629.
22. Targarona EM, Gracia E, Rodriguez M, et al. Hand-assisted laparoscopic surgery. *Arch Surg*. 2003;138:133-141.
23. Targarona EM, Gracia E, Garriga J, et al. Prospective randomized trial comparing conventional laparoscopic colectomy with hand-assisted laparoscopic colectomy: applicability, immediate clinical outcome, inflammatory response, and cost. *Surg Endosc*. 2002;16:234-239.
24. HALS Study Group. Hand-assisted laparoscopic surgery vs standard laparoscopic surgery for colorectal disease: a prospective randomized trial. *Surg Endosc*. 2000;14:896-901.
25. Cuschieri A. Laparoscopic hand-assisted surgery for hepatic and pancreatic disease. *Surg Endosc*. 2000;14:991-996.
26. Laveda R, Martinez J, Munoz C, et al. Different profile of cytokine synthesis according to the severity of acute pancreatitis. *World J Gastroenterol*. 2005;11: 5309-5313.
27. Lempinen M, Puolakkainen P, Kemppainen E. Clinical value of severity markers in acute pancreatitis. *Scand J Surg*. 2005;94:118-123.
28. Ramudo L, Manso MA, De Dios I. Biliary pancreatitis-associated ascitic fluid activates the production of tumor necrosis factor-alpha in acinar cells. *Crit Care Med*. 2005;33:143-148.
29. Papachristou GI, Whitcomb DC. Predictors of severity and necrosis in acute pancreatitis. *Gastroenterol Clin North Am*. 2004;33:871-890.
30. Pooran N, Indaram A, Singh P, Bank S. Cytokines (IL-6, IL-8, TNF): early and reliable predictors of severe acute pancreatitis. *J Clin Gastroenterol*. 2003; 37:263-266.
31. Dugernier TL, Laterre P-F, Wittebole X, et al. Compartmentalization of the inflammatory response during acute pancreatitis: correlation with local and systemic complications. *Am J Respir Crit Care Med*. 2003;168:148-157.
32. Raraty MGT, Neoptolemos JP. Compartments that cause the real damage in severe acute pancreatitis. *Am J Respir Crit Care Med*. 2003;168:141-142.
33. Kim WW, Jeon HM, Park SC, Lee SK, Chun SW, Kim EK. Comparison of immune preservation between CO2 pneumoperitoneum and gasless abdominal lift laparoscopy. *JSLS*. 2002;6:11-15.
34. West MA, Baker J, Bellingham J. Kinetics of decreased LPS-stimulated cytokine release by macrophages exposed to CO2. *J Surg Res*. 1996;63:269-274.

©2006 American Medical Association. All rights reserved.
Downloaded From: http://archsurg.jamanetwork.com/ on 08/28/2016

35. Wu FPK, Sietses C, von Blomberg BME, van Leeuwen PAM, Meijer S, Cuesta MA. Systemic and peritoneal inflammatory response after laparoscopic or conventional colon resection in cancer patients: a prospective, randomized trial. *Dis Colon Rectum*. 2003;46:147-155.
36. Zengin K, Taskin M, Sakoglu N, Salihoglu Z, Demiroluk S, Uzun H. Systemic inflammatory response after laparoscopic and open application of adjustable banding for morbidly obese patients. *Obes Surg*. 2002;12:276-279.
37. Kamei H, Yoshida S, Yamasaki K, Tajiri T, Shirouzu K. Carbon dioxide pneumoperitoneum reduces levels of TNF-a mRNA in the brain, liver, and peritoneum in mice. *Surg Endosc*. 2001;15:609-613.
38. Gupta A, Watson DI. Effect of laparoscopy on immune function. *Br J Surg*. 2001; 88:1296-1306.
39. Birkmeyer JD, Warshaw AL, Finlayson SR, Grove MR, Tosteson AN. Relationship between hospital volume and late survival after pancreaticoduodenectomy. *Surgery*. 1999;126:178-183.
40. Birkmeyer JD, Stukel TA, Siewers AE, Goodney PP, Wennberg DE, Lucas FL. Surgeon volume and operative mortality in the United States. *N Engl J Med*. 2003; 349:2117-2127.
41. Finlayson EVA, Goodney PP, Birkmeyer JD. Hospital volume and operative mortality in cancer surgery: a national study. *Arch Surg*. 2003;138:721-726.

DISCUSSION

L. William Traverso, MD, Seattle, Wash: First, a definition of pancreatic necrosis. Pancreatic necrosis is devitalized tissue, which can either be pancreatic parenchyma or peripancreatic tissue. In our experience, the "necrosum" is mostly peripancreatic. If a segment of the gland is necrotic, it is usually the central area of the gland. As the patient survives, the pancreas will be disconnected into 2 segments, the head and the tail: this is known as the disconnected gland syndrome and is usually associated with an external pancreatic fistula from the tail.

Now to the USC cases: in a 5-year period, 23 patients required pancreatic necrosectomy for necrotizing pancreatitis, or 4.6 patients per year. In 16 patients, the procedure was completed with a novel method, the laparoscopic hand-assisted technique as illustrated by the presentation.

The surgeries occurred a median of 65 days after the onset of pancreatitis, which means these patients were a setup for survival, having survived the early hemodynamic instability phase of this illness. They had thus entered the septic phase, which is the better time to undergo necrosectomy with the caveat, if it is clinically indicated. Almost all of the USC patients had been transferred to them. These middle-aged obese men were sick with an average ASA score of 3.4! Percutaneous drainage had been utilized in 78%. Organ failure has been experienced by 40%. The authors do not provide the etiology of the pancreatitis or the percent of the pancreas involved with necrosis. The indication in most was persistent sepsis or failure to improve with conservative support. The percent of the pancreas involved with necrosis has been related to mortality and is important to report when comparing treatments.

We have shown that the presence of a pancreatic ductal disruption, sometimes called a blow-out, is significantly associated with 3 items: pancreatic necrosis, length of stay, and mortality. Therefore, the presence and location of a disruption should be sought. The USC group documented a pancreatic fistula rate of 61% after the necrosectomy. This is a key item because the presence of pancreatic enzymes in the peripancreatic space drives the process of continued necrosis, infection, and uncontrolled sepsis. Necrosectomy alone is not enough: drainage must be maintained to prevent more necrosis. The key to avoiding mortality is to follow the rules of surgical drainage. If the patient is not tolerating the necrosis, then the surgeon must remove the necrosis or drain the pancreatic enzymes at the source of leakage, or both.

How well did the USC group accomplish this removal of necrosis and subsequent drainage of the evacuated space? Their 2½-hour, hand-assisted laparoscopic necrosectomy and drainage had an estimated blood loss of 350 mL and achieved a mortality rate of 12% with a LOS of 16 days, a commendable achievement for this pioneering effort. After open necrosectomy, the incidence of bowel fistula is high, but after the HAL technique, the incidence was zero.

Dr Parekh, what was your long-term occurrence of incisional hernia? How many of these patients had the disconnected gland syndrome, where the middle part of the gland is gone but the upstream pancreas remains viable and results in a permanent pancreatic fistula months after recovery? What was your long-term pancreatic fistula rate?

I agree with the manuscript that each patient's necrosectomy has to be customized using the CT scan as a map.

Why is the HAL technique appealing? Our primary treatment of clinically unstable patients with necrosis is percutaneous drainage. This has allowed us to avoid open necrosectomy in 85% of the patients with necrosis that were not clinically stable and would have required open necrosectomy and have a less than 10% mortality rate. However, this percutaneous drainage technique requires a huge team of interventional radiologists to maintain adequate drainage. CT scans and tube checks are required every 3 days. The LOS is long because time is required for the necrosis to liquefy and the necrosis cavities to shrink. In contrast, open surgery results in high rates of bowel fistula and incisional hernia while the drains are still necessary and have to be checked and exchanged in interventional radiology. The use of HAL represents a compromise, where necrosis is removed with a minimal invasive technique that retains the finger dissection so important in this procedure to avoid massive bleeding. HAL offers great visualization also. For these reasons, HAL is likely to truncate the length of hospitalization as Dr Parekh has shown.

HAL is not the only technique that has been successful. The first series using minimally invasive methods were from Clem Imrie's group in Glasgow using the working 2-channel nephroscope to help loosen and remove necrosis through already existing drain tracts placed by the interventional radiologist. Multiple sessions were required and a 20% mortality was observed in these clinically unstable ICU patients. Karen Horvath used an already existing drain tract but also a local cutdown to the retroperitoneum under the lateral costal margin to allow placement of a second instrument. This videoscopic-assisted retroperitoneal dissection (VARD) was successful in avoiding mortality altogether in small number of patients.

Sherry M. Wren, MD, Palo Alto, Calif: I have a few questions. First, what is the algorithm you are using to determine which patients require debridement? You did not present data about sterile vs infected necrosis in these patients: do you have it? What is your opinion of minimally invasive EGD pancreatic necrosectomy of the lesser sac through the stomach wall as demonstrated by the Germans?

Brett C. Sheppard, MD, Portland, Ore: I enjoyed your paper. I noticed that 2 of your complications I believe were line related and 1 was pneumonia. I also noted there seemed to be a fair amount of TPN used in your patients. I am wondering what your approach is to placing feeding jejunostomies at the time of this operation, and could that avoid some of these complications? Also, I would be interested in the outcome of the pancreatic fistulas.

Kimberly Kirkwood, MD, San Francisco, Calif: I also enjoyed this study and am planning to put it to use. You stressed the use of this technique late and conservative management early, and we agree. I think the data support your contention. There are, however, patients who present and require early surgery, and I am wondering if you have used the technique early? Some of those patients require reoperation. Have you tried going back in through the hand port?

Have you used argon beam coagulation in the retroperitoneum? We find it to be very useful laparoscopically.

William P. Schecter, MD, San Francisco: I have a question about the patients you operated on early vs late. You said there

©2006 American Medical Association. All rights reserved.
Downloaded From: http://archsurg.jamanetwork.com/ on 08/28/2016

were more complications if you operated earlier. My question is: did you compare the severity of illness between the patients operated on early and late? Maybe the patients who were operated on early were much sicker. You didn't mention the abdominal compartment syndrome in patients with pancreatitis. I have 2 patients in our ICU right now with open abdomens due to abdominal compartment syndrome. How do you see this problem in the overall management of these patients?

Dr Parekh: Thank you, Dr Traverso. I know that you came down specially to discuss this paper. We do not have the information on Balthazar's index and the percentage of necrosis. While Balthazar's index may be useful in identifying patients with acute pancreatitis who are likely to come to surgery, it has not been shown to be of any value in predicting outcomes in individual patients that have been operated on for severe pancreatitis; therefore, I'm unclear how information on the index would help with interpreting the data presented today. We did measure the weight of necrosis, however, and the necrosis amount in the 18 patients completed laparoscopically ranged from 20 to 200 g. The problem with this is that we are measuring wet weight, so we really don't know what the true dry weight is. Second, a large portion of the necrotic material that is removed is peripancreatic necrosis and not pancreatic necrosis, and so it is difficult to extrapolate what the actual amount of pancreatic necrosis is based on weight of the necrosis.

Eleven of the 14 patients developed a pancreatic fistula after the surgery. You have previously published that patients that are managed with aggressive, conservative management (as the majority of the patients in our study were) that eventually come to surgery usually have an underlying ductal injury, and I think that this study supports that observation. Of those 11 patients with a postoperative pancreatic fistula, 1 patient subsequently came to a surgery for a distal pancreatectomy; in the other 10 patients, the fistulae healed over time. The fistulae took weeks and sometimes months to heal, so the postoperative fistula is a difficult long-term morbidity in this group of patients. Postoperative pancreatic fistulae in patients who survive are probably a reflection of the severity of the underlying pancreatic necrosis, and its development is probably unrelated to and not influenced by any procedure that we do.

The median blood loss was shown on 1 of the slides. The median blood loss in the 18 patients that were successfully completed laparoscopically was 0 (0-8). Twelve patients did not require any blood transfusion. There were 2 patients who were outliers; 1 required a 4-unit transfusion, and the second patient required an 8-unit transfusion. Our data show that this procedure can be accomplished bloodlessly.

We are aware that your institution has emphasized aggressive percutaneous drainage. I think that within the context of a protocol, aggressive percutaneous drainage is a reasonable thing to study. We have several concerns with extended attempts at conservative treatment with multiple pigtail drains. Fifteen of the 18 patients in our study were referred to us after they had percutaneous drainage done on multiple occasions in outside facilities. Many of the patients in our study came to us late with multiple episodes of severe sepsis and repeated hospitalizations. The underlying reason why these patients remain sick, particularly the patients that are not tolerating a diet or continue to have septic episodes, is because of the persistence of necrosis in the retroperitoneum. Twelve to 16 French pigtail drains do not remove the necrosis and do lead to a prolonged period of illness. I think that removing the necrosis surgically is critical to resolution of their illness after a reasonable period of conservative treatment. It leads to a rapid recovery as shown in our study. The reason for the delay in surgery is because there is a perception that surgery is associated with bad outcomes, and so the patients tend to be referred late. When we looked at our data, more than half of our patients had 3 outside admissions prior to treatment at USC.

As we have discussed in the manuscript and you have noted in your discussion, other approaches have been described for minimal access surgery. The retroperitoneal approach is currently the one with most published experience. The published experience with retroperitoneal approaches show that multiple procedures are often required to completely debride the necrotic area due to a very limited exposure and difficulty with instrumentation in removing all the necrotic area with a single surgical procedure. Issues such as cost-effectiveness, prolongation of the illness, and extended hospitalizations have not been adequately addressed with this approach. Our experience has shown that clearing the retroperitoneum of all the necrotic material is critical to a rapid recovery, and therefore we feel a transperitoneal approach as described in this study is preferred to the retroperitoneal approaches. Minimal access approach similar to that reported in this study has been described previously in small studies. As you have noted, this is the largest report with a detailed report of the outcomes to our knowledge.

With regard to Dr Wren's question on sterile and infected necrosis, I think the paradigm has changed. The Atlanta classification defines distinct categories of sterile necrosis, infected necrosis, and pancreatic abscess. Today we are seeing a patient population that has gone through a period of conservative treatment with multiple attempts at interventional radiology, and as we found out in our study, the majority, 11 patients, had infection of the necrosis at the time of surgery. I am not sure if the implications of finding infected necrosis at surgery are the same in patients with prior radiological drainage as that in patients without any interventional procedures. So I am not really sure how relevant the classification of sterile and infected necrosis is in patients with preoperative radiological drainage since most patients with preoperative drainage will have bacterial contamination of necrosis, and therefore, in most of them you are going to culture bugs out in surgically debrided tissue.

We strongly disfavor transgastric drainage of pancreatic necrosis. We have seen 2 patients with attempted cystogastrostomies for pancreatic necrosis, who were very, very sick with prolonged periods of hospitalization. The transgastric approach is a dangerous approach and should not be practiced because of continuous contamination of the retroperitoneum with contaminated gastric content, particularly if the necrotic material is all not removed, as is usually the case due to inadequate access and difficulties with instrumentation with presently described techniques.

We put 4 feeding tubes in the study, and we are now routinely putting them in. I think the comment that jejunostomy feeding tubes may avoid the postoperative TPN is a valid one. Seven patients were operated on between 2 and 5 weeks and the rest later. I think if you look at the literature, most surgeons today would not operate on patients with pancreatic necrosis within the first 2 weeks because the necrosis has not separated or demarcated and it is difficult to do an adequate necrosectomy in that period. You can probably operate on most patients after about 2 weeks. There is a strong move to delayed treatment as discussed in our manuscript. We performed 4 reoperations as I showed in our presentation. The first 2 were done during the early part of our experience, and these were done open. The latter 2 reoperations were performed laparoscopically.

We have not used the argon beam, and we have not looked at the severity of illness in patients that were operated in the early phase within the first 5 weeks vs later.

©2006 American Medical Association. All rights reserved.
Downloaded From: http://archsurg.jamanetwork.com/ on 08/28/2016