Image of the Month

John A. Stauffer, MD; Jillian M. Bray, MD; Raouf E. Nakhleh, MD; Steven P. Bowers, MD

A 79-YEAR-OLD MAN WAS REFERRED BY HIS dermatologist for diffuse subcutaneous nodules that had been present for more than 1 year. These nodules were painful, ruborous, and erythematous and had overlying epithelial exfoliation (**Figure 1**). The patient noticed the nodules initially on only his lower extremities but at presentation noted them on his torso and upper extremities. Biopsy specimens of these lesions revealed superficial perivascular lymphocytic inflammation and interstitial dermatitis consistent with pancreatic panniculitis. His medical history was significant for hypertension, coronary artery disease, prostate cancer, melanoma, and arthritic joint pains. Family history included a brother with cancer of the pancreas. The physical examination was otherwise unrevealing.

Computed tomographic imaging of the abdomen revealed a 9-cm heterogenous mass arising from the tail of the pancreas (**Figure 2**). Laboratory investigation revealed a lipase level of 13 008 U/L (to convert to microkatals per liter, multiply by 0.0167) (reference range, 7-60 U/L), gastrin level of 32 pg/mL (to convert to picomoles per liter, multiply by 0.481) (reference range, 0-99 pg/mL), and glucagon level of 0.331 pg/mL (to convert to nanogram per liter, multiply by 1) (reference range, 0-0.08 pg/mL). Liver function test results and carcinoembryonic antigen and cancer antigen 19-9 levels were normal.

The patient underwent laparotomy, which demonstrated a large, well-circumscribed, solid mass in the tail of the pancreas measuring 9.0 × 7.5 × 6.5 cm. There was no evidence of surrounding organ involvement. The mass was removed in its entirety along with the spleen. Pathologic gross examination revealed a lobulated, focally necrotic–appearing mass. Microscopic examination showed cells arranged in a trabecular pattern with abundant basophilic cytoplasm and large nuclei with prominent nucleoli. Immunostaining was strongly positive for periodic acid–Schiff and trypsin and weakly positive for synaptophysin.

What Is the Diagnosis?

A. Pancreatic adenocarcinoma
B. Pancreatitis
C. Acinar cell carcinoma
D. Glucagonoma

Author Affiliations: Departments of Surgery (Drs Stauffer, Bray, and Bowers) and Pathology (Dr Nakhleh), Mayo Clinic, Jacksonville, Florida.

Figure 1. Photograph of a lower extremity subcutaneous nodule.

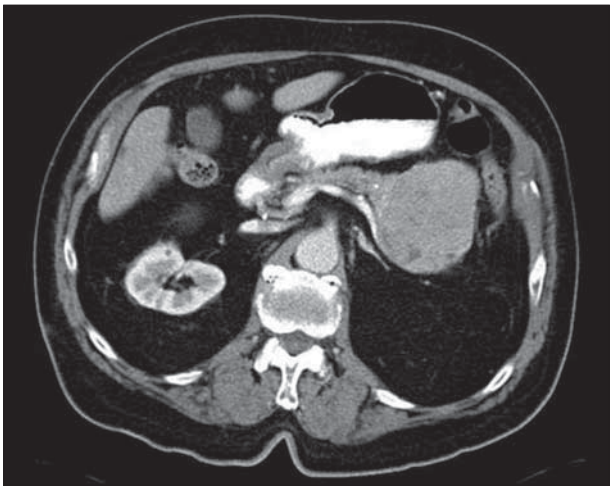

Figure 2. Computed tomographic image of the abdomen.

©2011 American Medical Association. All rights reserved.
Downloaded From: http://archsurg.jamanetwork.com/ on 04/25/2015