Answer

Internal Hernia Through the Left Hepatic Triangular Ligament

A laparotomy was performed and showed an internal hernia through the left hepatic triangular ligament with small-bowel strangulation (**Figure 2**). Because of ileum necrosis, intestinal resection with side-to-side anastomosis was performed. The patient's postoperative course was uneventful.

Internal hernia is a rare condition that occurs in no more than 2% of cases of small-bowel occlusion.[1] The main causes of peritoneal or mesenteric defects are congenital in young patients and traumatic or postoperative in adults.[2,3]

An anatomic classification of spontaneous internal hernia was recently reported by Gomes and Rodrigues.[4] The most frequent sites for internal hernia were paraduodenal (53%), paracecal (13%), transmesenteric (8%), and through the Winslow foramen (8%).[4] The incidence of internal hernia through the left hepatic triangular ligament is particularly hard to estimate. To the best of our knowledge, only 1 previous case has been reported in the literature.[5]

An explanation for this internal hernia could be that our patient has partial left-diaphragmatic palsy with ascension of the left diaphragm, which could have led to stretching of the left triangular ligament.

The diagnosis of an internal hernia through the left hepatic triangular ligament is challenging but may be aided by abdominal computed tomography.[6] The diagnosis is frequently made only during surgical exploration, which, to reduce morbidity and mortality, should not be delayed.

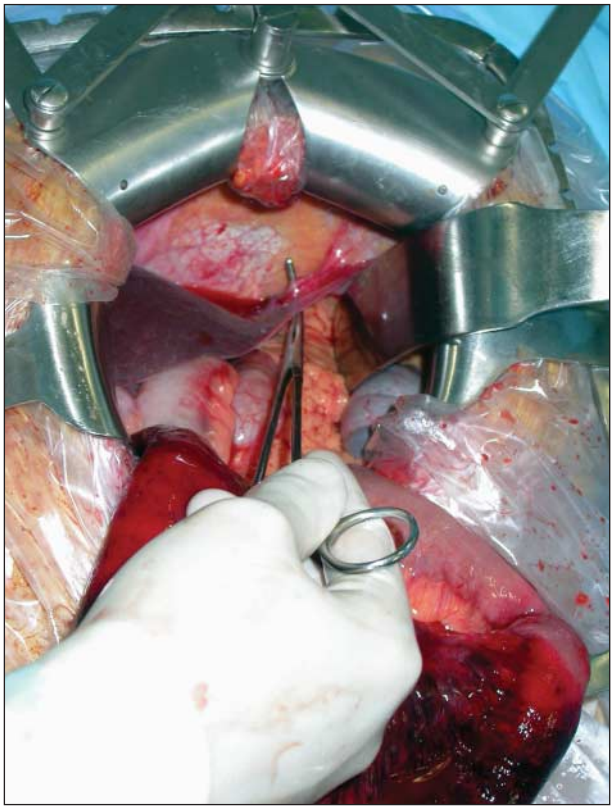

Figure 2. Perioperative view showing the defect in the left hepatic triangular ligament after removal of the incarcerated small bowel.

Accepted for Publication: June 13, 2010.
Correspondence: Jean Lubrano, MD, Department of Digestive Surgery and Liver Transplantation, Besançon University Hospital Jean Minjoz, 3, Blvd Fleming, 25000-Besançon, France (ghjuvanlubrano@hotmail.com).
Author Contributions: *Study concept and design:* Lubrano and Mantion. *Acquisition of data:* Delabrousse, Paquette, and Idelcadi. *Analysis and interpretation of data:* Lubrano. *Drafting of the manuscript:* Lubrano, Paquette, and Idelcadi. *Critical revision of the manuscript for important intellectual content:* Delabrousse and Mantion. *Administrative, technical, and material support:* Delabrousse. *Study supervision:* Lubrano and Mantion. *Performance of the surgical procedure:* Paquette and Idelcadi.
Financial Disclosure: None reported.

REFERENCES

1. Newsom BD, Kukora JS. Congenital and acquired internal hernias: unusual causes of small bowel obstruction. *Am J Surg.* 1986;152(3):279-285.
2. Ghahremani GG. Internal abdominal hernias. *Surg Clin North Am.* 1984;64(2):393-406.
3. Mock CJ, Mock HE Jr. Strangulated internal hernia associated with trauma. *AMA Arch Surg.* 1958;77(6):881-886.
4. Gomes R, Rodrigues J. Spontaneous adult transmesentric hernia with bowel gangrene. *Hernia.* 2011;15(3):343-345.
5. Peixoto HS, de Queiroz FN. Strangulation of an internal hernia in the triangular ligament: apropos of a case [in Portuguese] *Hospital (Rio J).* 1969;76(4):1405-1409.
6. Blachar A, Federle MP, Brancatelli G, Peterson MS, Oliver JH III, Li W. Radiologist performance in the diagnosis of internal hernia by using specific CT findings with emphasis on transmesenteric hernia. *Radiology.* 2001;221(2):422-428.

Submissions

The Editor welcomes contributions to the Image of the Month. Manuscripts should be submitted via our online manuscript submission and review system (http://manuscripts.archsurg.com). Articles and photographs accepted will bear the contributor's name. Manuscript criteria and information are per the Instructions for Authors for Archives of Surgery (http://archsurg.ama-assn.org/misc/ifora.dtl). No abstract is needed, and the manuscript should be no more than 3 typewritten pages. There should be a brief introduction, 1 multiple-choice question with 4 possible answers, and the main text. No more than 2 photographs should be submitted. There is no charge for reproduction and printing of color illustrations.

©2011 American Medical Association. All rights reserved.
Downloaded From: http://archsurg.jamanetwork.com/ on 05/06/2015