# Answer

## *Tension Occult Pneumothorax*

Subsequent computed tomography revealed a large left-sided residual occult pneumothorax (OPTX) (**Figure 2**), an extrapleural left chest tube, and a grade II splenic laceration with active contrast extravasation. The patient underwent immediate replacement of his left chest tube, which was associated with a rush of air, normalization of airway pressures, and hemodynamic improvement. This was followed by removal of his spleen, which was found to be moderately bleeding.

Supine anteroposterior chest radiography is an insensitive test for diagnosing posttraumatic pneumothoraces.[1] Subsequent computed tomography often detects pneumothoraces that were not diagnosed on preceding radiography (OPTX).[1,2] As a result, up to 76% of all pneumothoraces may be occult to a supine anteroposterior chest radiograph.[3] Occult pneumothoraces typically collect anteromedially in the supine trauma patient and are similar in size to overt pneumothoraces.[4] Secondary OPTXs (residual OPTXs despite tube thoracostomy) are also not uncommon.[4] Complications associated with tube thoracostomy approximate 22% and often include extrapleural placement.[5]

A tension pneumothorax is one that results in respiratory distress (or difficulty ventilating) and/or hemodynamic instability. It is strongly associated with positive pressure ventilation and is caused by an injury to the lung, bronchi, or trachea that allows continuous unidirectional leakage of air into the pleural space with subsequent collapse of the lung.[6] This life-threatening condition is treated by emergent chest decompression and should always be considered when appropriate volume replacement fails to improve hemodynamics. In summary, this report of a tension OPTX displays the importance of (1) knowing the limitations of a supine anteroposterior screening chest radiograph in detecting anteromedial OPTXs, (2) ensuring subsequent tube thoracostomy is appropriately located within the pleural space, and (3) recognizing that in addition to respiratory failure, tension pneumothoraces may also result in hemodynamic deaths secondary to impeded venous return.

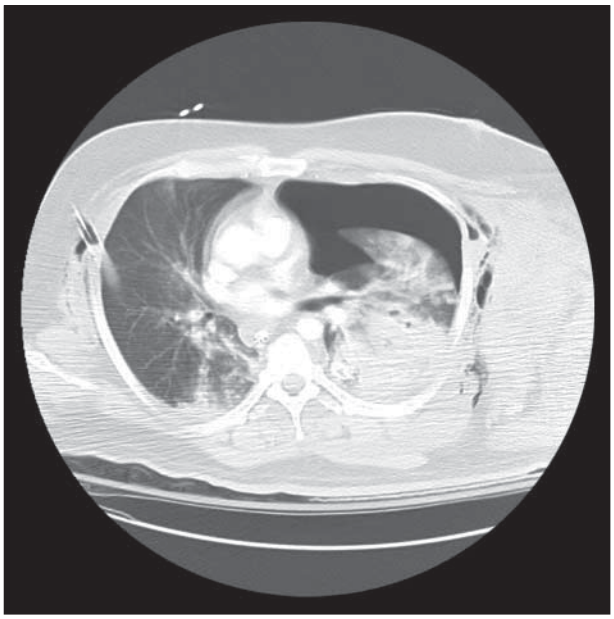

**Figure 2.** Computed tomographic image of a large residual tension occult pneumothorax with mediastinal shift to the right.

**Accepted for Publication:** September 13, 2010.
**Correspondence:** Chad G. Ball, MD, MSc, FRCSC, Foothills Medical Centre, 1403 29 St NW, Calgary, Alberta T2N 2T9, Canada (ball.chad@gmail.com).
**Author Contributions:** *Study concept and design:* Roberts and Ball. *Acquisition of data:* Roberts, Ball, and Tiruta. *Analysis and interpretation of data:* Roberts, Ball, and Kirkpatrick. *Drafting of the manuscript:* Roberts and Ball. *Critical revision of the manuscript for important intellectual content:* Roberts, Ball, Tiruta, and Kirkpatrick. *Statistical analysis:* Ball and Tiruta. *Obtained funding:* Ball. *Administrative, technical, and material support:* Roberts, Ball, and Kirkpatrick. *Study supervision:* Ball.
**Financial Disclosure:** None reported.

### REFERENCES

1. Ball CG, Kirkpatrick AW, Feliciano DV. The occult pneumothorax: what have we learned? *Can J Surg*. 2009;52(5):E173-E179.
2. Ball CG, Kirkpatrick AW, Laupland KB, et al. Incidence, risk factors, and outcomes for occult pneumothoraces in victims of major trauma. *J Trauma*. 2005; 59(4):917-925.
3. Ball CG, Ranson K, Dente CJ, et al. Clinical predictors of occult pneumothoraces in severely injured blunt polytrauma patients: a prospective observational study. *Injury*. 2009;40(1):44-47.
4. Ball CG, Kirkpatrick AW, Laupland KB, et al. Factors related to the failure of radiographic recognition of occult posttraumatic pneumothoraces. *Am J Surg*. 2005; 189(5):541-546.
5. Ball CG, Lord J, Laupland KB, et al. Chest tube complications: how well are we training our residents? *Can J Surg*. 2007;50(6):450-458.
6. Leigh-Smith S, Harris T. Tension pneumothorax: time for a re-think? *Emerg Med J*. 2005;22(1):8-16.

### *Submissions*

The Editor welcomes contributions to the Image of the Month. Manuscripts should be submitted via our online manuscript submission and review system (http://manuscripts.archsurg.com). Articles and photographs accepted will bear the contributor's name. Manuscript criteria and information are per the Instructions for Authors for Archives of Surgery (http://archsurg.ama-assn.org/misc/ifora.dtl). No abstract is needed, and the manuscript should be no more than 3 typewritten pages. There should be a brief introduction, 1 multiple-choice question with 4 possible answers, and the main text. No more than 2 photographs should be submitted. There is no charge for reproduction and printing of color illustrations.



©2011 American Medical Association. All rights reserved.
Downloaded From: http://archsurg.jamanetwork.com/ on 07/29/2016