

Image of the Month

Richard Bradbury, MBBS; Andreas L. Lambrianides, FRACS; Barry O'Loughlin, FRACS, FRCS; Sheyna Manawwar, MD

A 52-YEAR-OLD MAN PRESENTED TO THE emergency department with a history of acute left lower quadrant pain. On examination, he was normotensive and mildly tachycardic with a low-grade fever. He had a firm, distended abdomen with left lower quadrant tenderness. Computed tomography (CT) revealed diverticulitis and a large mass on the right side of the abdomen. This mass was further examined with magnetic resonance imaging (MRI) (**Figure 1**), which revealed that the mass displaced the kidney inferiorly, the liver superiorly, and the inferior vena cava and the second part of duodenum medially. After resolution of his

diverticulitis, a laparotomy was performed through a mid-line incision. The mass (**Figure 2**) was removed without complication, and the patient made a speedy recovery with early discharge.

What Is the Diagnosis?

- A. Teratoma
- B. Liposarcoma
- C. Adrenal myelolipoma
- D. Renal angiomyolipoma

Author Affiliations: Toowoomba Hospital, Toowoomba (Dr Bradbury), Redcliffe Hospital, Redcliffe (Dr Lambrianides), and Royal Brisbane and Women's Hospital, Brisbane (Drs O'Loughlin and Manawwar), Queensland, Australia.

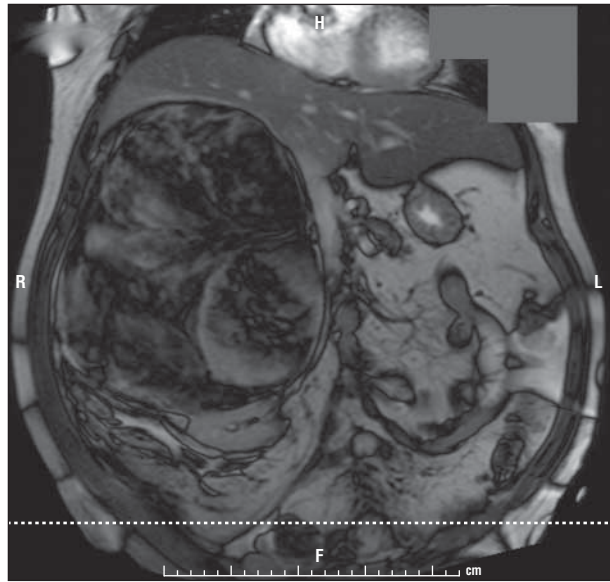


Figure 1. Sagittal section of a specimen showing a large, right-sided abdominal mass on magnetic resonance imaging.

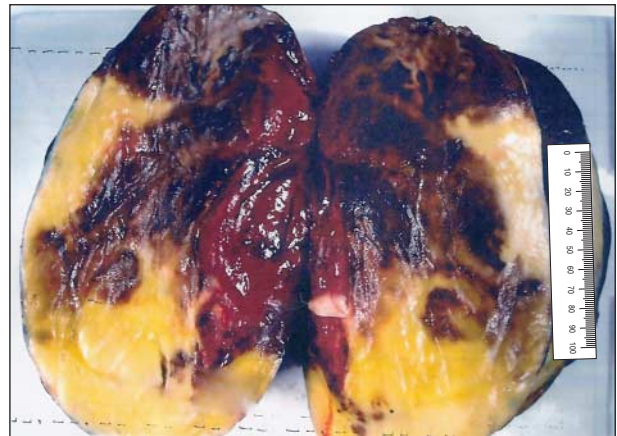


Figure 2. Section of a specimen of the mass.