ORIGINAL ARTICLE

Choledochal Cyst and Associated Malignant Tumors in Adults

A Multicenter Survey in South Korea

Seung Eun Lee, MD, PhD; Jin-Young Jang, MD, PhD; Young-Joo Lee, MD, PhD; Dong Wook Choi, MD, PhD; Woo Jung Lee, MD, PhD; Baik-Hwan Cho, MD, PhD; Sun-Whe Kim, MD, PhD; for the Korean Pancreas Surgery Club

Objective: To determine the clinical features and clinical outcomes of Korean adults treated surgically for choledochal cyst.

Design: Retrospective nationwide multicenter study.

Setting: Fifteen university hospitals (tertiary care referral centers) located in all 7 Korean provinces.

Patients: A total of 808 patients aged 18 years or older who underwent surgery for choledochal cyst from January 1, 1990, through December 31, 2007.

Main Outcome Measures: Demographic information, surgical data, associated biliary malignant tumors, and factors predicting malignant tumors.

Results: Type I was most common (499 [68.2%]) followed by type IVa (208 [28.4%]). Of 654 patients, anomalous pancreaticobiliary ductal union was identified in 467 patients (71.4%), 291 with the choledochal type (62.3%), 96 with the pancreatic type (20.6%), and 80 with the complex type (17.1%). Biliary tract malignant tumor was associated in 80 patients (9.9%); 40 had bile duct cancer (50.0%), 35 had gallbladder cancer (43.8%), 3 had periampullary cancer, and 2 had synchronous gallbladder and bile duct cancer. Twenty-two patients (26.3%) had a recurrence, with a median follow-up duration of 51.8 months. Factors predicting malignant tumor by univariate analysis were age more than 40 years, the absence of a gallstone, elevated carcinoembryonic antigen or cancer antigen 19-9 serum level, and the presence of anomalous pancreaticobiliary ductal union, and by multivariate analysis, an elevated cancer antigen 19-9 level.

Conclusions: Associated biliary malignant tumor should always be considered in patients with choledochal cyst, especially in aged patients or patients with anomalous pancreaticobiliary ductal union or an elevated tumor marker level. Lifelong follow-up is needed even after complete cyst excision because of the risk of the development of a metachronous biliary malignant tumor.

Arch Surg. 2011;146(10):1178-1184

Author Affiliations: Departments of Surgery, Chung-Ang University College of Medicine, Seoul (Dr S. E. Lee), Seoul National University College of Medicine, Seoul (Drs Jang and Kim), University of Ulsan College of Medicine, Ulsan (Dr Y.-J. Lee), Sungkyunkwan University School of Medicine, Seoul (Dr Choi), Yonsei University College of Medicine, Seoul (Dr W. J. Lee), and Chonbuk National University School of Medicine, Jeonju (Dr Cho), South Korea.
Group Information: The Korean Pancreas Surgery Club members are listed at the end of this article.

CHOLEDOCHAL CYST IS A relatively rare disease in the West, and thus most cases have originated from Asia. Furthermore, for unknown reasons, more than half of the reported cases have occurred in Japanese patients.[1] At least 60% of patients are diagnosed during the first decade of life, but 20% remain undiagnosed until adulthood.[1-7] Because of noninvasive hepatobiliary imaging improvements, adults with choledochal cyst are being increasingly encountered, and today up to 70% of all patients reported are adults.[8-12] Although a few world literature reviews[1-6] have been issued, to our knowledge, no nationwide data on adult patients have been reported in Japan or in other countries. Therefore, the Korean Pancreas Surgery Club undertook this nationwide multicenter study, which involved 15 university hospitals, to determine the clinicopathologic features and the long-term results of surgically treated adult patients with choledochal cyst.

METHODS

The design of this study was prepared by the scientific committee of the Korean Pancreas Surgery Club. A workshop was held on January 17, 2009, to approve the study design and to agree on a questionnaire. Subsequently, a nationwide survey was undertaken by 15 university hospitals (tertiary care referral centers) located in all 7 Korean provinces. Members of the Korean Pancreas Surgery Club were required to complete a questionnaire and a case registration form for each patient aged 18 years or older who underwent surgery for choledochal cyst from January 1, 1990, through December 31, 2007. Clinicopathologic findings and long-term follow-up results were ana-

©2011 American Medical Association. All rights reserved.
Downloaded From: http://archsurg.jamanetwork.com/ on 12/01/2015
Corrected on October 17, 2011

Table 1. APBDU Type by Todani Classification

Type	No. of Patients	Type of APBDU, No. (%) of That Type			Total No. (%) of Patients
		C-P	P-C	Complex	
Type I	499	204/330 (61.8)	76/330 (23.0)	50/330 (15.2)	330/499 (66.1)
Type II	7	1	0	0	1/7 (14.3)
Type III	4	0	0	0	0
Type IVa	208	86/135 (63.7)	20/135 (14.8)	29/135 (21.5)	135/208 (64.9)
Type IVb	9	0	0	1	1/9 (11.1)
Type V	5	0	0	0	0
Total		291/467 (62.3)	96/467 (20.6)	80/467 (17.1)	467/467 (100.0)

Abbreviations: APBDU, anomalous pancreaticobiliary ductal union; C-P, choledochal type; P-C, pancreatic type.

lyzed as determined by the Korean Pancreas Surgery Club. This retrospective study conformed to the ethical guidelines of the Declaration of Helsinki. The investigational review board or ethics committee at each institute approved the study.

Choledochal cyst was defined using the Todani-modified Alonso-Lej classification system.[4,7] Anomalous pancreaticobiliary ductal union (APBDU) was defined as a union of the common bile duct and pancreatic duct outside the duodenum, and the Japanese Study Group classification of pancreaticobiliary maljunction[13] was used to describe the junction type. Briefly, the choledochal (or right-angle) type involves the common bile duct joining the pancreatic duct, whereas the pancreatic (or acute-angle) type involves the pancreatic duct joining the choledochus. The complex type involves complicated union of the pancreaticobiliary ductal system.

Continuous data are expressed as mean (SD). Categorical variables were compared using the Pearson χ^2 test and continuous variables using the *t* test. A logistic regression model was used to identify factors predicting a coexistent biliary malignant cyst. All parameters with $P < .05$ by univariate analysis were included in the multivariate model. Survival was calculated using the Kaplan-Meier method, and the log-rank test was used to analyze differences. Statistical analyses were performed using SPSS, version 13.0 (SPSS Inc, Chicago, Illinois).

RESULTS

DEMOGRAPHIC CHARACTERISTICS AND CLINICAL PRESENTATION

Eight hundred eight patients were included in this study. Ulsan University Asan Medical Center enrolled 188 patients, Seoul National University Hospital enrolled 173, Yonsei University Severance Hospital enrolled 113, Samsung Medical Center enrolled 81, Chonbuk National University Hospital enrolled 62, and another 10 centers enrolled 191. The male to female ratio was 1:3.8, and the mean (SD) age of patients at diagnosis was 42 (14) years (range, 18-82 years). Abdominal pain was the most common presenting symptom (605 [74.9%]). However, 100 patients (100 [12.4%]) were asymptomatic, and no patient presented the classic triad of abdominal mass, jaundice, and pain. Eighty-seven patients (10.8%) had undergone prior biliary tract surgery. Fifty-three patients underwent cholecystectomy before receiving definitive treatment. Biliary lithiasis was observed in 225 patients (27.8%), and the most common site was the common bile duct. The bilirubin level was elevated in 173 patients (21.4%).

CYST TYPES AND APBDU

According to the Todani classification,[4,7] 499 patients (68.2%) had type I; 7 (0.9%) type II; 4 (0.5%) type III; 208 (28.4%) type IVa; 9 (1.2%) type IVb; and 5 (0.7%) type V. For the remaining 76 patients (9.4%), types could not be evaluated because of a lack of medical records. With regard to confluence between the terminal choledochus and the pancreatic duct, APBDU was present in 467 (71.4%) of 654 patients in whom the pancreaticobiliary ductal junction was visualized by endoscopic retrograde cholangiopancreatography or magnetic resonance cholangiopancreatography. The choledochal type was present in 291 patients (62.3%), pancreatic type in 96 (20.6%), and complex type in 80 (17.1%). **Table 1** shows patient proportions with respect to APBDU and the Todani classification. No significant difference between the prevalence of type I and that of type IVa was observed in those with and without APBDU or according to the types of APBDU.

SURGICAL OUTCOMES

Seven hundred forty-two patients (91.8%) underwent cyst excision, and 38 patients (4.7%) underwent only cystoenterostomy. Twenty-three patients underwent hepatectomy more than sectionectomy. Of these 23 patients, 17 had type IVa and 2 had type V; all 19 underwent hepatectomy because of associated intrahepatic complications, such as intrahepatic duct stone or parenchymal atrophy. Three patients underwent hepatectomy because of extension of bile duct cancer into the hilar bile duct and 1 patient because of advanced gallbladder cancer. One hundred four patients (12.9%) experienced a postoperative morbidity, and intra-abdominal abscess was the main complication (41 [39.4%]). Two patients died of sepsis within 1 month of surgery, an operative mortality rate of 0.2%.

BILIARY MALIGNANT TUMORS

Eighty patients (9.9%) presented with choledochal cyst associated with biliary malignant tumors. The male to female ratio of these 80 patients was 1:3.0, and their mean (SD) age at diagnosis was 50 (12) years (range, 21-82 years). The incidence of biliary malignant tumors was found to differ by age. Our data showed that the risk of a biliary malignant tumor increased from 1.3% in the

©2011 American Medical Association. All rights reserved.
Downloaded From: http://archsurg.jamanetwork.com/ on 12/01/2015
Corrected on October 17, 2011

Table 2. Operative Procedures Used to Treat a Choledochal Cyst With a Biliary Malignant Tumor

Operation	No. (%) of Patients				
	Total (N = 80)	BD (n = 40)	GB (n = 35)	Periampullary (n = 3)	GB+BD (n = 2)
Any	**78** (97.5)	39 (97.5)	35 (100)	2 (66.7)	2 (100.0)
CE and hepaticojejunostomy	**34**/78 (43.6)	25/39 (64.1)	9/35 (25.7)	0	0
CE and extended cholecystectomy	**22**/78 (28.2)	0	22/35 (62.9)	0	0
CE and hepatectomy[a]	**4**/78 (5.1)	3/39 (7.7)	1/35 (2.9)	0	0
Pancreatoduodenectomy	**11**/78 (14.1)	7/39 (17.9)	2/35 (5.7)	0	2/2 (100.0)
Cystoenterostomy	**2**/78 (2.6)	2/39 (5.1)	0	0	0
Open biopsy	**3**/78 (3.8)	2/39 (5.1)	1/35 (2.9)	0	0
Cholecystectomy and gastrojejunostomy	**1**/78 (1.3)	0	0	1/2 (50.0)	0
Gastrojejunostomy	**1**/78 (1.3)	0	0	1/2 (50.0)	0
Curative resection	**58**/78 (74.3)	25/39 (64.1)	32/35 (91.4)	0	1/2 (50.0)

Abbreviations: BD, bile duct; CE, cyst excision; GB, gallbladder.
[a] Right trisectionectomy (1 patient), right hepatectomy (2 patients), and right anterior sectionectomy (1 patient).

Table 3. Cases of Biliary Malignant Tumor Arising After Choledochal Cyst Surgery[a]

Patient No. /Sex/Age, y	Cyst Excision, Yes/No	Site	Time of Recurrence, mo	Stage	Treatment	Survival, mo
1/F/24	No, cystoduodenostomy	EHBD[b]	185	T1N0	Pancreatoduodenectomy	34
2/F/42	No, cystojejunostomy	EHBD	50	T3N0	Pancreatoduodenectomy	9
3/F/70	Yes	Pancreas head	25	cT4Nx	Chemotherapy	7
4/F/40	Yes	IHBD	53	cT4Nx	CCRT	6
5/F/22	Yes	EHBD[c]	240	T2N1	Bile duct resection	15
6/M/58	Yes	Duodenum	14	T4Nx	Palliative, gastrojejunostomy	11

Abbreviations: CCRT, concurrent chemoradiotherapy; EHBD, extrahepatic bile duct; IHBD, intrahepatic bile duct.
[a] All patients had type I, and all died.
[b] Cystoduodenostomy site.
[c] Mucinous carcinoma.

Table 4. Relationships Between Biliary Cancer Location and Choledochal Cyst and APBDU Types

Variable	No. (%)				
	Total	BD (n = 40)	GB (n = 35)	Periampullary (n = 3)	GB+BD (n = 2)
Todani type					
I	**57**/80 (71.3)	25/40 (62.5)	28/35 (80.0)	3/3 (100.0)	1/2 (50.0)
III	**1**/80 (1.3)	1/40 (2.5)	0	0	0
IVa	**18**/80 (22.5)	13/40 (32.5)	5/35 (14.3)	0	0
Unknown	**4**/80 (5.0)	1/40 (2.5)	2/35 (5.7)	0	1/2 (50.0)
APBDU					
Yes	**52**/80 (65.0)	24/40 (60.0)	26/35 (74.3)	1/3 (33.3)	1/2 (50.0)
C-P	**30**/52 (57.7)	15/24 (62.5)	14/26 (53.8)	1/3 (33.3)	0
P-C	**15**/52 (28.8)	5/24 (20.8)	9/26 (34.6)	0	1/1 (100.0)
Complex	**7**/52 (13.5)	4/24 (16.7)	3/26 (11.5)	0	0
No	**12**/80 (15.0)	9/40 (22.5)	2/35 (5.7)	1/3 (33.3)	0
Unknown	**16**/80 (20.0)	7/40 (17.5)	7/35 (20.0)	1/3 (33.3)	1/2 (50.0)

Abbreviations: APBDU, anomalous pancreaticobiliary ductal union; BD, bile duct; C-P, choledochal type; GB, gallbladder; P-C, pancreatic type.

group aged 21 to 30 years to 23.5% in the group aged 71 to 80 years.

LOCATION

Of the 80 patients with choledochal cyst associated with biliary malignant tumors, cancer of the extrahepatic bile duct was present in 39 (48.8%), cancer of the intrahepatic bile duct in 1 (1.3%), and cancer of the gallbladder in 35 (43.8%). Two patients had concurrent gallbladder and extrahepatic bile duct cancer. Of these 2 patients, one was a 54-year-old woman with a type Ia choledochal cyst and APBDU of the pancreatic type who underwent pancreatoduodenectomy. Results of the pathologic examination conducted after surgery showed that the gallbladder tumor was limited to the muscle layer

©2011 American Medical Association. All rights reserved.
Corrected on October 17, 2011
Downloaded From: http://archsurg.jamanetwork.com/ on 12/01/2015

Table 5. Stage of 80 Patients With a Malignant Tumor According to *AJCC* (7th Edition) Staging System

	No. (%)				
Stage	BD (n = 40)	GB (n = 35)	Periampullary (n = 3)	GB + BD (n = 2)	Total
CIS	2 (5.0)	3 (8.6)	0	0	**5** (6.3)
I	Ia 11 (27.5) Ib 5 (12.5)	7 (20.0)	0	0	**23** (23.8)
II	II a 4 (10.0) II b 9 (22.5)	9 (25.7)	0	1	**23** (28.8)
III	3 (7.5)	IIIa 4 (11.4) IIIb 5 (14.3)	0	1	**13** (16.3)
IV	5[a] (12.5)	IVa 1 (2.9) IVb 3[b] (8.6)	3[c]	0	**12** (15.0)
Unknown	1 (2.5)	3 (8.6)	0	**4** (5.0)	

Abbreviations: *AJCC, American Joint Committee on cancer*; BD, bile duct; CIS, carcinoma in situ; GB, gallbladder.
[a] Seeding (2 patients), liver meta (2 patients), and para-aortic lymph node meta (1 patient).
[b] Seeding (1 patient), liver meta (1 patient), and para-aortic lymph node meta (1 patient).
[c] Seeding (2 patients) and liver meta (1 patient).

(T1b), but that the extrahepatic bile duct tumor had invaded the pancreas (T3) and metastasized to the lymph nodes (N1). This patient remained alive for 43 months after surgery without evidence of recurrence. The other patient was a 62-year-old woman with a type Ia choledochal cyst and choledochal type APBDU. The Whipple operation was performed, and pathologic examination findings after surgery showed the gallbladder tumor had perforated serosa (T3) and that the extrahepatic bile duct tumor had invaded the pancreas (T3) and metastasized to the lymph nodes (N1). Eleven months after initial surgery, there was recurrence at the abdominal wall that extended to the transverse colon. Right hemicolectomy was performed, and the patient has been followed up for 10 months without any evidence of recurrence.

OPERATION

Surgery was performed on 78 of the 80 patients. The other 2 patients had an unresectable status at diagnosis and were treated by chemotherapy and concurrent chemoradiation therapy. Curative resection was performed in 58 of the 78 patients (74.4%). Details of the operations are provided in **Table 2**. Interestingly, significantly more patients with gallbladder cancer underwent curative resection than patients with bile duct cancer ($P = .004$).

METACHRONOUS CARCINOMA

Of the 80 patients with a malignant tumor, 74 were found to have a neoplasm at initial laparotomy. The other 6 (7.5%) developed metachronous carcinomas. The treatment and outcomes of these 6 patients with metachronous carcinomas are summarized in **Table 3**. Of the 38 patients who underwent cystoenterostomy and who were followed up, extrahepatic bile duct cancer occurred in 2 (5.3%), and of the 668 patients without a biliary malignant tumor who underwent cyst excision, biliary cancer developed in 4 (0.6%) during follow-up. Metachronous biliary malignant tumor occurred more frequently after cystoenterostomy than after cyst excision ($P = .03$). The median interval from initial operation to cancer development was 51.5 months.

TYPE OF CHOLEDOCHAL CYST AND LOCATION OF MALIGNANT TUMORS

Significantly more patients classified with type IVa had bile duct cancer and significantly more patients classified with type I had gallbladder cancer ($P = .03$) (**Table 4**). Furthermore, APBDU was more frequently associated with gallbladder cancer than with bile duct cancer ($P = .03$). No significant difference was observed between patients with bile duct cancer and those with gallbladder cancer in terms of APBDU type.

STAGE AND SURVIVAL

According to the *AJCC Cancer Staging Manual* (7th edition),[14] approximately 60% of all patients with biliary malignant tumor had stage I or II, and this was similar for patients with bile duct cancer or gallbladder cancer (**Table 5**). The overall 5-year survival rates of patients with bile duct cancer or gallbladder cancer were 39.9% and 61.2%, respectively (**Figure**, A). The 5-year survival rates of stage I and stage II bile duct cancer were 75.0% and 7.7%, respectively (Figure, B), and the 5-year survival rates of stage I, II, and III gallbladder cancer were 100%, 71.0%, and 44.4%, respectively (Figure, C). Median follow-up duration was 51.8 months, and recurrence developed in 22 patients (26.3%). Systematic recurrence (14 [61.9%]) was more common than local recurrence (**Table 6**).

COMPARISON OF PATIENTS WITH CHOLEDOCHAL CYST AND BILIARY MALIGNANT TUMOR WITH PATIENTS WITH CHOLECDOCHAL CYST ONLY

Univariate analysis showed that an age of more than 40 years ($P < .001$), the absence of cholelithiasis ($P = .09$), a preoperative serum carcinoembryonic antigen level greater

©2011 American Medical Association. All rights reserved.
Downloaded From: http://archsurg.jamanetwork.com/ on 12/01/2015
Corrected on October 17, 2011

than 0.05 ng/mL (to convert to micrograms per liter, multiply by 1.0) ($P = .01$), a preoperative serum cancer antigen 19-9 level greater than 37 U/L ($P < .001$), and the presence of APBDU ($P = .03$) were significantly associated with a choledochal cyst with a biliary malignant tumor. However, by multivariate analysis, a preoperative serum cancer antigen 19-9 level greater than 37 U/L ($P = .001$) was the only significant factor.

COMMENT

Choledochal cyst is a recognized surgical problem usually related to infancy and childhood. However, because of improvements in noninvasive hepatobiliary imaging, adult patients are being increasingly encountered, and the number of series conducted recently on children and adults confirms this trend.[11,12,15,16] However, this is likely to be an apparent increase due to the popularity of routine check-ups and imaging improvements. Adult patients with a choledochal cyst raise 2 additional considerations, namely, the presence of an associated biliary malignant tumor and delayed complications, such as a biliary stone. However, in this study, the mean follow-up period of patients without a biliary malignant tumor was 39 months, which is too short to allow analysis of benign delayed complications after surgery. Therefore, we focused on biliary malignant tumors associated with choledochal cyst.

Table 6. Long-term Results of Patients With a Malignant Tumor[a]

Variable	Total (N = 80)[b]	BD Cancer (n = 40)	GB Cancer (n = 35)
Recurrence	**22** (27.5)	14 (35.0)	8 (22.9)
Locoregional recurrence	**8** (38.1)	7 (50.0)	1 (12.5)
Systemic recurrence	**14** (61.9)	7 (50.0)	7 (87.5)
Peritoneal seeding	**12** (84.6)	7 (100)	5 (71.4)
Liver metastasis	**2** (15.4)	0	2 (28.6)

Abbreviations: BD, bile duct; GB, gallbladder.
[a] Data are given as number (percentage) of patients. Median follow-up time is 20.9 months for the BD cancer group and 43.7 months for the GB cancer group.
[b] Five patients had periampullary cancer (n = 3) and GB+BD cancer (n = 2).

Reported incidences of cancer associated with a primary choledochal cyst range from 2.5%[17] to 26%.[17] However, most cases have been reported in Japan, and the incidence of such cancer in Japan,[19] according to the Japanese Study Group on Pancreaticobiliary Maljunction, is 16.2%, which was calculated from a population of patients with APBDU with or without a choledochal cyst. Accordingly, this incidence is higher than the incidence based on patients with a choledochal cyst only, because the incidence of cancer in patients with APBDU but without a choledochal cyst is much higher than that in patients with a cyst.

It is widely known that cholangiocarcinoma is the most common malignant tumor associated with choledochal cyst. Reviews of cases[1,18-20] have shown that 70% to 90% of patients had bile duct cancer, whereas in our cohort, only 44% of patients had gallbladder cancer. Recently, a Japanese nationwide survey[13] reported that 34% of patients with a choledochal cyst have bile duct cancer and that 65% have gallbladder cancer. However, Japanese data on choledochal cyst were based on patients with APBDU. Therefore, the incidence of gallbladder cancer is much higher than previously reported[1,18-20] because most patients with APBDU are known to have gallbladder cancer.

Development of biliary malignant tumor after cyst excision is uncommon. A literature review[21,22] revealed 33 reported cases, and of these, 16 (47.1%) were type IVa and 9 (26.5%) were type I. The most common site of involvement was the hepatic duct at or near choledochoenteric anastomosis (13 [38.2%]), followed by the intrahepatic duct (11 [32.4%]) and distal choledochus (7 [20.6%]), and the mean (SD) time between cyst excision and cancer detection was 9.0 (5.5) years (range, 1-19 years). In the present study, the incidence of cancer development after cyst excision was 0.6%. Although the incidence of cancer after cyst excision was higher than that of biliary cancer in the general population, it was much lower than that of cancer in patients with a primary choledochal cyst (9.9%), which indicates that complete cyst excision effectively reduces malignant transformation in

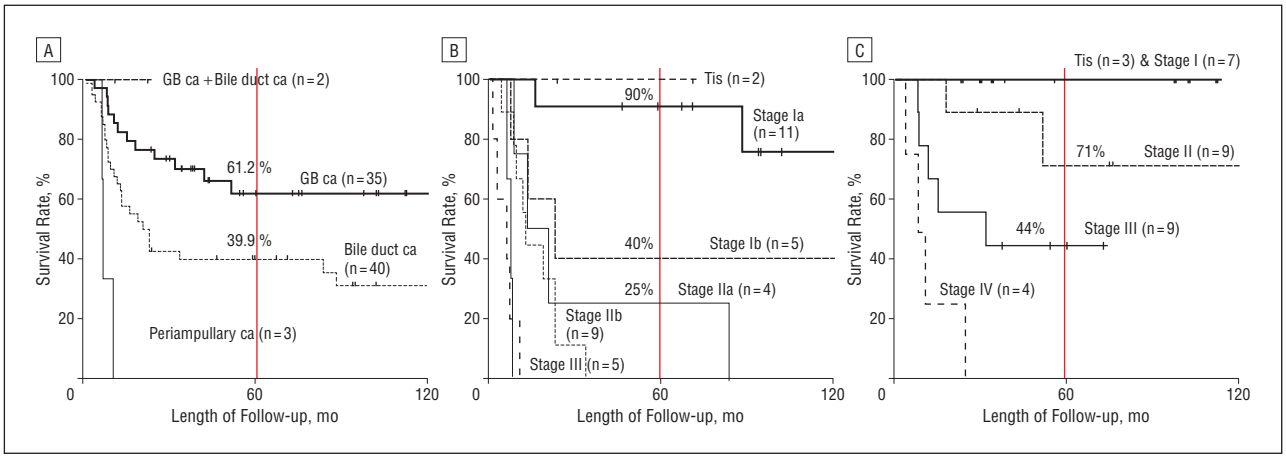

Figure. Comparison of survival according to tumor location and American Joint Committee on cancer (AJCC) stage. A, Survival curves of patients with a malignant tumor by tumor location. B, Survival curves of patients with bile duct cancer (ca) by *AJCC* (7th edition)[14] stage. C, Survival curves of patients with gallbladder (GB) cancer by *AJCC* (7th edition) stage.

©2011 American Medical Association. All rights reserved.
Corrected on October 17, 2011
Downloaded From: http://archsurg.jamanetwork.com/ on 12/01/2015

the biliary tree. However, lifelong follow-up is required even after complete cyst excision.

The prognosis for patients with cholangiocarcinoma arising from a choledochal cyst is as grim as for cholangiocarcinoma in general,[23-25] with a reported median survival of 6 to 21 months.[8,17,26] The reason for this poor prognosis is believed to be a resectability rate of less than 10%.[27] However, in the present study, approximately 60% of patients were classified as stage I or II, and 70% of patients underwent curative resection. As a result, the 5-year survival rates of patients with cholangiocarcinoma arising from a choledochal cyst in stage Ia, Ib, and IIa bile duct cancer were 90.4%, 40.0%, and 25.1%, respectively, and this was comparable with that of patients with cholangiocarcinoma in general. However, palliative resection was performed for 4 of the 9 patients in stage IIb, and these 4 plus the other 2 patients with T3 experienced early recurrence less than 12 months after operation. For this reason, the patients in stage IIb had poor survival. Although little is known about the prognosis for patients with gallbladder cancer arising from a choledochal cyst, as in cholangiocarcinoma, it is thought to be similar to that of patients with primary gallbladder cancer.

We summarize the results of our nationwide multicenter survey as follows. Todani type I (68.2%) and IVa (28.4%) were the 2 most common types, APBDU was present in 71.4% of patients, and the choledochal type (62.3%) was most common. Biliary malignant tumor was detected in 80 patients (9.9%). Forty patients (50.0%) had bile duct cancer and 35 (43.8%) had gallbladder cancer. Six patients (7.5%) had metachronous carcinoma, after cystenterostomy in 2 and after cyst excision in 4. Curative resection was possible in 58 patients (74.4%). The overall 5-year survival rate of patients with gallbladder cancer was 61.2% and that of patients with bile duct cancer was 39.9%. Factors predicting malignant tumors by univariate analysis were an age of more than 40 years, the absence of a gallstone, elevated carcinoembryonic antigen and cancer antigen 19-9 serum levels, and the presence of APBDU. However, only an elevated serum cancer antigen 19-9 level predicted the development or the presence of a malignant tumor by multivariate analysis.

In conclusion, an associated biliary malignant tumor should always be considered in patients with a choledochal cyst, particularly when patients are elderly or have APBDU or elevated tumor markers. Lifelong follow-up is needed, even after complete cyst excision, because of the risk of development of a metachronous biliary malignant tumor.

Accepted for Publication: March 21, 2011.
Correspondence: Sun-Whe Kim, MD, PhD, Department of Surgery, Seoul National University College of Medicine, 28 Yeongeon-dong, Jongno-gu, Seoul, 110-744, South Korea (sunkim@plaza.snu.ac.kr).
Author Contributions: Drs S. E. Lee and Jang contributed equally in this work. Drs S.E. Lee and Jang had full access to all the data in the study and take responsibility for the integrity of the data and the accuracy of the data analysis. *Study concept and design:* S.E. Lee, Jang, Y.-J. Lee, Choi, W.J. Lee, Cho, and Kim. *Acquisition of data:* S.E. Lee, Y.-J. Lee, Choi, W.J. Lee, and Cho. *Analysis and interpretation of data:* S.E. Lee, Jang, and Kim. *Drafting of the manuscript:* S.E. Lee, Jang, Y.-J. Lee, W.J. Lee, and Kim. *Critical revision of the manuscript for important intellectual content:* S.E. Lee, Jang, Choi, Cho, and Kim. *Statistical analysis:* S.E. Lee, and Y.-J. Lee. *Obtained funding:* Choi. *Administrative, technical, and material support:* S.E. Lee, Jang, Y.-J. Lee, Choi, W.J. Lee, Cho, and Kim. *Study supervision:* Jang, Y.-J. Lee, Choi, W.J. Lee, Cho, and Kim.
Financial Disclosure: None reported.
Korean Pancreas Surgy Club Members: Myung-Wook Kim, MD, PhD, Wook Hwan Kim, MD, PhD, and Jae-Myung Lee, MD, PhD, University Medical Center; Hee Cheol Yu, MD, PhD, Chonbuk National University Hospital; Hyun-Jong Kim, MD, PhD, Chol Kyoon Cho, MD, PhD, and Yang Seok Koh, MD, PhD, Chonnam National University Hospital; In-Sang Song, MD, PhD, Chungnam National University Hospital; Yong-Hoon Kim, MD, PhD, and Koo Jeong Kang, MD, PhD, Keimyung University Dongsan Hospital; Sang Gul Kim, MD, PhD, Kyungpook National University Hospital; Seong-Ho Choi, MD, PhD, and Jin Seok Heo, MD, PhD, Samsung Medical Center; Eun Jung Kim, MD, PhD, Ho-Seong Han, MD, PhD, Yoo-Seok Yoon, MD, PhD, and Jai Young Cho, MD, PhD, Seoul National University Bundang Hospital; Hyung Chul Kim, MD, PhD, and Jun-Chul Chung, MD, PhD, SoonChunHyang University Bucheon Hospital; Hong-Jin Kim, MD, PhD, and Sung-Soo Yun, MD, PhD, Yeungnam University Medical Center; and Chang-Moo Kang, MD, PhD, Dong-Sup Yoon, MD, PhD, and Joon Seong Park, MD, PhD, Yonsei University Kangnam Severance Hospital.

REFERENCES

1. Yamaguchi M. Congenital choledochal cyst: analysis of 1,433 patients in the Japanese literature. *Am J Surg.* 1980;140(5):653-657.
2. Shallow TA, Eger SA, Wagner FB. Congenital cystic dilatation of the common bile duct: case report and review of literature. *Ann Surg.* 1943;117(3):355-386.
3. Tsardakas E, Robnett AH. Congenital cystic dilatation of the common bile duct; report of three cases, analysis of fifty-seven cases, and review of the literature. *AMA Arch Surg.* 1956;72(2):311-327.
4. Alonso-Lej F, Rever WB Jr, Pessagno DJ. Congenital choledochal cyst, with a report of 2, and an analysis of 94, cases. *Int Abstr Surg.* 1959;108(1):1-30.
5. Shimura H, Hatae K, Nakamura Y. Congenital choledochal cyst: report of 8 cases and analysis of 131 cases in Japanese literature. *Surg Ther (Tokyo).* 1962; 7:483-487.
6. Kobayashi Y, Onoda K, Yoshishita T, et al. Congenital choledochal cyst; report 4 cases and analysis of 224 cases in Japanese literature. *Geka (Tokyo).* 1966; 28:272-276.
7. Todani T, Watanabe Y, Narusue M, Tabuchi K, Okajima K. Congenital bile duct cysts: classification, operative procedures, and review of thirty-seven cases including cancer arising from choledochal cyst. *Am J Surg.* 1977;134(2):263-269.
8. Liu CL, Fan ST, Lo CM, Lam CM, Poon RT, Wong J. Choledochal cysts in adults. *Arch Surg.* 2002;137(4):465-468.
9. Lenriot JP, Gigot JF, Ségol P, Fagniez PL, Fingerhut A, Adloff M; French Associations for Surgical Research. Bile duct cysts in adults: a multi-institutional retrospective study. *Ann Surg.* 1998;228(2):159-166.
10. Hewitt PM, Krige JE, Bornman PC, Terblanche J. Choledochal cysts in adults. *Br J Surg.* 1995;82(3):382-385.
11. Lipsett PA, Pitt HA, Colombani PM, Boitnott JK, Cameron JL. Choledochal cyst disease: a changing pattern of presentation. *Ann Surg.* 1994;220(5):644-652.
12. Nicholl M, Pitt HA, Wolf P, et al. Choledochal cysts in Western adults: complexities compared to children. *J Gastrointest Surg.* 2004;8(3):245-252.
13. Tashiro S, Imaizumi T, Ohkawa H, et al; Committee for Registration of the Japanese Study Group on Pancreaticobiliary Maljunction. Pancreaticobiliary maljunc-

©2011 American Medical Association. All rights reserved.
Corrected on October 17, 2011
Downloaded From: http://archsurg.jamanetwork.com/ on 12/01/2015

tion: retrospective and nationwide survey in Japan. *J Hepatobiliary Pancreat Surg*. 2003;10(5):345-351.
14. Edge SB, Byrd DR, Compton CC, eds, et al. *AJCC Cancer Staging Manual.* 7th ed. New York, NY: Springer; 2010.
15. Jordan PH Jr, Goss JA Jr, Rosenberg WR, Woods KL. Some considerations for management of choledochal cysts. *Am J Surg*. 2004;187(6):790-795.
16. Naga MI, Suleiman DN. Endoscopic management of choledochal cyst. *Gastrointest Endosc*. 2004;59(3):427-432.
17. Stain SC, Guthrie CR, Yellin AE, Donovan AJ. Choledochal cyst in the adult. *Ann Surg*. 1995;222(2):128-133.
18. Fieber SS, Nance FC. Choledochal cyst and neoplasm: a comprehensive review of 106 cases and presentation of two original cases. *Am Surg*. 1997;63(11): 982-987.
19. Tadokoro H, Yamaguchi M, Kozawa H, et al. Congenital choledochal cyst: analysis of 466 adult patients in Japanese literature [in Japanese]. *Nippon Rinsho GekaGgakkai Zasshi*. 1980;41:96-103.
20. Komi N, Tamura T, Miyoshi Y, Kunitomo K, Udaka H, Takehara H. Nationwide survey of cases of choledochal cyst: analysis of coexistent anomalies, complications and surgical treatment in 645 cases. *Surg Gastroenterol*. 1984;3(2): 69-73.
21. Watanabe Y, Toki A, Todani T. Bile duct cancer developed after cyst excision for choledochal cyst. *J Hepatobiliary Pancreat Surg*. 1999;6(3):207-212.
22. Ng WT. Bile duct carcinogenesis after excision of extrahepatic bile ducts in pancreaticobiliary maljunction. *Surgery*. 2000;128(3):492-494.
23. Lazaridis KN, Gores GJ. Cholangiocarcinoma. *Gastroenterology*. 2005;128(6):1655-1667.
24. Yalcin S. Diagnosis and management of cholangiocarcinomas: a comprehensive review. *Hepatogastroenterology*. 2004;51(55):43-50.
25. de Groen PC, Gores GJ, LaRusso NF, Gunderson LL, Nagorney DM. Biliary tract cancers. *N Engl J Med*. 1999;341(18):1368-1378.
26. Jan YY, Chen HM, Chen MF. Malignancy in choledochal cysts. *Hepatogastroenterology*. 2000;47(32):337-340.
27. Flanigan DP. Biliary carcinoma associated with biliary cysts. *Cancer*. 1977;40(2): 880-883.

Correction

Error in Byline. In the "In reply" by Stepaniak et al, published in the July 2011 issue of the *Archives* (2011;146[7]: 886-887), an author's name was misspelled in the byline. Guus Vries, PhD, should be spelled Guus de Vries, PhD.

©2011 American Medical Association. All rights reserved.
Downloaded From: http://archsurg.jamanetwork.com/ on 12/01/2015
Corrected on October 17, 2011