Image of the Month

Jennifer Hartwell, MD; Antonio Gangemi, MD; Steven Salzman, DO

A 51-YEAR-OLD MAN PRESENTED TO THE EMERgency department after experiencing a near syncopal episode and diaphoresis while riding the train home from work. He was seen by his primary care physician in an outpatient setting and was found to be orthostatic and sent immediately to the emergency department. On arrival at the emergency department, he was found to have a blood pressure of 92/62 mm Hg and heart rate of 112 beats per minute. His respiratory rate was 16 breaths per minute; pulse oximetry, 100% with room air; and temperature, 97.9°F. He was immediately given 2 liters of crystalloid intravenous fluids, and repeated blood pressure was 110/78 mm Hg. He had abdominal pain, primarily in the left upper quadrant, and felt light-headed and fatigued. He described that the pain had started the night before. He specifically denied chest pain, shortness of breath, cough, fevers, weight loss, diarrhea, or any other recent illness. He was otherwise in good health and reported no current medications or previous surgeries. He denied smoking, alcohol, or illicit drug use. He had no allergies. He did note a recent injury about 3 months prior in which he was involved in a sledding accident and was admitted to our institution for a grade 3 splenic injury noted on a computed tomographic (CT) scan. He successfully completed a period of observation with stable findings on physical examination and hemodynamic stability throughout his hospital course and was discharged home after 2 days without requiring surgery for the injury. At the current visit, physical examination revealed a calm and cooperative gentleman. His lungs were clear bilaterally and heart examination revealed tachycardia with regular rhythm. His abdomen was soft, not distended, and had mild pain on palpation of the left upper quadrant but no evidence of peritonitis. His extremities were warm, without edema, and he had palpable pulses in all 4 extremities.

Laboratory values were as follows: white blood cell count, $19.5 \times 10^3/\mu L$; hemoglobin level, 12.9 g/dL (to convert to grams per liter, multiply by 10.0); hematocrit, 38.5; platelet count, 203; and international normalized ratio, 1.1. After initial resuscitation in the emergency department, a chest x-ray was obtained, identifying a small left pleural effusion, but was otherwise negative. A CT scan of the chest, abdomen, and pelvis was completed (**Figure 1**).

Author Affiliations: Advocate Christ Medical Center, Oak Lawn, Illinois; and University of Illinois at Chicago, Chicago, Illinois.

What Is the Diagnosis?

A. Late-onset traumatic chylothorax
B. Splenic rupture
C. Left-sided pneumonia with reactive pleural effusion
D. Splenic infarction

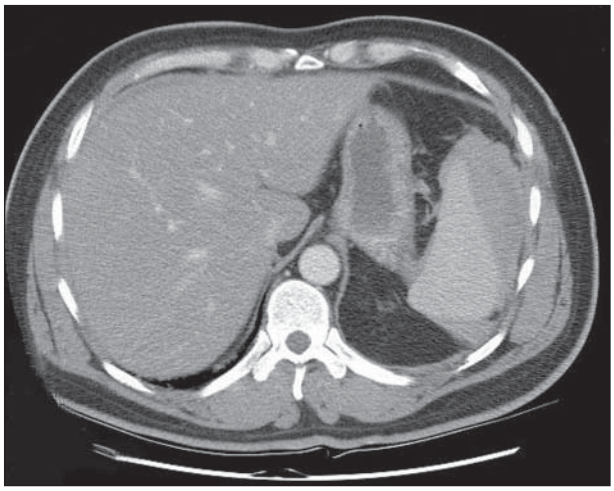

Figure 1. Computed tomography of the abdomen demonstrating splenic hematoma.

©2011 American Medical Association. All rights reserved.
Downloaded From: http://archsurg.jamanetwork.com/ on 08/27/2014

Answer

Delayed Splenic Rupture

The CT scan identified a significant amount of blood in the pelvis and acute hemorrhage from the spleen as well as the previously noted small left pleural effusion seen on chest x-ray. Based on the patient's history of prior splenic trauma, his acute presentation of hypotension, and the CT scan showing splenic hemorrhage, we immediately took the patient to the operating room for exploratory laparotomy and splenectomy. In the operating room, we discovered a significant amount of blood that had pooled in the pelvis and active bleeding from the splenic parenchyma (**Figure 2**). Hilar control was obtained and a splenectomy performed. The patient required transfusion of 4 units of packed red blood cells. He was observed in the intensive care unit overnight and was transferred to the trauma surgical floor the following morning. He received *Haemophilus influenza,* meningococcal, and pneumococcal vaccines prior to discharge.

On further questioning of the patient after the surgery, we discovered that the night prior to visiting the emergency department, the patient had been playing a series of sports games including tennis, baseball, and golf on the gaming console Wii (Nintendo, Redmond, Washington).

Newer gaming consoles require players to manipulate images on the screen not only with the use of a handheld controller but also with body movements. While several reports of musculoskeletal injuries[1,2] have been reported with the use of these gaming consoles, only a few reports[3,4] have been made of more severe or life-threatening injuries. Here, we present a case of a 51-year-old man who had a delayed splenic hemorrhage temporally related to the use of the gaming console Wii.

The spleen is the most commonly injured organ among blunt abdominal trauma cases across all age groups, occurring in as many as 25% of admissions for blunt trauma per year in level I trauma centers.[5] There is consensus that the advent of CT imaging has made conservative management of traumatic splenic injuries safer. However, our patient underwent successful conservative management for his original splenic injury only to bleed from a subcapsular hematoma after vigorous exercise several months later.

Traditionally, we advise patients to avoid contact sports for 2 to 6 months after splenic injury. This recommendation is based on experimental evidence that the spleen recovers its normal strength about 6 to 8 weeks after injury.[6] But the advent of this new generation of video game systems such as the Nintendo Wii that encourages users to be wholly physically involved in the game raises concerns about how we should advise patients who complete nonoperative management of splenic injuries. Specifically, our patient played a game on the Wii that required him to simulate the swinging motions of a tennis racquet, baseball bat, and golf club. These large and forceful movements presumably induced the splenic hematoma to rupture. Patients should be advised of the warning symptoms such as dizziness or abdominal pain that could herald bleeding from the healing spleen, and they should immediately seek medical care. Perhaps we should advise patients that any strenuous activity can place them at risk for bleeding after their initial injury.

Figure 2. Intraoperative photograph showing ruptured splenic hematoma.

Accepted for Publication: March 16, 2010.
Correspondence: Jennifer Hartwell, MD, Department of Surgery, University of Illinois at Chicago, 840 S Wood St, Ste 376-N CSN, Chicago, IL 60612 (hartwell.jennifer@gmail.com).
Author Contributions: *Study concept and design:* Hartwell and Salzman. *Analysis and interpretation of data:* Gangemi and Salzman. *Drafting of the manuscript:* Hartwell, Gangemi, and Salzman. *Critical revision of the manuscript for important intellectual content:* Hartwell, Gangemi, and Salzman. *Administrative, technical, and material support:* Hartwell and Salzman. *Study supervision:* Gangemi and Salzman.
Financial Disclosure: None reported.

REFERENCES

1. Harrison M. No Wii cause for concern. *Emerg Med J.* 2009;26(2):150.
2. Robinson RJ, Barron DA, Grainger AJ, Venkatesh R. Wii knee. *Emerg Radiol.* 2008; 15(4):255-257.
3. Peek AC, Ibrahim T, Abunasra H, Waller D, Natarajan R. White-out from a Wii: traumatic haemothorax sustained playing Nintendo Wii. *Ann R Coll Surg Engl.* 2008; 90(6):W9-10.
4. Wells JJ. An 8-year-old girl presented to the ER after accidentally being hit by a Wii remote control swung by her brother. *J Trauma.* 2008;65(5):1203.
5. Bjerke HS, Geibel J. Splenic rupture. Medscape Reference Web site. http://emedicine.medscape.com/article/432823-overview. Updated August 6, 2009. Accessed September 23, 2009.
6. Feliciano D, Mattox K, Moore E. *Trauma.* 6th ed. New York, NY: McGraw-Hill; 2007.

©2011 American Medical Association. All rights reserved.
Downloaded From: http://archsurg.jamanetwork.com/ on 08/27/2014