ORIGINAL ARTICLE

# Retroperitoneal Approach and Endoscopic Management of Peripancreatic Necrosis Collections

*Luc P. Gambiez, MD; Franck A. Denimal, MD; Henri L. Porte, MD; Alain Saudemont, MD; Jean-Pierre M. Chambon, MD; Pierre A. Quandalle, MD*

**Objective:** To review the results of the different modalities of treatment of acute necrotizing pancreatitis that have been used by a single team during a 6-year period to assess the technique and indications of an endoscopic method of retroperitoneal drainage that is routinely performed for the management of peripancreatic necrosis.

**Design and Setting:** Retrospective study of 53 patients in a tertiary care center.

**Results:** All patients had signs of peripancreatic necrosis on initial computed tomography scan, 20 patients experienced organ failure during the first 7 days of the disease, and bacterial contamination was proved in 22 (56%) of 39 samples of peripancreatic necrosis. Methods of treatment included supportive therapy alone (group 1), percutaneous drainage (group 2), endoscopic retroperitoneal drainage (group 3), and laparotomy and transperitoneal drainage (group 4). Mortality and mean hospital stay were as follows: group 1, 0% and 23 days; group 2, 20% and 89 days; group 3, 10% and 62 days; and group 4, 33% and 86 days. Percutaneous drainage was beneficial in only 3 cases of sterile collection. Two local complications were related to the method of endoscopic drainage. Primary laparotomy was not routinely performed except in patients with an intraperitoneal complication. Overall mortality was 13.2%; mortality was significantly higher in patients with an infected necrosis (32%).

**Conclusions:** The use of endoscopic retroperitoneal drainage seemed to be a significant factor in the observed improvement by providing a reliable drainage of the peripancreatic areas and avoiding the opening of the peritoneal cavity. This surgical approach is not exclusive and may be combined with a secondary laparotomy when needed. The preferred indications of this method are heterogeneous collections of necrosis with bacterial contamination.

*Arch Surg. 1998;133:66-72*

DESPITE NOTABLE progress during the past decade, acute necrotizing pancreatitis (ANP) still causes high mortality, ranging from 15% to 45% in recent reports.[1-4] Except for the forms showing massive necrosis of the gland, which have a fulminant course from the beginning and are invariably lethal, the main risk and prognostic factor is the secondary infection of peripancreatic necrosis, provoking general sepsis and/or local complications.[5-7] Therefore, the first management problem is to determine the bacterial contamination of the necrosis, this being aided by the use of computed tomography (CT)–guided fine-needle aspiration (FNA).[8] The second problem is to achieve a good débridement and drainage of the peripancreatic infected necrosis for which a large panel of surgical methods is currently proposed.[9,10] We have developed an endoscopic technique of débridement of peripancreatic fatty tissue necrosis that is based on a lumbar retroperitoneal approach. We have been using this technique in selected cases among a larger population of patients with ANP who otherwise had been treated by conventional methods. We reviewed the results of this method of retroperitoneal drainage and assessed its indications. Similarly, the clinical features and outcomes were analyzed for the patients who were managed with other techniques. We attempted to identify the elements of selection for each therapeutic method.

*From the Clinique Chirurgicale Ouest, Hôpital Claude Huriez, Centre Hospitalier Regional Universitaire, Lille, France.*

*This article is also available on our Web site: www.ama-assn.org/surgery.*



©1998 American Medical Association. All rights reserved.
Downloaded From: http://archsurg.jamanetwork.com/ on 06/01/2016

## PATIENTS AND METHODS

### POPULATION

From January 1, 1990, to December 31, 1995, 53 patients with ANP were admitted to our institution (35 men and 18 women); the patient age ranged from 25 to 91 years (mean, 49 years). Twenty-five patients were transferred from another hospital to our intensive care unit because of the severity of their disease. The day of onset of the disease was designated day 0 and was recorded on admission to the hospital.

The causes of ANP were identified as follows: alcohol (24 patients), gallstones (17 patients), and miscellaneous (12 patients). The severity of the disease was assessed by the Ranson criteria score.[11] There were fewer than 3 criteria in 11 patients, 3 to 5 criteria in 31 patients, and more than 5 criteria in 11 patients (mean value for our global population, 3.3). The presence of peripancreatic necrosis was routinely evaluated by contrast-enhanced CT scan on admission to the hospital, the extent of peripancreatic necrosis being assessed by the Ranson and Balthazar grading system[12]: grade D (1 collection), 16 patients; grade E (>1 collection), 37 patients. The possible necrosis of the pancreatic gland was also evaluated as absent (n=34), one third of the pancreas (n=13), or more than one third (n=6). During the first 6 weeks, a CT scan was performed every 7 days to evaluate the morphologic changes of the collections and to detect the outbreak of gas in the peripancreatic area. The contrast medium bolus injection was omitted in patients with a risk of renal failure. Microbiologic examinations were made in patients with septic signs as follows: blood cell cultures (n=44), FNA of the collections (n=13), and intraoperative samples of necrosis (n=36).

### CLINICAL MANAGEMENT AND PATIENT SELECTION FOR DRAINAGE OR SURGICAL PROCEDURE(S)

All patients initially were hospitalized in the intensive care unit to ensure nasogastric suction, total parenteral nutrition, and cardiac monitoring. Intravenous antibioprophylaxy was systematically instituted provided that patients had evidence of necrosis on CT scan, the duration of ANP was less than 7 days, and no other antibiotherapy regimen had been previously prescribed (in another institution). Thirty-six patients met these criteria. The different drugs (cefotaxime sodium, ceftazidime, cefuroxime sodium, and imipenem) were used in monotherapy. During the first 7 days we also used mechanical ventilation (n=15), hemodialysis (n=10), vasopressive or inotropic drugs (n=13), and peritoneal dialysis (n=4). A laparotomy was performed only to check the possibility of an intraperitoneal complication such as gut perforation, digestive necrosis, or hemoperitoneum.

The criteria for a drainage procedure were the secondary outbreak or persistence (>7 days) of signs of sepsis unexplained by a source of infection other than an abdominal abcess; and/or organ failure despite medical treatment; and/or bacteriological proof of infection (blood cell cultures and FNA). Percutaneous drainage (PD) was reserved to collections predominantly liquid on CT scan (low density and homogeneous); lumboscopic drainage was proposed to patients having heterogeneous collections and/or rapid enlargement on 2 successive examinations and/or outbreak of gas in the peripancreatic area.

The patients could be retrospectively divided in 4 groups, depending on the methods of treatment: supportive therapy alone (group 1, n=14), percutaneous drainage (group 2, n=10), endoscopic retroperitoneal drainage (group 3, n=20), and laparotomy plus transperitoneal drainage (group 4, n=9).

A feeding jejunostomy was performed in 47 patients using a conventional (n=35) or a laparoscopic (n=12) technique. One or several biliary procedures were needed in 23 patients: endoscopic retrograde cholangiopancreatography and endoscopic sphincterotomy alone (n=4), endoscopic retrograde cholangiopancreatography combined with endoscopic sphincterotomy and cholecystectomy (n=8), cholecystectomy alone (n=6), and cholecystectomy and T tube (n=5).

### METHOD OF ENDOSCOPIC RETROPERITONEAL DRAINAGE

The retroperitoneal approach to the pancreas was routinely conducted through a short lumbotomy (6 cm in length) centered on the 12th rib. The spleen and the descending colon were then mobilized anteriorly without opening the peritoneum, which provided direct access to the pancreas. Considering the depth of the operating field, we used a direct vision endoscope (23-cm mediastinoscope), which allowed a satisfactory exploration of the anterior pararenal space and prepancreatic area. For patients having collections in the right mesocolon and the right pararenal space, a similar right lumbotomy was used and the retropancreatic area was reached after mobilizing the ascending colon. The necrotic peripancreatic tissues and collections were removed by blunt dissection using a suction metal tube that also is equipped for electrocoagulation. After débridement, a tube drain allowing continuous irrigation was left in the retroperitoneal space and the wound was left open and packed to facilitate the subsequent procedures. The semilateral position of the patient allowed an abdominal extension of the incision in case of bleeding and feeding jejunostomy during the same operation.

The lumboscopic drainage was repeated under general anesthesia every 5 days until definitive elimination of all debris. Then a simple irrigation and lavage could be performed daily without anesthesia.

### MAIN OUTCOME AND STATISTICAL ANALYSIS

General or local complications were encountered, and reoperations or complementary procedures were done. The main outcome criteria in each group of patients were the mortality and the mean stay in our department from admission to the hospital to final release. Data were analyzed using the Fisher exact or the Wilcoxon test. Statistical significance was inferred for $P<.05$. Data are given as mean±SD.

## RESULTS

### GROUP 1

Fourteen patients did not meet the criteria for percutaneous or surgical drainage and were treated exclusively by medical therapy. These were less severe cases (**Table 1**). None of these patients underwent FNA. Two early complications were encountered: 1 *Staphylococcus aureus* septicemia and 1 transient and mild renal failure with no need for hemodialysis. A spontaneous resolution was observed in all of the cases without mortality. The mean hospital-



©1998 American Medical Association. All rights reserved.
Downloaded From: http://archsurg.jamanetwork.com/ on 06/01/2016

**Table 1. Preoperative Clinical and Radiological Features**

| Patient Group, Procedure | Mean Age, y* | Mean Ranson Criteria Score† | Computed Tomographic Grade‡ | Clinical Features§ |
|---|---|---|---|---|
| 1, No drainage (n=14) | 48 | 2.7 | 8 D, 6 E | No uncontrolled sepsis, no organ failure |
| 2, Primary percutaneous drainage (n=10) | 45 | 3.4 | 5 D, 5 E | Uncontrolled sepsis (all), respiratory failure (n=1), renal failure (n=1), multiorgan failure (n=3) |
| 3, Primary lumboscopic drainage (n=20) | 51 | 3.4 | 1 D, 19 E | Uncontrolled sepsis (all), respiratory failure (n=5), renal failure (n=3), multiorgan failure (n=2) |
| 4, Primary laparotomy (n=9) | 53 | 3.8 | 2 D, 7 E | Uncontrolled sepsis (all), respiratory failure (n=1), multiorgan failure (n=4) |

*P>.05 between the 4 groups.
†P>.05 between the 4 groups.
‡P<.01 between group 3 and groups 2 and 4. D indicates 1 collection of peripancreatic necrosis; E, more than 1 collection of peripancreatic necrosis.
§P<.01 between group 1 and groups 2, 3, and 4 for organ failure proportion; no difference between groups 2, 3, and 4.

ization stay was 23±9 days in this group ($P<.05$ vs groups 2, 3, and 4). One patient acquired diabetes as a definitive sequel.

## GROUP 2

In 10 patients, a PD was proposed after FNA. The preoperative clinical features of these patients are given in Table 1. The PD was performed between day 10 and day 25 (mean, day 17). One or 2 drain tubes were used, ranging in size from 5 to 10 mm. The mean duration of PD was 16 days (range, 4-22 days). The bacteriological features of these initial samples and the further events are given in **Table 2**. The patients who had a sterile collection underwent drainage because of the persistence of a large collection after day 20. The mean hospital stay was 89±24 days for the entire population of PD. There were 3 late pseudocysts persisting more than 6 weeks; 2 resolved within 3 months without specific treatment and 1 required a late PD. Two patients remained diabetic; 1 had to be reoperated on for a late hernia on the lumbotomy wound.

## GROUP 3

All patients had signs of uncontrolled sepsis before the lumboscopic drainage (Table 1). Three patients had previous proof of infection of a heterogeneous collection (FNA). Four patients had a positive blood cell culture for gram-negative rods. The other patients had indirect signs of infected necrosis on CT scan: presence of gas into the collection (n=4) and/or rapid enlargement of the collection in 2 successive examinations (n=7). The first lumboscopy procedure was performed between day 13 and day 26 (mean, day 18). A bacterial infection was observed on the intraoperative samples of the first lumboscopic procedure in 13 patients (Table 2). In the other 7 patients, the initial sample was sterile and a secondary superinfection occurred in 3 patients but may correspond to a contamination through the open wound. The mean number of lumboscopic procedures performed under general anesthesia was 5±4. Local complications occurred in 6 patients during the early postoperative phase (up to 4 weeks after the first lumboscopic drainage) (Table 2). Two of these complications (colonic fistula and splenic bleeding) obviously were caused by the technique of surgical drainage; the 4 other complications were more likely related to the location and severity of the pancreatitis (cephalic necrosis) and/or the persistence of an inflammatory process. In complement, a short laparotomy was needed in 2 patients to drain a persisting collection of the mesenteric root. A late complication (>6 weeks) occurred in 6 patients: 2 pseudocysts—1 treated by PD and 1 resolved spontaneously; 2 external pancreatic fistulas healed spontaneously without specific treatment; and 2 wound hernias on the lumbotomy required reoperation. Three patients remained diabetic. Mortality was 10% in this group. The mean hospital stay was 62±21 days ($P<.05$ vs groups 2 and 4).

## GROUP 4

All of the patients had signs of severe sepsis before the laparotomy with a suspected intraperitoneal complication (Table 1). The primary laparotomies were performed between day 4 and day 13. Two patients had a colonic perforation with peritonitis (1 death); 1 had a ruptured spleen with intraperitoneal hemorrhage. Two patients had a massive necrosis of the pancreatic gland (both patients died). The remaining 4 patients had no intraperitoneal complication but had multiple necrotic collections, with bacterial contamination in 2 patients. Bacteriological data and postoperative course are given in Table 2. Two late pseudocysts occurred and were treated by PD, 2 wound hernias required reoperation, and 3 patients remained diabetic. Mortality was 33% in this group ($P<.05$ vs group 1). The mean hospital stay was 86±32 days.

## MORTALITY

The overall mortality was 13.2% in this series. The average delay between the onset of the ANP and death was 47±44 days. Bacterial contamination was proved in 22 of 39 (56%) samples of peripancreatic necrosis. Mortality was significantly higher in patients having infected necrosis (7 of 22), compared with those with sterile collections (0 of 17) ($P<.05$).



©1998 American Medical Association. All rights reserved.
Downloaded From: http://archsurg.jamanetwork.com/ on 06/01/2016

**Table 2. Bacteriological Features and Postoperative Course**

| No. of Patients | Organisms Cultured (Primary Sample) | Further Course | Subsequent Procedure | Outcome |
|---|---|---|---|---|
| | | **Primary Percutaneous Drainage (Group 2)** | | |
| 1 | *Klebsiella* species | Persistent sepsis and colonic necrosis | Laparotomy, colectomy | Multiorgan failure, death |
| 1 | *Acinetobacter* species | Persistent sepsis and colonic perforation | Laparotomy, colectomy | Multiorgan failure, death |
| 1 | *Veillonella* species | Persistent sepsis | Lumboscopic drainage | Recovery |
| 3 | Sterile | Resolution | None | Recovery |
| 2 | Sterile | Superinfection | Lumboscopic drainage | Recovery |
| 2 | Sterile | Deterioration without bacterial evidence of superinfection | Lumboscopic drainage | Recovery |
| | | **Lumboscopic Drainage (Group 3)** | | |
| 1 | *Escherichia coli, Citrobacter* species | Resolution | Second-look lumboscopy | Recovery |
| 1 | *Proteus mirabilis* | Resolution | Second-look lumboscopy | Recovery |
| 1 | *Enterobacter* species | Resolution | Second-look lumboscopy | Recovery |
| 1 | Group D streptococcus | Resolution | Second-look lumboscopy | Recovery |
| 1 | *Bacteroides fragilis, Candida albicans* | Arterial bleeding and mesocolic collection | Embolization, 2 laparotomies | Recovery |
| 1 | *Pseudomonas* species | Resolution | Second-look lumboscopy | Recovery |
| 1 | *Enterobacter* species, group D streptococcus | Resolution | Second-look lumboscopy | Recovery |
| 1 | *Pseudomonas* species | Cephalic and bile duct necrosis | Laparotomy, T-tube drainage | Death |
| 1 | *B fragilis, Clostridium* species | Duodenocolic fistula and mesocolic collection | Laparotomy, drainage | Recovery |
| 1 | *E coli* | Colonic fistula | Colostomy | Recovery |
| 1 | *E coli* | Resolution | Second-look lumboscopy | Recovery |
| 1 | *Serratia* species, group D streptococcus | Splenic bleeding | Splenopancreatectomy | Death |
| 1 | *Veillonella* species | Resolution | Second-look lumboscopy | Recovery |
| 1 | Sterile | Arterial bleeding | Embolization and second-look lumboscopy | Recovery |
| 3 | Sterile | Superinfection | Second-look lumboscopy | Recovery |
| 3 | Sterile | Resolution | Second-look lumboscopy | Recovery |
| | | **Laparotomy (Group 4)** | | |
| 1 | *P mirabilis* | Multiorgan failure | None | Death |
| 1 | *Clostridium* species, *B fragilis, Klebsiella* species | Multiorgan failure | Second-look laparotomy, drainage | Death |
| 1 | *Acinetobacter* species, *Staphylococcus aureus,* group D streptococcus | Uncontrolled sepsis and persistent collection | Second-look laparotomy, drainage | Recovery |
| 1 | *S aureus* | Resolution | None | Recovery |
| 1 | *Acinetobacter* species, *Klebsiella* species | Multiorgan failure and persistent collection | Second-look laparotomy, drainage | Death |
| 1 | *Pseudomonas* species | Uncontrolled sepsis and arterial bleeding | Second-look laparotomy, packing | Recovery |
| 2 | Sterile | Persistent collection | Second-look laparotomy, drainage | Recovery |
| 1 | Sterile | Resolution | None | Recovery |

## COMMENT

Secondary infection of peripancreatic necrosis is regarded as the main prognostic factor of ANP.[5,6,13] The role of gram-negative bacteria originating from the gastrointestinal tract has been shown in humans and experimental models.[14-17] A major risk of bacterial contamination exists when a peripancreatic necrosis is present, depending on its extent and the duration of the disease.[18-20] Nevertheless, an exact prediction of a further infection is difficult in the early phase of the ANP. In our series, CT signs of peripancreatic necrosis were constant on admission to the hospital and were the basis for the inclusion of the patients in this study. However, retrospective analyses of patients' courses show significant differences between the study groups despite minimal variations of average Ranson criteria scores. Obviously, patients in group 1 had a relatively benign disease and were not candidates for aggressive therapeutic methods. Conversely, patients in group 4 had a more fulminant course and had more local complications than groups 2 and 3. Even though this retrospective grouping allows no comparison between the different results, it gives information about selection of the patients for each therapeutic modality.

Bacterial contamination may be suspected on clinical signs of sepsis and/or positive blood cell cultures, but



©1998 American Medical Association. All rights reserved.
Downloaded From: http://archsurg.jamanetwork.com/ on 06/01/2016

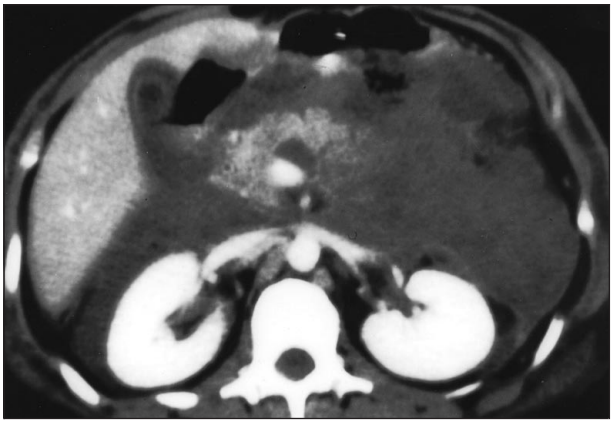

**Figure 1.** *Acute necrotizing pancreatitis with multiple collections of necrosis and uncontrolled sepsis, day 11. Patient underwent lumboscopic retroperitoneal drainage.*

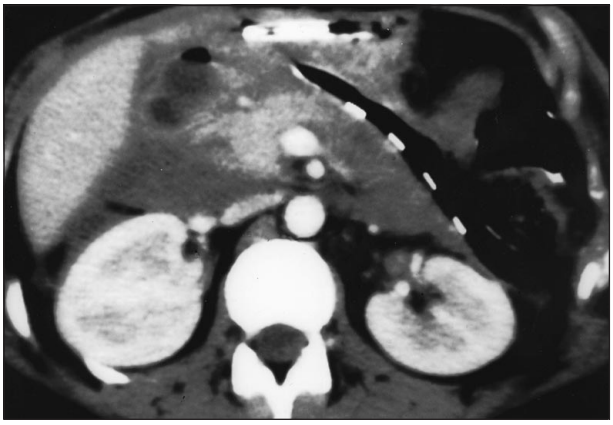

**Figure 2.** *Same patient as in Figure 1, 5 days after primary left lumboscopic drainage. The drain tube is placed beyond the midline.*

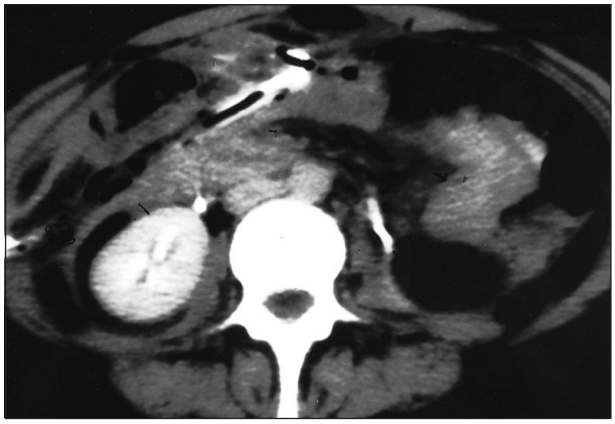

**Figure 3.** *Same patient as in Figure 1, 16 days after primary right lumboscopic drainage. The drain tube is in the right retrocolic area.*

both elements lack specificity. Respiratory or renal failure or any worsening of the clinical state strongly supports the hypothesis of a peripancreatic infected necrosis when they occur after 7 days of evolution.[5,21,22] In our experience, this has been an indication for drainage even without a previous bacteriological confirmation. In contrast, when organ failure is present from the beginning and persists despite supportive therapy, the use of FNA is of maximal value to show infection of necrotic tissues. We do not propose drainage in the absence of sepsis, organ failure, and/or bacteriological proof. In other words, we disagree with a policy of "prophylactic" débridement of sterile peripancreatic necrosis, which has been suggested by some authors.[23] Nevertheless, our cases in which initial bacteriological intraoperative samples were sterile indicate that a wider use of preoperative FNA should be recommended.

A debate persists about the reliability of PD of collections of peripancreatic necrosis.[24,25] Our data show satisfactory results only when PD was performed for a late (>20 days) persistence of large fluid collections, and the sterility of these collections indicated that they could have resolved spontaneously without drainage. On the other hand, failures of PD were observed in group 2, with the subsequent need for other therapeutic modalities (lumboscopy or laparotomy). In cases of infected necrosis containing thick tissue debris, PD with conventional caliber tubes has a poor outcome and may not be adapted to good quality and prolonged drainage.

Surgical débridement and drainage is widely regarded as the only reliable therapeutic method for peripancreatic infected fat necrosis.[1,2,6,26-28] In contrast, the benefit of excision of pancreatic parenchyma necrosis and/or pancreatic resections is controversial.[4,29] Accurate evaluation of the extent of gland necrosis is difficult and may result in excessive resections, especially when surgery is performed too early. Controversy also exists about the optimal time for débridement of peripancreatic fat necrosis.[30] In our experience, surgical débridement for infected necrosis is not performed before the seventh day of evolution. Nevertheless, because we did not systematically perform early FNA, we cannot assert that surgical drainage is useless during the first week of the disease.

The modalities of surgical treatment of infected peripancreatic necrosis are largely debated: surgical approach, closed or open drainage, and need for a continuous irrigation or iterative procedures.[9] The only general agreement concerns the necessity of a complete débridement of all the infected peripancreatic necrosis.[31] Before the CT scan, the use of the transperitoneal approach had the following justifications: it was the only way to provide an exhaustive assessment of multiple peripancreatic collections, it was the means to provide a total peripancreatic necrosectomy and drainage, it was the opportunity to inspect intraperitoneal organs, and it allowed biliary and/or "adjuvant" procedures, such as feeding jejunostomy and/or diversion loop ileostomy. In contrast, laparotomy had the following potential disadvantages: contamination of the peritoneal cavity, further intraoperative difficulties in case of relaparotomy, enhanced risk of multiple erosions of intestinal tract and splanchnic vessels due to the repeated procedures, wound mutilation with respiratory repercussions, and secondary occurrence of abdominal hernias.[9] Subsequently, the concept of retroperitoneal drainage with a lumbotomy has been developed to avoid these drawbacks,[32,33] an attitude that is aided by the systematic and repeated use of CT scan for detection of peripancreatic necrosis. The main drawback of this method is its narrowness and blindness about the potential risk of damage to visceral organs or vessels.[34]



©1998 American Medical Association. All rights reserved.
Downloaded From: http://archsurg.jamanetwork.com/ on 06/01/2016

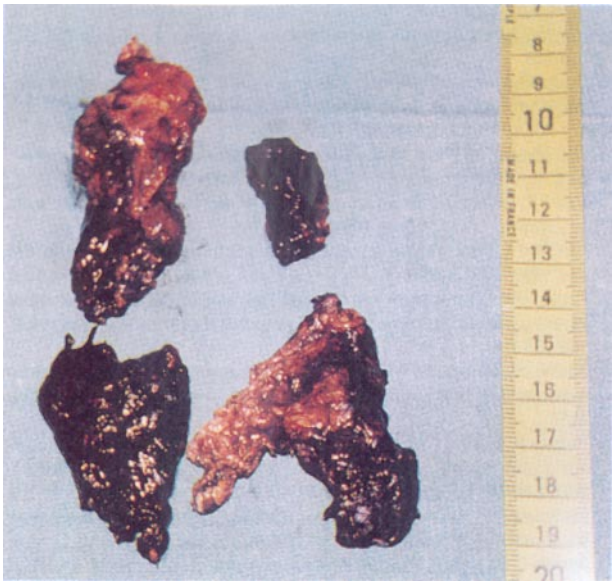

**Figure 4.** *Same patient as in Figure 1, debris of peripancreatic infected necrosis removed during lumboscopic drainage.*

**Figure 5.** *Same patient as in Figure 1, computed tomographic scan (day 32), 21 days after the initial lumboscopic drainage and 4 second-look procedures: progressive resolution of the collections.*

In this study, the use of endoscopic devices reduced the risk of visceral injury because the mobilization of intraperitoneal structures was minimal. When performed from the left, this method allows good access to the anterior side of the pancreas, beyond the midline (**Figure 1** and **Figure 2**), down to the Toldt fascia and possibly to the pelvis. From the right, this method gives access to the posterior side of the duodenopancreas and also to the retrocolic area (**Figure 3**). The procedure allows the careful inspection of the operative field and the excision of large tissue debris (**Figure 4**). Even though the quality of débridement is good, we have a policy of second-look operations based on successive CT examinations (**Figure 5**). Leaving an open wound with an irrigation and lavage system makes the repetition of the procedures easier and avoids the need for general anesthesia after an average of 5 operations. This policy has avoided a laparotomy in 13 patients (65%) of this group.

It may be argued that this method of retroperitoneal drainage cannot evacuate collections located in the transverse mesocolon or the mesentery root.[35] In our experience, such collections usually had a progressive resolution after retroperitoneal drainage, probably because there are anatomical connections between the splanchnic and retroperitoneal cellular spaces. When this type of collection persists, we propose a débridement through a size-limited, "targeted" transperitoneal incision. In our series, the other indication for a laparotomy was the suspicion of, or the occurrence of, a complication such as peritonitis, enteric fistula, or intraperitoneal bleeding; or the requirement for surgical treatment of a concomitant biliary cause. An algorithm for management of peripancreatic necrosis collections is shown in **Figure 6**.

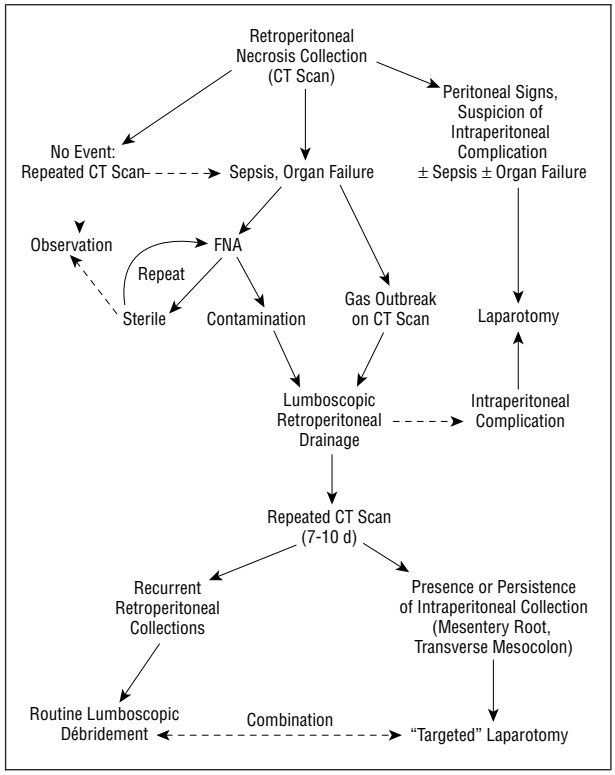


**Figure 6.** *Algorithm for the management of retroperitonal necrosis collections. CT indicates computed tomography; FNA, fine-needle aspiration.*

The overall mortality was 13.2% in this series of ANP, which compares with the results of recent studies.[1-4] Mortality was 10% in patients treated by retroperitoneal drainage. This may indicate that lumboscopic drainage provides a quality of débridement as good as the transperitoneal approach. However, the results of these 2 methods could not be compared in our series, because their indications were different. Lumboscopic drainage can be repeated easily under brief general anesthesia and avoids repeated opening of the peritoneal cavity and its possible contamination. This surgical approach is not exclusive and may be combined to a secondary laparotomy when needed. The preferred indications of this method are heterogeneous collections of necrosis with bacterial contamination. Even in an evident context of sepsis, FNA should be performed to decide about surgery and to adapt antibiotherapy.

*Reprints: Luc P. Gambiez, MD, Clinique Chirurgicale Ouest, Hôpital Claude Huriez, CHRU, F 59037 Lille Cedex, France.*



©1998 American Medical Association. All rights reserved.
Downloaded From: http://archsurg.jamanetwork.com/ on 06/01/2016

## REFERENCES


1. Beger HG. Operative management of necrotizing pancreatitis: necrosectomy and continuous closed postoperative lavage of the lesser sac. *Hepatogastroenterology.* 1991;38:129-133.
2. Bradley EL III. A fifteen-year experience with open drainage for infected pancreatic necrosis. *Surg Gynecol Obstet.* 1993;177:215-222.
3. Miller BJ, Henderson A, Strong RW, et al. Necrotizing pancreatitis: operating for life. *World J Surg.* 1994;18:906-911.
4. Teerenhovi O, Nordback I, Isolauri J. Influence of pancreatic resection on systemic complications in acute necrotizing pancreatitis. *Br J Surg.* 1988;75:793-795.
5. Beger HG, Bittner R, Block S, Buchler M. Bacterial contamination of pancreatic necrosis: a prospective study. *Gastroenterology.* 1986;91:433-438.
6. Stanten R, Frey CF. Comprehensive management of acute necrotizing pancreatitis and pancreatic abscess. *Arch Surg.* 1990;125:1269-1275.
7. Warshaw AL, Jin GL. Improved survival in 45 patients with pancreatic abscess. *Ann Surg.* 1985;202:408-415.
8. Gerzof SG, Banks PA, Robbins AH, et al. Early diagnosis of pancreatic infection by computed tomography-guided aspiration. *Gastroenterology.* 1987;93:1315-1320.
9. D'Egidio A, Schein M. Surgical strategies in the treatment of pancreatic necrosis and infection. *Br J Surg.* 1991;78:133-137.
10. Buchler M, Uhl W, Beger HG. Surgical strategies in acute pancreatitis. *Hepatogastroenterology.* 1993;40:563-568.
11. Ranson JHC, Rifkind KM, Roses DF, et al. Prognostic signs and the role of operative management in acute pancreatitis. *Surg Gynecol Obstet.* 1974;139:69-80.
12. Balthazar EJ, Ranson JHC, Naidish DP. Acute pancreatitis: prognostic value of CT. *Radiology.* 1985;156:767-772.
13. Fernandez-del Castillo C, Rattner DW, Warshaw AL. Acute pancreatitis. *Lancet.* 1993;342:472-479.
14. Runkel NS, Moody FG, Smith GS, et al. The role of the gut in the development of sepsis in acute pancreatitis. *J Surg Res.* 1991;51:18-23.
15. Lange JF, Van Gool J, Tytgat GN. The protective effect of a reduction in intestinal flora on mortality of acute haemorrhagic pancreatitis in the rat. *Hepatogastroenterology.* 1987;34:28-30.
16. Pederzoli P, Bassi C, Vesentini S, et al. A randomized multicenter clinical trial of antibiotic prophylaxis of septic complications in acute necrotizing pancreatitis with imipenem. *Surg Gynecol Obst.* 1993;176:480-483.
17. Bradley EL III, Allen K. A prospective longitudinal study of observation versus surgical intervention in the management of necrotizing pancreatitis. *Am J Surg.* 1991;161:19-25.
18. Ranson JHC, Balthazar E, Caccavale R, Cooper M. Computed tomography and the prediction of pancreatic abscess in acute pancreatitis. *Ann Surg.* 1985;201:656-665.
19. Clavien P-A, Hauser H, Meyer P, Rohner A. Value of contrast enhanced computerized tomography in the early diagnosis and prognosis of acute pancreatitis. *Am J Surg.* 1988;155:457-466.
20. Fink AS, Hiatt JR, Pitt H, et al. Indolent presentation of pancreatic abscess: experience with 100 cases. *Arch Surg.* 1988;123:1067-1072.
21. Madry S, Fromm D. Infected retroperitoneal fat necrosis associated with acute pancreatitis. *J Am Coll Surg.* 1994;178:277-282.
22. Lumsden A, Bradley EL III. Secondary pancreatic infections. *Surg Gynecol Obstet.* 1990;170:459-467.
23. Rattner DW, Legermate DA, Lee MJ, et al. Early surgical débridement of symptomatic pancreatic necrosis is beneficial irrespective of infection. *Am J Surg.* 1992;163:105-110.
24. Adams DB, Harvey TS, Anderson MC. Percutaneous catheter drainage of infected pancreatic and peripancreatic fluid collections. *Arch Surg.* 1990;125:1554-1557.
25. Rotman N, Mathieu D, Anglade MC, Fagniez PL. Failure of percutaneous drainage of pancreatic abscesses complicating severe acute pancreatitis. *Surg Gynecol Obstet.* 1992;174:141-144.
26. Farthmann EH, Lausen L, Schoffel U. Indications for surgical treatment of acute pancreatitis. *Hepatogastroenterology.* 1993;40:556-562.
27. Smadja C, Bismuth H. Pancreatic débridement in acute pancreatitis. *Br J Surg.* 1986;73:408-410.
28. Ranson JHC. The role of surgery in the management of acute pancreatitis. *Ann Surg.* 1990;211:382-393.
29. Aldridge MC, Ornstein M, Glazer G, Dudley HAF. Pancreatic resection for severe acute pancreatitis. *Br J Surg.* 1985;72:796-800.
30. Howard JM. Delayed debridement and external drainage of massive pancreatic or peripancreatic necrosis. *Surg Gynecol Obstet.* 1989;168:25-29.
31. Frey CF, Bradley EL III, Beger HG. Progress in acute pancreatitis. *Surg Gynecol Obstet.* 1988;167:282-286.
32. Villazon AS, Villazon OD, Terrazas FE, Rana RG. Retroperitoneal drainage in the management of the septic phase of severe acute pancreatitis. *World J Surg.* 1991;15:103-108.
33. Van Vyve EL, Reynart MS, Lengele B, et al. Retroperitoneal laparostomy: a surgical treatment of pancreatic abcesses after an acute necrotizing pancreatitis. *Surgery.* 1992;111:369-375.
34. Fagniez PL, Rotman N, Kracht M. Direct retroperitoneal approach to necrosis in severe acute pancreatitis. *Br J Surg.* 1989;76:264-267.
35. Berne TV, Donovan AJ. Synchronous anterior celiotomy and posterior drainage of pancreatic abscess. *Arch Surg.* 1981;116:527-53.


## IN OTHER AMA JOURNALS

ARCHIVES OF INTERNAL MEDICINE

### Confidentiality and Health Insurance Fraud


Neil J. Farber, MD; Mark S. Berger, MD; Elizabeth B. Davis, PhD; Joan Weiner, PhD; E. Gil Boyer, EdD; Peter A. Ubel, MD



**Background:** Health insurance fraud committed by patients may be an increasing problem given the number of underinsured and uninsured people in the United States. Physicians recognizing acts of health insurance fraud perpetrated by patients face an ethical dilemma: should they disclose the incident to the insurance company, or protect patient confidentiality?
**Objective:** To explore physicians' attitudes toward the reporting of patient-initiated health insurance fraud.
**Methods:** Three hundred seven physician members of the American College of Physicians returned a mailed questionnaire that presented 6 case vignettes (3 variables) of patients who used a relative's insurance to obtain health care in the past. For each vignette, respondents were asked whether the treating physician should report insurance fraud to the health insurance carrier.
**Results:** Sixty-three respondents (20.7%) indicated that physicians should report all the patients presented in the vignettes, while 45 (14.8%) indicated none should be reported; the rest indicated that the decisions to report should be based on the characteristics presented, with acute vs terminal illness ($P<.001$), history of fraud ($P<.001$), and wealth of the patient ($P<.001$) all causing physicians to be more likely to report the patient to the health insurance carrier. Multivariate analysis demonstrated that type of practice ($P=.04$) and respondents' experiences with insurance fraud ($P=.03$) had significant effects on the willingness to report patients.
**Conclusions:** Physicians are divided about whether to report patients who have committed insurance fraud. Their decisions to report insurance fraud are influenced by their attitudes and demographic features, as well as by patient factors. *Arch Intern Med. 1997;157:501-504*



*Reprints: Neil J. Farber, MD, Veterans Affairs Medical Center, University and Woodland Avenues, Philadelphia, PA 19104.*





©1998 American Medical Association. All rights reserved.
Downloaded From: http://archsurg.jamanetwork.com/ on 06/01/2016