ORIGINAL ARTICLE

Intraoperative Pancreatoscopy With the Ultrathin Pancreatoscope for Mucin-Producing Tumors of the Pancreas

Tetsuya Kaneko, MD; Akimasa Nakao, MD; Shuji Nomoto, MD; Tsuyoshi Furukawa, MD; Yoshiki Hirooka, MD; Nobuo Nakashima, MD; Tetsuro Nagasaka, MD

Objective: To evaluate the diagnostic accuracy of intraoperative pancreatoscopy with the ultrathin pancreatoscope for the main pancreatic lesions of mucin-producing tumors of the pancreas (MPT).

Design: Prospective diagnostic test study with a criterion standard of pathologic examination and masked comparison.

Setting: A university hospital.

Patients: Twenty-four consecutive patients with MPT referred for surgery in whom endoscopic retrograde pancreatography, endoscopic ultrasonography, and computed tomography had been performed as a diagnostic examination. All patients underwent surgery and the diagnosis was confirmed by pathologic examination.

Intervention: Intraoperative pancreatoscopy was performed with the ultrathin pancreatoscope.

Main Outcome Measures: Findings of intraoperative pancreatoscopy, endoscopic retrograde pancreatography, and endoscopic ultrasonography were confirmed by pathologic examination of resected specimens. The diagnostic accuracy of these 3 modalities in detection of MPT lesions in the main pancreatic duct was compared.

Results: The diagnostic criterion of MPT lesions in the main pancreatic duct by intraoperative pancreatoscopy was a granular and papillary mural nodule. An MPT lesion in the main pancreatic duct was found in 17 of 24 cases. Intraoperative pancreatoscopy detected 10 cases of intraductal MPT lesions that could not be detected by endoscopic ultrasonography or endoscopic retrograde pancreatography. Five of 10 cases were intraductal multicentric lesions. In 3 of these 5, additional pancreatic resection was performed. For diagnosis of MPT lesions, the sensitivity, specificity, and overall accuracy of intraoperative pancreatoscopy were all 100%; respective values were 43.8%, 100%, and 60.9% for endoscopic retrograde pancreatography and 47%, 100%, and 62.5% for endoscopic ultrasonography.

Conclusions: Intraoperative pancreatoscopy is safe and effective in diagnosing the intrapancreatic duct extension and multicentric lesions of MPT. It provides important information for operative strategy and contributes to successful pancreatic surgery.

Arch Surg. 1998;133:263-267

From the Departments of Surgery II (Drs Kaneko, Nakao, and Nomoto), Internal Medicine II (Drs Furukawa and Hirooka), and Clinical Laboratory (Drs Nakashima and Nagasaka), Faculty of Medicine, University of Nagoya, Nagoya, Japan.

With the recent better understanding of mucin-producing tumors of the pancreas (MPT), the number of reported cases has increased.[1] This disease was first reported in 1982 by Ohhashi et al,[2] who described 4 cases with hypersecretion of mucin from the pancreas caused by a ductal neoplasm. Various names have been given to this disease, such as mucin-hypersecreting carcinoma,[3] mucin-producing pancreatic tumor,[4] mucinous ductal ectasia,[5] mucinous cystadenoma and cystadenocarcinoma,[6,7] and mucin-producing cystic tumors of the pancreas.[8] In this article, the term *mucin-producing tumor of the pancreas* was used in accordance with the recommendation of Itai.[9] Mucin-producing tumors of the pancreas develop in the main pancreatic duct and histologically consist of well-differentiated mucus-secreting cells.

It is important to confirm the extent of MPT in the main pancreatic duct for pancreatic surgery, but it is difficult to determine the exact intrapancreatic duct extent of MPT with conventional imaging techniques, including endoscopic ultrasonography (EUS).[10] Multicentric lesions of MPT must also be checked intraoperatively to avoid residual lesions.[11] Thus, a thorough exploration of the pancreatic duct is necessary to perform successful pancreatic surgery for MPT.

©1998 American Medical Association. All rights reserved.
Downloaded From: http://archsurg.jamanetwork.com/ on 09/03/2015

PATIENTS AND METHODS

From June 1992 to October 1996, 24 consecutive patients with MPT were prospectively studied with the intraoperative pancreatoscope. The study group consisted of 14 men and 10 women, with a mean age of 62 years (range, 44-78 years). The MPT was defined as a cystic or duct ectatic lesion or tumor with mucin excretion through a patulous orifice of the enlarged papilla and a dilated main pancreatic duct filled with mucin. According to the classification of Nakazawa et al,[8] the 24 MPT were classified into main-duct type and branch-duct type. There were 5 main-duct types and 19 branch-duct types. The MPT was located at the head of the pancreas in 15 cases, at the body in 8 cases, and at the tail in 1 case. In all patients, pancreatic resection and pathologic examination were performed.

TECHNIQUES

Intraoperative pancreatoscopy was performed with an ultrathin pancreatoscope (Clinical Supply Co Ltd, Gifu, Japan) (**Figure 1**). This scope has an 1.7-mm external diameter and a 120-cm effective length. It consists of 6000 image fibers, and its visual depth is above 2 mm. After laparotomy, the MPT lesion was explored according to the preoperative imaging diagnosis, and its location was confirmed with intraoperative ultrasonography. The pancreatic resection line was then determined and the pancreas was amputated. The pancreatoscope was inserted into the main pancreatic duct from the cut surface of the pancreas. First, the main pancreatic duct of the MPT side (resection side) was examined, followed by the main pancreatic duct on the nonresection side. Saline solution was sometimes infused into the main pancreatic duct through the small-bore channel of the pancreatoscope to obtain a sharp image. Saline solution overflow was collected in the basin of the operative field to avoid spillage of saline solution and mucin into the abdominal cavity.

Pancreatoscopic images were displayed on a 9-in color television monitor and recorded on 8-mm videotape. Individual still frames of investigated lesions were recorded on slide film. There was one observer (T.K.) of the intraoperative pancreatoscopic findings. Tabulation of the pancreatoscopic findings was performed during surgery. The reader (T.K.) of the pancreatoscopic studies was blinded to the results of other imaging procedures.

PREOPERATIVE EXAMINATION

In all patients, EUS and computed tomography, including dynamic study, were performed. In all but 1 patient, endoscopic retrograde pancreatography (ERP) was performed. The ERP procedure could not be performed in 1 patient who had previously undergone gastrectomy with Billroth II reconstruction.

Endoscopic retrograde pancreatography was performed by an expert endoscopist (T.F.). A well-defined filling defect of polypoid tumor was the diagnostic criterion for an intraductal MPT lesion. The ERP findings were reviewed without knowledge of the results of other examinations.

Endoscopic ultrasonography was performed by an expert endoscopist (Y.H.) and also was reviewed without knowledge of the results of other examinations. It was performed with a 7.5-MHz system (GF-UM 2, Olympus Corp, Tokyo, Japan). The diagnostic criterion for intraductal MPT by EUS was hyperechoic vegetation in the main pancreatic duct.

PATHOLOGIC EXAMINATION

In each case, the resected pancreatic specimens were serially cut into 5-mm stepwise tissue sections along the main pancreatic duct. The prepared slices were then dyed with hematoxylin-eosin. Histological examination was performed by 2 pathologists (T.N. and N.N.).

EVALUATION OF DIAGNOSTIC ACCURACY

The intraoperative pancreatoscopy results were correlated with the histological findings in the resected specimens. In terms of MPT lesion in the main pancreatic duct, the results of intraoperative pancreatoscopy were compared with the results of the other 2 imaging techniques (ERP and EUS). Comparison of proportions for statistical significance was calculated with the use of the Fisher exact probability test. $P<.05$ was considered significant in all statistical comparisons.

With the recent progress of endoscopic technology, a small-bore endoscope with good resolution has been developed.[12] We performed intraoperative pancreatoscopy to evaluate the MPT lesion in the main pancreatic duct with an ultrathin pancreatoscope. The aim of this study is to evaluate the diagnostic accuracy of intraoperative pancreatoscopy for intraductal mural nodules of MPT and its advantage in pancreatic surgery for MPT.

RESULTS

In all patients, intraoperative pancreatoscopy was performed without complications. It took less than 10 minutes to perform this examination. The normal main pancreatic duct was visualized as a white smooth lumen with a slight knot. The orifice of the pancreatic duct branch was seen. Any MPT lesion was visualized as a reddish, granular, and papillary mural nodule with an appearance similar to that of salmon roe.

Pancreatoscopic findings of intraductal MPT were described as follows. In the case of hyperplasia, the diameter of the intraductal mural nodule was small and faintly red (**Figure 2**). In adenoma, the diameter of intraductal mural nodule was large and reddish (**Figure 3**). In carcinoma, the intraductal mural nodule was a solid tumor (**Figure 4**).

Intraoperative pancreatoscopy detected 9 cases of intraductal MPT lesions that could not be found by ERP, and 9 cases of MPT lesions not found by EUS. Five of 10 cases in which intraductal MPT lesions could not be detected by ERP or EUS had multifocal lesions located apart from one another. In 2 of these 5 cases, separate lesions

©1998 American Medical Association. All rights reserved.
Downloaded From: http://archsurg.jamanetwork.com/ on 09/03/2015



Figure 1. *The tip of the ultrathin pancreatoscope. The diameter is 1.7 mm.*

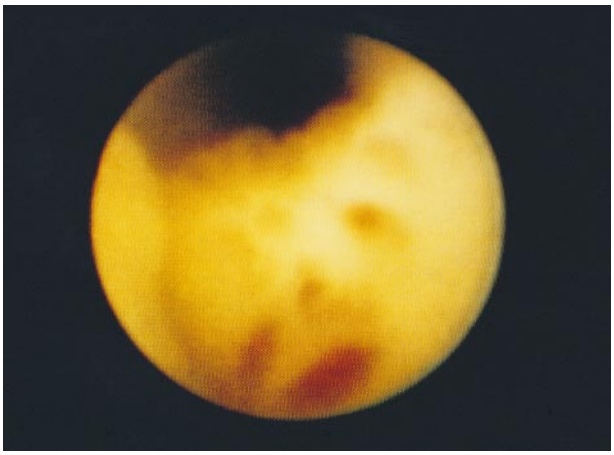

Figure 2. *Intraoperative pancreatoscopy showed a small reddish intraductal mural nodule.*

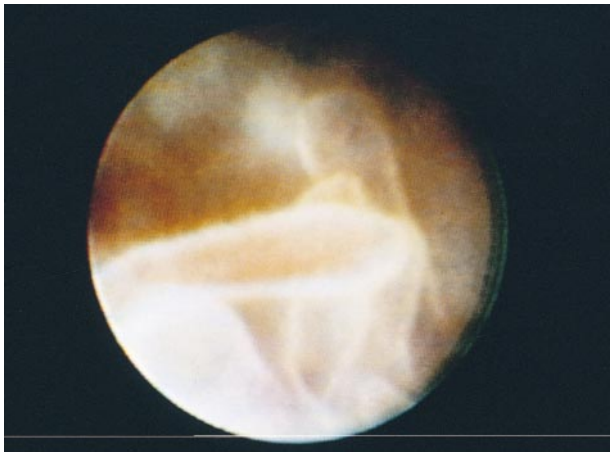

Figure 3. *Intraoperative pancreatoscopy showed large mural nodules in the main pancreatic duct.*

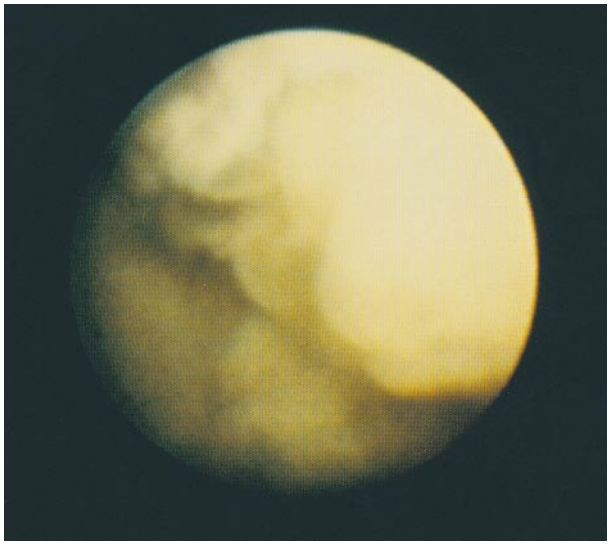

Figure 4. *Intraoperative pancreatoscopy showed a solid mural nodule in the main pancreatic duct.*

were located in the same side of the resected pancreas. In the remaining 3 cases, another intraductal MPT lesion was unexpectedly found in the residual side of the pancreas (**Figure 5**). Thus, in these 3 cases in which pancreaticoduodenectomy or pylorus-preserving pancreaticoduodenectomy was performed, additional resection of the pancreatic body was necessary.

In 2 cases of MPT at the pancreatic body, intraductal lesions extended more to the head side of the pancreas than to the point that was diagnosed preoperatively by ERP and EUS. Intraoperative ultrasonography revealed that the head side of the MPT lesion was located on the right side of the portal venous wall. The pancreas was amputated at the right side of the portal venous wall according to the intraoperative ultrasonography finding. Intraoperative pancreatoscopy was then performed in the remnant pancreas (head of the pancreas) to check the residual lesion of the main pancreatic duct. Unexpectedly, the tip of a polypoid lesion of MPT was found in the main pancreatic duct of the head of the pancreas and removed. Intraoperative pancreatoscopy was performed again and complete resection of MPT was confirmed.

All patients underwent surgical resection, including pylorus-preserving pancreaticoduodenectomy in 13 patients, pancreaticoduodenectomy in 2, distal pancreatectomy in 5, and segmental resection of the pancreas in 4. Histologically, the tumors consisted of well-differentiated, mucin-secreting cells, and showed a papillary or papillotubular growth pattern. The pathologic diagnosis of the 24 MPT was hyperplasia of pancreatic duct epithelium in 11, intraductal papillary adenoma in 8, and intraductal papillary adenocarcinoma in 5. The mean diameter of intraductal mural nodule was 3.2 mm in the 11 hyperplasia, 6.4 mm in the 8 adenoma, and 10.5 mm in the 5 adenocarcinoma cases. In this study, there were no operative deaths. All patients were alive without recurrence within 4 years' follow-up time.

In the diagnosis of intraductal mural nodules of MPT, the results of intraoperative pancreatoscopy were compared with those of ERP and EUS. The accuracy of each method was calculated from the compiled data (**Table 1**). The sensitivity of pancreatoscopy in detection of intraductal mural nodules of MPT was statistically superior to that of ERP and EUS ($P<.001$). The overall accuracy of pancreatoscopy in the detection of intraductal mural nodules of MPT was statistically superior to that of ERP and EUS ($P<.01$) (**Table 2**).

COMMENT

Pancreatic tumors with intraductal growth and cystic transformation of the duct system have received increasing attention.[13] Mucin-producing tumors are character-

©1998 American Medical Association. All rights reserved.
Downloaded From: http://archsurg.jamanetwork.com/ on 09/03/2015

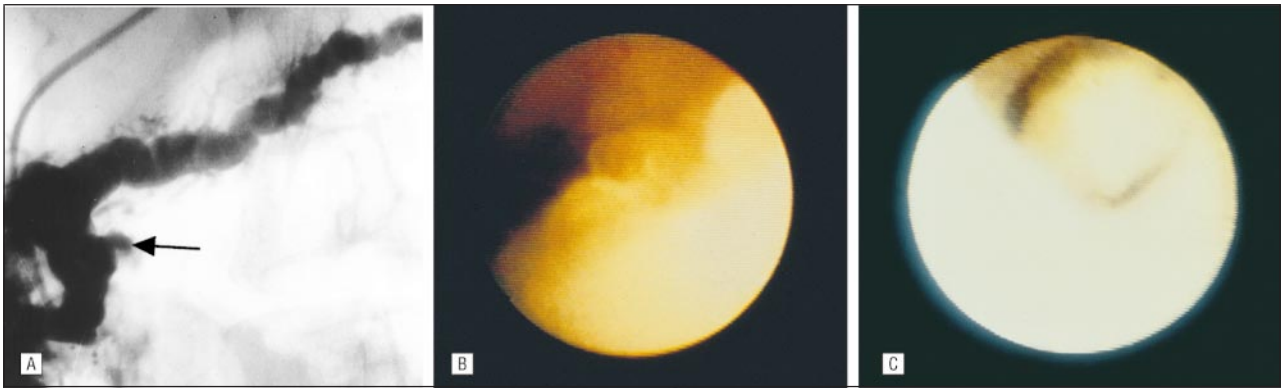

Figure 5. *A, Endoscopic retrograde pancreatography showed a diffuse dilatation of the main pancreatic duct. Uncinate branch was not visualized (arrow) owing to the mucin-producing tumor lesion. No obvious mural nodule was visualized in the main pancreatic duct. B, Intraoperative pancreatoscopy showed a solid mural nodule in the main pancreatic duct at the head of the pancreas. C, Intraoperative pancreatoscopy detected a multicentric lesion in the main pancreatic duct at the pancreatic body. Additional pancreatic resection was performed to remove this lesion.*

Table 1. Comparative Results of 3 Modalities*

Type of Case	Intraoperative Pancreatoscopy	ERP	EUS
True positives	17	7	9
True negatives	7	7	7
False positives	0	0	0
False negatives	0	9	8
Total	**24**	**23**	**24**

**ERP indicates endoscopic retrograde pancreatography; EUS, endoscopic ultrasonography.*

Table 2. Comparative Accuracies of 3 Modalities*

Percent	Intraoperative Pancreatoscopy	ERP	EUS
Sensitivity	100†	43.8†	47†
Specificity	100	100	100
Overall accuracy	100‡	62.5‡	62.5‡

**ERP indicates endoscopic retrograde pancreatography; EUS, endoscopic ultrasonography.*
†P<.001 for intraoperative pancreatoscopy vs ERP and EUS.
‡P<.01 for intraoperative pancreatoscopy vs ERP and EUS.

ized by mucin excretion through a patulous orifice of the enlarged ampulla of Vater and a dilated main pancreatic duct filled with mucin. Most MPT are categorized as intraductal papillary neoplasms of the pancreas and regarded as low-grade neoplasms, and the term includes a broad spectrum of histopathologic disorders, from hyperplasia to adenocarcinoma.[14]

In cases of adenocarcinoma of MPT, a large portion of the tumor consists of papillary hyperplasia and adenoma, with a small area being cancerous. Thus, a sequential change from papillary hyperplasia through adenoma to adenocarcinoma is considered to occur in the pancreatic duct.[14] A benign MPT lesion has malignant potential, so we adopted a policy of surgical resection of MPT lesions.

Mucin-producing tumors spread along the pancreatic duct with replacement of normal epithelium.[15] Main-duct type tumors extend along the main pancreatic duct, and the accurate diagnosis of tumor extent in the main pancreatic duct is important. Branch-duct type tumors also extend into the main pancreatic duct and show a superficial spread along the pancreatic duct epithelium. Yamada et al[14] reported that malignant cases of the branch-duct type extended into the main pancreatic duct in 66.7% of cases, vs 28.6% in benign cases. In our study, adenocarcinoma of branch-duct type MPT extended into the main pancreatic duct in all cases, adenoma of branch-duct type extended into the main pancreatic duct in 66.7%, and hyperplasia of branch-duct type MPT extended into the main pancreatic duct in 50% of the cases under study. Thus, it is also important to evaluate the intrapancreatic duct extension of the branch-duct type MPT.

Multicentric development of MPT poses another problem.[16,17] Fujii et al[16] reported that the incidence of multicentric lesions of MPT was 32%. In our study, the incidence was 20.8%. Multicentric MPT lesions were difficult to diagnose preoperatively by conventional imaging techniques.

Because of the main pancreatic duct spread and multicentricity of MPT, accurate diagnosis of MPT extent in the main pancreatic duct is important to formulate an operative strategy that will not leave any residual lesion. Despite the recent progress of imaging technology, however, the accurate detection of mural nodules in the main pancreatic duct remains difficult.[10,18] Especially in hyperplasia of MPT, the diagnostic accuracy of EUS and ERP was 16.7% in the present study because the mural nodule averaged only 3.2 mm in size. Even in malignant cases, 2 cases were not detected accurately by EUS and ERP. In 1 case, the main MPT lesion was at the uncinate branch of the main pancreatic duct, and the MPT lesion at the main pancreatic duct was too small to be detected by EUS and ERP. In another case, the multicentric lesion in the main pancreatic duct was also too small to be recognized by conventional imaging techniques.

With the recent progress of endoscopic technology, an ultrathin endoscope was developed for pancreatic duct observation.[19] There are several reports about peroral pancreatoscopy using an ultrathin caliber endoscope.[20,21] The improved endoscope has made it much

©1998 American Medical Association. All rights reserved.
Downloaded From: http://archsurg.jamanetwork.com/ on 09/03/2015

easier to observe main pancreatic duct lesions. The diagnostic accuracy of peroral pancreatoscopy for MPT was reported to be 85%.[22] Thorough observation throughout the main pancreatic duct has proved difficult, however, because of the angle formed by the junction of the ducts of Wirsung and Santorini and the main pancreatic duct kinking.[12,23]

Thus, we performed intraoperative pancreatoscopy to observe the main pancreatic duct with an ultrathin pancreatoscope to overcome the aforementioned difficulty. One of the advantages of intraoperative pancreatoscopy is direct observation of the pancreatic duct with good visual field and easy technique. By moving the amputated pancreas manually, the pancreatoscope can be positioned in the center of the main pancreatic duct. This maneuver overcomes the duct tortuosity or kinking that prevents observation of the pancreatic duct. Another advantage of intraoperative pancreatoscopy is its excellent detection rate for intraductal mural nodules in the main pancreatic duct. It is very difficult to diagnose nodules smaller than 5 mm by ERP or EUS, much less by computed tomographic scan.[24] In our pancreatoscopy, intraductal mural nodules were characteristically visualized as a reddish papillary mass with a resemblance to salmon roe.

For the detection of MPT mural nodules in the main pancreatic duct, intraoperative pancreatoscopy was clearly superior to ERP or EUS. Moreover, the characteristic salmon roe appearance was a definite clue in MPT mural nodule diagnosis. It was important to differentiate MPT from other pancreatic diseases, especially chronic pancreatitis.

Mucin-producing tumors are premalignant or malignant lesions that should be completely removed, even if the patient is asymptomatic. It is basically a low-grade malignant tumor and a good prognosis can be expected after resection unless it has invaded the pancreatic parenchyma or adjacent structures.[17,25,26] From the surgical point of view, limited resection of MPT without residual lesion is expected; organ-preserving procedures are the mainstream in pancreatic surgery in recent years. For MPT at the pancreatic head, pylorus-preserving pancreaticoduodenectomy is performed in our department. Recently, duodenum-preserving pancreatic head resection has been performed for MPT at the pancreatic head in some institutions.[27,28] For MPT at the pancreatic body, distal pancreatectomy is the rule. As an organ-preserving procedure, segmental resection of the pancreas is undertaken for limited MPT lesion. We performed segmental resection in 4 cases of MPT at the pancreatic body. We have experienced no recurrence of MPT in our study patients during 4 years of follow-up. However, longer follow-up is needed to confirm the benefits of this technique for prognostic improvement of MPT.

In our study, intraoperative pancreatoscopy proved useful to diagnose the intrapancreatic duct extension, to pinpoint small lesions, and to detect multicentric lesions of MPT, while providing important information for operative planning and assuring the success of pancreatic surgery for MPT.

Reprints: Tetsuya Kaneko, MD, Department of Surgery II, Faculty of Medicine, University of Nagoya, 65 Tsurumai-cho, Showa-ku, Nagoya 466, Japan.

REFERENCES

1. Richaert F, Cremer M, Deviere J, et al. Intraductal mucin-hypersecreting neoplasms of the pancreas: a clinicopathologic study of eight patients. *Gastroenterology*. 1991;101:512-519.
2. Ohhashi K, Murakami Y, Takekoshi T, et al. Four cases of "mucin-producing" cancer of the pancreas on specific findings of the papilla Vater. *Prog Dig Endosc*. 1982;20:348-351.
3. Itai Y, Kokubo T, Atomi Y, Kuroda A, Haraguchi Y, Terano A. Mucin-hypersecreting carcinoma of the pancreas. *Radiology*. 1987;165:51-55.
4. Itoh S, Ishiguchi T, Ishigaki T, Sakuma S, Maruyama K, Senda K. Mucin-producing pancreatic tumor: CT finding and correlation. *Radiology*. 1992;183:81-86.
5. Warshaw AL. Mucinous cystic tumors and mucinous ductal ectasia of the pancreas. *Gastrointest Endosc*. 1991;37:199-201.
6. Itai Y, Ohhashi K, Nagai H. "Ductectatic" mucinous cystadenoma and cystadenocarcinoma of the pancreas. *Radiology*. 1986;161:697-700.
7. Martin T, McAdena OJ, Urmacher C, Herman B, Shiu MH. Pancreatic cystadenoma: a clinicopathologic study. *Arch Surg*. 1989;124:1271-1274.
8. Nakazawa S, Yamao K, Yamada M, et al. Study of the classification of mucin-producing cystic tumor of the pancreas. *Jpn J Gastroenterol*. 1988;85:924-932.
9. Itai Y. Different terms of the same disease: intraductal mucin-producing tumor versus mucinous tumors of the pancreas. *Radiology*. 1996;200:285.
10. Kobayashi G, Fujita N, Lee S, et al. Correlation between ultrasonographic findings and pathological diagnosis of the mucin-producing tumor of the pancreas. *Jpn J Gastroenterol*. 1990;87:235-242.
11. Obara T, Saitoh Y, Maguchi H, et al. Multicentric development of pancreatic intraductal carcinoma through atypical papillary hyperplasia. *Hum Pathol*. 1992;23:82-85.
12. Mizuno S, Nakajima M, Yasuda K, et al. Shape memory alloy catheter system for peroral pancreatoscopy using an ultrathin-caliber endoscope. *Endoscopy*. 1994;26:676-680.
13. Obara T, Magichi H, Saitoh Y, et al. Mucin-producing tumor of the pancreas: a unique clinical entity. *Am J Gastroenterol*. 1991;86:1619-1625.
14. Yamada M, Kozuka S, Yamao K, Nakazawa S, Naitoh Y, Tsukamoto Y. Mucin-producing tumor of the pancreas. *Cancer*. 1991;68:159-168.
15. Fujita N, Lee S, Kobayashi G, Kimura K, Watanabe H, Mochizuki F. *Dig Endosc*. 1990;2:110-115.
16. Fujii T, Obara T, Maguchi H, Tanno S, Ura H, Kohgo Y. Clinicopathological study of multiple mucin-producing tumors of the pancreas: multicentric development of carcinoma through atypical hyperplasia. *J Jpn Pancreatol Soc*. 1996;11:344-352.
17. Morohoshi T, Kanda M, Asanuma K, Köpplel G. Intraductal papillary neoplasms of the pancreas: a clinicopathologic study of six patients. *Cancer*. 1989;64:1329-1335.
18. Procacci C, Graziani R, Bicego E, et al. Intraductal mucin-producing tumors of the pancreas: imaging findings. *Radiology*. 1996;198:249-257.
19. Kozarek RA. Direct cholangiography and pancreatoscopy at time of endoscopic retrograde cholangiopancreatography. *Am J Gastroenterol*. 1988;83:55-57.
20. Yamao K, Nakazawa S, Yoshino J, et al. Clinical study of peroral transpapillary pancreatoscopy (POPS) by ultra-thin pancreatoscope. *J Jpn Pancreatol Soc*. 1984;4:1-6.
21. Rieman JF, Kohler B. Endoscopy of the pancreatic duct: value of different endoscope types. *Gastointest Endosc*. 1993;39:367-370.
22. Yamaguchi T, Saisho H, Tsuchiya S. Clinical usefulness of peroral pancreatoscopy in the diagnosis of mucin-producing tumor of the pancreas. *Int J Pancreatol*. 1996;19:259-260.
23. Tajiri H, Kobayashi M, Niwa H, Furui S. Clinical application of an ultra-thin pancreatoscope using a sequential video converter. *Gastrointest Endosc*. 1993;39:371-374.
24. Yamaguchi K, Ogawa Y, Chijiiwa K, Tanaka M. Mucin-hypersecreting tumors of the pancreas: assessing the grade of malignancy preoperatively. *Am J Surg*. 1995;171:427-431.
25. Warhsaw AL, Comton CC, Lewandrowski K, Cardenosa G, Muller PR. Cystic tumors of the pancreas: new clinical, radiologic, and pathologic observations in 67 patients. *Ann Surg*. 1990;212:432-445.
26. Re Mine SG, Frey D, Rossi RL, Munson L, Braasch JW. Cystic neoplasms of the pancreas. *Arch Surg*. 1987;122:443-446.
27. Kimura W, Nagai H. Study of surgical anatomy for duodenum-preserving resection of the head of the pancreas. *Ann Surg*. 1995;221:359-363.
28. Imaizumi T, Hanyu F, Suzuki M, et al. Duodenum preserving total resection of the head of the pancreas. *Gastroenterol Surg*. 1991;14:475-488.

©1998 American Medical Association. All rights reserved.
Downloaded From: http://archsurg.jamanetwork.com/ on 09/03/2015