ORIGINAL ARTICLE

Preoperative Chemoembolization of Hepatocellular Carcinoma

A Comparative Study

François Paye, MD; Pascal Jagot, MD; Valérie Vilgrain, MD; Olivier Farges, MD, PhD; Dominique Borie, MD; Jacques Belghiti, MD, PhD

Objective: To assess the efficacy and adverse effects of preoperative transcatheter chemoembolization (CE) on surgical resection, postoperative outcome, and recurrence of hepatocellular carcinoma.

Design: A before-after trial comparing a group of patients undergoing liver resection after CE (CE group) with a group of patients undergoing liver resection without prior CE (control group), matched for tumor size and underlying liver disease.

Setting: A tertiary care university hospital in a metropolitan area.

Patients: Twenty-four patients in each group, treated between 1986 and 1992.

Interventions: A mean of 1.6±0.2 preoperative CE procedures were performed per patient in the CE group. Tumorectomies, segmentectomies, and major liver resections were performed with a comparable frequency in each group.

Results: Overall, CE was not associated with a significant reduction of tumor size (7.8±1 cm prior to CE vs 7.1±1 cm after CE) or α-fetoprotein levels (2560±2091 µg/L prior to CE vs 1788±1270 µg/L after the last CE). Chemoembolization promoted tumor necrosis but did not influence tumor encapsulation, invasion of the capsule, venous permeation, presence of daughter nodules, or surgical margins. Liver resection was rendered more difficult by preoperative CE as a result of pediculitis and gallbladder lesions in 37% of patients, but the postoperative course was not altered. Disease-free survival (33%±12% vs 32%±12% at 3 years) and overall survival were comparable.

Conclusions: Convincing evidence is lacking to support systematic preoperative CE in patients with initially resectable hepatocellular carcinoma. Further studies should aim to identify the subgroup of patients who may benefit from this neoadjuvant treatment.

Arch Surg. 1998;133:767-772

From the Departments of Digestive Surgery (Drs Paye, Jagot, Farges, Borie, and Belghiti) and Radiology (Dr Vilgrain), Hôpital Beaujon, University Paris VII, Clichy, France.

TECHNICAL ADVANCES and a better selection of patients allow resection of hepatocellular carcinoma (HCC) to be performed in specialized centers with an in-hospital mortality rate of less than 10%.[1-5] Intrahepatic recurrence of HCC still affects 60% to 75% of the patients undergoing resection[6-9] and remains the cause of 60% of deaths.[6] Transcatheter arterial chemoembolization (CE) combining intrahepatic delivery of a cytostatic product emulsified in ethiodized oil (Lipiodol, Laboratories Guerbet, Aulnay-sous-bois, France) with a temporary embolization of intrahepatic arterial branches by gelatin is widely used to treat resectable or nonresectable HCC.[5,10-12] Chemoembolization is now also performed preoperatively by surgical teams as a neoadjuvant therapy to prevent recurrences of HCC[13-16] or to facilitate resection of large tumors.[17] The effect of preoperative CE on surgical resection remains controversial, and its effectiveness in preventing recurrence is not yet proven.[15-18] This study aims at assessing the role of preoperative CE on the early and long-term outcome following resection of HCC, using a matched group of patients in whom HCC was resected without preoperative CE as controls.

RESULTS

The 2 groups, paired with the 4 main criteria previously described, seemed to be well matched for the following secondary criteria collected at the time of diagnosis of HCC: age, sex ratio, cause of underlying liver disease, presence of esophageal varices, and degree of portal branch obstruction (**Table 1**). The AFP levels did not differ significantly between the control group (mean, 4229 µg/L; range,

©1998 American Medical Association. All rights reserved.
Downloaded From: http://archsurg.jamanetwork.com/ on 12/22/2014

PATIENTS AND METHODS

DIAGNOSIS OF HCC

At least 3 of the following 4 criteria were required to allow the diagnosis of HCC: a proven chronic diffuse liver disease, a nodular lesion on ultrasonography, a nodular captation of Lipiodol on a computed tomographic scan performed 2 to 3 weeks after a lipiodolized arteriography, and a serum α-fetoprotein (AFP) level exceeding 500 µg/L. If 1 criterion was not satisfied, a positive percutaneous biopsy specimen from the tumor was required.

PREOPERATIVE CE GROUP

Between December 1989 and January 1992, 24 consecutive patients in our center underwent a resection of HCC after preoperative CE (CE group). All patients included had a tumor considered as initially resectable. Contraindications to CE were portal obstruction of at least 3 segmental branches or hepatic insufficiency of Child-Pugh class C. The CE was performed by radiologists who had experience with Lipiodol CE. First, the superior mesenteric artery was injected through a Seldinger femoral approach to assess the portal flow. When the portal flow was adequate, the hepatic artery was selectively catheterized. The tip of the catheter was placed distal to the gastroduodenal artery and 40 to 60 mg of doxorubicin (Farmitalia Carlo Erba, Milan, Italy) emulsified in 10 to 15 mL of Lipiodol were injected under fluoroscopic control, followed by an embolization with gelatin-sponge particles (Upjohn, Kalamazoo, Mich). Antibiotics (amoxicillin and clavulanic acid) and an anti-H_2 receptor (cimetidine) were administered for 4 days after CE. If the average diameter of the main tumor had decreased by at least 25% (compared with that seen on previous imaging) on the computed tomographic scan performed 6 weeks later, or if a fall of at least 30% of plasma AFP levels was observed, a second preoperative CE was performed 2 months after the first CE; this cycle was repeated as long as the reducing effect persisted and no contraindication emerged. Resections were perfomed after a mean delay of 45±40 days after the last CE.

CONTROL GROUP

During the 3 previous years (December 1986 to December 1989), 55 patients underwent a resection of HCC without preoperative CE. To form the control group, each patient from the CE group was paired with 1 patient chosen among these 55 patients using 4 criteria: tumor size at time of diagnosis (7.8±1 cm in the CE group vs 7.3±1 cm in the control group), Child-Pugh class (22 patients class A and 2 patients class B in both groups), histology of nontumorous liver (1 normal, 10 fibrous, 13 cirrhotic in both groups), and absence of any contraindication to CE.

DATA COLLECTED

The morbidity of CE was recorded. To assess the antitumoral effect of preoperative CE, the tumor size and AFP levels were measured prior to and after CE. In both groups, intraoperative difficulties and operative duration were collected from the detailed operative notes of surgical resections. The resections in both groups were performed by the same surgeon (J.B.), according to a previously described technique.[8] The requirement for intraoperative and postoperative tranfusions of red blood cells was established and the postoperative morbidity was assessed. Histological examination results of the resection specimen were reviewed. After resection, clinical examinations, liver ultrasonography, and AFP measurements were performed every 3 months during the first 2 years and every 6 months thereafter. Data on recurrences and survival were collected until the fourth year following the liver resection of the last patient included in each group.

STATISTICAL ANALYSIS

The global cumulative survival rates and the cumulative survival rates without recurrence were calculated using the Kaplan-Meier method. Survival curves were compared using the Mantel-Haenszel test. Numeric variables were compared using the Student *t* test, unpaired or paired when adequate. The χ^2 test with Yates correction was used to compare qualitative variables. $P<.05$ was considered significant. Values are expressed as mean±SD.

2-73 000 µg/L) and the CE group (mean, 2560 µg/L; range, 2-46 000 µg/L).

MORBIDITY AND EFFICACY OF CE PRIOR TO RESECTION

One to 4 CEs were performed preoperatively per patient (mean, 1.6±0.2 procedures per patient). Morbidity of CE increased with the number of CEs performed (**Figure 1**). One thrombosis and 1 dissection of the common hepatic artery occurred during a second and a fourth CE, respectively. One thrombosis of the right hepatic arterial branch associated with a decrease of the arterial blood supply of the left side of the liver contraindicated a fourth procedure. One attack of acute cholecystitis following a first CE resolved with conservative therapy. One patient experienced transient ascites associated with a simultaneous 25% fall of prothrombin time following a second course of CE, which did not recur after a subsequent CE. There were no deaths related to CE.

A clinical "post-CE syndrome," defined as a fever of 38.5°C or higher associated with pain of the right upper quadrant warranting analgesic medication, occurred in 9 patients (37%). The mean duration of the hospital stay was 8.5 days.

Overall, preoperative CE did not result in a significant decrease in tumor size (7.8±4.8 cm prior to the first CE vs 7.5±4.6 cm 6 weeks after the last CE). This includes 13 patients in whom tumor size remained unchanged (7.4±5.3 cm), 5 patients in whom tumor size increased (5.2±3.3 cm prior to the first CE vs 7±3.8 cm after the last CE; $P<.01$), and 6 patients in whom the tumor size decreased (10.1±5.3 cm vs 6.6±4.4 cm; $P<.01$). Similarily, mean plasma AFP level was not significantly

©1998 American Medical Association. All rights reserved.
Downloaded From: http://archsurg.jamanetwork.com/ on 12/22/2014

Table 1. Clinical, Biological, and Radiological Data From the 2 Matched Groups*

Characteristic	CE Group (n = 24)	Control Group (n = 24)
Mean ± SD age, y	57 ± 2	54 ± 3
Sex ratio, M/F	21/3	17/7
Alcohol abuse	7	4
Hepatitis B virus	5	6
Hepatitis C virus	2	4
Underlying liver disease	2	1
Hemochromatosis		
Primary biliary cirrhosis	0	1
Unknown	8	1
None	1	1
No. of nodules		
1	15	18
2	6	2
≥3	3	4
Portal branch thrombosis	3	3
Esophageal varices	7	7
Mean ± SD AST level, U/L	76 ± 64	65 ± 55
Mean ± SD ALT level, U/L	66 ± 65	63 ± 51

Data are given as number of patients unless otherwise indicated. The 2 groups were matched using 4 main criteria (see "Patients and Methods" section). There were no significant differences for all secondary criteria listed here. AST indicates aspartate aminotransferase; ALT, alanine aminotransferase; and CE, chemoembolization.

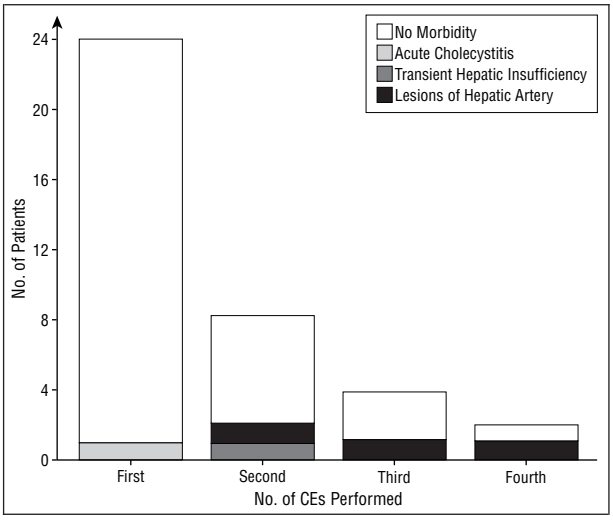

Figure 1. *Morbidity of preoperative chemoembolization (CE) as a function of the number of CEs performed.*

Table 2. Liver Resections: Anatomical Type, Duration of Hepatic Pedicle Inflow Occlusion, Intraoperative Difficulties Encountered, and In-Hospital Mortality*

	CE Group (n = 24)	Control Group (n = 24)
Resection		
Tumorectomy	8	6
1-3 segments	4	8
≥4 segments	12	10
Mean ± SD duration of pedicle inflow occlusion, min	31 ± 3	34 ± 3
Pediculitis	9	0†
Perihepatic adhesions	5	3
Arterial branch thrombosis	3	0
Portal branch thrombosis	3	3
In-hospital mortality	3	2

Data are given as number of patients unless otherwise indicated. The hepatic segments were defined according to the Couinaud classification. Pediculitis was defined by alterations (fibrosis and inflammation) of the connective tissue surrounding the vascular and biliary elements of the hepatic pedicle and complicating their division. Perihepatic adhesions complicating the surgical procedure were listed only if the patient did not undergo previous abdominal surgery. CE indicates chemoembolization.
†P<.05.

reduced by CE (2560±2091 µg/L prior to the first CE vs 1788±1270 µg/L after the last CE). Levels of AFP had decreased in 4 patients, of whom 1 had a reduced tumor size and 3 a stable size tumor. Levels of AFP had increased in 4 patients, of whom 1 had an enlarged tumor and 3 a stable one.

INFLUENCE OF PREOPERATIVE CE ON LIVER RESECTIONS

The extent of resections and the duration of hepatic pedicle inflow occlusion were comparable in the 2 groups (**Table 2**). However, duration of liver resection was significantly longer in the CE group than in the control group (279±20 minutes vs 215±23 minutes; $P<.05$). This was related to a more difficult dissection in the CE group due to inflammatory pediculitis, perihepatic adhesions, or arterial thrombosis (Table 2). These lesions were observed in 7 (44%) of 16 patients who underwent a single preoperative CE and in 7 (88%) of 8 patients who underwent several preoperative CEs ($P=.10$). In 1 of the 3 patients with a thrombosis of the hepatic artery or its first branches, a left hepatectomy was performed instead of the segmentectomy previously planned because of a intraoperative injury to the left bile duct. An injury to the portal vein occured in 1 other patient and was sutured. The number of red blood cell units transfused in the CE group did not differ significantly from that in the control group (1.4±0.5 vs 2.4±1).

Preoperative CE did not alter the postoperative course. Three patients died postoperatively in the CE group (1 of myocardial infarction, 1 of hepatic failure, and 1 of sepsis) and 2 in the control group (both of sepsis). Postoperative ascites affected 11 patients in the CE group vs 12 in the control group. Transient encephalopathy occurred in 1 patient in each group. Temporary renal insufficiency was recorded in 1 patient in the CE group and 3 patients in the control group. A postoperative truncular portal vein thrombosis occurred in 2 patients in the CE group but none of the patients in the control group ($P=.14$).

INFLUENCE OF PREOPERATIVE CE ON TUMOR HISTOLOGY

A comparison of histological examination results of the resected specimens did not demonstrate any difference due to preoperative CE for encapsulation and invasion of the capsule, venous permeation, daughter nodules, and surgical margin. However, tumor necrosis was signifi-

©1998 American Medical Association. All rights reserved.
Downloaded From: http://archsurg.jamanetwork.com/ on 12/22/2014

Table 3. Histological Study of Resected Tumors*

	CE Group (n = 24)	Control Group (n = 24)
Encapsulated tumor	13	16
Invasion of the capsule	4	9
Venous permeation	8	8
Daughter nodules	9	12
Resection margin <0.5 cm	3	3
Tumor necrosis, %†		
None	7	14
<50	8	9
>50	8	1
Complete	1	0

*Data are given as numbers of resected specimens with the studied criteria.

†Tumor necrosis was more frequent and extensive in the chemoembolization (CE) group (P = .03).

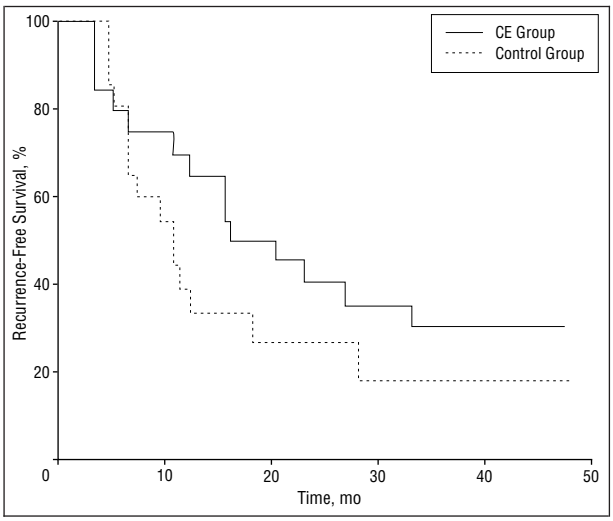

Figure 2. *Cumulative survival rates without recurrence (operative mortality excluded). CE indicates preoperative chemoembolization.*

cantly more frequent and extensive in the CE group (**Table 3**).

INFLUENCE OF PREOPERATIVE CE ON RECURRENCES AND SURVIVAL

A recurrence occurred in 14 patients in each group. These recurrences occurred after a mean delay from the initial resection of 14±9 months in the CE group, longer than the mean delay of 8±4 months observed in the control group ($P = .05$). However, the cumulative recurrence-free survival in patients surviving the first resection was comparable in the 2 groups (**Figure 2**). The locations of these recurrences were comparable in the 2 groups: in the CE group, the recurrences were extrahepatic in 2 patients (1 lung metastasis associated with hepatic recurrence and 1 isolated bone metastasis) and intrahepatic in 10 patients, whereas in the control group, isolated bone metastasis occurred in 2 patients and intrahepatic recurrence in 12 patients. During the follow-up, 6 patients died of recurrence in the CE group and 4 patients died of recurrence in the control group after a

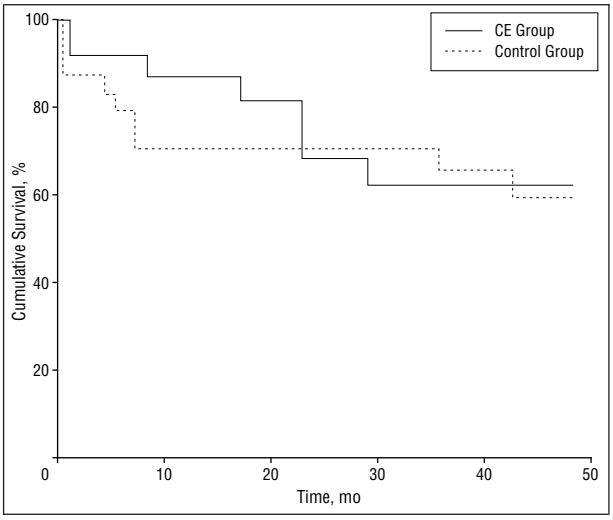

Figure 3. *Cumulative global survival rates (operative mortality included). CE indicates preoperative chemoembolization.*

comparable mean delay from first resection (17±15 months and 14±9 months, respectively). One patient in the control group died of a pancreatic tumor. The cumulative global survival (operative mortality included) was not different in the 2 groups (**Figure 3**). In the CE group, the number of preoperative CEs performed, the preoperative evolution of tumor size or AFP levels, and the extent of tumor necrosis observed on resected specimens did not influence survival and recurrences (data not shown).

COMMENT

Neoadjuvant CE is used by many groups to prevent tumor recurrence following resection of HCC,[13-17] although clear evidence to support this strategy is lacking. Imaoka et al[19] recommended this neoadjuvant treatment on the basis of an uncontrolled retrospective study without establishing appropriate matching of the groups. Hwang et al[13] did not include enough patients to draw definite conclusions. Several retrospective studies[18-22] failed to demonstrate any favorable effect of this neoadjuvant treatment. The only prospective trial available, recently published by Wu et al,[17] did not show any benefit of preoperative CE for large HCC of more than 10 cm (mean, 14.5 cm) frequently involving adjacent organs (40%): resection was not facilitated, recurrence rates were not modified, and survival was even worse in the CE group.

We have therefore designed a retrospective matched-group study to assess the results of preoperative CE used in our center since 1989. Matching was based on criteria (tumor size, Child-Pugh class, and histological characteristics of nontumorous liver) that are considered strong predictors of tumor recurrence and patient survival after resection of HCC.[3,6,15,23,24] The 2 groups also seemed to be well matched for other prognostic factors such as number of HCC nodules,[9,25] portal branch obstruction,[9] and AFP levels.[26] This matching procedure as well as the follow-up of the patients treated by the same

©1998 American Medical Association. All rights reserved.
Downloaded From: http://archsurg.jamanetwork.com/ on 12/22/2014

surgeon during a short period support the validity of this comparative study.

A necrotizing effect of CE has frequently been described, but without comparison to a proper control group,[14,16,21,27] which is essential as spontaneous necrosis of HCC nodules occurs frequently.[28] Tumor necrosis was significantly increased by CE in our study. There was no correlation between the reduction of the tumor size and the extent of necrosis on the resected specimen, as previously reported.[15] The role of tumor necrosis on prognosis remains controversial. The extent of necrosis has never been reported as a favorable prognostic factor[22] and its adverse effect has even been evoked by favoring cell dislodgment into the bloodstream during hepatic resection.[21,29] A tumor-promoting effect of CE on postoperative recurrences was not observed here and has not been reported.[22]

Other pathologic changes attributable to preoperative CE have been assessed on the resected specimen, focusing on previously identified histological prognostic criteria. In contrast to the noncomparative results of Higushi et al,[16] preoperative CE did not promote encapsulation of the resected HCC or the enlargement of the resection margins, both considered favorable prognostic factors.[6,8,25,30-32]

Overall, preoperative CE did not significantly reduce the tumor size in the CE group. However, 5 patients (21%) had a tumor reduction with a mean delay between CE and resection of 1.5 months. This rate of morphologic response has previously been reported by Bismuth et al.[15] Studies from the Far East reported higher rates of tumor reduction,[17,22,27] maybe reflecting differences in tumorous biology.

The post-CE syndrome, with associated fever and abdominal pain, affected 37% of patients. This syndrome is frequently considered to be a manifestation of tumor necrosis,[13,33-35] but we found no correlation with the extent of HCC necrosis in this study. Although there was no CE-related death, a significant morbidity caused by preoperative CE was observed, increasing with repetition of this procedure.[27] Cholecystitis and ascites following CE[4,15,34] were treated medically. Pediculitis, perihepatic adhesions, and arterial lesions significantly increased the difficulties and duration of the resections performed. These lesions, sequelae of tissue ischemia caused by the repeated embolization of hepatic arteries, were previously reported[15,17,27] and are clearly identified in this comparative study. They did not induce an increase in the volume of transfusions but constitute a strong argument against the repetition of these preoperative CEs.

Preoperative CE did not alter the location of the recurrences or improve the cumulative recurrence-free survival. Consequently, there was no significant effect of preoperative CE on the global cumulative survival, confirming some recent studies.[17,18,20-22] It may be argued that the number of CEs performed prior to liver resection may have been insufficient to demonstrate their beneficial influence as a neoadjuvant treatment on recurrence and survival. However, the lack of correlation between the number of CEs performed and the survival observed in this study does not favor this hypothesis.

It seems that preoperative CE of initially resectable HCC, although increasing tumor necrosis and well tolerated when only 1 CE procedure is performed, can complicate surgical resection and does not prevent tumor recurrence, leading us to question the utility of this neoadjuvant therapy.

For initially resectable tumors, there is no available proof of the benefit of this invasive procedure.[36] However, our data demonstrate that a single CE procedure is safe, does not increase the morbidity of the subsequent resection, and induces tumor necrosis. One lipiodolized CE could be therefore performed preoperatively to ensure the detection of additionnal small hepatocellular nodules on a computed tomographic scan performed 2 to 3 weeks later[15,37] and local control of tumor growth until resection. However, this preoperative CE should not be repeated and probably has no significant effect on recurrence and prognosis. This treatment could also allow a safer wait for a graft liver if a liver transplantation is decided on.[38,39] For initially nonresectable tumors, a debulking effect has been reported in some cases, allowing the surgeon to perform secondarily a resection that might improve the prognosis of these patients.[22,40] This volumetric reduction is very inconstant and should be carefully assessed case by case after the first CE. Indeed, the repetition of this procedure can damage the liver and its blood supply and could reduce its functional reserve.[36] Prospective randomized trials should assess the respective merits of these therapeutic options.

Reprints: Jacques Belghiti, MD, Service de Chirurgie Digestive, Hôpital Beaujon, 100 bd du Général Leclerc, 92118 Clichy, France.

REFERENCES

1. Al-Hadeedi S, Choi TK, Wong J. Extended hepatectomy for hepatocellular carcinoma. *Br J Surg*. 1990;77:1247-1250.
2. Franco D, Capussotti L, Smadja C. Resection of hepatocellular carcinomas: results in 72 European patients with cirrhosis. *Gastroenterology*. 1990;98:733-738.
3. Belghiti J. Resection of hepatocellular carcinoma complicating cirrhosis. *Br J Surg*. 1991;78:257-258.
4. Iwatsuki S, Starzl TE, Sheahan DG. Hepatic resection versus transplantation for hepatocellular carcinoma. *Ann Surg*. 1991;214:221-229.
5. Yoshimi F, Nagao T, Inoue S, et al. Comparison of hepatectomy and transcatheter arterial chemoembolization for the treatment of hepatocellular carcinoma: necessity for prospective randomized trial. *Hepatology*. 1992;16:702-706.
6. Nagasue N, Uchida M, Makino Y, et al. Incidence and factors associated with intrahepatic recurrence following resection of hepatocellular carcinoma. *Gastroenterology*. 1993;105:488-494.
7. Nonami T, Isshiki K, Kishimoto W, Harada A, Nakao A, Tagaki H. The potential role of postoperative hepatic artery chemotherapy in patients with high-risk hepatomas. *Ann Surg*. 1990;213:222-226.
8. Belghiti J, Panis Y, Farges O, Benhamou JP, Fekete F. Intrahepatic recurrence after resection of hepatocellular carcinoma complicating cirrhosis. *Ann Surg*. 1991; 214:114-117.
9. Takayashu K, Wakao F, Moriyama N, et al. Postresection recurrence of hepatocellular carcinoma treated by arterial embolization: analysis of prognostic factors. *Hepatology*. 1992;16:906-911.
10. Taniguchi K, Nakata K, Kato Y, et al. Treatment of hepatocellular carcinoma with transcatheter arterial embolization. *Cancer*. 1994;73:1341-1345.
11. Jeng KS, Yang FS, Chiang HJ, Ohta I. Repeat operation for nodular recurrent hepatocellular carcinoma within the cirrhotic liver remnant: a comparison with transcatheter arterial chemoembolization. *World J Surg*. 1992;16:1188-1192.
12. Kanematsu T, Matsumata T, Shirabe K, et al. A comparative study of hepatic resection and transcatheter arterial embolization for the treatment of primary hepatocellular carcinoma. *Cancer*. 1993;71:2181-2186.

©1998 American Medical Association. All rights reserved.
Downloaded From: http://archsurg.jamanetwork.com/ on 12/22/2014

13. Hwang TS, Chen MF, Lee TY, Chen TJ, Lin DY, Liaw YF. Resection of hepatocellular carcinoma after transcatheter arterial embolization: reevaluation of the advantages and disadvantages of preoperative embolization. *Arch Surg*. 1987; 122:756-759.
14. Shimamura Y, Gunvén P, Takenaka Y, et al. Combined peripheral and central chemoembolization of liver tumors. *Cancer*. 1988;61:238-242.
15. Bismuth H, Morino M, Sherlock D, et al. Primary treatment of hepatocellular carcinoma by arterial chemoembolization. *Am J Surg*. 1992;163:387-394.
16. Higushi T, Kikushi M, Okazaki M. Hepatocellular carcinoma after transcatheter hepatic arterial embolization. *Cancer*. 1993;73:2259-2267.
17. Wu C, Ho Y, Ho W, Liu T, P'eng F. Preoperative transcatheter arterial chemoembolization for resectable large hepatocellular carcinoma: a reappraisal. *Br J Surg*. 1995;82:122-126.
18. Nagasue N, Galizia G, Kohno H, et al. Adverse effects of preoperative chemoembolization for resectable hepatocellular carcinoma: a retrospective comparison of 138 liver resections. *Surgery*. 1989;106:81-86.
19. Imaoka S, Sasaki Y, Shibata T, et al. A preoperative chemoembolization therapy using lipiodol cisplatin and gelatin sponge for hepatocellular carcinoma. *Cancer Chemother Pharmacol*. 1989;23:S126-S128.
20. Monden M, Okamura J, Sakon M, et al. Significance of transcatheter chemoembolization combined with surgical resection for hepatocellular carcinomas. *Cancer Chemother Pharmacol*. 1989;23:S90-S95.
21. Adachi E, Matsumata T, Nishisaki T, Hashimoto H, Tsuneyoshi M, Sugimashi K. Effects of preoperative transcatheter hepatic arterial chemoembolization for hepatocellular carcinoma. *Cancer*. 1993;72:3593-3598.
22. Harada T, Matsuo K, Inoue T, Tamesue S, Inoue T, Nakamura I. Is preoperative chemoembolization safe and effective for hepatocellular carcinoma? *Ann Surg*. 1996;224:4-9.
23. Nagao T, Inoue S, Yoshimi F, et al. Postoperative recurrence of hepatocellular carcinoma. *Ann Surg*. 1990;211:28-33.
24. Okuda K, Ohtsuhi T, Obata H, et al. Natural history of hepatocellular carcinoma and prognosis in relation to treatment: study of 850 patients. *Cancer*. 1985;56: 918-928.
25. Jwo SC, Chiu JH, Chau GY, Loong CC, Lui WY. Risk factors linked to tumor recurrence of human hepatocellular carcinoma after hepatic resection. *Hepatology*. 1992;16:1367-1371.
26. Belghiti J. Resection hépatique chez le cirrhotique. In: Belghiti J, Gillet M, eds. *La Chirurgie Digestive chez le Cirrhotique: Rapport du 93éme Congrès Français de Chirurgie*. Paris, France: Springer-Verlag; 1993:113-129.
27. Yu YQ, Xu DB, Zhou XD, Lu JZ, Tang ZY, Mack P. Experience with liver resection after hepatic arterial chemoembolization for hepatocellular carcinoma. *Cancer*. 1993;71:62-65.
28. Imaoka S, Sasaki Y, Matsutani S, et al. Necrosis of hepatocellular carcinoma caused by spontaneously arising arterial thrombus. *Hepatogastroenterology*. 1994;41: 359-362.
29. Liou TC, Shih SC, Kao CR, Chou SY, Lin SC, Wang HY. Pulmonary metastasis of hepatocellular carcinoma associated with transarterial chemoembolization. *J Hepatology*. 1995;23:563-568.
30. Ng IO, Lai EC, Ng MM, Fan ST. Tumor encapsulation in hepatocellular carcinoma: a pathologic study of 189 cases. *Cancer*. 1992;70:45-49.
31. Yoshida Y, Kanematsu T, Matsumata T, Takenaka K, Sugimashi K. Surgical margin and recurrence after resection of hepatocellular carcinoma in patients with cirrhosis. *Ann Surg*. 1989;209:297-301.
32. Matsumata T, Kanematsu T, Takenaka K, Sugimashi K. Lack of intra-hepatic recurrence of hepatocellular carcinoma by temporary portal venous embolisation with starch microspheres. *Surgery*. 1989;105:188-191.
33. Groupe d'Etude et de Traitement du Carcinome Hépatocellulaire. A comparison of lipiodol chemoembolization and conservative treatment for unresectable hepatocellular carcinoma. *N Engl J Med*. 1995;332:1256-1261.
34. Chung JW, Park JH, Han JK, et al. Hepatic tumors: predisposing factors for complications of transcatheter oily chemoembolization. *Radiology*. 1996;198:33-40.
35. Castells A, Bruix J, Ayuso C, et al. Transarterial embolization for hepatocellular carcinoma: antibiotic prophylaxis and clinical meaning of post-embolization fever. *J Hepatol*. 1995;22:410-415.
36. Uchida M, Kohno H, Kubota H, et al. Role of preoperative transcatheter arterial oily chemoembolization for resectable hepatocellular carcinoma. *World J Surg*. 1996;20:326-331.
37. Portolani N, Tiberio AM, Bonardelli S, et al. Arterial chemoembolization in hepatocellular carcinoma suitable for surgery. *Hepatogastroenterology*. 1996;43: 1566-1574.
38. Pilchmayr R, Weinmann A, Steinhoff G, Ringe B. Liver transplantation for hepatocellular carcinoma: clinical results and future aspects. *Cancer Chemother Pharmacol*. 1992;31:S157-S161.
39. Mazzaferro V, Regalia E, Doci R, et al. Liver transplantation for the treatment of small hepatocellular carcinomas in patients with cirrhosis. *N Engl J Med*. 1996; 334:693-699.
40. Sitzmann JV, Abrams R. Improved survival for hepatocellular cancer with combination surgery and multimodality treatment. *Ann Surg*. 1993;217:149-154.

IN OTHER AMA JOURNALS

ARCHIVES OF INTERNAL MEDICINE

Duration of Estrogen Replacement Therapy in Relation to the Risk of Incident Myocardial Infarction in Postmenopausal Women

Susan R. Heckbert, MD, PhD; Noel S. Weiss, MD, DrPH; Thomas D. Koepsell, MD, MPH; Rozenn N. Lemaitre, PhD, MPH; Nicholas L. Smith, MPH; David S. Siscovick, MD, MPH; Danyu Lin, PhD; Bruce M. Psaty, MD, PhD

Background.—There is little information about whether an increasing duration of estrogen replacement therapy is associated with a declining risk for myocardial infarction in postmenopausal women.
Objective.—To conduct a population-based, case-control study among enrollees of the Group Health Cooperative (GHC) of Puget Sound, Seattle, Wash.
Subjects and Methods.—Case subjects were all postmenopausal women who were enrolled in the GHC with an incident fatal or nonfatal myocardial infarction from July 1986 through December 1993. Control subjects were a stratified random sample of postmenopausal women who were enrolled in the GHC without myocardial infarction and matched to case subjects by age and calendar year. We reviewed the medical records of the 850 case subjects and 1974 control subjects and conducted telephone interviews with consenting survivors. Use of estrogen or estrogen and progestin was assessed using GHC's computerized pharmacy database.
Results.—Among women who were currently using estrogen, a longer duration of use was inversely associated with a risk for myocardial infarction after adjustment for age, year of identification, diabetes mellitus, angina, and smoking. For categories of increasing duration of estrogen use (never, >0-<1.8 years, 1.8-<4.2 years, 4.2-<8.2 years, and ≥8.2 years), the odds ratios for myocardial infarction were 1.00 (reference), 0.91, 0.70, 0.65, and 0.55 (for trend among the current users, $P=.05$). Among women who had used estrogen in the past, there was no evidence of decreasing risk with increasing duration of estrogen use.
Conclusion.—In this study, a long duration of hormone replacement therapy among women currently using estrogen was associated with a reduced risk for first myocardial infarction. *Arch Intern Med. 1997;157:1330-1336*

Reprints: Susan R. Heckbert, MD, PhD, Cardiovascular Health Research Unit, Metropolitan Park, East Tower, Suite 1360, 1730 Minor Ave, Seattle, WA 98101-1448.

©1998 American Medical Association. All rights reserved.
Downloaded From: http://archsurg.jamanetwork.com/ on 12/22/2014