PAPER

Role of Bronchial Artery Embolization in the Management of Hemoptysis

Hiran C. Fernando, FRCS; Moni Stein, MD; John R. Benfield, MD; Daniel P. Link, MD

Objective: To assess the modern morbidity of hemoptysis and the contribution of therapeutic bronchial artery embolization to its management.

Methods: Medical record review of patients admitted for the treatment of hemoptysis from January 1991 to November 1995 and of patients who had therapeutic bronchial artery embolization from June 1986 to August 1995. Hemoptysis was labeled major or minor.

Results: A total of 138 patients were admitted with hemoptysis, 31 with major and 107 with minor hemoptysis. No emergency pulmonary resections were required. Mean follow-up was 13.5 months. Mortality was 29.7% (41/138) but was caused by bronchial bleeding in only 4.3% (6/138). Twenty-six patients underwent therapeutic bronchial artery embolization (mean follow-up [range], 14 months [0.3-69.0 months]). The initial success rate (no further bleeding during the initial admission) was 85% (22/26). The long-term success rate (no further bleeding during follow-up) was 58% (15/26). Only 2 patients with therapeutic bronchial artery embolization died of further hemoptysis.

Conclusions: Hemoptysis signals life-threatening diseases. Therapeutic bronchial artery embolization is a good treatment adjunct to control bronchial bleeding and reduces the need for high-risk emergency lung resections.

Arch Surg. 1998;133:862-866

From the Divisions of Cardiothoracic Surgery (Drs Fernando and Benfield) and Interventional Radiology (Drs Stein and Link), University of California, Davis, Medical Center, Sacramento.

THE DEFINITION of massive hemoptysis and the incidence of cancer as a cause for pulmonary bleeding have ranged widely (**Table 1**). Pulmonary resection to treat massive hemoptysis has been associated with the best results, but postoperative death rates have been about 40% when operations were undertaken as emergencies (**Table 2**). In relatively recent years, therapeutic bronchial artery embolization (TBAE) has been added to the treatment options available for the control of hemoptysis.[6] The rationale for TBAE is that the higher-pressured systemic pulmonary circulation (bronchial arteries) is often the source of major hemoptysis. This reasoning is based in part on evidence that inflammatory lung disease and lung cancer enhance the systemic circulation in areas of decreased pulmonary circulation and that hemoptysis occurs secondary to the rupture of systemic arteries in areas of inflamed or necrotic tissue.[7] Recent information about the effects of TBAE on the management of hemoptysis, however, is limited. Therefore, we have evaluated the role that TBAE occupied in our treatment of hemoptysis in recent years.

RESULTS

One hundred thirty-eight patients were admitted to the University of California, Davis, Medical Center for the treatment of hemoptysis during the 5-year period covered in this study. These patients included 31 who had major and 107 who had minor hemoptysis. Fifty-eight patients had active inflammatory disease, including bronchitis, pneumonia, cystic fibrosis, and mycobacterial and fungal infections. Thirty-eight patients had neoplasms, 15 patients had bronchiectasis, and in 5 patients, bleeding was due to pulmonary hypertension. Other causes for hemoptysis in the 22 remaining patients included autoimmune vasculitis (n = 2), pulmonary embolus (n = 2), coagulopathy (n = 2), laryngeal lesions (n = 3), idiopathic thrombocytopenic purpura (n = 1), arteriovenous malformation (n = 1), stimulant-induced pulmonary toxicity (n = 1), bronchial stump bleeding after lung resection (n = 1), and 9 patients with an indeterminate cause. The distribution of the aforementioned diseases as causes for major or minor hemoptysis is shown in the **Figure**. Neoplasms accounted for 11 (35%) of 31 patients with major hemoptysis.

©1998 American Medical Association. All rights reserved.
Downloaded From: http://archsurg.jamanetwork.com/ on 05/23/2015

PATIENTS AND METHODS

DEFINITIONS

Major hemoptysis was defined as 1 or more of the following: bleeding 200 mL or more per 24 hours, bronchial blood loss that caused hemodynamic or respiratory compromise, or bleeding that resulted in a hematocrit of less than 0.30 (<30%). *Technically successful* TBAE denotes that following embolization, radiological evidence of the cessation of blood flow in the desired target vessels was seen at angiography. *Initial success* means that bleeding stopped after TBAE without recurrence during the remainder of the hospital admission. *Long-term success* denotes that patients who had TBAE had no further hemoptysis during their entire period of follow-up.

PATIENTS

The medical records of all patients admitted for the treatment of hemoptysis, including those who had TBAE from January 1991 to November 1995, were reviewed. The medical records of all patients who had TBAE from June 1986 to August 1991 were also reviewed. Follow-up information was obtained by direct contact with patients or by medical records review.

THERAPEUTIC BRONCHIAL ARTERY EMBOLIZATION

Our method of TBAE has been described in detail.[7] Briefly, the transfemoral approach was used to pass a 5F or 6F catheter into the descending thoracic aorta to catheterize the appropriate bleeding bronchial artery selectively. Whenever feasible, a 3F catheter was introduced in a coaxial manner and advanced as distally as possible in the target vessel where the embolization was performed. Therapeutic bronchial artery embolization was undertaken using absorbable gelatin sponge (Gelfoam) pledgets, Hilal coils (Look Inc, Bloomington, Ind), or polyvinyl alcohol particles. The Hilal coils and polyvinyl alcohol particles were sometimes used together, with the larger Hilal coils (usually 2-5 mm) placed proximally and the smaller polyvinyl alcohol particles (usually 300-500 µm) injected distally into the abnormal bleeding vessels.

Table 1. Major Hemoptysis Caused by Neoplastic Disease

Source, y	Major Hemoptysis, mL/24 h	Patients, No.	Incidence of Neoplasms, %*
Bobrowitz et al,[1] 1983	100	113	NA
Knott-Craig et al,[2] 1993	200	120	5.0
Present study, 1998	≥200	31	35.5
Cremaschi et al,[3] 1991	300	209	3.8
Conlan et al,[4] 1983	600	123	4.8
Gourin and Garzon,[5] 1974	600	62	3.2

*NA indicates not available.

Table 2. Results of Lung Resections as Treatment of Hemoptysis

Source, y	Patients, No.	Postoperative Mortality Rate, No. of Deaths/No. of Resections (%): Overall	After Emergency Operations*
Gourin and Garzon,[5] 1974	55	10/55 (18.2)	7/19 (36.8)
Bobrowitz et al,[1] 1983	31	4/31 (12.9)	NA
Conlan et al,[4] 1983	34	6/34 (17.6)	NA
Knott-Craig et al,[2] 1993	42	3/42 (7.1)	3/7 (42.9)

*NA indicates not available.

Treatment with appropriate medications and observation was the mainstay of therapy for 109 of 138 patients. From 1991 to 1995, the following invasive therapies were used for 29 patients: bronchoscopic methods such as balloon tamponade or laser heater probe application to bleeding sites (n = 14), angiography with therapeutic intent (n = 18), and elective pulmonary resections (n = 3). In some patients, more than 1 invasive type of treatment was used.

Among 138 patients treated for hemoptysis, the overall long-term death rate was 29.7%. Fourteen patients (10.1%) died during the initial hospital stay, and 27 (19.6%) died later of causes other than bleeding. Continued hemoptysis was the cause of death in only 6 patients, or 4.3%. All 6 of these patients had neoplasms that were too advanced for an operation, and all died during the initial hospital stay. Other causes of death were pneumonia, congestive heart failure, and renal failure.

Of 124 patients who left the hospital, follow-up was possible in only 105 patients (84.7%) for a mean duration of 13.5 months (range, 2 days to 56 months). During follow-up, 27 additional patients died of various diseases; none of these deaths was due to further hemoptysis.

Three patients had elective pulmonary resections. One patient with advanced lung cancer died of pneumonia following pneumonectomy. Another patient with extensive scarring from bronchiectasis who had TBAE on 3 occasions died of intraoperative hemorrhage. The third patient had successful completion of pneumonectomy after a prior lobectomy for fibrosing alveolitis following radiotherapy for a lymphoma.

From 1986 to 1995, angiography with therapeutic intent was undertaken in 31 patients. This included 26 patients who had a technically successful TBAE and 5 patients whose TBAE could not be completed. Failure to accomplish TBAE was due to the inability to catheterize the desired bronchial arteries in 4 patients who had advanced neoplasms and in 1 patient whose alcoholic liver disease was associated with coagulopathy and a hemorrhagic lung cyst. Death occurred in 4 of the 5 patients, none of whom would have benefited from an operation. One patient had successful control of bronchial bleeding with endobronchial laser treatment of lung cancer after TBAE had failed.

©1998 American Medical Association. All rights reserved.
Downloaded From: http://archsurg.jamanetwork.com/ on 05/23/2015

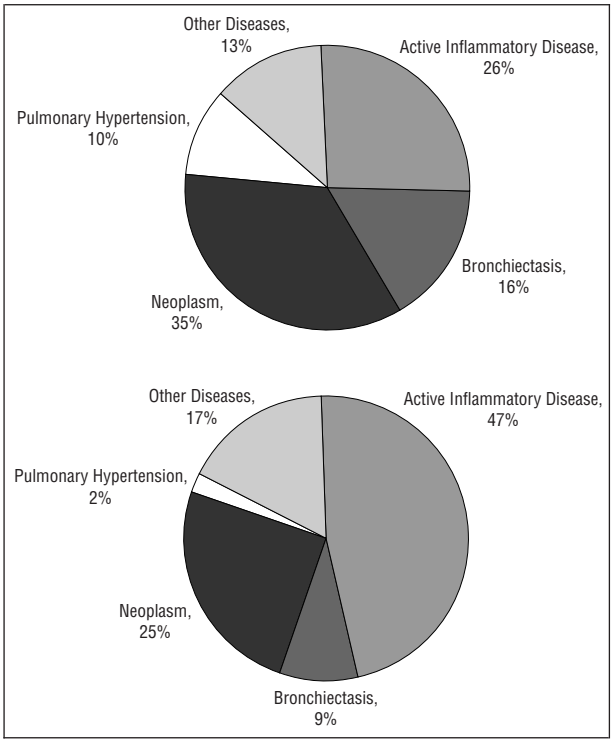

The distribution of diseases causing bronchial bleeding for both major (top; 31 patients) and minor (bottom; 107 patients) hemoptysis. Note the high incidence of neoplasms as a cause.

Among the 26 patients who had technically successful TBAE, there were 23 with major bleeding and 3 with minor bleeding. Bleeding sites were localized by angiography in 17 patients (65.4%), including 16 patients with bleeding that had been localized by bronchoscopy and 1 patient in whom bleeding from aspergillosis had been localized by chest radiography before TBAE. During the initial hospital stay, 1 patient died of pneumonia, and another, who had advanced recurrent cancer, died of persistent hemoptysis. The only angiographic complication was a small splenic infarct caused by nontarget embolization of a coil into a peripheral splenic arterial branch.

Among 24 patients who left the hospital after TBAE, follow-up was available for 22 patients with a mean duration of 14 months (range, 1 day to 69 months). The patient with the shortest duration of follow-up after discharge from the hospital had bilateral obstructive endobronchial carcinoma; he died of massive recurrent hemoptysis the day after hospital discharge and 7 days after TBAE had temporarily stopped his bleeding. Hemoptysis recurred in 11 patients at a mean of 5.1 months, including 4 patients whose rebleeding occurred during the initial hospital admission. Thus, our initial success rate was 85% (22/26), and our long-term success rate was 58% (15/26).

When bleeding recurred after TBAE, it was less severe than the initial hemoptysis in 4 patients and of a similar magnitude in 7. In 1 patient with bronchiectasis, rebleeding was from a new site in the other lung 51 months after the first episode. Treatment of the 11 patients who had recurrent hemoptysis after TBAE included a second embolization in 4 patients and a third embolization in 1 patient who then successfully underwent an operation electively. The remaining 6 patients who rebled were managed using endoscopic methods (n = 2) or by nonoperative means (n = 4).

In total, 9 patients among the 26 who had TBAE subsequently died. Deaths were due to hemoptysis in only 2 patients, who represented 7.6% of our experience with TBAE.

Table 3. Mortality After Hospital Admission With Hemoptysis

Source, y	Patients, No.	Type of Hemoptysis	Patients Operated on, No.	Hospital Mortality, No. (%)
Gourin and Garzon,[5] 1974	62	Major only	55	15 (24)
Conlan et al,[4] 1983	120	Major only	34	28 (23)
Knott-Craig et al,[2] 1993	120	Major only	42	12 (10)
Hirshberg et al,[10] 1997	208	All	18	19 (9)
Present study, 1998	138	All	3	14 (10)

COMMENT

The purpose of our study was to evaluate the modern morbidity associated with hemoptysis and to evaluate possible trends in outcome as a result of increasing availability of intensive care units and specialists. The cited common causes of major hemoptysis have been bronchitis, tuberculosis, and bronchiectasis.[8,9] As seen in Table 1, cancer has rarely been acknowledged as a cause of major hemoptysis. In our experience, neoplasms accounted for 27.5% of all bronchial bleeding and 35.5% of major hemoptysis. During the 5-year study period, 10.1% of our patients died during their initial hospital admission and 29.7% died during the entire follow-up. **Table 3** summarizes mortality data from both our study and selected representative articles. Although the overall mortality of hemoptysis remains high, exsanguination from bronchial bleeding has become uncommon; only 4.3% of our patients (all with advanced neoplasms) died of continued bronchial bleeding.

When bronchopulmonary bleeding can be localized to a single area, pulmonary resection has been associated with the best results. For example, operations apparently reduced the mortality from 54% to 18%[5] and from 31.8% to 17.6%.[4] More recently, a South African report[2] of 120 patients demonstrated a 7.1% mortality for those patients who had undergone an operation compared with 11.5% mortality for those patients managed nonoperatively. Furthermore, in patients managed nonoperatively, 36.4% had massive recurrent hemoptysis compared with no rebleeding in the group who had undergone operations. Thus, there is convincing evidence that the resection of bleeding areas in the lungs is an overall effective treatment with a mortality rate of 7% to 18%. As summarized in Table 2, however, the mortality of pulmonary resection increases significantly to about 40% when undertaken emergently. Therefore, we think it is

©1998 American Medical Association. All rights reserved.
Downloaded From: http://archsurg.jamanetwork.com/ on 05/23/2015

best to undertake operations for hemoptysis in a planned, unhurried manner whenever circumstances permit. This is consistent with the way in which we used TBAE and the fact that all operations we performed were elective.

In our experience, pulmonary angiography never provided the only way to localize bleeding sites. This is consistent with the report by Saumench et al[11] in which the bleeding site was identified in 68% of patients by bronchoscopy compared with only 55% by angiography. Angiographic signs of pulmonary hemorrhage include extravasation of contrast media, hypervascularization, abnormal arborization of bronchial arteries, systemic-pulmonary shunts, and bronchial artery aneurysms.[7] In our experience, angiographic evidence of bleeding was present in only 17 (65.4%) of our 26 patients who had TBAE. In all of our patients, bleeding sites were localized by other means before angiography. We recommend bronchial angiography when embolization is intended and not for the sole purpose of localizing bleeding sites. Using this policy, we were able to stop bleeding in 85% of our patients with the first TBAE, and 58% of our patients had no recurrence of bleeding during follow-up. Conversely stated, our initial failure rate was about 15.4%, and 42.3% of patients had recurrent bleeding following hospital discharge. Other studies[3,6,12,13] have demonstrated rebleeding rates between 16% and 21% after TBAE. Because none of these authors reported their duration of follow-up, their results likely reflect what we have termed initial success rate and their findings and ours are likely entirely consistent with one another.

Therapeutic bronchial artery embolization is but one of several ways to manage major hemoptysis. In some patients, endoscopic fulguration with or without use of a laser may be best. For some patients, pulmonary resection may be the treatment of choice, and sometimes irradiation may be recommended. We do not intend to address the overall issue of the management of hemoptysis in this report. Instead, we have presented evidence that TBAE is an effective adjunct in the management of bronchial bleeding that can be used to stop bronchial bleeding in the short term, thus replacing high-risk emergency operations with safer elective pulmonary resections.

Presented at the 69th Annual Session of the Pacific Coast Surgical Association, Maui, Hawaii, February 18, 1998.

Reprints: John R. Benfield, MD, Division of Cardiothoracic Surgery, University of California, Davis, Medical Center, 4301 X St, Sacramento, CA 95817-2214.

REFERENCES

1. Bobrowitz ID, Ramakrishna S, Shim YS. Comparison of medical versus surgical treatment of major hemoptysis. *Arch Intern Med.* 1983;143:1343-1346.
2. Knott-Craig CJ, Oostuizen JG, Rossouw G, Joubert JR, Barnard PM. Management and prognosis of massive hemoptysis. *J Thorac Cardiovasc Surg.* 1993; 105:394-397.
3. Cremaschi P, Nascimbene C, Vitulo P, et al. Therapeutic embolization of bronchial artery: a successful treatment in 209 cases of relapse hemoptysis. *Angiology.* 1993;44:295-299.
4. Conlan AA, Hurwitz SS, Krige L, Nicolau N, Pool R. Massive hemoptysis: review of 123 cases. *J Thorac Cardiovasc Surg.* 1983;85:120-124.
5. Gourin A, Garzon AA. Operative treatment of massive hemoptysis. *Ann Thorac Surg.* 1974;18:52-60.
6. Uflacker R, Kaemmerer A, Neves C, Picon RD. Management of massive hemoptysis by bronchial artery embolization. *Radiology.* 1983;146:627-634.
7. Tan RT, McGahan JP, Link DP, Lantz BMT. Bronchial artery embolization in the management of hemoptysis. *J Intervent Radiol.* 1991;6:67-76.
8. Benfield JR. Surgical treatment of hemoptysis. *West J Med.* 1991;155:407-408.
9. Cahill BC, Ingbar DG. Massive hemoptysis: assessment and management. *Clin Chest Med.* 1994;15:147-168.
10. Hirshberg B, Biran I, Glazer M, Kramer M. Hemoptysis: etiology, evaluation, and outcome in a tertiary referral hospital. *Chest.* 1997;112:440-444.
11. Saumench J, Escarrabill J, Padro L, Montana J, Clariana A, Canto A. Value of fiberoptic bronchoscopy and angiography for diagnosis of the bleeding site in hemoptysis. *Ann Thorac Surg.* 1989;48:272-274.
12. Katoh O, Kishikawa T, Yamada H, Matsumoto S. Recurrent bleeding after arterial embolization in patients with hemoptysis. *Chest.* 1990;97:541-546.
13. Zhang J, Cui Z, Wang M, Yang L. Bronchial arteriography and transcatheter embolization in the management of hemoptysis. *Cardiovasc Intervent Radiol.* 1994; 17:276-279.

DISCUSSION

Anees J. Razzouk, MD, Loma Linda, Calif: Massive hemoptysis constitutes a medical emergency that may be associated with a variety of bronchopulmonary neoplastic, inflammatory, infectious, traumatic, or congenital conditions. Patients with nontraumatic major hemoptysis have a high mortality. Currently, the management of hemoptysis may be medical, surgical, endobronchial, endovascular, or any combination of these modalities. For the past 25 years, transcatheter hemostatic techniques have been used to control massive, life-threatening, or repeated hemoptysis. Dr Fernando and colleagues are commended for addressing "the modern morbidity of hemoptysis" and attempting to define the role of TBAE in the management of hemoptysis. On the one hand, this report is a retrospective review of their experience with 26 patients having TBAE from 1986 to 1995; on the other hand, it is limited to patients treated for hemoptysis between 1991 and 1995. I am sure the authors have their reasons for this odd mixing and unusual grouping of 2 patient populations!

Thirty-one patients with major hemoptysis were managed between 1991 and 1995. At least 2 patients were treated medically, and 29 patients had 1 or more forms of invasive therapy (eg, balloon tamponade, laser application, or surgery), including 18 patients who underwent angiography with therapeutic intent. Also, 3 patients in this entire series with minor hemoptysis underwent TBAE. This leads to my first question: What is the role of TBAE in the management of hemoptysis? What are your indications for performing TBAE as opposed to another therapy? Does the amount of bleeding or the underlying lesions responsible for bleeding determine the type of treatment? How many of the 26 patients treated with TBAE were actually bleeding at the time of the procedure?

Systemic nonbronchial vessels—eg, internal thoracic artery, intercostal arteries, phrenic artery—have been recognized as important collaterals and a significant source of bronchial bleeding. Did you perform angiography of nonbronchial arteries? If so, when?

Were there any patients who got TBAE where (1) the bleeding site localized nonangiographically was in a different site than that seen on angiography, or vice versa; and (2) the bronchial arteries looked normal?

How often did you visualize the spinal artery? How did that alter your embolization procedure?

Adnan Cobanoglu, MD, Portland, Ore: The message I get from this presentation is that therapeutic embolization of the bronchial artery gives an initial success rate of 85%, and thus, these patients can be stabilized, temporized, and the operation, if necessary, done in a more elective manner. There is a significant rate of recurrent bleeding in these patients during long-term follow-up. It is close to 50%, so clearly one has to keep a close eye on these patients during that hospital admis-

©1998 American Medical Association. All rights reserved.
Downloaded From: http://archsurg.jamanetwork.com/ on 05/23/2015

sion and later on, but still, to temporize and plan an elective and well-organized operation is of great benefit.

In reviewing the authors' paper, I noted that 5 patients with pulmonary hypertension in the overall series of patients presented with hemoptysis. Was bronchial artery embolization attempted in any of these patients? If so, was it successful? My second question is related to patients previously deemed as having advanced carcinoma and having been turned down for surgical intervention for their cancer. What is your approach to these patients when they are admitted with hemoptysis at times reaching your level of more than 200 mL of blood per day? Do you proceed with therapeutic embolization in these patients or any other surgical approach?

Jack H. Bloch, MD, Bakersfield, Calif: Like many good papers, this one raises a series of interesting questions, and I have 3. The first is, could you tell us a little more about your current algorithm for the management of patients with massive hemoptysis as has been pointed out by Dr Razzouk? At what point do you entertain the idea that this is the right time for an embolization? If you have a patient who is bleeding fairly massively and on bronchoscopy there is too much blood in the airway to accurately localize even where to put a balloon or to do any topical treatment, will angiography show you with any reliability the point of the target vessel that is bleeding and be accurate enough to allow the embolization?

My second question is, in a patient with a high-risk lesion, a carcinoma, or a cavity that shows an initial minor hemoptysis, is the minor hemoptysis a sentinel bleed? For example, does it say that one had better act fairly rapidly to prevent a major hemoptysis, or can we continue to temporize with minor hemoptysis?

The third question is, how risky is bronchial artery embolization? I have a difficult time in convincing our interventional radiologists to embolize a bronchial artery. They have been carefully taught that the artery of Adamkiewicz frequently arises immediately opposite the bronchial artery and, even with visualization of the major blood supply to the spinal cord, inadvertent embolization could create a spinal cord disaster and litigation. Is bronchial artery embolization within the capability of the average interventional radiologist, or do you have people with special skills that allow you to use this more frequently than some of the rest of us might be able to?

Ralph W. Aye, MD, Seattle, Wash: Could you clarify the role of this technique in a benign inflammatory process that is chronic? Is this ever considered definitive treatment, or is it only temporizing?

Philip C. Jolly, MD, Seattle: I would point out that major life-threatening hemoptysis is no longer commonly seen. In earlier times when there was a large reservoir of patients with cavitary tuberculosis that was beyond surgical treatment, major hemoptysis was often the cause of death. Also, the population of patients with bronchiectasis has declined, probably because of the common use of antibiotics. There still is a group of patients with inflammatory cavitary disease. These are usually immunosuppressed patients, and they often have an atypical form of tuberculosis that is not as receptive to antibiotic chemotherapy. In these patients, the cavity is often invaded by *Aspergillus*. In my experience, the best way of treating this group of patients is by resection, but you need to have a clear airway to do it safely. I think that this form of embolization is an excellent way to achieve that.

In patients with unresectable lung cancers who do bleed, would the authors rely on embolization as the primary mode of therapy, or would they first attempt to control the bleeding by using an endobronchial laser?

Dr Benfield: I would like first to address Dr Jolly's comment. He said that massive hemoptysis has become less common, and that is certainly true in the United States where tuberculosis and bronchiectasis are no longer common. Several years ago, I had the privilege of visiting South America where I was asked to discuss our experience with hemoptysis. In South America, the experience with massive hemoptysis remains extensive. Hemoptysis from tuberculosis and bronchiectasis is still extraordinarily common in less-advantaged societies, whereas in our environment it has become uncommon. That change is manifested in part by the fact that so many of our patients had cancer, and relatively few of them had bronchiectasis.

Dr Razzouk asked why our report described experience with 26 TBAE procedures, only some of which occurred from 1991 to 1995. This was simply a matter of record keeping. We had complete records regarding all patients admitted with hemoptysis from 1991 onward. Before 1991, we had to rely on the personal records of the angiographers who worked with us, and these served only to identify patients who had TBAE and not to find patients with hemoptysis. All of the patients from 1991 to 1995 are included in the overall group of TBAE patients. Dr Razzouk also wondered what the indications are for the use of TBAE. When patients had bronchoscopy, bleeding persisted, and it appeared to be either already life-threatening or likely to become life-threatening, the next step was angiography with the intent to do transbronchial arteriography. Bronchoscopy is still the mainstay of the diagnosis and treatment of massive hemoptysis. In no instance did angiography provide the only way for locating the site of the bleeding. In each instance, it was bronchoscopy that identified the site of bleeding.

Dr Cobanoglu addressed the issue of rebleeding. When bleeding recurred after TBAE, it was invariably less than it had been previously. Therefore, the embolization had in each case been of some benefit, at least transiently. There is an exception to this statement, and that is the group of patients with pulmonary hypertension. When pulmonary hypertension was the cause of hemoptysis, then transbronchial arterial embolization did not regularly work effectively.

The issue of how far to go in trying to stop bleeding in patients with far-advanced cancer is a difficult one that is not limited to patients with lung cancer. This is simply a matter of the best available judgment of the surgeons, physicians, patients, and patients' families at the time decisions are needed. I don't have any good answers to that question.

Dr Bloch wondered what the algorithm is. The algorithm begins with airway control and hemodynamic stabilization. Next, it proceeds to bronchoscopy, including the use of endobronchial balloons, if necessary, for tamponading. I do not use bronchial dividers or double-lumen endotracheal tubes for the treatment of hemoptysis because I find that the small lumen on the tracheal divider is awkward at best in an intensive care unit. The next step is bronchial artery embolization. If necessary, elective or semielective pulmonary resection is the next step.

Another question Dr Bloch asked was about the risk of transbronchial embolization and whether this procedure is available in any hospital by any good angiographer. This has been, in our hands, a safe procedure. We have had no spinal complications. We have had only 1 splenic infarct. We are, indeed, blessed with angiographers who have a particular interest in this area and who have special expertise. I think that TBAE by competent angiographers is probably safe to do. The risks of major hemoptysis are so great that the risks of angiography or transbronchial embolization can be justified.

Dr Aye asked, is this a temporizing or a definitive procedure? I would say it is a temporizing procedure, and the definitive procedure is either resection or continued nonoperative treatment to take care of the underlying problem, be it cancer or an inflammatory disease.

©1998 American Medical Association. All rights reserved.
Downloaded From: http://archsurg.jamanetwork.com/ on 05/23/2015