PAPER

Results of Treatment of Inferior Vena Cava Syndrome With Expandable Metallic Stents

William S. Fletcher, MD; Paul C. Lakin, MD; Rodney F. Pommier, MD; Thea Wilmarth

Background: Patients with hepatic metastases often develop obstruction of the intrahepatic inferior vena cava (IVC), known as IVC syndrome. This obstruction is debilitating due to the development of ascites and anasarca.

Objectives: To update our experience in the diagnosis and treatment of IVC syndrome and to evaluate the efficacy of expandable stents in the treatment of IVC syndrome.

Design: Retrospective review.

Setting: University hospital.

Patients: Twenty-eight patients with hepatic metastases diagnosed as having IVC syndrome.

Intervention: Patients underwent transfemoral placement of Gianturco-Rösch self-expandable Z metallic stents in the intrahepatic IVC. One patient was treated with a Wallstent. Stents were 15 to 25 mm in diameter and 60 to 140 mm in length. Pressure gradients across the IVC were measured before and after stent placement in all patients.

Main Outcome Measures: Change in pressure gradient, relief of ascites and anasarca, loss of weight, patency of the primary stent, and survival after stent placement.

Results: Pressure gradients were reduced in all patients, which was followed by rapid reduction of ascites and anasarca with a median weight loss of 5.85 kg. Survival after stent placement varied from 1 to 99 days, with a mean of 34 days. Stent patency remained until death in all patients.

Conclusion: The debilitation of IVC syndrome due to ascites and anasarca can be considerably palliated by placement of transfemoral percutaneous stents.

Arch Surg. 1998;133:935-938

From the Section of Surgical Oncology, Departments of Surgery (Drs Fletcher and Pommier and Ms Wilmarth) and Interventional and Diagnostic Radiology (Dr Lakin), Oregon Health Sciences University, Portland.

In a previous study,[1] we described the inferior vena cava (IVC) syndrome caused by intrahepatic constriction of the vena cava by primary, or more commonly, metastatic malignant neoplasms. This condition results in a combination of signs and symptoms, the most noticeable and disabling of which is the rapid onset of ascites and anasarca of the lower extremities, which can be differentiated from other causes of edema by its occurrence only below the diaphragm. Hepatomegaly may be present but is difficult to assess owing to ascites. The ascites and edema are poorly responsive to diuretic use, and proteinuria may be present as a result of back pressure on the renal veins. The results of inferior venacavography routinely reveal intrahepatic compression of the vena cava, often with increased development of collateral vessels depending on the duration and severity of the obstruction. Pressure gradients across the constricted area are variable but are usually 20 mm Hg, which appears to be the pressure required to induce the symptom complex.

Patients in the original study[1] (1976-1986) were treated with systemic chemotherapy, hepatic artery infusion with 5-fluorouracil, and in some cases with a strip of irradiation along the intrahepatic vena cava.[1] Sixteen patients responded to therapy with complete or partial remission and 17 patients did not respond to therapy. All the patients died of malignant neoplasms except for one patient with hemangioendothelioma who remains alive and healthy 12 years after treatment.

Since 1989, we have treated IVC syndrome with percutaneous, transfemorally placed self-expanding metallic stents. Others[2-5] documented that patency and initial technical success can be achieved in major venous obstruction with the placement of self-expanding, metallic stents.

©1998 American Medical Association. All rights reserved.
Downloaded From: http://archsurg.jamanetwork.com/ on 10/10/2015

PATIENTS, MATERIALS, AND METHODS

Between 1989 and l997, 28 patients were evaluated and treated for IVC syndrome. There were 17 women aged 45 to 82 years (median age, 61 years) and 11 men aged 38 to 70 years (median age, 56 years). All patients had documented stage IV cancer. Of the 28 patients, 26 (93%) had documented leg edema and in 2 patients, the information was not recorded. Of the 28 patients, 19 (68%) had documented ascites, 8 did not have documented information, and 1 patient had no ascites. The following 9 primary tumor types were represented among the patients: breast (8), melanoma (7), colonic (3), pancreatic (3), esophageal (3), gastrointestinal stromal tumor (1), gastric (1), liver (1), and ovarian (1).

All stents were placed in the intrahepatic vena cava using a percutaneous, transfemoral approach. The stents were placed through a 12F to 16F Teflon sheath as described previously.[6] Inferior venacavography and manometry were performed before and after stent placement. Twenty-seven of the stents were Gianturco-Rösch self-expandable Z metallic stents (Cook, Bloomington, Ind), and 1 was a Wallstent (Schneider [USA] Inc, Plymouth, Minn). The length of the stent varied from 60 to 140 mm, and the diameter varied from 15 to 25 mm. The diameter of the stent appears not to be critical to the reduction in pressure gradient. The centrifugal force of the stent holds it in place, and there have been no stent migrations once the stent is seated in the cava.

Outcomes were evaluated by reduction in pressure gradient, weight loss, survival, and, when possible, stent patency. All but one of the patients studied were patients of one of us (W.S.F.). **Figure 1** demonstrates vena caval compression by tumor, stent placement in the intrahepatic vena cava, and subsequent relief of constriction of the vena cava. The pressure gradient dropped from 8 to 1 mm Hg.

Survival rates were calculated by the Kaplan-Meier method.[7] Comparison of survival distributions was made by log-rank analysis.

This article updates our experience in the diagnosis and treatment of IVC syndrome and evaluates the results of treatment with expandable metallic stents.

RESULTS

Data on pressure gradient reduction are provided in **Table 1**. Successful stent placement was due to the perserverance of the operating radiologist and sometimes required the placement of several stents for the management of long or tortuous constrictions. Pressure gradients across the caval constriction before stent placement varied from 6 to 25 mm Hg, and pressure gradients after stent placement varied from 0 to 13 mm Hg.

Due to the patient's condition, accurate pretreatment and posttreatment weight and abnormal girth measurements were not always available. However, we observed that patients underwent a dramatic reduction in ascites and lower extremity edema with concomitant improvement in breathing, eating, and mobility. **Table 2** provides data on the 12 patients who were weighed and whose weights were recorded before stent placement and 6 to 9 days after stent placement. Weight loss varied from 1.35 to 10.35 kg (median, 5.85 kg). There was a marked increase in urine output. There were no instances of overt heart failure from the massive fluid shifts resulting from placement of the stents.

Patients did not undergo repeated angiography to determine patency of the stents, so only indirect evidence of stent patency was available. Patients who have vena cava occlusion above the renal veins experience sudden anuria and death within a few days. Since the patients did not have this clinical picture and had other documented progression of their disease to account for death, the stents were considered patent.

Survival ranged from 1 to 99 days. The overall mean survival was 34 days (median, 27.5 days). In women, the mean survival was 30 days (median, 22 days). Men survived slightly longer, with a mean survival of 40.5 days (median, 43 days).

Two patients experienced complications: 1 man had a thrombus that required an additional stent placement on the day following the initial stent, and 1 woman had a pulmonary embolus 3 days following stent placement that was successfully managed with anticoagulant therapy.

Figure 2 depicts the overall survival of all evaluable patients who received intrahepatic caval stents. The mean survival was 34 days and the median survival was 27.5 days. **Figure 3** depicts the survival of patients with caval gradients above and below 15 mm Hg. There is no significant difference.

COMMENT

There is no question that stents remove the pressure gradient in the vena cava and reduce the symptoms of ascites and anasarca of the lower extremities. Bedridden patients can often regain activity, and this improvement in the quality of life is enough to warrant further study of the problem. Although difficult to quantitate in this study, the benefits in the quality of life were sudden and dramatic in most patients. The improvements included massive weight loss, improvement in or disappearance of ascites, reduction in ankle edema, and improvement in breathing and eating. With these changes, there was a marked improvement in the patient's perceived state of well-being. Major objectives of future studies should be earlier diagnosis and improved survival. The study of patients with these complicated problems and with many variables to document would best be done in a controlled clinical research environment.

Ultimately, it will be necessary to evaluate the cost-benefit relationship of the described treatment. However, the purposes of this phase 1 study are to draw attention to the syndrome and describe a new effective treatment. We hope that as more physicians recognize IVC syndrome and more centers develop the capability

©1998 American Medical Association. All rights reserved.
Downloaded From: http://archsurg.jamanetwork.com/ on 10/10/2015

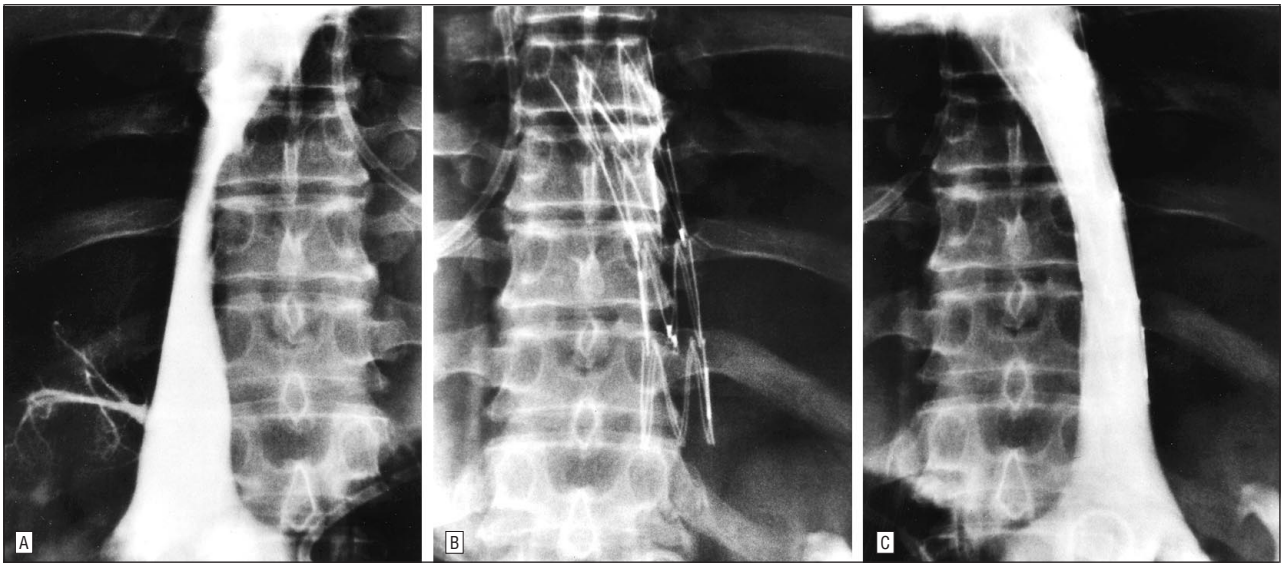

Figure 1. *Intrahepatic inferior vena cava (IVC) compression secondary to esophageal adenocarcinoma metastatic to the liver in a 48-year-old man. A, Inferior venacavogram in this man with ascites and pitting edema of the lower extremities demonstrates a fusiform stenosis of the intrahepatic IVC. B, A 4-body self-expanding metallic stent (25 mm in diameter and 10 mm in length) was positioned in the IVC. C, Follow-up venacavogram demonstrates excellent restoration of flow. A 1–mm Hg residual pressure gradient remains from the IVC to the right atrium. There was significant improvement in both the ascites and the pedal edema until the patient's death.*

Table 1. Reduction in Pressure Gradient After Inferior Vena Caval Stents*

Gradient Pressure, mm Hg			
Before Stent	After Stent	Change	Percent Change, %
11	3	8	73
20	3	17	85
11	1	10	91
6	1	5	83
11	0	11	100
13	1	12	92
13	1	12	92
9	0	9	100
24	9	15	63
11	7	4	36
13	1	12	92
18	12	6	33
20	9	11	55
14	4	10	71
21	0	21	100
18	8	10	55
10	4	6	60
7	2	5	71
20	8	12	60
16	13	3	19
11	9	2	18
12	0	12	100
25	4	21	84
18	3	15	83
19	4	15	79
12	0	12	100
8	2	6	75
10	0	10	100

**The total number of stents placed in the inferior vena cava was 28.*

of stent placements, factors such as optimum patient selection, therapy for the primary disease, and costs will become more clear.

Table 2. Reduction in Weight After Inferior Vena Caval Stent Placement*

Weight Before Stent Placement, kg	Weight After Stent Placement, kg	Weight Lost, kg
81.00	79.65	1.35
61.65	59.40	2.25
60.30	57.15	3.15
83.70	80.10	3.60
78.75	74.25	4.50
83.25	77.40	5.85
72.45	66.60	5.85
65.70	59.40	6.30
98.10	91.80	6.30
114.30	107.10	7.20
109.35	100.35	9.00
89.10	78.75	10.35

**The total number of patients weighed was 12; median weight loss, 5.85 kg; and mean weight loss, 5.40 kg.*

The patients described in this study were drawn from a population of patients with heavily treated end-stage cancer. The syndrome was recognized because the patients were being seen frequently to undergo chemotherapy or other treatment. Clearly, although earlier diagnosis might improve survival, it may not be possible without unwarranted invasive procedures. In our experience, diagnosis of the described syndrome using ultrasonography has not been reliable, and the results of venacavography are required. Treatment at an earlier phase of disease would also allow the use of systemic agents, which are effective if they shrink the tumor enough to relieve the pressure on the vena cava. We hope that the use of new chemotherapeutic agents will also improve survival. The most important factor in diagnosis and survival is being aware of IVC syndrome and performing venacavography when new ascites and leg edema occur.

©1998 American Medical Association. All rights reserved.
Downloaded From: http://archsurg.jamanetwork.com/ on 10/10/2015

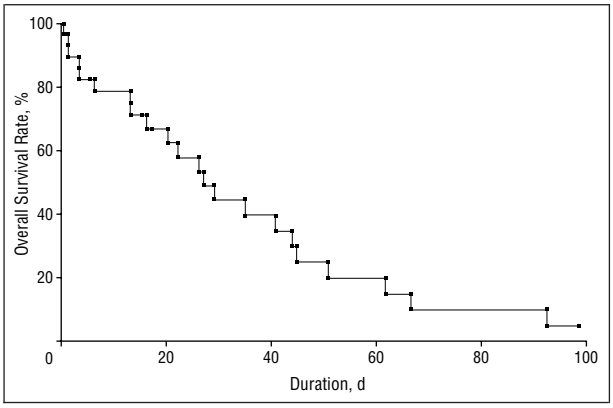

Figure 2. *Overall survival of the 28 patients.*

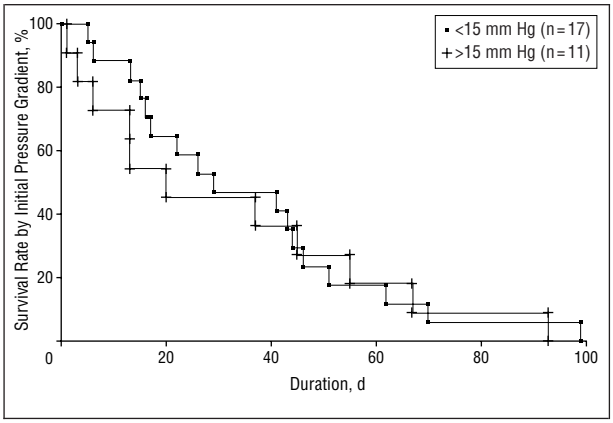

Figure 3. *Survival by initial pressure gradient.*

CONCLUSIONS

Constriction of the intrahepatic vena cava by primary or, more commonly, metastatic malignant neoplasms causes the rapid onset of ascites and anasarca below the diaphragm. We term this condition IVC syndrome. The increased caval pressure and its sequelae can be promptly relieved by transfemoral placement of self-expanding metallic stents into the intrahepatic vena cava. Pressure gradients across the constriction are promptly reduced to normal or near normal levels with resolution of ascites and edema. Survival after placment of the stents ranged from 1 to 99 days in this population of patients with end-stage cancer who had frequently undergone chemotherapy or other therapy. Improved survival may be anticipated with greater awareness of the syndrome and earlier diagnosis as well as the use of better systemic agents for control of the tumor.

This article was written with financial support from the Oregon Chapter, Order of Eastern Star, Portland.

Presented as a poster at the 69th Annual Session of the Pacific Coast Surgical Association, Maui, Hawaii, February 16, 1998.

Reprints: William S. Fletcher, MD, Section of Surgical Oncology, CR145, Oregon Health Sciences University, 3181 SW Sam Jackson Park Rd, Portland, OR 97201-3098 (e-mail: fletchew@ohsu.edu).

REFERENCES

1. Hartley JW, Awrich AE, Wong J, Stevens K, Fletcher WS. Diagnosis and treatment of the inferior vena cava syndrome in advanced malignant disease. *Am J Surg.* 1986;152:70-74.
2. Furui S, Sawada S, Irie T, et al. Hepatic inferior vena cava obstruction: treatment of two types with Gianturco expandable metallic stents. *Radiology.* 1990;176:655-670.
3. Furui S, Sawada S, Kuramoto K, et al. Gianturco stent placement in malignant caval obstruction: analysis of factors for predicting the outcome. *Radiology.* 1995;195:147-152.
4. Oudkerk M, Heystraten FMJ, Stoter G. Stenting in malignant vena caval obstruction. *Cancer.* 1993;71:142-146.
5. Irving JD, Dondelinger RF, Reidy JF, et al. Gianturco self-expanding stents: clinical experience in the vena cava and large veins. *Cardiovasc Intervent Radiol.* 1992;15:328-333.
6. Lakin PC. Venous thrombolysis and stenting. In: Baum S, Pentecost MJ, eds. *Abrams' Angiography: Interventional Radiology.* Boston, Mass: Little Brown & Co Inc; 1996:1046-1057.
7. Kaplan E, Meier P. Nonparametric estimation from incomplete observations. *J Am Stat Assoc.* 1958;53:457-481.

Announcement

The *Archives of Surgery* will give priority review and early publication to seminal works. This policy will include basic science advancements in surgery and critically performed clinical research.

©1998 American Medical Association. All rights reserved.
Downloaded From: http://archsurg.jamanetwork.com/ on 10/10/2015