Image of the Month

Hiroka Kondo, MD; Kensuke Adachi, MD, PhD

A 76-YEAR-OLD MAN WITH A 2-YEAR HISTORY of chronic intermittent epigastric pain presented to our hospital. He was afebrile and had a few episodes of nausea and vomiting. His medical history was unremarkable with no previous abdominal surgery. Laboratory and physical test results revealed no abnormalities. An abdominal computed tomographic scan with intravenous contrast showed a cluster of small intestinal loops in the right upper abdomen and anterolateral displacement of the superior mesenteric artery and vein in the free edge of the hernia sac (**Figure 1**A). Subsequently, upper gastrointestinal contrast studies also demonstrated a circumscribed ovoid mass containing the small intestine loop in the sac (Figure 1B). The patient refused surgery at that time because his symptoms spontaneously disappeared. One year later, he developed severe colicky abdominal pain and was vomiting. An emergency laparotomy was performed.

Author Affiliations: Department of Surgery, Tokyo Metropolitan Tama Medical Center, Japan.

What Is the Diagnosis?

A. Left paraduodenal hernia.
B. Right paraduodenal hernia.
C. Foramen of Winslow hernia.
D. Transomental hernia.

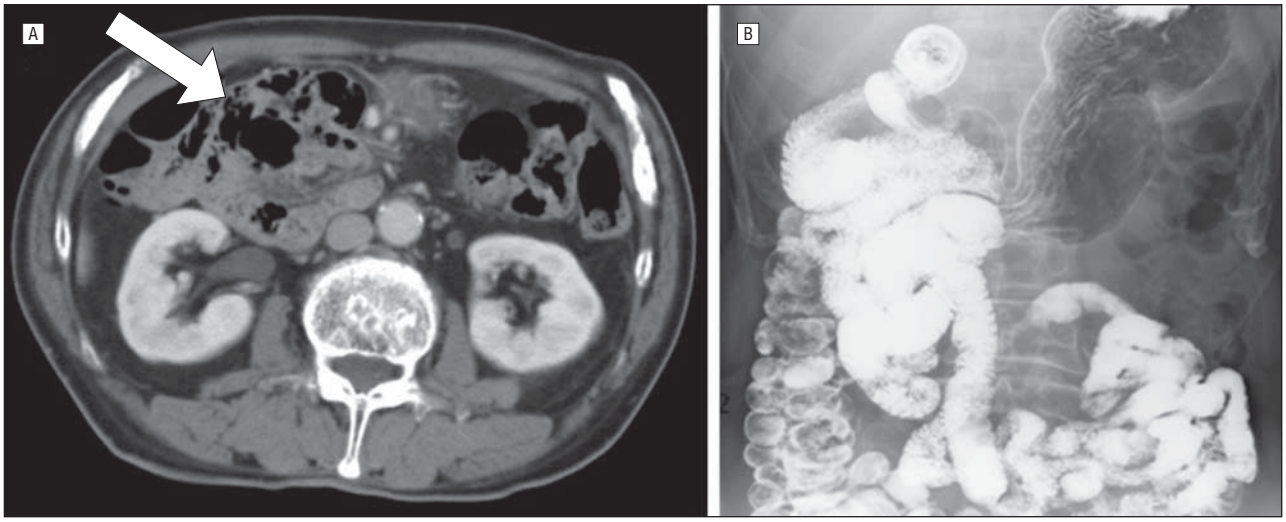

Figure 1. A, An abdominal computed tomographic scan with intravenous contrast showing a cluster of small intestinal loops in the right upper abdomen as well as anterolateral displacement of the superior mesenteric artery and vein in the free edge of the hernia sac. B, Upper gastrointestinal series also demonstrated a circumscribed ovoid mass containing the small intestine loop in the sac. The cecum was in the normal position, but the horizontal part of the duodenum was absent.

©2012 American Medical Association. All rights reserved.
Downloaded From: http://archsurg.jamanetwork.com/ on 05/24/2016