Image of the Month

Eric C. Nelson, MD; George R. Thompson III, MD; Tamas J. Vidovszky, MD

A 53-YEAR-OLD AFRICAN AMERICAN MAN PRESENTED with abdominal bloating and pain over 3 weeks. Intermittent nausea and vomiting was associated with the pain and he lost about 11 kg over the past 3 months despite good appetite. Three months prior, he had several weeks of dry cough and was diagnosed with walking pneumonia. This was treated with antibiotics and resolved. The patient had no medical problems and was human immunodeficiency virus (HIV) negative. He had an umbilical hernia repaired many years ago and did not take any medications. He did not smoke. He worked doing home construction in central California.

On examination, the patient had normal vital signs and appeared well. His abdomen was distended with a fluid wave and he had mild right upper quadrant tenderness but no rebound, guarding, or masses. Chemistry, complete blood cell count, and liver function test findings were significant only for mild anemia. Results of an upper endoscopy were normal. Computed tomography of his abdomen and pelvis demonstrated studding of his peritoneal lining (**Figure 1**) and large ascites as well as a 2-cm nodule in his right lower lobe. Chest computed tomography demonstrated no further abnormalities and the lesion was biopsied under computed tomographic guidance with findings of "granulomatous disease." A paracentesis aspirated 1.4 L of serous ascitic fluid that showed numerous lymphocytes but pathology and culture results were negative. The patient then underwent diagnostic laparoscopy with peritoneal biopsy with findings as shown in **Figure 2**.

Author Affiliations: Department of Surgery (Drs Nelson and Vidovszky) and Division of Infectious Diseases, Department of Internal Medicine, University of California, Davis, Medical Center (Dr Thompson), University of California, Davis, Sacramento, and Department of Medical Microbiology and Immunology, Coccidioidomycosis Serology Laboratory, University of California, Davis, Davis (Dr Thompson).

What Is the Diagnosis?

A. Adenocarcinomatosis of unknown primary origin
B. Disseminated coccidioidomycosis
C. Peritoneal tuberculosis
D. Primary peritoneal mesothelioma

Figure 1. Peritoneal studding on the anterior wall of the abdomen seen during laparoscopy.

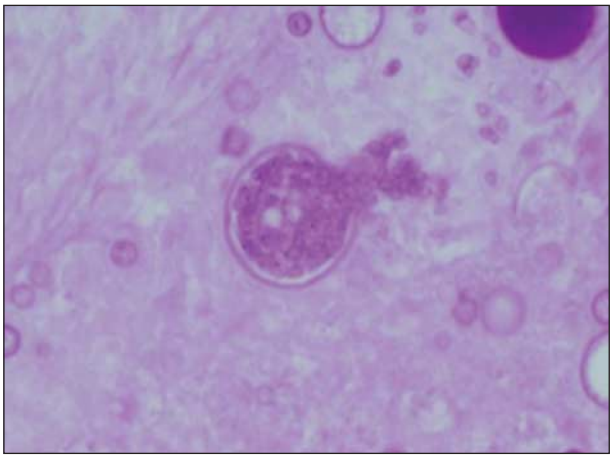

Figure 2. Pathology specimen of peritoneal biopsy.

©2012 American Medical Association. All rights reserved.
Downloaded From: http://archsurg.jamanetwork.com/ on 07/24/2014