Answer

PNET of the Pancreas

Exploratory laparotomy revealed a huge infiltrating solid mass, likely arising from the stomach or the pancreatic body and tail (not clearly detectable). An en bloc resection of the tumor was accomplished with a total gastrectomy, a subtotal splenopancreatectomy, and a resection of the transverse colon. On macroscopic evaluation (**Figure 2**), the mass measured 33 × 29 × 16 cm and infiltrated a wide area of the pancreatic parenchyma, which was almost totally replaced by neoplastic tissue. The neoplasm was composed of nests of monomorphic epithelium-like cells. Immunohistochemistry revealed a consistent cell membrane labeling with CD99 and vimentin. On conventional cytogenetic analysis, a rearrangement of the Ewing sarcoma breakpoint region 1 (*EWSR1*) gene on 22q12 was proven. The reverse transcription–polymerase chain reaction assay results for the most common translocations involving the *EWSR1* gene (*EWS/FLI-1*, *EWS/FEV*, *EWS/ETV1*, *EWS/FLI-4*, *EWS/ERG*, and *EWS/ETV4*) were negative. The histological, immunohistochemical, and cytogenetic aspects were consistent with the diagnosis of a PNET of the pancreas. The patient underwent adjuvant chemotherapy and, 9 month after surgery, was alive and doing well, with no signs of local or distant recurrence.

Primitive neuroectodermal tumors, previously known as neuroblastomas, are extremely rare small round cell neoplasms that originate from primitive neuroepithelial stem cells.[1] They are identified as part of the Ewing sarcoma family of tumors because they harbor the same cytogenetic abnormality involving the *EWSR1* gene on 22q12, namely the chromosomal translocation t(11;22)(q24;q12) creating the *EWS/FLI-1* fusion gene.[2] They usually occur in childhood and adolescence, and, in the majority of cases, they originate in the peripheral nervous system and soft tissue of the thorax, the pelvis, and the lower extremities; occasionally, they originate in the solid organs containing neuroendocrine cells (such as the pancreas, kidney, ovary, and uterus).[3] To our knowledge, except for the present case, there have been only 14 reports of pancreatic PNETs, accounting for approximately less than 0.5% of all primary pancreatic tumors.[4,5] These tumors highly express the glycoprotein CD99. These tumors had the characteristic *EWS/FLI-1* fusion gene in 85% to 90% of cases.[1] At present, there is no established therapeutic strategy[6]; the reported 5-year survival rate for individuals with a PNET is approximately 50%.[1] Surgical resection has been accomplished whenever possible (85% of patients), and 40% of patients underwent a chemotherapy regimen. The present case is the largest pancreatic PNET ever identified; besides having histological and immunohistochemical aspects similar to 1 of the 2 cases reported by Lüttges et al,[4] our patient first presented (2 months before the diagnosis of the abdominal mass) with bilateral exophthalmos (without endocrine or intracranial alterations) that was significantly reduced after surgery so that it could probably be considered a paraneoplastic syndrome with an unknown mechanism.

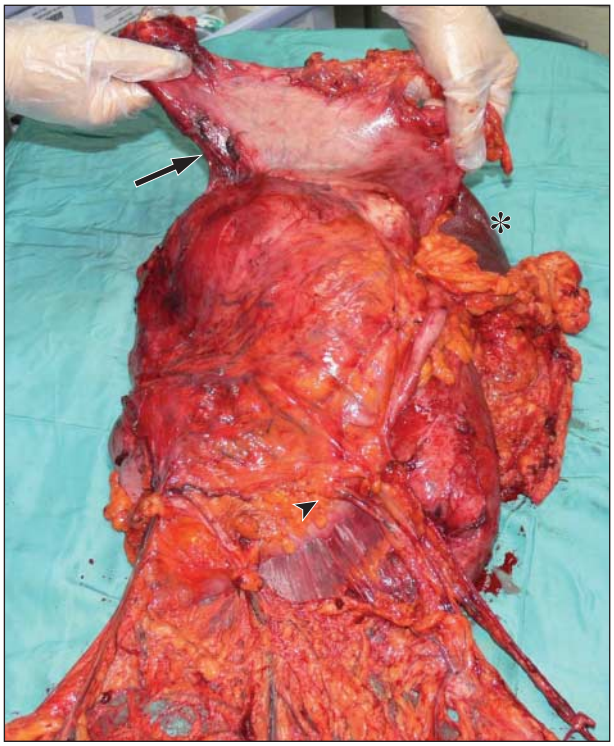

Figure 2. Tumor excised en bloc with the stomach (arrow), the transverse colon (arrowhead), the body and tail of the pancreas (not recognizable), and the spleen (asterisk).

Accepted for Publication: October 28, 2012.
Correspondence: Antonio Pio Tortorelli, MD, Digestive Surgery Division, Department of Surgical Sciences, Catholic University, School of Medicine, Largo A. Gemelli, 8, Rome 00168, Italy (dr_aragorn78@yahoo.it).
Author Contributions: *Study concept and design:* Tortorelli, Alfieri, and Doglietto. *Acquisition of data:* Tortorelli, Sanchez, and Rosa. *Drafting of the manuscript:* Tortorelli and Sanchez. *Critical revision of the manuscript for important intellectual content:* Alfieri, Rosa, and Doglietto. *Statistical analysis:* Tortorelli. *Administrative, technical, and material support:* Alfieri, Sanchez, and Rosa. *Study supervision:* Doglietto.
Conflict of Interest Disclosures: None reported.

REFERENCES

1. Movahedi-Lankarani S, Hruban RH, Westra WH, Klimstra DS. Primitive neuroectodermal tumors of the pancreas. *Am J Surg Pathol.* 2002;26(8):1040-1047.
2. Perek S, Perek A, Sarman K, Tuzun H, Buyukunal E. Primitive neuroectodermal tumor of the pancreas. *Pancreatology.* 2003;3(4):352-356.
3. Welsch T, Mechtersheimer G, Aulmann S, et al. Huge primitive neuroectodermal tumor of the pancreas. *World J Gastroenterol.* 2006;12(37):6070-6073.
4. Lüttges J, Pierré E, Zamboni G, et al. Malignant non-epithelial tumors of the pancreas [in German]. *Pathologe.* 1997;18(3):233-237.
5. Shorter NA, Glick RD, Klimstra DS, Brennan MF, Laquaglia MP. Malignant pancreatic tumors in childhood and adolescence. *J Pediatr Surg.* 2002;37(6):887-892.
6. Doi H, Ichikawa S, Hiraoka A, et al. Primitive neuroectodermal tumor of the pancreas. *Intern Med.* 2009;48(5):329-333.

©2012 American Medical Association. All rights reserved.
Downloaded From: http://archsurg.jamanetwork.com/ on 05/06/2015