REVIEW ARTICLE

Irreversible Electroporation for the Ablation of Liver Tumors

Are We There Yet?

Kevin P. Charpentier, MD

Objective: To explore irreversible electroporation (IRE) as a novel, nonthermal form of tissue ablation using high-voltage electrical current to induce pores in the lipid bilayer of cells, resulting in cell death.

Data Sources: PubMed searches were performed using the keywords electroporation, IRE, and ablation. The abstracts for the 2012 meetings of both the American Hepato-Pancreato-Biliary Association and the Society for Interventional Radiology were also searched. All articles and abstracts with any reference to electroporation were identified and reviewed.

Study Selection: All studies and abstracts pertaining to electroporation.

Data Extraction: All data pertaining to the safety and efficacy of IRE were extracted from preclinical and clinical studies. Preclinical data detailing the theory and design of IRE systems were also extracted.

Data Synthesis: Preclinical studies have suggested that IRE may have advantages over conventional forms of thermal tumor ablation including no heat sink effect and preservation of the acellular elements of tissue, resulting in less unwanted collateral damage. The early clinical experience with IRE demonstrates safety for the ablation of human liver tumors. Short-term data regarding oncologic outcome is now emerging and appears encouraging.

Conclusion: Irreversible electroporation is likely to fill a niche void for the ablation of small liver tumors abutting a major vascular structure and for ablation of tumors abutting a major portal pedicle where heat sink and collateral damage must be avoided for maximum efficacy and safety. Studies are still needed to define the short-term and long-term oncologic efficacy of IRE.

Arch Surg. 2012;147(11):1053-1061

Metastatic colorectal cancer (MCRC) represents the most common indication for liver resection.[1,2] Five-year survival may be as high as 60% following liver resection for MCRC.[3-5] Unfortunately, only 10% to 20% of patients with MCRC are candidates for potentially curative liver resection.[2] Improved survival and quality of life have been reported in patients with unresectable MCRC treated with radiofrequency ablation (RFA) compared with patients treated with chemotherapy alone.[4,6-9]

Thermal ablation in the future liver remnant may also be used in combination with surgical resection to get more patients to a potentially curative resection when all sites of disease are not amenable to surgical resection alone.[4,10] Ablation alone or in combination with resection has been reported for the treatment of liver metastases from various primary tumor sites including breast,[11-15] testicular,[12] neuroendocrine,[12] and renal,[11-13] as well as melanoma[11,13] and sarcoma.[11-13,16]

Thermal ablation has also proven effective for the treatment of primary liver cancer. The pathologic complete response rate of RFA for the treatment of small (<3 cm) hepatocellular carcinoma (HCC) in selected patients is approximately 65%.[17,18] The results of microwave ablation and RFA for the treatment of HCC appear equivalent.[19]

See Invited Critique at end of article

Several significant limitations exist with thermal ablation. First, optimal results with thermal ablation are achieved for the treatment of small tumors (<3 cm).[20] Complete pathologic response rates following RFA fall to 10% to 25% when tumor size exceeds 3 cm.[17,18] Berber et al[7] reported an improvement in median survival following RFA for the treatment of unresectable MCRC when treating tumors less than

Author Affiliations: University Surgical Associates and Alpert Medical School, Brown University, Providence, Rhode Island.

©2012 American Medical Association. All rights reserved.
Downloaded From: http://archsurg.jamanetwork.com/ on 09/04/2015

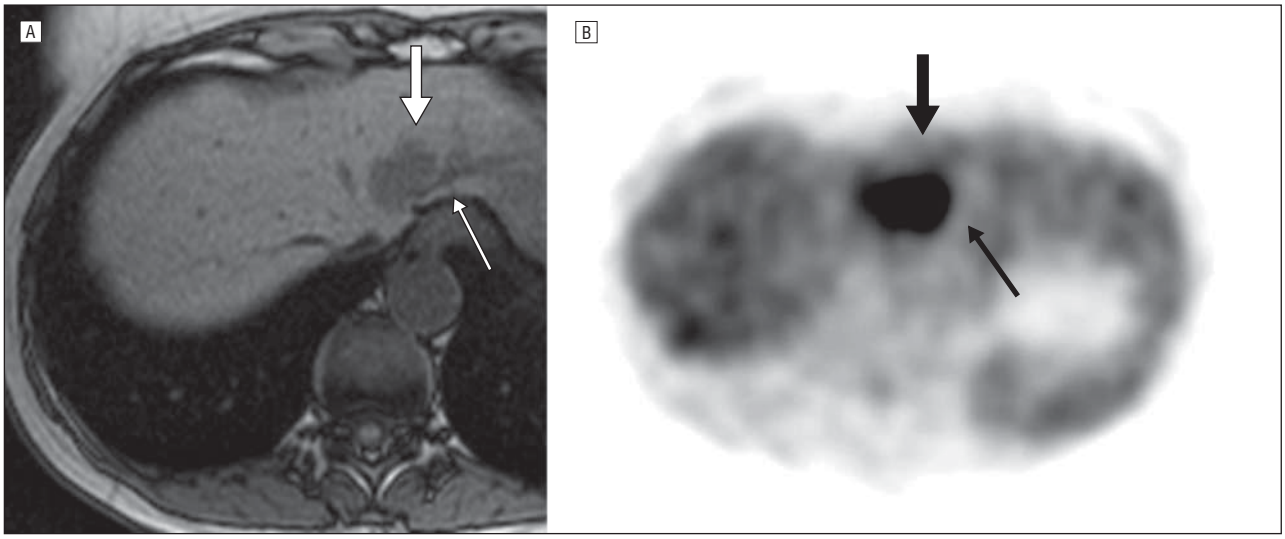

Figure 1. Local failure of thermal ablation owing to heat sink. A 67-year-old woman presented with left-sided colon cancer and synchronous, bilobar liver metastases. Following resection of the colon primary, she was treated with 8 cycles of leucovorin, fluorouracil, and oxaliplatin, as well as bevacizumab (Avastin). She was deemed unresectable owing to concerns about functional liver reserve and was treated by microwave ablation of tumors in segments 7 and 4a. A, The tumor in segment 4a (thick arrow) measuring 2.7 cm and abutting the left hepatic vein (thin arrow). B, Positron-emission tomographic scan image depicting increased fluorodeoxyglucose activity (thick arrow) in segment 4a, consistent with residual tumor adjacent to the left hepatic vein (thin arrow). Heat sink was implicated as a possible contributing cause of the residual disease. She is alive 3 years after initial diagnosis.

3 cm vs those greater than 3 cm (38 months vs 21 months, respectively). Siperstein et al[8] also showed a trend toward improved median survival following RFA of unresectable hepatic metastases less than 3 cm vs those greater than 3 cm (28 months vs 20 months, respectively).

Second, thermal ablation relies on the ability to heat the target tissue to 60°C for instantaneous cell death.[21] The inability to reach the target temperature for effective ablation of tumors abutting a large vein (heat sink) represents another major limitation of thermal ablation.[22] Tumors adjacent to the hepatic veins, large portal veins, and inferior vena cava are at greatest risk for incomplete tumor necrosis and local recurrence owing to heat sink (**Figure 1**).

Finally, thermal ablation carries a risk for collateral damage to normal structures adjacent to the desired zone of ablation (**Figure 2**).[23,24]

METHODS

PubMed searches were performed using the keywords electroporation, IRE, and ablation. All articles with any reference to electroporation were identified and reviewed from PubMed as well as the abstracts for the 2012 meetings of the American Hepato-Pancreato-Biliary Association and the Society for Interventional Radiology. All data pertaining to the safety and efficacy of IRE were extracted from preclinical and clinical studies, and preclinical data detailing the theory and design of IRE systems were also extracted.

RESULTS

ELECTROPORATION

Breakdown of the cell membrane owing to an induced electric field was first described in the 1970s.[25-27] Electroporation can be applied in either a reversible (RE) or an irreversible manner (IRE), depending on the strength and duration of the electrical field. Pulses of direct current are delivered to tissue in rapid, short intervals (milliseconds), permeabilizing the lipid bilayer of the cell membrane.[28-32]

REVERSIBLE ELECTROPORATION

When the electrical field strength is below a critical threshold or when the electrical field is turned off prior to achieving a critical pore radius, the process is reversible.[28] Reversible electroporation has been used to promote uptake of chemotherapy into tumor cells—electrochemotherapy.[33,34] Studies have shown that RE in combination with bleomycin therapy is safe and improves outcomes for the treatment of squamous cell carcinoma of the head and neck when compared with bleomycin therapy alone.[35,36]

IRREVERSIBLE ELECTROPORATION

Preclinical Data

Irreversible electroporation uses higher voltage direct current to overcome the ability of the cell membrane to seal, resulting in cell death.[28,30] Electron microscopy reveals that the pore size is larger following IRE of hepatocytes (80-490nm) compared with RE.[37] Davalos et al[38] introduced the concept of nonthermal tissue ablation using IRE. They showed that IRE could be used to ablate substantial volumes of liver tissue without undesirable thermal effects.[39]

The application of 1500 V/cm in sets of 10 pulses of 300 microseconds produces complete ablation of hepatocarcinoma cells in vitro.[40] Delivering the electrical energy in multiple pulses is more effective for tumor cell ablation than delivering the same energy in a single pulse.

©2012 American Medical Association. All rights reserved.
Downloaded From: http://archsurg.jamanetwork.com/ on 09/04/2015

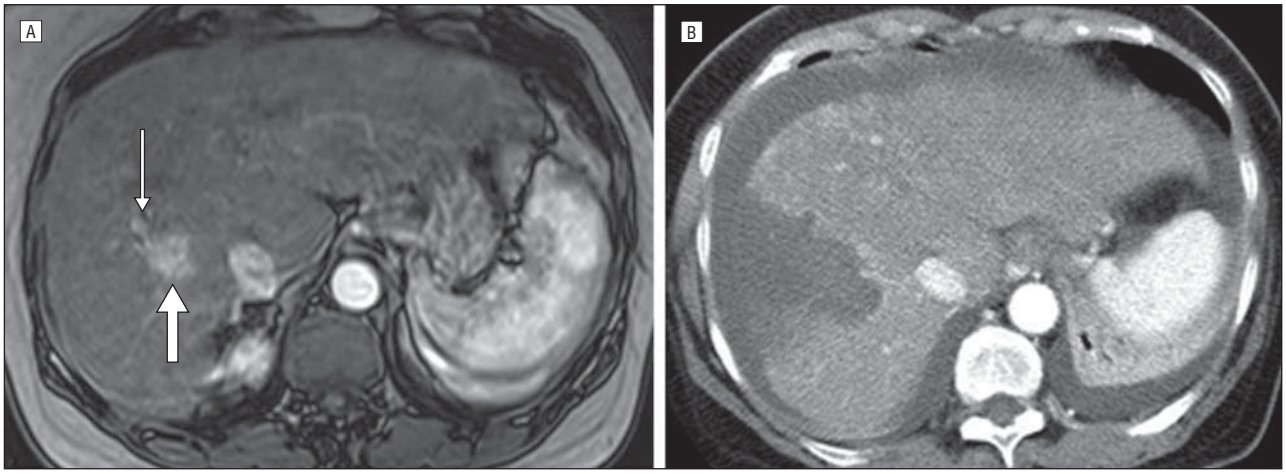

Figure 2. Collateral damage following thermal ablation. A 76-year-old woman underwent laparoscopic microwave ablation for multifocal hepatocellular carcinoma. A, A hepatoma (thick arrow) abutting the segment 7 portal pedicle (thin arrow). B, Infarction of segment 7 as a result of collateral damage to the segment 7 portal pedicle during microwave ablation. The patient went on to a full recovery and is alive 28 months following initial ablation.

To my knowledge, the first description of liver ablation in vivo using IRE was reported by Rubinsky et al[41] in 2007. They reported their results creating 35 ablations in 14 swine livers. They varied the electrode configuration between 2 and 4 electrodes, with varying electric pulse parameters. All 14 animals survived to the designated time (24 hours to 14 days). Reversible, chemical paralysis was shown to be necessary to control unwanted, muscular contractions. The ablation zones were well demarcated and extended to a predicted electrical field magnitude of 600 V/cm. Histologic analysis showed hemorrhagic necrosis of the hepatocytes with preservation of the bile ducts within the zone of ablation. Hepatocytes immediately adjacent to central veins were ablated, suggesting that IRE is not affected by heat sink.

The design of the first IRE system approved for clinical use was reported in 2007.[42] Using this system, Lee et al[43] created ablations in swine liver up to 6 cm in maximal dimension with preservation of the portal structures and no evidence of heat sink. Bcl-2 oncoprotein staining was noted in all of the ablation zones but not detected in normal hepatic tissue, suggesting apoptosis as a possible mechanism of cell death.

Our group performed 16 liver ablations in 8 swine using 2 monopolar electrodes spaced 2 cm apart.[44] Treatments included 90 pulses of 2500 to 3000 V/cm with a pulse length of 100 microseconds. Pulses were delivered in groups of 10, with a 250-microsecond pause between grouped pulses. Using this technique, we were able to create elliptical ablations ranging from 2.3 cm to 3.3 cm × 1.5 cm. Hemorrhagic necrosis of the hepatocytes was noted in the zone of ablation (**Figure 3**). Liver tissue immediately adjacent to the hepatic veins was ablated with no evidence of heat sink (**Figure 4**).

In addition, we performed 4 ablations across a portal pedicle in the liver hilum. Treatments included 90 pulses of 3000 V/cm, with a pulse length of 100 microseconds and a 2-cm exposed length of the active portion of the electrodes. Pulses were delivered in groups of 10 with a 250-microsecond pause between grouped pulses. This resulted in an elliptical ablation measuring a mean (SD) 4.45 (0.07) cm × 1.8 (0) cm. The hepatic artery, portal vein, and bile duct within the ablation zone were relatively preserved and appeared to be more resistant to the effects of IRE, as previously described (**Figure 5**).

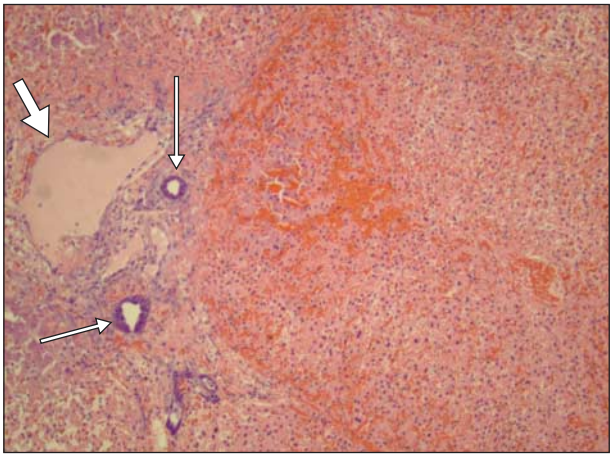

Figure 3. Hemorrhagic necrosis following irreversible electroporation of the liver. Hematoxylin and eosin stain of liver tissue 48 hours after irreversible electroporation showing hemorrhagic necrosis of the hepatocytes with preservation of the portal vein (thick arrow) and bile ducts (thin arrows). Original magnification ×20.

Irreversible electroporation has also been shown to be safe and effective for the ablation of extrahepatic tissues including of the prostate,[45] carotid artery,[46] atrial appendage,[47] pancreas,[48,49] small bowel,[50] kidney,[51-53] and lung.[54,55] These studies showed similar findings to those described previously with effective ablation of the target tissue, lack of heat sink, and preservation of critical structures in and around the zone of ablation such as nerve tissue for prostate IRE, renal pelvis during kidney IRE, and duodenal and vascular preservation following IRE of the pancreatic head.

Defining Ablation

While the effects of thermal ablation are evident immediately, the zone of ablation following IRE is not immediately evident owing to the mechanism of cell death. Triphenyltetrazolium chloride staining is able to predict the

©2012 American Medical Association. All rights reserved.
Downloaded From: http://archsurg.jamanetwork.com/ on 09/04/2015

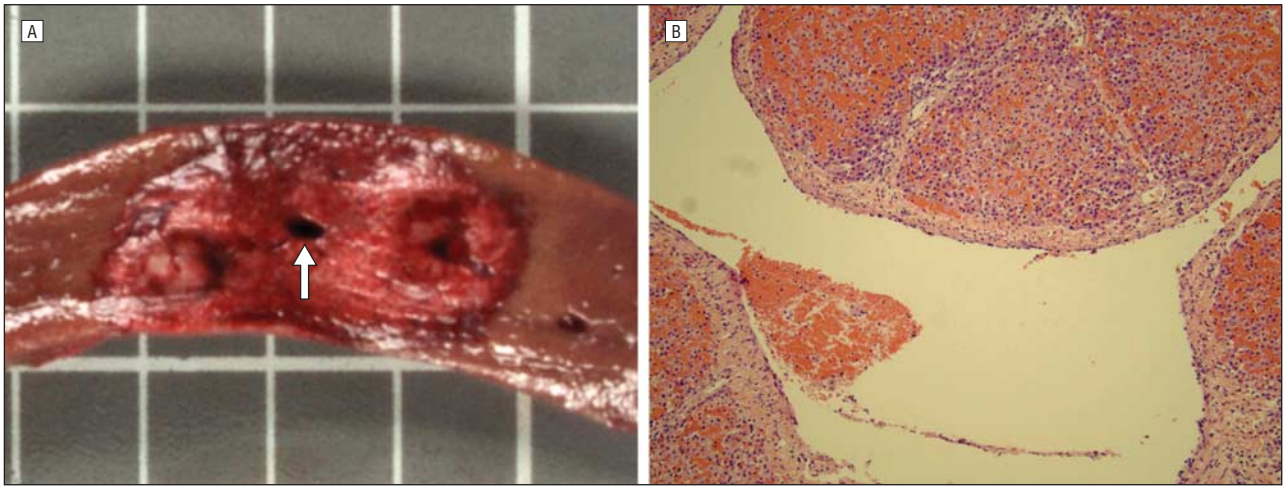

Figure 4. Absence of heat sink following irreversible electroporation of the liver. Liver tissue is shown following ablation by irreversible electroporation. A, The arrow highlights a hepatic vein in the center of the ablation zone, with hepatocyte cell death immediately adjacent to the vein. B, Hematoxylin and eosin staining confirms hemorrhagic necrosis of the hepatocytes immediately adjacent to the central vein without evidence of heat sink. Original magnification ×4.

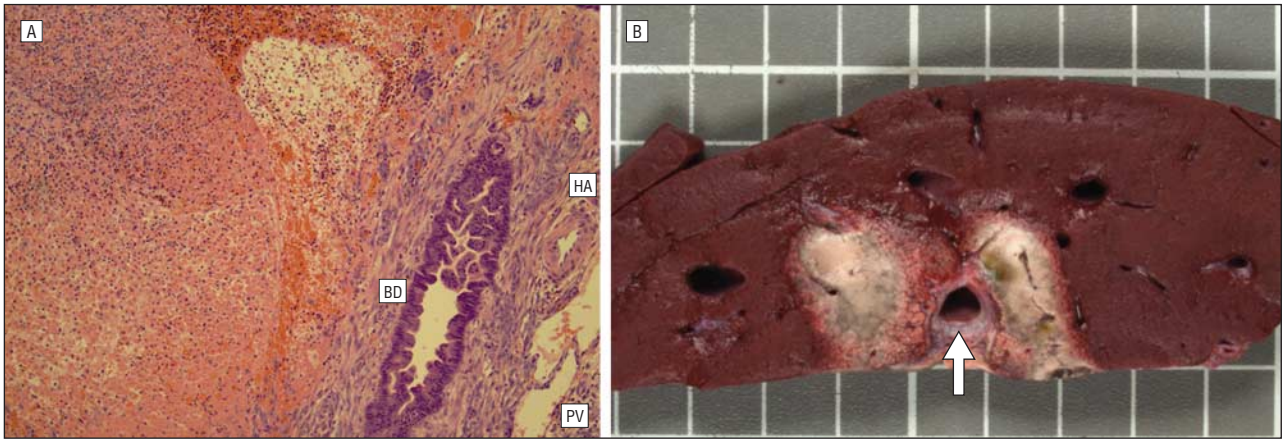

Figure 5. Irreversible electroporation of the liver hilum. A, Liver tissue following ablation with irreversible electroporation showing preservation of the bile duct (BD), hepatic artery (HA), and portal vein (PV) within the zone of ablation. B, Liver tissue stained with triphenyltetrazolium chloride following IRE ablation of the hilum including the portal pedicle. The viable tissue retains the red triphenyltetrazolium chloride dye, while the area of ablation does not. The arrow highlights a patent, preserved portal vein in the center of the ablation zone.

zone of ablation as early as 15 minutes following IRE (**Figure 6**).[44] Ultrasonography and magnetic resonance imaging have also been reported to accurately predict the zone of ablation following IRE.[56-58]

Preclinical Oncologic Data

The experience treating cancer cells with IRE is growing. Al-Sakere et al[59] reported complete regression in 12 of 13 cutaneous tumors implanted in mice with IRE.

Guo et al[60] created hepatomas in 30 Sprague-Dawley rats. Animals were either treated by IRE using 8 100-microsecond pulses of 2500 V/cm or served as control subjects. Nine of 10 animals treated with IRE and euthanized 7 to 15 days after treatment had a pathologic complete response.

Other groups have reported the ability of IRE to ablate prostate cancer cells in vitro,[61] breast cancer cells in vitro,[62] breast tumors orthotopically implanted in nude mice in vivo,[63] and pancreas ductal adenocarcinoma in vivo in a mouse model.[64]

Safety

To my knowledge, the first prospective study of IRE for the treatment of human tumors was designed as an ablation followed by resection trial in 6 patients with renal tumors. No clinically significant electrocardiographic, hemodynamic, or serum biologic changes were noted during or following IRE. One patient in the series had a transient, self-limiting supraventricular arrhythmia.[65]

The first article detailing IRE in human liver was a retrospective report detailing the complications encountered while performing 28 IRE ablations in 21 patients.[66] Seventeen procedures treated liver tumors, 8 renal tumors, and 3 lung tumors. In this study, complications included transient systolic hypertension in all patients, muscular contractions in inadequately paralyzed patients, postoperative pain following 13 procedures (46%), acid-base disturbances following 4 procedures (14%), and pneumothorax related to electrode placement in 3 procedures (11%). Ventricular tachycardia occurred during 7 procedures (25%). In 4 of these 7 cases, the arrhythmia was as-

©2012 American Medical Association. All rights reserved.
Downloaded From: http://archsurg.jamanetwork.com/ on 09/04/2015

sociated with markedly decreased blood pressure. In a follow-up article, the authors reported only 2 episodes of arrhythmia in 30 patients using electrocardiogram synchronization of the IRE treatment—supraventricular tachycardia (n=1) and atrial fibrillation (n=1).[67]

Mali et al[68] reported on the effects of electroporation on the function of the heart in human patients. Fourteen patients were treated with electrochemotherapy. In this series, voltages for electrochemotherapy ranged from 680 to 960 V/cm compared with the 2500 to 3000 V/cm typically used for liver IRE. No pathologic morphologic changes of the electrocardiogram in any of the patients treated were reported. The authors suggested an algorithm for cardiac synchronization with electroporation that may improve its safety.

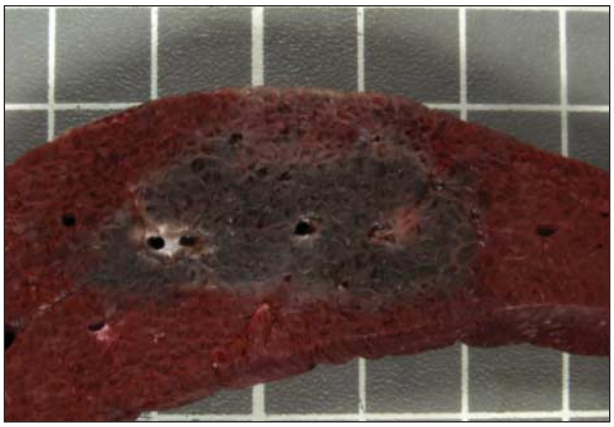

Figure 6. Triphenyltetrazolium chloride staining following irreversible electroporation of the liver. Liver tissue explanted 2 hours after ablation with irreversible electroporation and stained with triphenyltetrazolium chloride. Viable hepatocytes retain the red dye. The zone of ablation does not retain the triphenyltetrazolium chloride stain.

Table 1. Early, Retrospective Experience With Irreversible Electroporation of the Liver and Pancreas Presented in Abstract Form

	Patients (Lesions Ablated), No.			
Study	Liver Patients	Pancreas Patients	Lung Patients	Other Patients
Narayanan et al[70]	0	8 (8)	0	0
Bagla et al[71]	0	4 (7)	0	0
Narayanan et al[72]	49 (76)	0	0	0
Hays et al[73]	33[a]	1[a]	12[a]	4[a]

[a] Some patients treated at more than 1 site.

In a subsequent study, Deodhar et al[69] reported improved safety with IRE with the use of cardiac synchronization in a swine model. All of the 7 ablations performed within 1.7 cm of the heart without electrocardiogram synchronization resulted in a severe, life-threatening arrhythmia compared with no serious arrhythmias in 12 ablations performed within 1.7 cm of the heart but with cardiac synchronization. No serious arrhythmias occurred in either the synchronized or unsynchronized group when the electrode was positioned more than 1.7 cm from the heart; however, unsynchronized ablations still had a higher incidence of minor, self-limiting arrhythmias compared with synchronized ablations (2/11 and 0/7, respectively). The distance of 1.7 cm was modeled to predict an electrical field strength of 100 V/cm, which is less than the threshold to achieve RE. They concluded that the risk for cardiac arrhythmia during IRE is directly related to the distance of the electrode from the heart and that serious arrhythmias can be avoided with cardiac synchronization.

In the last 2 years, a growing volume of experience with IRE for ablation of human tumors has been reported in abstract form. Four abstracts presented at the 2012 meeting of the Society for Interventional Radiology detailed the experience and safety of IRE for the ablation of 158 tumors in 106 patients (**Table 1** and **Table 2**).[70-73] A multi-institutional, voluntary tumor treatment registry has been established for IRE. Data from the registry was presented at the national meeting of the American Hepato-Pancreato-Biliary Association in March 2012. This experience had considerable overlap with the data presented at the Society for Interventional Radiology's 2012 meeting and detailed a similar safety profile for IRE of the liver in humans.[74]

Irreversible electroporation appears to be finding a niche for ablation of small tumors (<3 cm) abutting large vessels or other critical structures where either heat sink or collateral damage are a concern. Narayanan et al[75] reported narrowing or thrombosis in only 3 of 84 vessels in close proximity to the ablation.

A recent case report describes IRE for the treatment of unresectable MCRC abutting a portal pedicle, validating our group's preclinical experience showing the safety of IRE for liver ablations across the porta hepatis.[44,76]

Oncologic Efficacy

The most important study to date regarding IRE for liver tumors is a well-designed, prospective, multicenter study to evaluate the safety and efficacy of IRE as first-line treatment in biopsy-proven, early-stage HCC (clinicaltrials

Table 2. Safety of Irreversible Electroporation in the Early Experience With Ablation of Human Liver and Pancreas Tumors

	Events/Ablations, No.					
Study	Pneumothorax	Hypertension	Arrhythmia	Pancreatitis	Other/Self-limiting	Death
Narayanan et al[70]	1/8	NR	NR	1/8		0
Bagla et al[71]	0	7/7	0	NR	1/7	0
Narayanan et al[72]	6/49	NR	2/49[a]	NR	2/49	NR
Hays et al[73]	7/50	1/50	0	NR	2/50	NR

Abbreviation: NR, not reported.
[a] Self-limiting.

©2012 American Medical Association. All rights reserved.
Downloaded From: http://archsurg.jamanetwork.com/ on 09/04/2015

.gov Identifier: NCT01078415).[77] In this series, Lencioni et al[77] reported a complete response in 23 of 29 tumors (79%) by the Modified Response Evaluation Criteria in Solid Tumors as assessed by an independent, central, blinded review. The authors reported no 30-day mortality in the series. Major complications were rare and included only 1 case of hemothorax related to electrode placement and 1 case of transient hepatic decompensation with spontaneous resolution.

Narayanan et al[72] reported a complete response in 20 of 49 patients (41%) with 76 tumors (median tumor size, 2.1 cm; range, 0.8-6.0 cm) treated by IRE. Perhaps more encouraging, they described a patient who initially presented with locally, advanced unresectable biopsy-proven pancreatic cancer treated with combination therapy including IRE. After successful downstaging, the patient underwent surgical resection with a pathologic complete response.[70] Ali et al[78] also reported a complete pathologic complete response in 2 primary liver tumors treated by IRE, which subsequently underwent liver explantation.

COMMENT

FUTURE DIRECTIONS

Additional data are needed to establish the efficacy of IRE for the treatment of human liver tumors before proceeding with head to head studies of IRE vs microwave ablation and/or RFA.

Electrical field strength diminishes with increasing distance from the electrode(s).[28,30,79] When the field strength exceeds 500 to 600 V/cm, IRE can be achieved. Field strengths between 100 and 500 V/cm produces a mostly reversible form of electroporation. When the field strength falls to less than 100 V/cm, the ability to reliably electroporate the cell membrane is lost.

It follows that when IRE is performed, a margin of reversibly electroporated tissue exists between the ablation zone and normal liver. Capitalizing on this principle, Au et al[80] demonstrated successful gene transfer in 31 of 36 liver IRE ablations in a swine model. The authors went on to suggest further clinical studies of IRE ablation together with delivery of immunostimulatory plasmids for combined local ablation and systemic immunotherapy.

Another area of future study is combining IRE with electrochemotherapy to take therapeutic advantage of the zone of RE surrounding the area of irreversible ablation.

Finally, Belkind et al[81] reported on the development of an electrically responsive cisplatin-loaded hydrogel that releases the drug in a voltage-dependent fashion following electroporation, laying the ground work for a novel method of drug delivery to solid tumors.

THE NANOKNIFE SYSTEM

The only system currently available for clinical use is the NanoKnife (AngioDynamics), which has received 510(k) approval for soft-tissue ablation but has not received any tissue-specific indications. The Federal Food and Drug Administration has granted an investigational device exemption to study IRE for the treatment of prostate cancer and is currently reviewing another investigational device exemption application to study NanoKnife for the treatment of locally advanced, unresectable pancreatic cancer.

Irreversible electroporation can be performed using a percutaneous, laparoscopic, or open surgical technique.[43,72] Tumor size and configuration can be programmed into the NanoKnife system, which then generates a treatment plan. The treatment plan is displayed on the computer interface and can be modified by the user to optimize accuracy and efficacy. Up to 6 electrodes (19 gauge) can be positioned around the tumor with image guidance depending on the size and shape of the tumor before delivering the treatment.

The list price for NanoKnife is $395 000 but center-specific pricing may vary significantly. Electrodes cost from $1000 to $2000 per piece; therefore, the cost per case varies on the number of electrodes used. NanoKnife is approved by the Federal Food and Drug Administration for soft-tissue ablation; therefore, in some cases, generic ablation codes may be reimbursed.

LESSONS LEARNED FROM THE ADOPTION OF NEW TECHNOLOGIES

The introduction of novel medical technology is a complex process with multiple competing interests. Innovators and corporations have an intellectual and financial interest in seeing their products developed. Patients have a vested interest in new technologies that could improve the length and/or quality of life; however, this is trumped by their desire for safety and autonomy during the phase of innovation and early adoption of new technology, the so-called learning curve. Physicians also have a vested interest in new technologies that can improve either the length and/or quality of life for their patients. At times, physician motives for using innovative technologies have been questioned, with some citing concerns of conflicts of interest and with potential secondary gains being academic development or financial gain. Strasberg and other members of the Balliol Collaboration have published a series of articles highlighting the potential pitfalls and conflicts of interest that can occur during the adoption of new technology.[82-85] Through the IDEAL model (Innovation, Development, Exploration, Assessment, and Long-term study) recommendations, they went on to suggest a framework through which surgical innovation may be developed that protects and promotes the interests of innovators, patients, and early adopters of new technology into surgical practice.

Based on the IDEAL model recommendations, IRE is in Stage 2a development (**Table 3**). The data supporting the proof of concept for ablation of liver tumors with IRE is robust. The early innovators have published several case series describing the safety and technical successes of the procedure, as detailed previously. Now, we are seeing IRE use expanding out to a wider range of users—the early adopters. More data are emerging to support safety, and prospective data are just now emerging to establish early efficacy of IRE for liver tumor ablation. A prospective, voluntary database for IRE of human tumors is established, and we are beginning to see

©2012 American Medical Association. All rights reserved.
Downloaded From: http://archsurg.jamanetwork.com/ on 09/04/2015

Table 3. Stages of Surgical Innovation: The IDEAL Model[a]

	1: Idea	2a: Development	2b: Exploration	3: Assessment	4: Long-term Study
Purpose	Proof of concept	Development	Learning	Assessment	Surveillance
Number and types of patients	Single digit; highly selected	Few; selected	Many; may expand to mixed; broadening indication	Many; expanded indications (well defined)	All eligible
Number and types of surgeons	Very few; innovators	Few; innovators and some early adopters	Many; innovators, early adopters, early majority	Many; early majority	All eligible
Output	Description	Description	Measurement; comparison	Comparison; complete information for non-RCT participants	Description; audit, regional variation; quality assurance; risk adjustment
Intervention	Evolving; procedure inception	Evolving; procedure development	Evolving; procedure refinement; community learning	Stable	Stable
Method	Structured case reports	Prospective development studies	Research database; explanatory or feasibility RCT (efficacy trial); diseased based (diagnostic)	RCT with or without additions/modifications; alternative designs	Registry; routine database (eg, SCOAP, STS, NSQIP); rare case reports
Outcomes	Proof of concept; technical achievement; disasters; dramatic successes	Mainly safety; technical and procedural success	Safety; clinical outcomes (specific and graded); short-term outcomes; patient-centered (reported) outcomes; feasibility outcomes	Clinical outcomes (specific and graded); middle-term and long-term outcomes; patient-centered (reported) outcomes; cost-effectiveness	Rare events; long-term outcomes; quality assurance
Ethical approval	Sometimes	Yes	Yes	Yes	No
Examples	NOTES video	Tissue-engineered vessels	Italian D2 gastrectomy study	Swedish obese patients study	UK national adult cardiac surgical database

Abbreviations: IDEAL, Innovation, Development, Exploration, Assessment, and Long-term study; NOTES, natural orifice translumenal endoscopic surgery; NSQIP, National Surgical Quality Improvement Program; RCT, randomized controlled trial; SCOAP, Surgical Clinical Outcomes Assessment Program; STS, Society of Thoracic Surgeons.

[a] Adapted with permission from Elsevier.

reports from that data set regarding safety and outcomes. Finally, a well-designed prospective study using IRE to treat HCC has been completed and the preliminary data have been reported and seem very encouraging in terms of both safety and efficacy.

CONCLUSIONS

Irreversible electroporation is a novel, nonthermal method for tumor ablation. The early clinical and preclinical experiences with IRE establish its safety for liver tumor ablation when electrocardiogram synchronization is used and when the treatment is delivered in properly selected patients and by someone with experience and expertise in image-guided tumor ablation. Irreversible electroporation is likely to find a niche for the ablation of small, unresectable liver tumors that abut the vena cava, large hepatic veins, or portal structures where conventional forms of thermal ablation are limited owing to heat sink and/or concerns regarding collateral damage. Further study is needed to establish the oncologic efficacy for IRE in the treatment of primary and metastatic liver cancer.

Accepted for Publication: May 26, 2012.
Correspondence: Kevin P. Charpentier, MD, Alpert Medical School, University Surgical Associates, Brown University, 2 Dudley St, Ste 470, Providence, RI 02905 (kcharpentier@usasurg.org).
Conflict of Interest Disclosures: Dr Charpentier serves on the data safety monitoring board for ONC-204, a trial of NanoKnife for the treatment of locally advanced, unresectable pancreatic cancer. He has also previously received a research grant from AngioDynamics.

REFERENCES

1. Wingo PA, Tong T, Bolden S. Cancer statistics, 1995. *CA Cancer J Clin.* 1995;45(1):8-30.
2. Abdalla EK, Adam R, Bilchik AJ, Jaeck D, Vauthey JN, Mahvi D. Improving resectability of hepatic colorectal metastases: expert consensus statement. *Ann Surg Oncol.* 2006;13(10):1271-1280.
3. Choti MA, Sitzmann JV, Tiburi MF, et al. Trends in long-term survival following liver resection for hepatic colorectal metastases. *Ann Surg.* 2002;235(6):759-766.
4. Abdalla EK, Vauthey JN, Ellis LM, et al. Recurrence and outcomes following hepatic resection, radiofrequency ablation, and combined resection/ablation for colorectal liver metastases. *Ann Surg.* 2004;239(6):818-825, discussion 825-827.
5. Fong Y, Fortner J, Sun RL, Brennan MF, Blumgart LH. Clinical score for predicting recurrence after hepatic resection for metastatic colorectal cancer: analysis of 1001 consecutive cases. *Ann Surg.* 1999;230(3):309-318, discussion 318-321.
6. Stang A, Fischbach R, Teichmann W, Bokemeyer C, Braumann D. A systematic review on the clinical benefit and role of radiofrequency ablation as treatment of colorectal liver metastases. *Eur J Cancer.* 2009;45(10):1748-1756.
7. Berber E, Pelley R, Siperstein AE. Predictors of survival after radiofrequency thermal ablation of colorectal cancer metastases to the liver: a prospective study. *J Clin Oncol.* 2005;23(7):1358-1364.

©2012 American Medical Association. All rights reserved.
Downloaded From: http://archsurg.jamanetwork.com/ on 09/04/2015

8. Siperstein AE, Berber E, Ballem N, Parikh RT. Survival after radiofrequency ablation of colorectal liver metastases: 10-year experience. *Ann Surg*. 2007;246 (4):559-565, discussion 565-567.
9. Ruers TJ, Joosten JJ, Wiering B, et al. Comparison between local ablative therapy and chemotherapy for non-resectable colorectal liver metastases: a prospective study. *Ann Surg Oncol*. 2007;14(3):1161-1169.
10. Tanaka K, Shimada H, Nagano Y, Endo I, Sekido H, Togo S. Outcome after hepatic resection versus combined resection and microwave ablation for multiple bilobar colorectal metastases to the liver. *Surgery*. 2006;139(2):263-273.
11. Timmerman RD, Bizekis CS, Pass HI, et al. Local surgical, ablative, and radiation treatment of metastases. *CA Cancer J Clin*. 2009;59(3):145-170.
12. Evrard S, Becouarn Y, Fonck M, Brunet R, Mathoulin-Pelissier S, Picot V. Surgical treatment of liver metastases by radiofrequency ablation, resection, or in combination. *Eur J Surg Oncol*. 2004;30(4):399-406.
13. Berber E, Ari E, Herceg N, Siperstein A. Laparoscopic radiofrequency thermal ablation for unusual hepatic tumors: operative indications and outcomes. *Surg Endosc*. 2005;19(12):1613-1617.
14. Livraghi T, Goldberg SN, Solbiati L, Meloni F, Ierace T, Gazelle GS. Percutaneous radio-frequency ablation of liver metastases from breast cancer: initial experience in 24 patients. *Radiology*. 2001;220(1):145-149.
15. Sofocleous CT, Nascimento RG, Gonen M, et al. Radiofrequency ablation in the management of liver metastases from breast cancer. *AJR Am J Roentgenol*. 2007; 189(4):883-889.
16. Pawlik TM, Vauthey JN, Abdalla EK, Pollock RE, Ellis LM, Curley SA. Results of a single-center experience with resection and ablation for sarcoma metastatic to the liver. *Arch Surg*. 2006;141(6):537-543, discussion 543-544.
17. Pompili M, Mirante VG, Rondinara G, et al. Percutaneous ablation procedures in cirrhotic patients with hepatocellular carcinoma submitted to liver transplantation: assessment of efficacy at explant analysis and of safety for tumor recurrence. *Liver Transpl*. 2005;11(9):1117-1126.
18. Mazzaferro V, Battiston C, Perrone S, et al. Radiofrequency ablation of small hepatocellular carcinoma in cirrhotic patients awaiting liver transplantation: a prospective study. *Ann Surg*. 2004;240(5):900-909.
19. Shibata T, Iimuro Y, Yamamoto Y, et al. Small hepatocellular carcinoma: comparison of radio-frequency ablation and percutaneous microwave coagulation therapy. *Radiology*. 2002;223(2):331-337.
20. Hur H, Ko YT, Min BS, et al. Comparative study of resection and radiofrequency ablation in the treatment of solitary colorectal liver metastases. *Am J Surg*. 2009; 197(6):728-736.
21. Nahum Goldberg S, Dupuy DE. Image-guided radiofrequency tumor ablation: challenges and opportunities, part I. *J Vasc Interv Radiol*. 2001;12(9):1021-1032.
22. Goldberg SN, Hahn PF, Tanabe KK, et al. Percutaneous radiofrequency tissue ablation: does perfusion-mediated tissue cooling limit coagulation necrosis? *J Vasc Interv Radiol*. 1998;9(1, pt 1):101-111.
23. Diehn FE, Neeman Z, Hvizda JL, Wood BJ. Remote thermometry to avoid complications in radiofrequency ablation. *J Vasc Interv Radiol*. 2003;14(12):1569-1576.
24. Carey RI, Leveillee RJ. First prize: direct real-time temperature monitoring for laparoscopic and CT-guided radiofrequency ablation of renal tumors between 3 and 5 cm. *J Endourol*. 2007;21(8):807-813.
25. Crowley JM. Electrical breakdown of bimolecular lipid membranes as an electromechanical instability. *Biophys J*. 1973;13(7):711-724.
26. Neumann E, Rosenheck K. Permeability changes induced by electric impulses in vesicular membranes. *J Membr Biol*. 1972;10(3):279-290.
27. Zimmermann U, Pilwat G, Riemann F. Dielectric breakdown of cell membranes. *Biophys J*. 1974;14(11):881-899.
28. Sugar IP, Neumann E. Stochastic model for electric field-induced membrane pores. Electroporation. *Biophys Chem*. 1984;19(3):211-225.
29. Benov LC, Antonov PA, Ribarov SR. Oxidative damage of the membrane lipids after electroporation. *Gen Physiol Biophys*. 1994;13(2):85-97.
30. Freeman SA, Wang MA, Weaver JC. Theory of electroporation of planar bilayer membranes: predictions of the aqueous area, change in capacitance, and pore-pore separation. *Biophys J*. 1994;67(1):42-56.
31. Mir LM, Orlowski S. Mechanisms of electrochemotherapy. *Adv Drug Deliv Rev*. 1999;35(1):107-118.
32. Neumann E, Kakorin S, Toensing K. Fundamentals of electroporative delivery of drugs and genes. *Bioelectrochem Bioenerg*. 1999;48(1):3-16.
33. Okino M, Mohri H. Effects of a high-voltage electrical impulse and an anticancer drug on in vivo growing tumors. *Jpn J Cancer Res*. 1987;78(12):1319-1321.
34. Mir LM, Orlowski S, Belehradek J Jr, Paoletti C. Electrochemotherapy potentiation of antitumour effect of bleomycin by local electric pulses. *Eur J Cancer*. 1991; 27(1):68-72.
35. Allegretti JP, Panje WR. Electroporation therapy for head and neck cancer including carotid artery involvement. *Laryngoscope*. 2001;111(1):52-56.
36. Bloom DC, Goldfarb PM. The role of intratumour therapy with electroporation and bleomycin in the management of advanced squamous cell carcinoma of the head and neck. *Eur J Surg Oncol*. 2005;31(9):1029-1035.
37. Lee EW, Wong D, Prikhodko SV, et al. Electron microscopic demonstration and evaluation of irreversible electroporation-induced nanopores on hepatocyte membranes. *J Vasc Interv Radiol*. 2012;23(1):107-113.
38. Davalos RV, Mir IL, Rubinsky B. Tissue ablation with irreversible electroporation. *Ann Biomed Eng*. 2005;33(2):223-231.
39. Al-Sakere B, Bernat C, Andre F, et al. A study of the immunological response to tumor ablation with irreversible electroporation. *Technol Cancer Res Treat*. 2007; 6(4):301-306.
40. Miller L, Leor J, Rubinsky B. Cancer cells ablation with irreversible electroporation. *Technol Cancer Res Treat*. 2005;4(6):699-705.
41. Rubinsky B, Onik G, Mikus P. Irreversible electroporation: a new ablation modality: clinical implications. *Technol Cancer Res Treat*. 2007;6(1):37-48.
42. Bertacchini C, Margotti PM, Bergamini E, Lodi A, Ronchetti M, Cadossi R. Design of an irreversible electroporation system for clinical use. *Technol Cancer Res Treat*. 2007;6(4):313-320.
43. Lee EW, Loh CT, Kee ST. Imaging guided percutaneous irreversible electroporation: ultrasound and immunohistological correlation. *Technol Cancer Res Treat*. 2007;6(4):287-294.
44. Charpentier KP, Wolf F, Noble L, Winn B, Resnick M, Dupuy DE. Irreversible electroporation of the liver and liver hilum in swine. *HPB (Oxford)*. 2011;13(3): 168-173.
45. Onik G, Mikus P, Rubinsky B. Irreversible electroporation: implications for prostate ablation. *Technol Cancer Res Treat*. 2007;6(4):295-300.
46. Maor E, Ivorra A, Leor J, Rubinsky B. The effect of irreversible electroporation on blood vessels. *Technol Cancer Res Treat*. 2007;6(4):307-312.
47. Lavee J, Onik G, Mikus P, Rubinsky B. A novel nonthermal energy source for surgical epicardial atrial ablation: irreversible electroporation. *Heart Surg Forum*. 2007;10(2):e162-e167.
48. Charpentier KP, Wolf F, Noble L, Winn B, Resnick M, Dupuy DE. Irreversible electroporation of the pancreas in swine: a pilot study. *HPB (Oxford)*. 2010;12 (5):348-351.
49. Bower M, Sherwood L, Li Y, Martin R. Irreversible electroporation of the pancreas: definitive local therapy without systemic effects. *J Surg Oncol*. 2011; 104(1):22-28.
50. Phillips MA, Narayan R, Padath T, Rubinsky B. Irreversible electroporation on the small intestine. *Br J Cancer*. 2012;106(3):490-495.
51. Wendler JJ, Pech M, Blaschke S, et al. Angiography in the isolated perfused kidney: radiological evaluation of vascular protection in tissue ablation by nonthermal irreversible electroporation. *Cardiovasc Intervent Radiol*. 2012;35(2):383-390.
52. Wendler JJ, Pech M, Porsch M, et al. Urinary tract effects after multifocal nonthermal irreversible electroporation of the kidney: acute and chronic monitoring by magnetic resonance imaging, intravenous urography and urinary cytology. *Cardiovasc Intervent Radiol*. 2012;35(4):921-926.
53. Deodhar A, Monette S, Single GW Jr, et al. Renal tissue ablation with irreversible electroporation: preliminary results in a porcine model. *Urology*. 2011; 77(3):754-760.
54. Dupuy DE, Aswad B, Ng T. Irreversible electroporation in a swine lung model. *Cardiovasc Intervent Radiol*. 2011;34(2):391-395.
55. Deodhar A, Monette S, Single GW Jr, et al. Percutaneous irreversible electroporation lung ablation: preliminary results in a porcine model. *Cardiovasc Intervent Radiol*. 2011;34(6):1278-1287.
56. Appelbaum L, Ben-David E, Sosna J, Nissenbaum Y, Goldberg SN. US findings after irreversible electroporation ablation: radiologic-pathologic correlation. *Radiology*. 2012;262(1):117-125.
57. Schmidt CR, Shires P, Mootoo M. Real-time ultrasound imaging of irreversible electroporation in a porcine liver model adequately characterizes the zone of cellular necrosis. *HPB (Oxford)*. 2012;14(2):98-102.
58. Guo Y, Zhang Y, Nijm GM, et al. Irreversible electroporation in the liver: contrast-enhanced inversion-recovery MR imaging approaches to differentiate reversibly electroporated penumbra from irreversibly electroporated ablation zones. *Radiology*. 2011;258(2):461-468.
59. Al-Sakere B, André F, Bernat C, et al. Tumor ablation with irreversible electroporation. *PLoS One*. 2007;2(11):e1135.
60. Guo Y, Zhang Y, Klein R, et al. Irreversible electroporation therapy in the liver: longitudinal efficacy studies in a rat model of hepatocellular carcinoma. *Cancer Res*. 2010;70(4):1555-1563.
61. Rubinsky J, Onik G, Mikus P, Rubinsky B. Optimal parameters for the destruction of prostate cancer using irreversible electroporation. *J Urol*. 2008;180 (6):2668-2674.
62. Neal RE II, Davalos RV. The feasibility of irreversible electroporation for the treatment of breast cancer and other heterogeneous systems. *Ann Biomed Eng*. 2009; 37(12):2615-2625.

©2012 American Medical Association. All rights reserved.
Downloaded From: http://archsurg.jamanetwork.com/ on 09/04/2015

63. Neal RE, Singh R, Hatcher HC, et al. Treatment of breast cancer through the application of irreversible electroporation using a novel minimally invasive single needle electrode. *Breast Cancer Res Treat*. 2010;123(1):295-301.
64. José A, Sobrevals L, Ivorra A, Fillat C. Irreversible electroporation shows efficacy against pancreatic carcinoma without systemic toxicity in mouse models. *Cancer Lett*. 2012;317(1):16-23.
65. Pech M, Janitzky A, Wendler JJ, et al. Irreversible electroporation of renal cell carcinoma: a first-in-man phase I clinical study. *Cardiovasc Intervent Radiol*. 2011;34(1):132-138.
66. Ball C, Thomson KR, Kavnoudias H. Irreversible electroporation: a new challenge in "out of operating theater" anesthesia. *Anesth Analg*. 2010;110(5):1305-1309.
67. Thomson KR, Cheung W, Ellis SJ, et al. Investigation of the safety of irreversible electroporation in humans. *J Vasc Interv Radiol*. 2011;22(5):611-621.
68. Mali B, Jarm T, Corovic S, et al. The effect of electroporation pulses on functioning of the heart. *Med Biol Eng Comput*. 2008;46(8):745-757.
69. Deodhar A, Dickfeld T, Single GW, et al. Irreversible electroporation near the heart: ventricular arrhythmias can be prevented with ECG synchronization. *AJR Am J Roentgenol*. 2011;196(3):w330-w335.
70. Narayanan G, Arora G, Barbery KJ, et al. Downstaging locally advanced pancreatic adenocarcinoma (LAPC) with vascular encasement using percutaneous irreversible electroporation (IRE). *J Vasc Interv Radiol*. 2012;23(3):s6-s7. doi:10.1016/j.jvir.2011.12.041.
71. Bagla S, Papadouris D, van Breda A. Percutaneous irreversible electroporation (IRE) of surgically unresectable pancreatic carcinoma: single center safety experience. *J Vasc Interv Radiol*. 2012;23(3):s54. doi:10.1016/j.jvir.2011.12.170.
72. Narayanan G, Hosein P, Mohin G, et al. Percutaneous irreversible electroporation (IRE) in the treatment of hepatocellular carcinoma (HCC) and metastatic colorectal cancer (mCRC) to the liver. *J Vasc Interv Radiol*. 2012;23(3):s54. doi:10.1016/j.jvir.2011.12.171.
73. Hays D, Robbins KV, Goodwin WJ, St Amour TE. Single center, multiuser experience and safety of 50 irreversible electroporation (IRE) ablation. *J Vasc Interv Radiol*. 2012;23(3):s80. doi:10.1016/j.jvir.2011.01.205.
74. Cannon RM, Hays D, Goodwin W, et al. Safety and early efficacy of irreversible electroporation for hepatic tumors in proximity to vital structures. *HPB*. 2012;14(s1):10.
75. Narayanan G, Arora G, Quintana D, et al. Vessel patency post irreversible electroporation (IRE) ablation: a 15 month follow-up. *J Vasc Interv Radiol*. 2012;23(3):s53. doi:10.1016/j.jvir.2011.12.168.
76. Kasivisvanathan V, Thapar A, Oskrochi Y, Picard J, Leen EL. Irreversible electroporation for focal ablation at the porta hepatis [published online February 25, 2012]. *Cardiovasc Intervent Radiol*. .
77. Lencioni R, Izzo F, Crocetti L, et al. A prospective, multicenter phase II clinical trial using irreversible electroporation for the treatment of early stage HCC. *J Vasc Interv Radiol*. 2012;23(8):1114. doi:10.1016/j.jvir.2012.05.018.
78. Ali NS, Cohn S, Raofi V. Single center experience with irreversible electroporation for liver and pancreas tumor ablation. *HPB*. 2012;14(s1):2.
79. Golberg A, Rubinsky B. Towards electroporation based treatment planning considering electric field induced muscle contractions. *Technol Cancer Res Treat*. 2012;11(2):189-201.
80. Au JT, Wong J, Mittra A, et al. Irreversible electroporation is a surgical ablation technique that enhances gene transfer. *Surgery*. 2011;150(3):474-479.
81. Belkind N, Larson AC, Omary RA. Electroporation enables controlled cisplatin release from a novel drug delivery hydrogel. *J Vasc Interv Radiol*. 2012;23(3):s88-s89. doi:10.1016/j.jvir.2011.12.265.
82. Strasberg SM, Ludbrook PA. Who oversees innovative practice? is there a structure that meets the monitoring needs of new techniques? *J Am Coll Surg*. 2003;196(6):938-948.
83. Barkun JS, Aronson JK, Feldman LS, et al; Balliol Collaboration. Evaluation and stages of surgical innovations. *Lancet*. 2009;374(9695):1089-1096.
84. Ergina PL, Cook JA, Blazeby JM, et al; Balliol Collaboration. Challenges in evaluating surgical innovation. *Lancet*. 2009;374(9695):1097-1104.
85. McCullough P, Altman DG, Campbell WB, et al. Surgical innovation and evaluation 3: no surgical innovation without evaluation, the IDEAL recommendations. *Lancet*. 2009;372:1105-1112.

INVITED CRITIQUE

Another Club in the Bag

In the event that you have had any difficulty keeping up with the near explosion of new technologies and techniques that continue to rapidly change the nature of hepatobiliary surgery, in this article,[1] Kevin P. Charpentier, MD, has graciously provided a timely, comprehensive, and thoughtful review of yet another new treatment option.

With the increasing incidence of primary hepatic malignancies, such as hepatocellular carcinoma and cholangiocarcinoma, as well as a host of secondary tumors, including colorectal and neuroendocrine tumors, there is certainly a need for new options. Improvements in imaging, surgical tools and techniques, catheter-based treatments, and ablative technologies have all converged to expand the locoregional treatment alternatives. Indeed, the concepts of unresectable and untreatable tumors are undergoing continuous redefinition. With more on the horizon, irreversible electroporation (IRE) represents one relatively new such modality. I may be horrible at golf, but I do understand the concept: choose the best club based on where the ball lies. Unfortunately, relative to critical anatomy, sometimes tumors in the liver lie in very unfortunate locations. In this article, Charpentier gives us a perspective on soft-tissue tumor ablation, explains the underlying mechanisms, and describes the role potentially filled by IRE. I especially appreciated learning about the IDEAL (Innovation, Development, Exploration, Assessment, and Long-term study) framework for assessing surgical innovation and the place currently held by the IRE technology. In its current state, IRE is costly and indicated for a relatively small niche, but it certainly has promise for an expanded role as more is learned. To answer Charpentier's question, I doubt whether we are there yet; however, as we play the course, it certainly cannot hurt to have a new, albeit expensive, club in the bag.

Steven D. Colquhoun, MD

Author Affiliation: Liver Transplant Program, Cedars-Sinai Medical Center, Los Angeles, California.
Correspondence: Dr Colquhoun, Liver Transplant Program, Cedars-Sinai Medical Center, 8635 W 3rd St, Ste 590W, Los Angeles, CA 90048 (colquhouns@cshs.org).
Conflict of Interest Disclosures: None reported.

1. Charpentier KP. Irreversible electroporation for the ablation of liver tumors: are we there yet? *Arch Surg*. 2012;147(11):1053-1061.

©2012 American Medical Association. All rights reserved.
Downloaded From: http://archsurg.jamanetwork.com/ on 09/04/2015