Answer

Pseudoaneurysm

Our patient had life-threatening hemobilia due to a pseudoaneurysm caused by chronic pancreatitis. Enhanced CT demonstrated a small pseudoaneurysm at the anterosuperior pancreaticoduodenal artery adjoining the pancreas head (Figure 1C). As this lesion communicated with the common bile duct, it might have caused massive hemobilia, resulting in the patient's hemodynamic instability. Although his condition required emergent angiography with embolization, it was not possible because of an anomaly of the hepatic artery. Instead, he underwent emergent laparotomy. To control the massive hemobilia, we performed a pancreaticoduodenectomy. Fortunately, the patient had an uneventful postoperative course. Microscopic investigation of the resected specimen showed chronic alcoholic fibrous pancreatitis accompanied by microfistula formation between the common bile duct and bleeding pseudoaneurysm (**Figure 2**). This connection could have facilitated the massive hemobilia.

Hemobilia is rare but should be included in the differential diagnosis of gastrointestinal hemorrhage. It occurs when an injury or disease causes communication between the biliary tract and surrounding blood vessels. Its causes include accidental or operative trauma, inflammation, gallstones, tumors, and coagulation or vascular disorders.[1,2] Chronic pancreatitis is an uncommon cause of gastrointestinal bleeding,[3] but approximately 10% of patients with this condition have a pseudoaneurysm adjoining the pancreas.[4,5] Hemosuccus pancreaticus is most commonly caused by rupture of the pseudoaneurysm into the main pancreatic duct and is associated with acute or chronic pancreatitis.

In patients with hemobilia, identifying the source of bleeding is often problematic. Endoscopy with side-viewing duodenoscopy for observation of the papilla of Vater is definitive,[1] while ultrasonography and CT are also helpful. If results indicate a pseudoaneurysm, abdominal angiography is required to confirm the diagnosis. The exact mechanism of pseudoaneurysm development is unclear but probably varies according to local pathology. Chronic continuous inflammation is a possible cause of the development of a pseudoaneurysm.[5] Pressure necrosis or enzymatic degeneration of the arterial wall due to chronic pancreatitis may accelerate formation and rupture of a pseudoaneurysm.[1]

Angiography with embolization is a definitive therapy for hemobilia due to a pseudoaneurysm in the pancreaticoduodenal arcade,[4] but this approach has serious complications such as bleeding, abscess formation, gallbladder fibrosis, hepatobiliary necrosis, and liver failure. Once the patient is hemodynamically stabilized through this procedure, interventional drainage or surgical resection can be planned electively. Ideally, hemobilia due to a pseudoaneurysm should be managed in this 2-step fashion; if this is not feasible, as in our case, an emergent operation should be undertaken because of the high mortality in untreated patients.[5]

Hemobilia is an uncommon but serious complication of chronic pancreatitis. Importantly, hemobilia caused by a pseudoaneurysm may be massive but intermittent. Our case highlights its potentially lethal outcome. Awareness of this condition and its appropriate therapy can assist in rapid diagnosis and treatment.

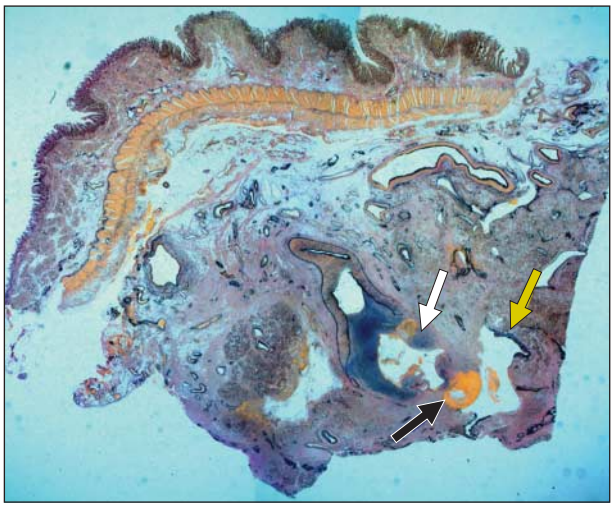

Figure 2. Histological investigation of the resected specimen showed chronic fibrous inflammatory changes due to alcoholic pancreatitis, accompanied by microfistula formation (black arrow) between the bile duct (yellow arrow) and irregularly disrupted vessel-like structures (white arrow) (elastica van Gieson stain, original magnification ×2).

Accepted for Publication: November 16, 2011.
Correspondence: Kensuke Adachi, MD, PhD, Department of Surgery, Tokyo Metropolitan Tama Medical Center, 2-8-29 Musashidai, Fuchu, Tokyo 183-8524, Japan (kensuke_adachi@tmhp.jp).
Author Contributions: *Study concept and design:* Adachi. *Acquisition of data:* Adachi. *Analysis and interpretation of data:* Adachi and Minami. *Drafting of the manuscript:* Adachi. *Critical revision of the manuscript for important intellectual content:* Adachi and Minami. *Administrative, technical, and material support:* Minami. *Study supervision:* Adachi and Minami.
Conflict of Interest Disclosures: None reported.
Additional Contributions: Kazuaki Enatsu, MD, PhD, provided expertise in pathologic diagnosis and interpretation.

REFERENCES

1. Yoshida J, Donahue PE, Nyhus LM. Hemobilia. *Am J Gastroenterol*. 1987;82(5):448-453.
2. Yao CA, Arnell TD. Hepatic artery pseudoaneurysm following laparoscopic cholecystectomy. *Am J Surg*. 2010;199(1):e10-e11.
3. Merrell SW, Schneider PD. Hemobilia. *West J Med*. 1991;155(6):621-625.
4. Sousa HT, Amaro P, Brito J, et al. Hemobilia due to pseudoaneurysm of the cystic artery. *Gastroenterol Clin Biol*. 2009;33(1, pt 1):80-82.
5. Shankar S, Russell RC. Haemorrhage in pancreatic disease. *Br J Surg*. 1989;76(8):863-866.

©2012 American Medical Association. All rights reserved.
Downloaded From: http://archsurg.jamanetwork.com/ on 04/24/2015