ORIGINAL ARTICLE

Antireflux Surgery Enhances Gastric Emptying

Mikko Viljakka, MD; Keijo Saali, MSc; Matti Koskinen, PhD; Lauri Karhumäki, MD; Jyrki Kössi, MD; Markku Luostarinen, MD; Ossi Teerenhovi, MD; Jouko Isolauri, MD

Objective: To evaluate the influence of antireflux surgery on gastric emptying.

Design: Nonrandomized controlled trial 3 months before and after surgical intervention.

Setting: Secondary and tertiary referral center.

Patients and Control Subjects: Twenty consecutive patients (7 women, 13 men), mean age 49.2 years, with symptomatic, objectively confirmed gastroesophageal reflux disease and 10 healthy control subjects (3 women, 7 men), mean age 37.3 years.

Intervention: Laparoscopic or open Nissen fundoplication (in 1 case Toupet 180° posterior hemifundoplication).

Main Outcome Measures: Gastric emptying scintigraphy, using solid food, in control subjects and patients 3 months before and 3 months after the operation; time to halving of the maximal activity and the activity remaining at 60, 100, and 120 minutes.

Results: Preoperative symptoms included pyrosis in 19 of 20 patients and regurgitation in 18. Three months postoperatively, 19 patients were symptom-free. The mean time to halving of the maximal activity decreased from 113 to 78 minutes ($P = .001$). Delayed gastric emptying was found postoperatively in 3 patients, compared with preoperative values, using activity at 60, 100, 120 minutes and the mean time to halving of the maximal activity as the variables. Compared with control subjects, gastric emptying was slower in patients preoperatively and faster postoperatively, but the difference was not statistically significant.

Conclusion: Gastric emptying is enhanced after antireflux surgery, along with cessation of symptoms and healing of esophagitis.

Arch Surg. 1999;134:18-21

From the Department of Surgery, the Medical School, University of Tampere, Tampere (Dr Viljakka); the Departments of Clinical Physiology and Surgery, Kanta-Häme Central Hospital, Hämeenlinna (Mr Saali and Dr Karhumäki); the Departments of Clinical Physiology and Surgery, Tampere University Central Hospital, Tampere (Drs Koskinen, Luostarinen, and Teerenhovi); the Department of Surgery, Loimaa District Hospital, Loimaa (Dr Kössi); and Department of Surgery, Turku University Central Hospital, Turku (Dr Isolauri), Finland.

THE PATHOGENESIS of gastroesophageal reflux disease is multifactorial.[1] In surgical management, Nissen fundoplication is the favored method, with success rates of 91% to 95%.[2,3] Multiple mechanisms of action have been suggested for Nissen fundoplication.[4-9] Restoration of the normal lower esophageal sphincter pressure with reduced frequency of transient lower esophageal relaxation is documented,[4,5] but its role in curing the esophagitis has been questioned.[6,7] Esophageal motor activity was found to improve after fundoplication.[8,9]

The role of gastric emptying in the pathogenesis of gastroesophageal reflux disease is controversial. Some investigators reported delayed gastric emptying in about 40% of patients with reflux[10,11] and esophagitis,[11,12] whereas others found no correlation between reflux and delayed gastric emptying,[13,14] and such delay was associated with normal rather than inflamed esophageal mucosa.[15] Accelerated gastric emptying could be demonstrated after Nissen fundoplication,[16,17] but not after the Hill operation.[18] The failure of antireflux operations has been associated with delayed gastric emptying.[19] The aim of the present study was to evaluate the influence of antireflux surgery on gastric emptying.

RESULTS

CLINICAL EXAMINATIONS

All patients had received medication for reflux symptoms; 14 had used proton pump inhibitors, and 8 had used histamine$_2$ blocking agents (some patients had used both types of medications). Cisapride, antacids, and sucralfate also were used. Preoperatively, 19 patients had pyrosis, 18 had regurgitation, and 5 had ex-

©1999 American Medical Association. All rights reserved.
Downloaded From: http://archsurg.jamanetwork.com/ on 11/28/2015

PATIENTS, CONTROL SUBJECTS, AND METHODS

PATIENTS, CLINICAL EXAMINATIONS, AND SUBJECTS

Twenty patients (7 women, 13 men), mean age 49 years (range, 28-70 years), underwent surgery for the treatment of symptomatic gastroesophageal reflux disease at the Kanta-Häme Central Hospital, Hämeenlinna, Finland, between October 1, 1995, and August 31, 1996. The diagnosis was based preoperatively on the presence and duration of pyrosis, regurgitation, and dysphagia and the use of medication to treat reflux symptoms. Preoperative examinations included esophagogastroduodenoscopy, esophageal manometry, and 24-hour pH monitoring. Pathological reflux was found by the 24-hour pH recording (pH <4.00 for >4.2% of the recording time) in 18 of 20 patients (mean, 23.3% of the total monitoring time). The other 2 patients had erosive esophagitis and had experienced symptoms for many years. The clinical assessment was repeated 1 month and 3 months after the operation, and at 3 months, a control esophagogastroduodenoscopy was performed to observe the healing of esophagitis and the location and competence of the fundic wrap.

Ten healthy volunteers (3 women, 7 men; mean age, 37 years; age range, 25-52 years) served as control subjects. The control subjects were using no medications.

OPERATION

Nissen fundoplication was performed on 16 patients by using a laparoscopic procedure and on 3 patients by using an open procedure (2 of these owing to previous abdominal surgery). A wrap 2 cm in length was constructed with a 50F Maloney bougie inside the esophagus. The short gastric vessels were not divided. One of the open operations was begun as a laparoscopic procedure but was converted to an open procedure owing to technical problems. For 1 patient with propulsive, low-amplitude peristalsis, the Toupet hemifundoplication was preferred.

GASTRIC EMPTYING SCINTIGRAPHY

The patients fasted from midnight before the test. The test meal was taken with a glass of water. The test steak consisted of technetium Tc 99m colloid–labeled egg (20 MBq), 50 g of minced meat, and 1 to 2 spoons of bread crumbs cooked in a microwave oven. Immediately after the meal, imaging with a gamma camera was begun with the patient in a semisitting position. Two cobalt 57 (^{57}Co) markers were attached on the skin. The dynamic stage of imaging lasted 30 minutes. Acquisition, at 1 frame per 20 seconds, was performed in an anteroposterior direction. Thereafter, static images for 5-minute periods were collected at 15- to 30-minute intervals, during which the patients were permitted to get up. The camera and seat positions were kept constant, and minor shifts were corrected with the aid of the ^{57}Co marker. Imaging was continued until the activity of gastric contents had decreased to less than half of the maximal value, or for a maximum of 240 minutes. The 10 control subjects underwent the same gastric emptying scintigraphy.

ANALYSIS OF GAMMA IMAGING

The dynamic imaging and the 5-minute static images were linked in a file in temporal order. At this stage, if necessary, the static images were adjusted with the spots of the ^{57}Co markers. Dynamic images were added as 5-minute periods to obtain dynamic stage activity values at 5, 10, 15, 20, 25, and 30 minutes. Half-time correction of technetium Tc 99m was performed. By using dynamic and static values, an activity curve was plotted, with background activity subtracted, expressing the activity as a percentage of the first time point. Activities (as percentages of the maximal activity) at 60, 100, and 120 minutes (A_{60}, A_{100}, and A_{120}) were interpolated from the 2 nearest measurement points, and the time required for the activity to decrease to half of the maximal activity was defined ($T_{1/2}$).

STATISTICAL ANALYSIS

We used the *t* test for paired samples to compare preoperative and postoperative data and the *t* test for unpaired samples to compare data for the patients and control subjects, with $P<.05$ considered significant. The mean differences with 95% confidence limits were calculated. Correlation coefficients were calculated for age and emptying data ($T_{1/2}$ and A_{60}). The study was approved by the ethics committees of Kanta-Häme Central Hospital and Tampere University Hospital, Tampere.

perienced dysphagia at some time. The respective numbers of patients experiencing these symptoms at 1 month after the operation were 0, 1, and 9, and at 3 months, they were 1, 1, and 2, respectively. The preoperative esophagogastroduodenoscopy grades for esophagitis (using Savary-Miller grading [grade 1, linear, nonconfluent erosions; grade 2, longitudinal, confluent, noncircumferential erosions; grade 3, longitudinal, confluent, circumferential erosions bleeding readily; and grade 4, ulcer]) were as follows: grade 0, 7 patients; grade 1, 7 patients; grade 2, 4 patients; grade 3, 1 patient; and grade 4, 1 patient. Two patients had Barrett esophagus, that was histologically confirmed (gastric-type epithelium >3 cm above the most cranial fold of gastric mucosa). Postoperative esophagogastroduodenoscopy showed no esophagitis (grade 0) in 18 patients and grade 1 in 1 patient; 1 patient refused to undergo esophagogastroduodenoscopy.

GASTRIC EMPTYING

In the preoperative imaging, the activity had fallen below 50% of the maximal before 100 minutes in 2 patients and before 120 minutes in 3 patients. In the postoperative imaging, the respective numbers of patients were 7 and 13. For these patients, the values at respective times were linearly extrapolated for statistical comparison. The means for all variables (**Table**) indicated enhanced gastric emptying 3 months after the operation. All changes were significant. For 3 patients, gastric emptying at 60, 100, or 120 minutes was slower or the $T_{1/2}$ was longer than

©1999 American Medical Association. All rights reserved.
Downloaded From: http://archsurg.jamanetwork.com/ on 11/28/2015

Comparison of Preoperative vs Postoperative Gastric Emptying Data for Patients and Data for Patients vs Control Subjects*

	Preoperative	Mean Difference† (95% Confidence Interval)	Postoperative	*P*†	Control Subjects‡
$T_{½}$, min	113.1 (40.5)	−35 (−54 to −17)	77.6 (26.6)	.001	93.3 (40.8)
A_{60}, %	83.1 (13.3)	−20 (−31 to −9)	63.2 (20.4)	.001	76.9 (28.5)
A_{100}, %	56.4 (16.7)	−28 (−40 to −16)	28.5 (24.4)	<.001	40.7 (31.6)
A_{120},%	42.9 (20.0)	−26 (−38 to −15)	16.5 (22.1)	<.001	29.3 (29.3)

*Unless otherwise indicated, data are given as mean (SD). $T_{½}$ indicates time until half of the radioactivity leaves the stomach; A_{60}, A_{100}, and A_{120}, activity remaining after 60, 100, and 120 minutes, respectively.

†Preoperative vs postoperative data.

‡Comparisons of preoperative and postoperative data for patients vs control subjects were not significant.

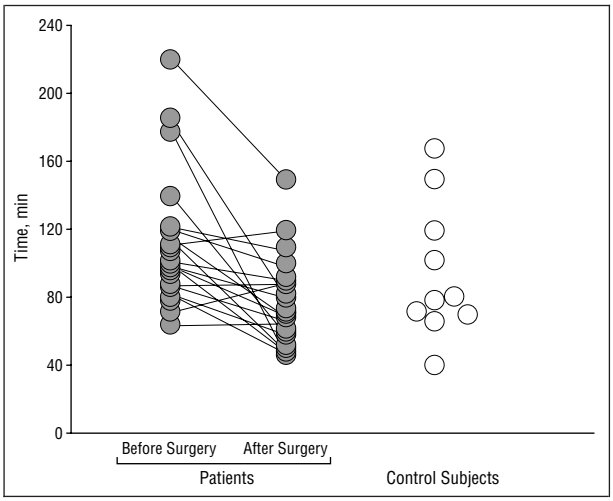

Figure 1. *The time required for half of the gastric contents to leave the stomach in patients before and after the operation and in control subjects.*

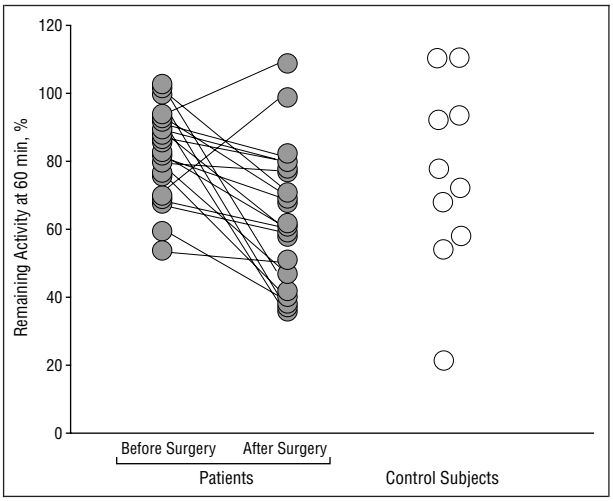

Figure 2. *The percentage of solid food retained at 60 minutes in patients before and after the operation and in control subjects.*

in the preoperative examinations. Compared with control subjects, the preoperative gastric emptying was slower in patients (Table), but no statistical difference was noted between the patients for preoperative or postoperative examinations and the control subjects. The variation in the gastric emptying rate was wide for the patients and the control subjects (**Figure 1** and **Figure 2**). No significant correlation was found between age and $T_{1/2}$ or A_{60} in the preoperative and postoperative examination results for patients or between age and $T_{1/2}$ or A_{60} for the patients and the control subjects.

COMMENT

Three months after antireflux surgery, gastric emptying was enhanced in most patients. By using $T_{1/2}$ or activity at 60 minutes as the variables, gastric emptying was enhanced in 18 of 20 patients. Simultaneously, there was total abolition of symptoms and esophagitis in 18 patients (90%). Although these findings may not be mutually explanatory,[18] they agree with the findings of previous studies[16,17] and could suggest a role for accelerated gastric emptying in the action mechanism of antireflux procedures.

For 3 of the patients in the present study, gastric emptying was slower after fundoplication than before, but for 2 of them, the preoperative rate was faster than the average of the patients. Delayed gastric emptying has been associated with the failure of antireflux procedures to abolish symptoms of reflux,[19] but these 3 patients were totally asymptomatic 3 months after the operation. These cases suggest that enhanced gastric emptying is not essential to the effectiveness of antireflux surgery. All patients with postoperative symptoms at 3 months had improved gastric emptying. Furthermore, no statistical difference in gastric emptying was found between preoperative and postoperative examination results for patients or between patients and control subjects.

Although the preoperative gastric emptying was slower in patients, we could not demonstrate as clear a distinction between patients with gastroesophageal reflux disease and control subjects as was demonstrated in previous studies,[10-12] because there was considerable overlap between and variation within the present study groups.

The enhancement of gastric emptying could have resulted from the reduction in gastric volume related to the use of the fundus for plication. Similar enhancement was not found with the Angelchik prosthesis.[20] Functional studies showed that the proximal stomach initially stores the solid component of food before its redistribution and emptying from the stomach,[21] and removal of this reservoir may lead to accelerated emptying. It also has been suggested that delayed proximal rather than total gastric emptying could be important in the induction of transient lower esophageal sphincter relaxation.[22] With simultaneous restoration of the lower esoph-

©1999 American Medical Association. All rights reserved.
Downloaded From: http://archsurg.jamanetwork.com/ on 11/28/2015

ageal sphincter pressure,[4] enhanced gastric emptying can promote the progress of gastric contents into the intestine, thus inhibiting reflux into the esophagus.

Esophageal transit times tend to normalize after Nissen fundoplication when the fundus is not mobilized,[23] as in the present study. The improvement of esophageal transit[23] and gastric emptying together may reflect improved upper gastrointestinal tract motility after antireflux surgery. Optimum esophageal motor function is desirable, since impairment is associated with esophagitis and reflux disease,[24,25] although the significance of this finding has been questioned.[26]

After fundoplication, some patients complain of postprandial fullness,[27] which may be related to delayed gastric emptying.[28] Postoperatively, the increased gastric wall tension together with the reduced gastric volume also may account for the fullness.[29] Heightened gastric tone can, in turn, enhance emptying. Flatulence also increases after fundoplication in some patients,[30] but it is not accompanied by an increase of the intra-abdominal gas volume,[30] which likewise may be explained by accelerated gastric emptying and possibly by normal, instead of abnormal, esophageal motility.[31]

To study gastric emptying, we used solid food, which seems to be preferable to liquids for detecting delayed emptying in patients with gastroesophageal reflux disease[18] or esophagitis.[11] Furthermore, solid food (with a glass of water) more closely mimics the postprandial state, when some patients experience excessive reflux.[32] In postoperative tests, the percentage of retention of solid food at 100 minutes was similar to the findings in previous studies,[16,17,19,28] as was the $T_{1/2}$.[33] The ages of the control subjects (mean, 37 years) and patients (mean, 49 years) differed, but there was no correlation between the age and gastric emptying, and gastric emptying was not influenced by age in previous studies.[10,13]

The symptoms of gastroesophageal reflux disease were relieved by antireflux surgery. At the 3-month postoperative follow-up, scintigraphy showed significantly enhanced gastric emptying. The preoperative gastric emptying for the patients was slower than for the control subjects, but in the small groups in the present study, no significant difference was found.

This study was supported by grants from the Finnish Foundation for Gastroenterological Research, Helsinki, and the Medical Research Fund of Tampere University Hospital, Tampere; and Medical Research Fund of Kanta-Häme Central Hospital, Hämeelinna.

Reprints: Jouko Isolauri, MD, Turku University Central Hospital, Kiinamyllynkatu 4-8, 20520 Turku, Finland (e-mail: jouko.isolauri@tyks.fi).

REFERENCES

1. Katz PO. Pathogenesis and management of gastroesophageal reflux disease. *J Clin Gastroenterol.* 1991;13(suppl 2):S6-S15.
2. DeMeester TR, Bonavina L, Albertucci M. Nissen fundoplication for gastroesophageal reflux disease: evaluation of primary repair in 100 consecutive patients. *Ann Surg.* 1986;204:9-20.
3. Shirazi S, Schulze K, Soper R. Long-term follow-up for treatment of complicated chronic reflux esophagitis. *Arch Surg.* 1987;122:548-551.
4. Ellis FH, Crozier RE. Reflux control by fundoplication: a clinical and manometric assessment of the Nissen fundoplication. *Ann Thorac Surg.* 1984;38:387-392.
5. Ireland AC, Holloway RH, Toouli J, Dent J. Mechanisms underlying the antireflux action of fundoplication. *Gut.* 1993;34:303-308.
6. Bancewicz J, Mughal M, Marples M. The lower oesophageal sphincter after floppy Nissen fundoplication. *Br J Surg.* 1987;74:162-164.
7. Fisher RS, Malmud LS, Lobis IF, Maier WP. Antireflux surgery for symptomatic gastroesophageal reflux. *Dig Dis.* 1978;23:152-160.
8. Gill RC, Bowes KL, Murphy PD, Kingma YJ. Esophageal motor abnormalities in gastroesophageal reflux and the effects of fundoplication. *Gastroenterology.* 1986; 91:364-369.
9. Grande L, Lacima G, Ros E, et al. Dysphagia and esophageal motor dysfunction in gastroesophageal reflux are corrected by fundoplication. *J Clin Gastroenterol.* 1991;13:11-16.
10. McCallum RW, Berkowitz DM, Lerner E. Gastric emptying in patients with gastroesophageal reflux. *Gastroenterology.* 1981;80:285-291.
11. Maddern GJ, Chatterton BE, Collins PJ, Horowitz M, Shearman DJC, Jamieson GG. Solid and liquid gastric emptying in patients with gastro-oesophageal reflux. *Br J Surg.* 1985;72:344-347.
12. Little AG, DeMeester TR, Kirchner PT, O'Sullivan GC, Skinner DB. Pathogenesis of esophagitis in patients with gastroesophageal reflux. *Surgery.* 1980;80:101-107.
13. Shay SS, Eggli D, McDonald C, Johnson LF. Gastric emptying of solid food in patients with gastroesophageal reflux. *Gastroenterology.* 1987;92:459-465.
14. Keshavarzian A, Bushnell DL, Sontag S, Yegelwel EJ, Smid K. Gastric emptying in patients with severe reflux esophagitis. *Am J Gastroenterol.* 1991;86: 738-742.
15. Schwizer W, Hinder RA, DeMeester TR. Does delayed gastric emptying contribute to gastroesophageal reflux disease? *Am J Surg.* 1989;157:74-80.
16. Maddern GJ, Jamieson GG. Fundoplication enhances gastric emptying. *Ann Surg.* 1985;201:296-299.
17. Jamieson GG, Maddern GJ, Myers JC. Gastric emptying after fundoplication with and without proximal gastric vagotomy. *Arch Surg.* 1991;126:1414-1417.
18. Velasco N, Hill LD, Gannan RM, Pope CE II. Gastric emptying and gastroesophageal reflux. *Am J Surg.* 1982;144:58-62.
19. Maddern GJ, Jamieson GG, Chatterton BE. Is there an association between failed antireflux procedures and delayed gastric emptying? *Ann Surg.* 1985;202:162-165.
20. Maddern GJ, Myers JC, McIntosh N, Bridgewater FHG, Jamieson GG. The effect of the Angelchik prosthesis on esophageal and gastric function. *Arch Surg.* 1991; 126:1418-1422.
21. Collins PJ, Houghton LA, Read NW, et al. Role of proximal and distal stomach in mixed solid and liquid meal emptying. *Gut.* 1991;32:615-619.
22. Lundell L, Anvari M, Collins PJ, Myers JC, Jamieson GG. The association between gastric emptying, gastric distension and transient lower esophageal sphincter relaxations in patients with gastroesophageal reflux disease. *Gastroenterology.* 1992;102:A478.
23. Luostarinen MES, Koskinen MO, Isolauri JO. Effect of fundal mobilisation in Nissen-Rossetti fundoplication on oesophageal transit and dysphagia. *Eur J Surg.* 1996; 162:37-42.
24. Singh P, Adamopoulos A, Taylor RH, Colin-Jones DG. Oesophageal motor function before and after healing of esophagitis. *Gut.* 1992;33:1590-1596.
25. Lin S, Ke M, Xu J, Kahrilas PJ. Impaired esophageal emptying in reflux disease. *Am J Gastroenterol.* 1994;89:1003-1006.
26. Timmer R, Breumelhof R, Nadorp JHSM, Smout AJPM. Ambulatory esophageal pressure and pH monitoring in patients with high-grade reflux esophagitis. *Dig Dis Sci.* 1994;39:2084-2089.
27. Negre JB. Post-fundoplication symptoms: do they restrict the success of Nissen fundoplication? *Ann Surg.* 1983;198:698-700.
28. Lundell LR, Myers JC, Jamieson GG. Delayed gastric emptying and its relationship to symptoms of "gas-bloat" after antireflux surgery. *Eur J Surg.* 1994;160: 161-166.
29. Holloway RH, Hongo M, Berger K, McCallum RW. Gastric distension: a mechanism for postprandial gastroesophageal reflux. *Gastroenterology.* 1985;89: 779-784.
30. Luostarinen M, Koskinen M, Reinikainen P, Karvonen J, Isolauri J. Two antireflux operations: floppy versus standard Nissen fundoplication. *Ann Med.* 1995; 27:199-205.
31. Bremner RM, DeMeester TR, Crookes PF, et al. The effect of symptoms and nonspecific motility abnormalities on outcomes of surgical therapy for gastroesophageal reflux disease. *J Thorac Cardiovasc Surg.* 1994;107:1244-1250.
32. DeMeester TR, Johnson LF, Joseph GJ, Toscano MS, Hall AW, Skinner DB. Patterns of gastroesophageal reflux in health and disease. *Ann Surg.* 1976;184: 459-469.
33. Vassilakis JS, Xynos E, Kasapidis P, Chrysos E, Mantides A. The effect of floppy Nissen fundoplication on esophageal and gastric motility in gastroesophageal reflux. *Surg Gynecol Obstet.* 1993;177:608-616.

©1999 American Medical Association. All rights reserved.
Downloaded From: http://archsurg.jamanetwork.com/ on 11/28/2015