ORIGINAL ARTICLE

Primary Common Bile Duct Closure

A. Kent Seale, MD; Walter P. Ledet, Jr, MD

Objective: To show that primary closure of the common bile duct following minicholecystectomy is safe and effective.

Design: Eighty-nine primary common bile duct closures done over 13 years.

Setting: General community hospital.

Patients: Patients with cholangiographic evidence of stones in the common bile duct.

Interventions: Minicholecystectomy followed by a primary common bile duct closure or common bile duct closure over a T tube.

Main Outcome Measures: Successful clinical result of primary common bile duct closure following minicholecystectomy.

Results: Eighty-nine primary closures of the common bile duct between 1983 and 1986, resulting in successful clinical outcomes.

Conclusion: Primary closure of the common bile duct following minicholecystectomy is safe, effective, and inexpensive.

Arch Surg. 1999;134:22-24

OBSTRUCTION of the common bile duct as a result of the presence of stones has historically been corrected by opening the common bile duct and removing the stones. The duct is then closed around a T tube. Unfortunately, the use of T tubes carries a significant morbidity. The tube can be dislodged before a tract has developed and reoperation becomes necessary. A T tube must be left in place from 3 to 4 weeks before removal. There is a large amount of pain associated with the presence of the T tube over such a long period. In addition, a drain must also be positioned, and postoperative x-ray films are necessary before removal. Patients are reluctant to return to work with a T tube in place and can lose from 3 to 4 weeks of work.

We believe that primary common bile duct closure using modern operative techniques can be as safe as primary common bile duct closure using a T tube. The patient returns home with 1 drain instead of 2 and the drain remains in place an average of 3 to 5 days. Early dislodgment of the drain does not always require reoperation and postdischarge x-ray films are not required. The patient has a smoother postoperative course, with less pain and an earlier return to work.

Recently, common bile duct stones found during laparoscopic cholecystectomy have been handled by laparoscopic transcystic duct exploration or endoscopic sphincterotomy. Liberman and Phillips[1] reviewed a group of 76 patients, 59 of whom had a laparoscopic cholecystectomy and laparoscopic transcystic duct exploration and 17 of whom had laparoscopic cholecystectomy and endoscopic sphincterotomy. Their length of hospital stay of 6 to 7 days and their cost of $15 000 to $20 000 was considerably higher than a common bile duct exploration with primary closure.

As early as 1917, Halstead[2] described primary closure of the common bile duct that was drained using a tube through the cystic duct stump. Later closures were done using only a Penrose drain in the hepatorenal recess. Mayo,[3] Kirschner,[4] Mirrizzi,[5] Edwards and Herrington,[6] and Herrington et al[7] have written articles supportive of primary closure of the

From the Sulphur Surgical Clinic, Sulphur, La.

This article is also available on our Web site: www.ama-assn.org/surgery.

©1999 American Medical Association. All rights reserved.
Downloaded From: http://archsurg.jamanetwork.com/ on 07/28/2015

MATERIALS AND METHODS

Methods for primary bile duct closure were developed in 1983. After a minicholecystectomy, a cholangiogram is done on the patients with laboratory and visual indications of an obstructed common bile duct. The ducts with stones are opened longitudinally in a convenient area. The relationship of the cystic duct to the incision in the common bile duct is not proven to be of consequence. The incision should not be extended within 1 cm of the bifurcation of the common bile duct. The stones in the common bile duct are removed either blind or using a choledochoscope, as well as Fogarty catheters, grasping forceps, irrigation, or stone baskets. The absence of stones in the common bile duct is verified using the choledochoscope. Using a headlight and ×2 magnification, the common bile duct is closed primarily using a 3-0 chromic running stitch (**Figure**). It is imperative that only small bites of the common bile duct are taken. A cystic duct cholangiogram is repeated after the bile duct has been primarily closed. A closed suction drain is always positioned.

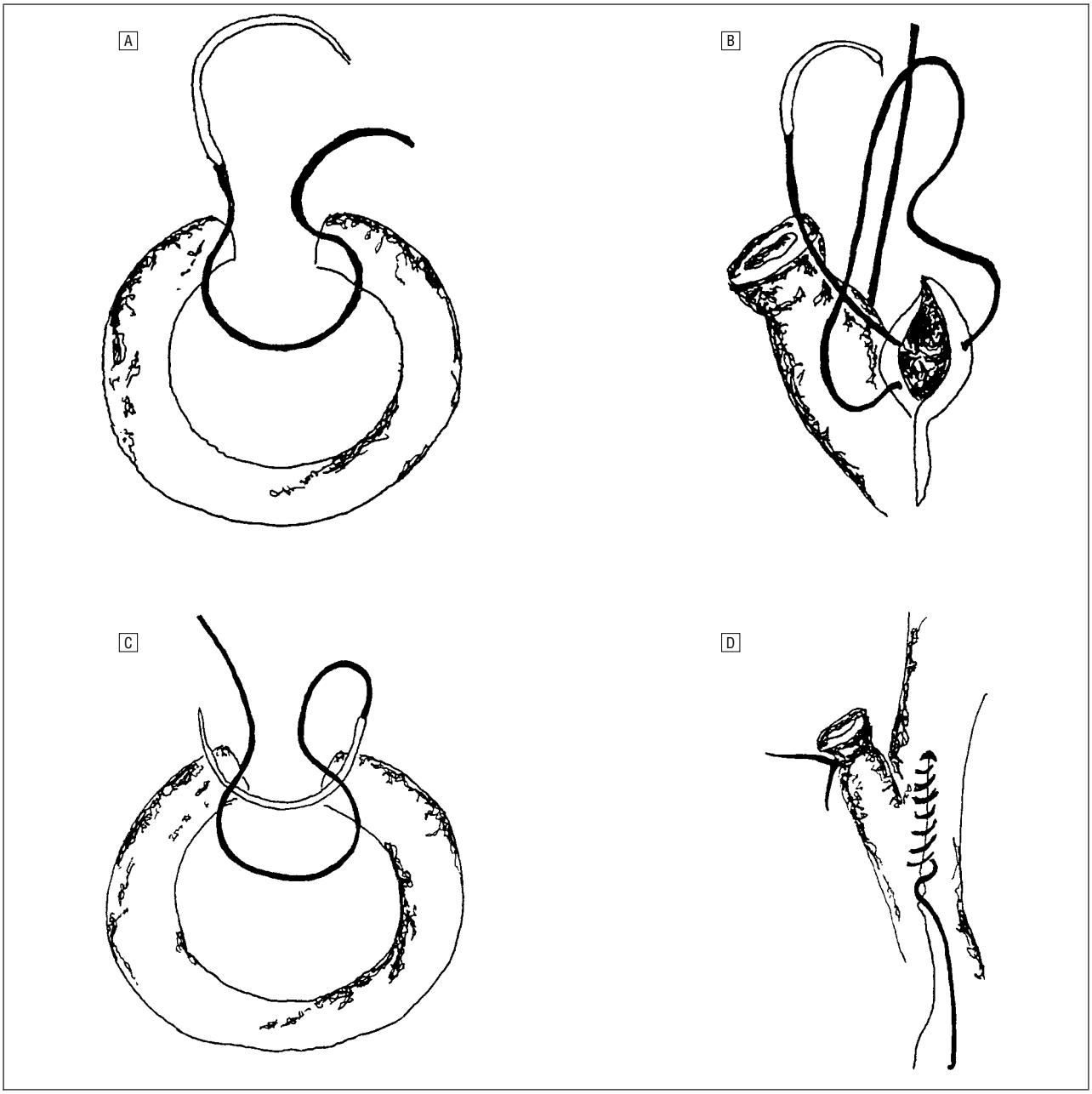

A, The initial stitch approximating only muscularis and mucosa is positioned at the proximal apex. B, The tail of the stitch is held and not tied. C, The suture proceeds distally to the apex, holding tension behind the running stitch. D, After reaching the apex, the suture line proceeds proximally approximating only the serosal layer. On reaching the proximal apex, the suture is tied.

©1999 American Medical Association. All rights reserved.
Downloaded From: http://archsurg.jamanetwork.com/ on 07/28/2015

Characteristics of Patients Who Underwent Primary Common Duct Closure

Patient Age Group, y	Primary Closure	Average Stay, d	T Tube†
20-30	7	2.5	1
30-40	7	2.1	1
40-50	5	3.8	2
50-60	9	2.1	0
60-70	16	3.1	4
70-80	27	4.1	10
80-90	15	4.5	0
90-100	3	6.0	0
Total	**89**	**3.6**	**18**

**The duration of hospital stay is an average of the length of stay for each designated age group. In calculating the average, there were some patients who stayed as short as 0 days (day of surgery) and some who stayed as long as 7 days.*

†A comparison of the average stay of patients with a T tube is inappropriate as this procedure is done on sicker patients with multiple problems.

common bile duct. We believe that primary common bile duct closure can be both safe and effective.

RESULTS

Of the 1882 cholecystectomies performed between 1983 and 1996, 107 common bile duct explorations were performed: primary closure was performed in 89 and T-tube closure was performed in 18.

Our patients for whom primary closure was performed ranged in age from 22 to 90 years (**Table**). The length of hospital stay for these patients ranged from 0 (day of surgery) to 7 days. Drains remained in place 3 to 10 days. We had no wound infections or drain tract infections. There were no associated intra-abdominal infections or abscesses and no phlebitis or pulmonary emboli. Postoperative bile leakage in all patients was controlled with the closed suction drainage; no reoperations were necessary. No patient returned with common bile duct strictures or retained stones and no patient who underwent primary common bile duct closure died postoperatively or within 90 days of discharge from the hospital.

CONCLUSIONS

Primary closure of the common bile duct offers improved patient care and should be considered a primary option. The average hospital costs for a minicholecystectomy, common bile duct exploration, and primary closure of the common bile duct was $5000 and the average length of hospital stay was 3.6 days. As opposed to T-tube drainage, the patient remained in the hospital for a shorter period and was not burdened over a 3- to 6-week interval by the T tube. Compared with laparoscopic transcystic exploration or endoscopic sphincterotomy, the average stay in the hospital was 2.6 less days, and the average cost was approximately $10 000 less.

Closure of the common bile duct is a safe, effective, and less expensive means of handling stones in the common bile duct. It requires a shorter hospital stay and is notably less expensive. Many patients return to work within 5 to 10 days.

Corresponding author: A. Kent Seale, MD, Sulphur Surgical Clinic, 914 Cypress St, Sulphur, LA 70663.

REFERENCES

1. Liberman MA, Phillips EH. Cost-effective management of complicated choledocholithiasis: laparoscopic transcystic duct exploration or endoscopic sphincterotomy. *J Am Coll Surg*. 1996;182:488-494.
2. Halstead WS. *Surgical Papers*. Vol 2. Baltimore, Md: Johns Hopkins University Press. 1924:427-472.
3. Mayo WI. An address on the surgery of the hepactic and common bile ducts. *Lancet*. 1923;1:1299-1302.
4. Kirschner M, ed. Operations on the gall bladder and the bile passage. In: Radvin IS, trans. Vol 2. *Abdomen and Rectum*. In: *Operative Surgery*. Philadelphia, Pa: JB Lippincott; 1933:460-517.
5. Mirrizzi PL. Primary suture of the common bile duct in choledocholithiasis. *Arch Surg*. 1942;44:44-54.
6. Edwards LW, Herrington JL Jr. Closure of the common bile duct following its exploration. *Am Surg*. 1953;137:189.
7. Herrington JL Jr, Dawson RE, Edwards WH, Edwards LW. Further consideration in the evaluation of primary closure of the common bile duct following its exploration. *Am Surg*. 1957;145:153-161.

Surgical Anatomy

The thoracic duct enters the neck on the left side of the esophagus, and, at the level of C7, arches laterally and forward on to the cervical pleura. It opens into the angle between the left internal jugular and subclavian veins. Its last half inch (ie, beyond its last valve) may be distended with venous blood.

1. Grant JCB. *A Method of Anatomy: Descriptive and Deductive*. 5th ed. Baltimore, Md: Williams & Wilkins; 1952:682-683.

©1999 American Medical Association. All rights reserved.
Downloaded From: http://archsurg.jamanetwork.com/ on 07/28/2015