

Parathyroid Autotransplantation During Thyroidectomy

Is Frozen Section Necessary?

Chung-yau Lo, FRCS(Edin); King-yin Lam, FRCPA

Objective: To evaluate the accuracy of parathyroid gland identification and the need for routine frozen section examination before parathyroid autotransplantation during thyroidectomy.

Design: A prospective case series.

Setting: An endocrine surgical unit.

Patients: From January 1, 1995, to December 31, 1997, parathyroid autotransplantation was attempted for devascularized or inadvertently removed glands in 152 (33.7%) of 450 patients during thyroidectomy. Before autotransplantation, a biopsy specimen of the transplanted tissue was sent for histological examination without frozen section confirmation.

Main Outcome Measures: Positive identification of parathyroid tissue in microscopic examination.

Results: Of 179 attempted autotransplantations of para-

thyroid glands, parathyroid tissue was confirmed in 167 biopsy specimens (93.3%). Incorrect identification of parathyroid gland occurred in 12 instances. The tissue mistaken as parathyroid gland included fat in 6 cases, thyroid tissue in 4 cases, lymph node in 1 case, and thymus in 1 case. Transplantation of at least 1 parathyroid gland (range, 1-3) was confirmed in 144 patients. For patients with confirmed parathyroid autotransplantation at risk of hypoparathyroidism (n = 112), postoperative transient hypocalcemia occurred in 22 (19.6%), while no patient developed any permanent hypocalcemia during a median follow-up of 6 months.

Conclusions: Devascularized or inadvertently removed parathyroid glands can be identified expeditiously without routine frozen section during thyroid surgery. Immediate autotransplantation should be performed and permanent hypoparathyroidism can be avoided with this measure.

Arch Surg. 1999;134:258-260

THE FIRST successful parathyroid autotransplantation was performed by Lahey¹ in 1926 in patients undergoing partial thyroidectomy. Although the practice of implanting parathyroid glands has a long surgical tradition, not until the past 20 years has indication for parathyroid autotransplantation extended to radical head and neck surgery, including total thyroidectomy.²⁻⁴ Parathyroid autotransplantation has been increasingly performed to prevent permanent hypoparathyroidism during total, subtotal, or completion thyroidectomy for benign or malignant conditions of the thyroid.⁵⁻¹¹

Although the technique of parathyroid autotransplantation varies, parathyroid identity is routinely confirmed intraoperatively by frozen section before autotransplantation.⁵⁻⁸ In fact, in an addendum to his 1926 report, Lahey stated

that 19 of 26 specimens autotransplanted were subsequently identified histologically as lymph nodes, rather than parathyroid glands.¹ This emphasizes the difficulty of correct identification of normal parathyroid glands for autotransplantation. The present study aims at documenting the accuracy of parathyroid gland identification and evaluating the need for routine frozen section examination before autotransplantation during thyroidectomy.

RESULTS

Parathyroid autotransplantation was attempted in 152 patients (33.7%). There were 26 males and 126 females whose ages ranged from 15 to 75 years (median, 42 years).

Types of operative procedures included total or near-total thyroidectomy in 64 patients, bilateral subtotal thyroid-

From the Departments of Surgery (Dr Lo) and Pathology (Dr Lam), University of Hong Kong Medical Centre, Queen Mary Hospital, Hong Kong, China.

PATIENTS AND METHODS

From January 1, 1995, to December 31, 1997, 450 patients underwent thyroidectomy for treatment of various thyroid diseases by a single surgeon or by senior surgical residents operating in conjunction with that surgeon. Any devascularized or inadvertently removed parathyroid gland was identified for autotransplantation, even for patients who underwent unilateral thyroid lobectomy. The suspected parathyroid gland was minced into small (0.5-mm) pieces of which 1 was sent for microscopic examination to confirm its histological identity. The remaining tissue was immediately implanted into a muscle pocket fashioned in the ipsilateral sternocleidomastoid muscle. Routine frozen section examination was not performed.

The accuracy of parathyroid gland identification and removal for autotransplantation is expressed herein as the numbers of positive biopsy specimens divided by the numbers of attempted parathyroid autotransplantations. The resected thyroid specimens were examined histologically, and the incidence of serendipitously identified glands during histological examination is expressed as the percentage of glands at risk. Replacement therapy with calcium supplement (calcium carbonate, 2-3 g/d) or calcitriol (Rocaltrol, 0.25-0.5 µg/d) or both was commenced in the presence of symptomatic hypocalcemia or a serum calcium level of 1.70 mmol/L or less (≤ 6.8 mg/dL) (reference range, 2.10-2.55 mmol/L [8.4-10.2 mg/dL]). Medications were gradually discontinued during 1 to 6 months of follow-up in the presence of normal serum calcium levels.¹¹

ectomy in 34, unilateral lobectomy in 33, ipsilateral total and contralateral subtotal thyroidectomy in 14, and completion total thyroidectomy by unilateral lobectomy in 7. The indications for surgery are listed in **Table 1**.

Of the 179 attempted parathyroid autotransplantations performed in 152 patients, 167 parathyroid glands (93.3%) were subsequently confirmed to be normal parathyroid tissue during histological examination of the biopsy specimens. One to 3 (median, 1) parathyroid glands were autotransplanted in 144 patients (94.7%): 1 gland in 123 (85.4%), 2 glands in 19 (13.2%), and 3 glands in 2 (1.4%). The final histological findings in the 12 biopsy specimens that did not confirm parathyroid tissue included fat (n = 6), thyroid (n = 4), lymphatic (n = 1), and thymic (n = 1) tissues. The accuracy of identification of parathyroid glands in relation to their position is shown in **Table 2**. Incorrect identification of parathyroid glands occurred during thyroidectomy for diffuse toxic goiter (n = 7) and nodular goiter (n = 5).

For the 119 patients who were at risk of developing postoperative hypocalcemia after bilateral or completion total thyroidectomy, parathyroid tissue reimplantation was confirmed in 112 patients. Twenty-two patients (19.6%) developed postoperative hypocalcemia requir-

Table 1. Indications for Surgery in 152 Patients With Attempted Parathyroid Autotransplantation

Primary Disease	No. (%)
Nodular goiter*	82 (54)
Graves disease*	32 (21)
Papillary carcinoma	19 (12)
Follicular adenoma	12 (8)
Follicular carcinoma	4 (3)
Miscellaneous†	3 (2)
Total	152 (100)

*Occult papillary carcinoma in 6 patients (3.9%).

†Anaplastic carcinoma (n = 2) and lymphoma of thyroid gland (n = 1).

Table 2. Position of Parathyroid Glands in Relation to Accuracy of Parathyroid Identification

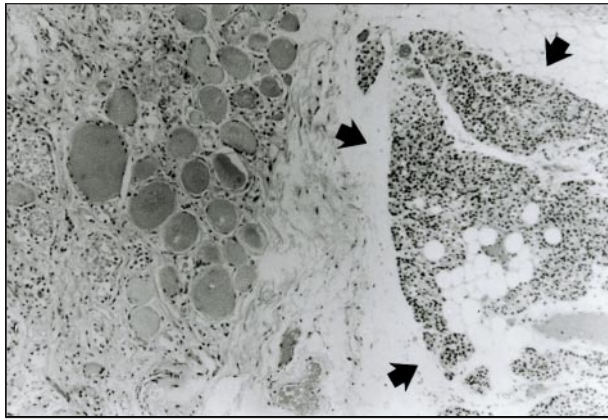
	Position			
	Right		Left	
	Upper	Lower	Upper	Lower
No. transplanted (n = 179)	37	51	35	56
No. confirmed (n = 167)	33	48	35	51
Accuracy, %	89	94	100	91

ing calcium or calcitriol supplements or both. During a median follow-up of 6 months (range, 6 weeks to 30 months), all patients reverted to normocalcemia without the need for medications. Of the 264 lobes of thyroid gland examined histologically, 11 parathyroid tissue fragments were identified attached to the resected thyroid lobe (**Figure**). The incidence of serendipitously discovered parathyroid glands in resected thyroid specimens was 2.1%.

COMMENT

Permanent hypoparathyroidism is a recognized complication of thyroidectomy and is of sufficient concern that surgeons may refrain from performing radical thyroid surgery, particularly for malignant neoplasms of the thyroid. Parathyroid autotransplantation has been shown to prevent permanent hypoparathyroidism during radical thyroidectomy. Investigators who selectively or routinely use parathyroid autotransplantation reported a low incidence of permanent hypoparathyroidism,^{8,9} with more recent series reporting an incidence of less than 2%.^{5-7,10,11} One earlier report¹² showed unfavorable results after parathyroid autotransplantation, with a permanent hypoparathyroidism rate of 43%. That report represents an exception to the uniform success, and the poor result was attributed to transplantation of insufficient parathyroid tissue.⁵

The technique of parathyroid autotransplantation differs for different series. Thin sectioning, mincing, and homogenization into a paste form have been described.^{2,9,13} In general, a frozen section biopsy specimen is obtained to confirm that it is parathyroid tissue before reimplantation is performed.⁵⁻⁸ In the case of sur-



Photomicrograph showing a parathyroid gland (arrows) attached to the resected thyroid specimen at a subcapsular position (hematoxylin-eosin, original magnification $\times 10$).

gery for malignant disease, frozen section examination can also disclose the presence of malignant involvement of the parathyroid gland and avoid the reimplantation of tumor cells.⁵ Cervical exploration for primary hyperparathyroidism by experienced surgeons has been shown to be the best localization tool to detect abnormal parathyroid gland, with a success rate of 95% to 99%.^{14,15} There is no doubt that enlarged parathyroid glands can be identified expeditiously in their normal or ectopic sites by experienced surgeons. However, it is generally agreed that the identification of normal parathyroid glands can be difficult. The ability of surgeons to identify and preserve parathyroid glands during thyroid surgery has not been well documented and is indirectly reflected by the incidence of permanent hypocalcemia. Routine biopsy of all normal glands is not necessary and should not be recommended. In addition, extensive dissection to identify normal glands should be avoided because of potential devascularization and damage to normal glands. A prospective study to assess the accuracy of correct identification of all parathyroid glands during thyroidectomy would be impractical or unethical.

Intraoperative frozen section confirmation was routinely performed and only patients with confirmed parathyroid tissue reimplantation were included in previous reports.⁵⁻⁸ As a result, the ability of the surgeons to identify devascularized or inadvertently removed parathyroid glands for autotransplantation has not been documented. Salander and Tisell⁸ reported on 86 of 97 patients with well-differentiated thyroid carcinoma who had parathyroid tissue implanted during total thyroidectomy. Biopsy specimens were taken from 132 of the 183 implanted parathyroid glands. The reason for not taking specimens in all cases was the fact that some glands were unquestionable on their macroscopic appearance and the ambition to save a maximal amount of parathyroid tissue.⁸ Some parathyroid glands were implanted even before the result of the frozen section biopsy was known.

Parathyroid autotransplantation is advocated because it is simple and effective in preventing permanent hypoparathyroidism by preserving functions of damaged para-

thyroid glands. Frozen section examination adds additional cost and time to the operation. This is particularly true when inadvertently removed glands are identified at the end of the operation when the resected thyroid lobe is examined. Various sites of autotransplantation have been described,^{2,13} although the neck remains an ideal site for patients during thyroidectomy except in surgery for medullary carcinoma in patients with multiple endocrine neoplasia type 2.⁵

Our results showed that devascularized or inadvertently removed glands can be accurately identified before autotransplantation. Most thyroidectomies were performed for benign thyroid conditions, and the risk of reimplantation of malignant tissue should be negligible. The fact that only 1 of the 12 incorrectly identified tissues was confirmed to be lymphoid in origin suggests that implantation of lymph node or metastasis is unlikely. Immediate autotransplantation of suspected devascularized or inadvertently removed glands should be attempted without the need for routine frozen section confirmation. Not only can a maximal amount of parathyroid tissue and operative time be saved, but ischemic damage to the transplanted parathyroid tissue can be reduced.

Reprints: Chung-yau Lo, FRCS(Edin), Division of Endocrine Surgery, Department of Surgery, University of Hong Kong Medical Centre, Queen Mary Hospital, Pokfulam, Hong Kong, China (e-mail: cylo@hkucc.hku.hk).

REFERENCES

1. Lahey FH. The transplantation of parathyroids in partial thyroidectomy. *Surg Gynecol Obstet.* 1926;62:508-509.
2. Wells SA, Ross AJ, Dale JK, Gray RS. Transplantation of the parathyroid glands: current status. *Surg Clin North Am.* 1979;59:167-177.
3. Saxe A. Parathyroid transplantation: a review. *Surgery.* 1984;95:507-526.
4. Baumann DS, Wells SA Jr. Parathyroid autotransplantation. *Surgery.* 1993;113:130-133.
5. Olson JA Jr, DeBenedetti MK, Baumann DS, Wells SA Jr. Parathyroid autotransplantation during thyroidectomy: results of long-term follow-up. *Ann Surg.* 1996;223:472-480.
6. Shaha AR, Burnett C, Jaffe BM. Parathyroid autotransplantation during thyroid surgery. *J Surg Oncol.* 1991;46:21-24.
7. Walker RP, Paloyan E, Keley TF, et al. Parathyroid autotransplantation in patients undergoing a total thyroidectomy: a review of 261 patients. *Otolaryngol Head Neck Surg.* 1994;111:258-264.
8. Salander H, Tisell LE. Incidence of hypoparathyroidism after radical surgery for thyroid carcinoma and autotransplantation of parathyroid glands. *Am J Surg.* 1977;134:358-362.
9. Paloyan E, Lawrence AM, Paloyan D. Successful autotransplantation of the parathyroid glands during total thyroidectomy for carcinoma. *Surg Gynecol Obstet.* 1977;145:364-368.
10. Smith MA, Jarosz H, Hessel P, Lawrence AM, Paloyan E. Parathyroid autotransplantation in total thyroidectomy. *Am Surg.* 1990;56:404-406.
11. Lo CY, Lam KY. Postoperative hypocalcemia in patients who did or did not undergo parathyroid autotransplantation during thyroidectomy: a comparative study. *Surgery.* 1998;124:1081-1087.
12. Ohman V, Granberg P, Lindell B. Function of the parathyroid glands after total thyroidectomy. *Surg Gynecol Obstet.* 1978;146:773-778.
13. Funahasi H, Sutoh Y, Imai T, et al. Our technique of parathyroid autotransplantation in operation for papillary thyroid carcinoma. *Surgery.* 1993;114:92-96.
14. Kaplan EL, Yashiro T, Salti G. Primary hyperparathyroidism in the 1990s: choice of surgical procedures for this disease. *Ann Surg.* 1992;215:300-317.
15. Van Heerden JA, Grant CS. Surgical treatment of primary hyperparathyroidism: an institutional perspective. *World J Surg.* 1991;15:688-692.