

Sporadic Primary Hyperparathyroidism in Young Patients

A Separate Disease Entity?

C. Richard Harman, MD; Jon A. van Heerden, MD; David R. Farley, MD; Clive S. Grant, MD; Geoffrey B. Thompson, MD; Kathleen Curlee, RN

Hypothesis: Sporadic primary hyperparathyroidism (1 HPT) in young persons is thought to be extremely rare. The exact incidence is unknown and little is known of the characteristics of the disease.

Methods: From 1976 to 1998, 33 patients aged 19 years or younger underwent operation for sporadic 1 HPT at a single institution. Data were recorded regarding the clinical, surgical, pathologic, and biochemical aspects, as well as long-term patient follow-up.

Results: There were 17 male subjects and 16 female subjects ranging in age from 9 to 19 years (median age, 17 years). Thirty-one (94%) were symptomatic: 14 (42%) had renal stones, 9 (27%) had bone disease, 1 (3%) had pancreatitis, and 7 (21%) had vague nonspecific symptoms alone. The high incidence of symptoms was matched by correspondingly high biochemical values (mean serum calcium level, 3.02 mmol/L [12.1 mg/dL]) and large

adenomas (mean weight, 967 mg). Five patients (15%) underwent exploration for persistent/recurrent 1 HPT. Thirty-one patients (94%) were normocalcemic postoperatively. One patient was temporarily hypocalcemic. No patient had vocal cord paralysis or paresis. Two patients developed recurrent disease in the mean follow-up period of 10.3 years. None have shown evidence of an inherited disorder.

Conclusions: It appears that 1 HPT in young patients presents as a more severe disease, in terms of symptoms, biochemistry, and extent of pathologic findings. Physicians should be aware that 1 HPT does occur in young persons in a nonfamilial setting and that it may be responsible for a wide spectrum of symptoms. As in the adult population, 1 HPT is safely and effectively treated with surgical intervention.

Arch Surg. 1999;134:651-656

SPORADIC PRIMARY hyperparathyroidism (1 HPT) in young persons is thought to be extremely rare, although the exact incidence is unknown.¹⁻³ The surgical literature regarding the disease is limited to case reports and a few small series of cases. In 1982, Allo et al¹ described 53 young patients with 1 HPT, only 18 of whom were younger than 18 years and half of whom had chief cell hyperplasia. Ten of the 53 patients had an inherited multiple endocrine neoplasia syndrome. Rapaport et al⁴ documented a series of 7 patients younger than 17 years with sporadic 1 HPT. In this series, the disease appeared different than that in adults in that all patients were symptomatic with a high incidence of bone disease and nephrolithiasis. It was also noted that there was a higher incidence of the disease found in young male subjects, which is in sharp contrast to the preponderance of the dis-

ease in female subjects in the adult population.

We have compiled a database of 33 patients with sporadic 1 HPT presenting to our institution at age 19 years or younger. By comparing these patients with a large adult population of patients with 1 HPT,⁵ we have identified several areas in which the disease differs significantly between the 2 groups.

RESULTS

DEMOGRAPHICS

There were 17 male subjects and 16 female subjects who ranged in age from 9

From the Department of Surgery, Mayo Clinic and Mayo Foundation, Rochester, Minn.

This article is also available on our Web site: www.ama-assn.org/surgery.

PATIENTS AND METHODS

From a total of 49 patients aged 19 years or younger with 1 HPT (1976-1998) at the Mayo Clinic in Rochester, Minn, 33 patients underwent an operation for sporadic 1 HPT. Patients with multiple endocrine neoplasia or any associated non-multiple endocrine neoplasia familial diseases were excluded (n = 16).

We examined the patient demographics, pre-operative symptoms and complications of the disease, laboratory values, localization techniques, operative procedure and postoperative complications, pathologic findings, and immediate and long-term disease status. Follow-up was obtained by review of the medical records and direct contact with the patient and/or home physician.

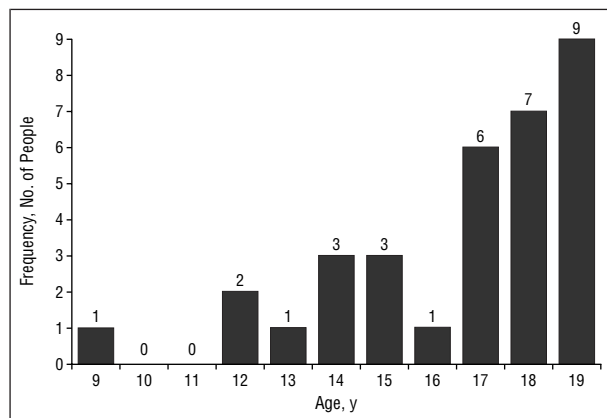


Figure 1. Age histogram of young patients with primary hyperparathyroidism.

to 19 years (median age, 17 years) at presentation (Figure 1). Five patients (15%) had persistent disease, having undergone unsuccessful exploration elsewhere prior to our evaluation.

SYMPTOMS AT PRESENTATION

Eighty-two percent (n = 27) of the patients were symptomatic, with 20 patients having major symptoms attributable to 1 HPT: renal stones, bone disease, or pancreatitis. Twenty-one percent (n = 7) had symptoms that were categorized as nonspecific (Table 1).

The most common finding was renal colic, defined as pain attributed to the documented history of the passage of a kidney stone or the presence of kidney stones on radiologic examination. Of the 14 patients (42%) presenting with kidney stones, all but 2 had symptoms and 5 had required surgical intervention. Bone disease, which was present in 9 patients (27%), implied bone pain, typical x-ray film changes, diminished bone densitometry, or actual fractures. Two patients had lytic lesions in their long bones, the most severe case being a 14-year-old girl who had been healthy until the age of 11 years when she developed genu valgum requiring orthopedic intervention. In addition, mul-

Table 1. Symptoms in 33 Young Patients With Primary Hyperparathyroidism

Symptoms	No. (%) [*]
Major symptoms from	20 (61)
Kidney stones	14 (42)
Bone disease	9 (27)
Pancreatitis	1 (3)
Nonspecific symptoms alone	7 (21)
Severe fatigue	4 (12)
Depression	1 (3)
Fatigue, anorexia, and weight loss	1 (3)
Severe fatigue, polydipsia, polyuria, and hypertension	1 (3)
Asymptomatic	6 (18)
Total	33 (100)

*Some patients had more than 1 symptom.

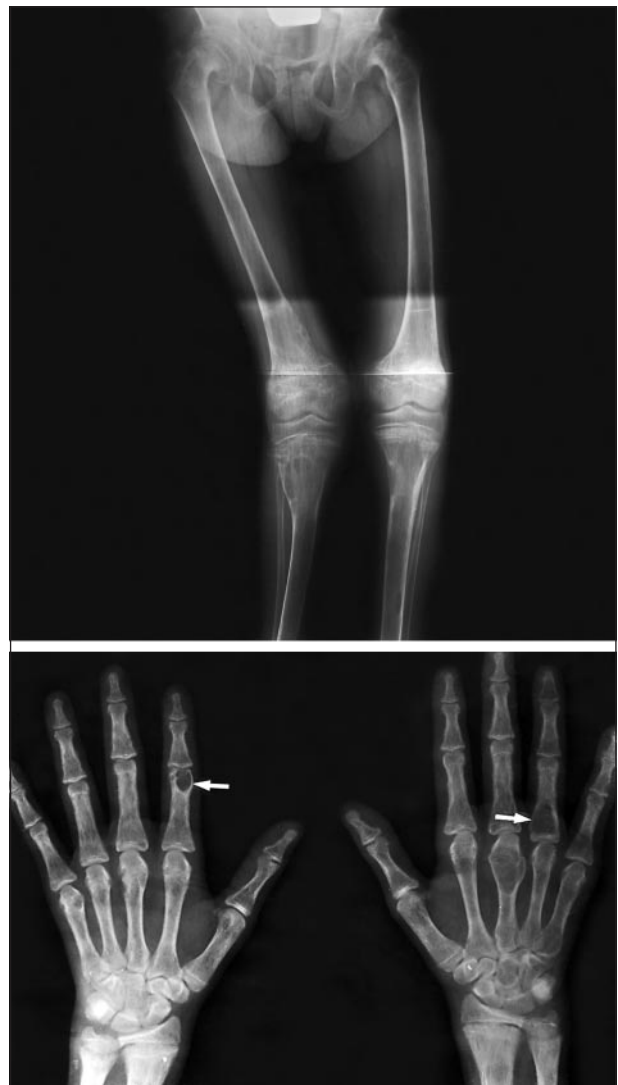

Figure 2. Top, Severe genu valgum. Bottom, Multiple brown tumors (arrows).

iple lytic lesions (brown tumors) were present in her metacarpal bones (Figure 2, top and bottom).

One patient presented with acute pancreatitis and required hospitalization for 10 days. This 11-year-old girl

Table 2. Biochemical Data of 33 Young Patients With Primary Hyperparathyroidism*

Biochemical Value and Unit	No. of Patients Undergoing Test	Mean	Range	Reference Range
Serum calcium, mmol/L (mg/dL)	100	3.02 (12.1)	2.55-4.55 (10.2-18.2)	2.22-2.52 (8.9-10.1)
Serum phosphorus, mmol/L (mg/dL)	100	0.93 (2.9)	0.61-1.32 (1.9-4.1)	0.81-1.45 (2.5-4.5)
Urinary calcium, mmol/d (mg/24 h)	100	99.25 (397)	29.75-282.50 (119-1370)	0-62.50 (0-250)
ICMA, pmol/L	36	9.9	2.7-34	1-5.2
PTH, pmol/L	64	22.1	2.7-170	1.0-5.2

*ICMA indicates immunochemiluminescent assay; PTH, parathyroid hormone.

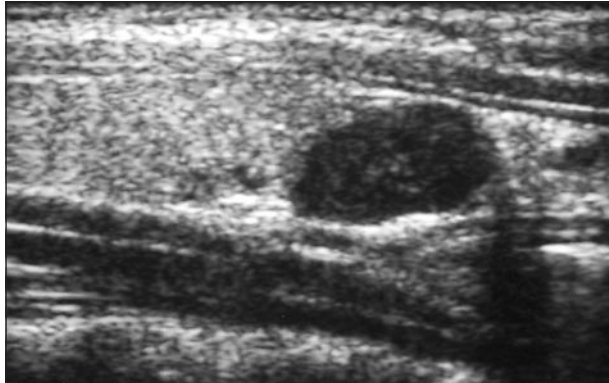


Figure 3. An ultrasound view of a 400-mg adenoma in an 11-year-old girl who presented with pancreatitis, renal stones, lethargy, and weight loss.

also had a history of renal stones, bone disease, a weight loss of 44.1 kg, anorexia, and severe fatigue. In those patients classified as having major symptoms, 7 also had associated nonspecific symptoms (4 with fatigue, 4 with polydipsia and polyuria, 3 with weight loss, 1 with headache, and 1 with anxiety). In the remaining asymptomatic group (n = 6), the disease was discovered coincidentally during the evaluation of an unrelated medical problem.

Three patients presented with a serum calcium level greater than 3.87 mmol/L (>15.5 mg/dL). One patient presented with hypercalcemic crisis and had a serum calcium level of 4.55 mmol/L (18.2 mg/dL). This patient required large-volume intravenous saline infusion and both mithramycin and calcitonin preoperatively and a semiurgent operative procedure with excision of a 1.6-g parathyroid adenoma.

BIOCHEMISTRY

All patients in the study were hypercalcemic. The relevant biochemical details are listed in **Table 2**.

LOCALIZATION

Prior to their operation, 17 patients had preoperative localization studies. Small-part ultrasonography was the most common modality employed (n = 16), with a sensitivity of 70% and an accuracy of 70%. **Figure 3** shows the typical ultrasound image of a parathyroid adenoma. Other localization studies employed were computed tomographic (CT) scanning (n = 3), thallium-technetium sestamibi scanning (n = 2), and magnetic resonance imaging (n = 1). Three such studies clearly identified the adenoma (CT, 1; thallium-technetium scanning 1; and magnetic resonance imag-

ing, 1). The indications for preoperative localization in those who had not had previous surgery were young age and disease severity at presentation.

Three of the 5 patients who had persistent disease had preoperative localization. Findings from half of these localizing studies (CT, 2; ultrasonography, 1; and thallium-technetium scanning, 1) were normal, while the other half were abnormal (CT, 1; ultrasonography, 2; and thallium-technetium scanning, 1). The 2 patients who did not have preoperative localization were thought to have had an inadequate exploration elsewhere and were operated on in 1977 prior to currently established localization techniques.

SURGERY AND PATHOLOGIC EXAMINATION

All patients underwent operative intervention. Thirty-one patients had cervical exploration and 2 had combined cervical-mediastinal exploration requiring sternotomy. Chief cell adenomas were removed in 31 patients (mean weight, 967 mg; median, 410 mg; range, 100-9760 mg). No patient was found to have parathyroid hyperplasia. In 2 patients, no abnormal parathyroid tissue was removed. Both sides of the neck were routinely explored and additional normal glands were identified in all but 1 patient, who had a thymic adenoma. Sixteen patients had all 4 glands identified, 7 had 3, 7 had 2, 2 had 1, and in 1 patient, no parathyroid glands were identified.

COMPLICATIONS

There was no long-term morbidity. One patient was rendered temporarily hypocalcemic and required calcium supplementation for 6 months; this patient had 2 remaining normal glands (after removal of a 1450-mg adenoma) on which biopsies were performed, which likely resulted in some degree of parathyroid devascularization. Two patients had small superficial hematomas that did not require drainage. One patient had an area of superficial skin necrosis on the superior skin flap of the cervical incision. No patient had either temporary or permanent recurrent laryngeal nerve dysfunction.

FOLLOW-UP

Long-term follow-up via telephone interview was possible in 29 of the 33 patients. In the 4 patients whom we were unable to contact, documented 1-month postoperative serum calcium levels were normal. Long-term follow-up ranged from 1 to 266 months, with a mean of 123 months (10.3 years).

Thirty-one patients were initially cured (rendered normocalcemic) after removal of a parathyroid adenoma. Two patients in whom no abnormal tissue was removed remained hypercalcemic postoperatively. One of these patients, an 18-year-old woman, underwent an unsuccessful reoperation after a negative exploration elsewhere. Postoperatively, a CT scan of the neck and chest was normal and the patient declined a third exploration. Her serum calcium level remained elevated for 6 years, after which the level spontaneously returned to normal.

The other patient who was not cured had 2 normal superior glands identified at cervical exploration. Both inferior glands could not be identified. A diagnosis of mediastinal adenoma was pursued. The patient had a normal thallium-technetium scan. Because the original biochemical diagnosis of 1 HPT was equivocal, the diagnosis was questioned. She was discharged from the study, but 4 years after her unsuccessful surgery she remains hypercalcemic (serum calcium level, 2.92 mmol/L [11.7 mg/dL]) with renal stones.

Two patients who initially recovered have developed recurrent disease. One of them underwent the removal of a 1240-mg adenoma from the left superior position. A normal left inferior gland was seen, but no glands were identified on the right side. This patient developed hypercalcemia and renal stones 17 years later. A 2½ gland parathyroidectomy for hyperplasia resulted in normocalcemia. The other patient had a hypercalcemic crisis (serum calcium level, 3.42 mmol/L [13.7 mg/dL]) 9 years after his original operation (a 1550-mg adenoma excised). At the time of the second exploration, a 910 mg second adenoma was excised, and the the patient's serum calcium level has since remained normal for 11 years.

At long-term follow up, 32 of patients (97%) remain surgically cured of 1 HPT. No patients have developed features of associated endocrinopathies or have offspring with parathyroid disease that might suggest familial disease.

COMMENT

Sporadic 1 HPT in young patients is thought to be extremely rare. The exact incidence is unknown and little is known of the characteristics of the disease.^{1-4,6-8} The prevalence of 1 HPT has been suggested as being approximately between 1 and 3 in 1000 adolescents.⁹ This study represents the largest group of patients younger than 20 years with sporadic 1 HPT evaluated and treated at a single institution. During the study period, 4919 patients were operated on at our institution for 1 HPT. These 33 patients, therefore, represent 0.7% of such patients, emphasizing the extreme rarity of 1 HPT in the young. Several differences between the adult group and this group are apparent. Comparing the results of this study with a previous study from this institution of all patients with 1 HPT in a 2-year period⁵ highlights the differences (**Table 3**).

In contrast to our adult population, 1 HPT in young patients seems to be at least as common in males; others report that 1 HPT is even more common in young men than in young women.^{1,3,6,8} The preponderance of 1 HPT in women is attributed to an increase in the incidence of 1 HPT in postmenopausal women.¹⁰

Table 3. Comparison of Young and Adult Patients With Primary Hyperparathyroidism

Variable	Adult Patients (n = 379)	Young Patients (n = 33)
Female patients, %	74	48
Patients with symptoms, %	44	79
Mean serum calcium level, mmol/L (mg/dL)	2.82 (11.3)	3.02 (12.1)
Mean weight of adenoma, mg	948	967

Most of the patients (82%) in this series had symptoms that could be directly attributable to 1 HPT. This is in contrast to our adult series, where only 44% had overt symptoms and most patients were diagnosed from routine blood screening. Some of our young patients had severe symptoms, which at times were life threatening. In fact, 3 patients had serum calcium levels higher than 3.87 mmol/L (>15.5 mg/dL), which is tantamount to a hypercalcemic crisis in the adult population.^{11,12}

One of the striking findings of this study was the severity of the young patients' symptoms. Most patients with renal stones were symptomatic, and 5 had required surgical intervention for nephrolithiasis. Three of the 10 patients with bone disease had severe changes on x-ray films, and 1 patient had genu valgum, had stopped growing, and required orthopedic surgical intervention.

While others have noted an increase in incidence of both renal (in children with nephrolithiasis, approximately 6% have 1 HPT) and bone disease,^{1,13} to our knowledge, none have commented on the generalized severity of symptoms identified in this study group. On the contrary, some authors^{3,14,15} have suggested that the incidence of renal involvement is less than that of their adult counterparts. There are reports of severe bone disease in which the patients developed genu valgum.⁶ The changes seen are similar to the changes seen in rickets, and the association with 1 HPT is not well reported.⁴ A single patient in this series presented with acute pancreatitis. As in the adult population, this is a rare complication of the disease, but it has been reported previously.^{16,17}

The severity of symptoms may be reflected in the magnitude of the serum calcium level and the large size and weight of the glands removed, which were both as high as those in the adult population. Does this mean that it is a different disease than the one in the adult population? Probably not; it is more likely that a biased sector of patients with this disease is seen, and that the patients being identified are the ones with severe disease who have become symptomatic. Only 18% of our patients were diagnosed incidentally, in contrast to our adult series,⁵ where the asymptomatic patients made up 56% of the group. This is a trend that is historically well known. In the 1930s, half of the patients had renal stones and severe bone disease, whereas most patients are now diagnosed even before they become symptomatic. The younger patients are much less likely to undergo a serum calcium level screening than their adult counterparts; thus, 1 HPT may be a more common entity in young people than previously thought.⁸ Physicians should be aware that this disease does exist in the young and may be a cause of nonspecific symptoms such

as lethargy, failure to thrive, growing problems, headaches, and the more well-known symptoms of renal stones, bone pain and deformities, and pancreatitis. Delay in diagnosis of this disease can be associated with long-term renal dysfunction.¹⁸ While only 1 patient in this study underwent thallium-technetium sestamibi scanning, 3 of the 33 patients had a mediastinal adenoma excised (2 via sternotomy). We were similarly struck by the high incidence (15%) of failed initial operation in this group of patients and would suggest that all young patients have a thallium-technetium sestamibi scan prior to surgery to help localize the tumor and to exclude a mediastinal adenoma to prevent unsuccessful surgery in these young patients.

The surgery for this disease in the sporadic form can be performed as safely as in adults despite the fact that many patients had serum calcium levels that were dangerously high (as long as the patients are well-hydrated preoperatively). None of the patients in this study developed post-operative problems secondary to their hypercalcemia, and most of the operations can be performed electively.

Allo et al¹ stated that hyperplasia was common in these younger patients, although she included all patients with 1 HPT, including those with multiple endocrine neoplasia. This was not the case in our study. We excluded patients with multiple endocrine neoplasia, and only 1 of our patients had 4-gland hyperplasia identified with operative intervention and long-term follow-up. Huang et al⁸ studied 100 young patients with HPT reported in the literature. While 30 had hyperplasia, 87% of those with hyperplasia were neonates. Neonates should be considered a different group and characteristically do have hyperplasia.¹⁹⁻²² We have identified only 1 patient with definite hyperplasia and 1 with a double adenoma, both identified many years after their initial curative surgery. This emphasizes 2 points: (1) although hyperplasia is rare in young patients, these patients need to be screened for the disease as in adults, and (2) young patients need long-term follow-up.

One of the 2 patients who were not cured by operation underwent "spontaneous" normalization of her serum calcium level 6 years after cervical exploration. Although this is a rare event, it is well documented and is most likely due to partial or total devascularization of the abnormal gland during cervical exploration.²³

CONCLUSION

We have demonstrated several differences in the presentation of sporadic 1 HPT in the young patients compared with adult patients. It is likely that 1 HPT is only diagnosed when the symptoms are severe and that we may actually greatly underestimate the number of young people with this disorder. Physicians should be aware that 1 HPT may be responsible for a wide spectrum of symptoms. A serum calcium level test is useful to screen the young patient presenting with constitutional or vague symptoms potentially attributable to renal stones, bone disease, or pancreatitis. The disease is usually due to a single adenoma, and surgery is an extremely safe and effective method of preventing complications of this disease.

Presented at the 106th Scientific Session of the Western Surgical Association, Indianapolis, Ind, November 16, 1998.

Corresponding author: Jon A. van Heerden, MD, Department of Surgery Mayo Clinic, 200 First St SW, Rochester, MN 55905.

REFERENCES

- Allo M, Thompson NW, Harness JK, Nishiyama RH. Primary hyperparathyroidism in children, adolescents, and young adults. *World J Surg.* 1982;6:771-776.
- Girard RM, Belanger A, Hazel B. Primary hyperparathyroidism in children. *Can J Surg.* 1982;25:11-32.
- Bjernulf A, Hall K, Spogren I, et al. Primary hyperparathyroidism in children. *Acta Paediatr Scand.* 1970;59:249-258.
- Rapaport D, Ziv Y, Rubin M, Huminer D, Dintsman M. Primary hyperparathyroidism in children. *J Pediatr Surg.* 1986;21:395-397.
- van Heerden JA, Grant CS. Surgical treatment of primary hyperparathyroidism: an institutional perspective. *World J Surg.* 1991;15:688-692.
- Heath H, Hodgson SF, Kennedy MA. Primary hyperparathyroidism: incidence, morbidity and potential economic impact in a community. *N Engl J Med.* 1980;302:189-193.
- Makhdoomi KR, Chalmers J, Campbell IW, Browning GGP. Delayed diagnosis of juvenile primary hyperparathyroidism. *J R Coll Surg Edinb.* 1996;41:351-353.
- Huang C-B, Huang S-C, Chou F-F, Chen W-J. Primary hyperparathyroidism in children: report of a case and a brief review of the literature. *J Formos Med Assoc.* 1993;92:1095-1098.
- Horowitz M, Nordin BEC. Primary hyperparathyroidism. In: Norbin BEC, Neel AG, Morris HA, eds. *Metabolic Bone and Stone Disease*, 3rd ed. London, England: Churchill Livingstone Inc; 1993:119-131.
- Muller H. Sex, age and hyperparathyroidism. *Lancet.* 1969;1:449-450.
- Allo MD. Hypercalcemic crisis. In: van Heerden JA, ed. *Common Problems in Endocrine Surgery*. Chicago, Ill: Year Book Medical Publishers Inc; 1989:151-155.
- Grossman RF, Jossart GH. Hypercalcemic crisis. In: Clark OH, Duh Q-Y, eds. *Textbook of Endocrine Surgery*. Philadelphia, Pa: WB Saunders Co; 1997:432-438.
- Malek RS, Panayotis PK. Urologic manifestations of hyperparathyroidism in childhood. *J Urol.* 1976;15:717-719.
- Mannix HJ. Primary hyperparathyroidism in children. *Am J Surg.* 1975;29:528-531.
- Vazquez AM. Nephrocalcinosis and hypertension in juvenile primary hyperparathyroidism. *AJDC.* 1973;125:104-106.
- Daum F, Rosen JF, Boley S. Parathyroid adenoma, parathyroid crisis and acute pancreatitis in an adolescent. *J Pediatr.* 1973;83:275-277.
- Karitzky D. Akute Pankreatitis Als Erstmanifestation Einer Hypercalcämie Bei Primärem Hyperparathyroidismus Im Kindersalter. *Monatsschr Kinderheilkd.* 1989;137:225-227.
- Palmer M, Bergstrom R, Akerstrom G, et al. Survival and renal function in untreated hypercalcaemia: population-based cohort study with 14 years of follow-up. *Lancet.* 1987;1:59.
- Hillman DA, Seriver CR, Pedvis S, et al. Neonatal familial primary hyperparathyroidism. *N Engl J Med.* 1960;270:483-490.
- Thompson NW, Carpenter LC, Kessler DL, et al. Hereditary neonatal hyperparathyroidism. *Arch Surg.* 1978;113:100-103.
- Spiegel AM, Harrison HE, Stephen JM, et al. Neonatal primary hyperparathyroidism with autosomal dominant inheritance. *J Pediatr.* 1977;90:269-272.
- Goldbloom RB, Gillis DA, Prasad M. Hereditary parathyroid hyperplasia: a surgical emergency of early infancy. *Pediatrics.* 1972;49:514-523.
- Mir R, Gerold T, Khan S, Weitz J. Spontaneous infarction of parathyroid adenoma: case report and literature review. *Head Neck.* 1993;15:566-568.

DISCUSSION

Norman W. Thompson, MD, Ann Arbor, Mich: First I would like to congratulate Dr Harman, Dr van Heerden, and colleagues for an excellent presentation, sharp, concise, beautiful slides, and conclusions that I can agree with. I was the coauthor of one of the papers that you initially mentioned with Drs Maria Allo and Jay Harness. We reviewed our experience in 1982, and it was published in the *World Journal of Surgery*. At that time it was the largest series in the world, but once again, the Mayo Clinic has outdone us. The truth is that we had 53 patients in contrast to the 33 in this group, but the difference was that we included patients up to the age of 30 because many of those patients had symptoms that had gone undetected, as far as hyperparathyroidism was concerned, for as long as 10 years. Actually, 27 of those patients had symptoms before the age of 18. We also included patients with familial disease because it

was frequently diagnosed only in retrospect. In fact, there were 4 previously unrecognized MEN type 1 patients in that group who have, in the ensuing 16-year period, all had distal pancreatectomies for neuroendocrine disease. None of those were known to have MEN type 1 at the time of exploration. I know from the article that during this same period, the Mayo Clinic had 16 patients with parathyroid hyperplasia due to MEN type 1 or MEN type 2 who were not included in this paper. I would like to point out that some of these patients present just like any other patient with sporadic hyperparathyroidism. I would ask Dr van Heerden, who is going to close, what he would do today when he encounters a patient with no family history and 4-gland hyperplasia such as that seen in 1 of your patients. What kind of follow-up studies would be necessary?

As the authors pointed out, what is striking about the young patients is that they basically have the same disease as the adults, but it is apparently more advanced. Fifty percent of their patients had kidney stones and 50% of our patients had kidney stones when they first presented. Many of them had other symptoms that represented advanced disease, such as brown tumors or von Recklinghausen's bone disease. Your series had a considerably higher incidence of bone disease than ours.

These diagnosed cases may represent only the tip of the iceberg. I would ask you at the Mayo Clinic, do the pediatricians screen their patients as adults are screened with serum calcium levels? Until we reviewed our experience, our pediatricians did not, but now do so and in the ensuing 16 years we've had an increasing incidence of children in whom the disease is detected at an earlier stage.

Another striking point is that in this series of 33 patients, 3, or 9%, actually had a deep mediastinal adenoma. That is much higher than in adults. In the article, the question was raised whether all children should have a thallium-technetium sestamibi scan or other localization study before their procedure. I think this consideration was based on that higher incidence of deep mediastinal disease. In our series, we had 2 out of 53 who had deep mediastinal tumors. I personally don't think that possibility alone is a reasonable justification. I would ask the authors whether they would address that issue and whether they really feel that localization studies are indicated in children. Identification of 1 tumor does not rule out a second tumor or multiple gland disease merely on the basis of a localization study.

Finally, there is a technical point that I think is worth emphasizing in which children differ from adults. I will show 1 slide to illustrate the point. When you explore a young patient who has a serum calcium level of 13 or 14 mg/dL, as some of your patients did, I think the objective should be to cure the disease with 1 operative procedure. In children, even with deep mediastinal adenomas, you can usually do that. If you find 3 glands that are normal, the fourth gland is likely to be in the deep mediastinum. The difference in children and young adults as in this patient is that the mediastinal tumor can be extracted from a cervical incision, as shown in this picture, showing an adenoma within the thymus 13 cm below the level of the sternal notch. In children with thymuses that are not atrophic, one can usually extract the deep mediastinal tumor within the thymus with the exclusion of those in the aortopulmonary window. The other thymic point is that some of these children have thymic tissue around all 4 parathyroid glands. We recently saw a patient who had 3 normal parathyroid glands removed because the surgeon, with all due respect to our President, who was a pediatric surgeon at another institution, mistakenly thought they were enlarged glands. The fourth gland was in the chest and was an adenoma that had been missed on a preoperative thallium-technetium sestamibi scan because the scan had not been done low enough to show a deep mediastinal tumor.

Orlo H. Clark, MD, San Francisco, Calif: I have 2 questions. Is there a different cause than that found in older individuals? Have

you ruled out benign familial hypocalciuric hypercalcemia, and did all of these children have urinary calcium levels determined? Also, did any of them have radiation exposure that, as you know, can increase the frequency of parathyroid disease? What were the final pathologic findings in these patients? Were the distribution of parathyroid pathologic findings the same as in your adult population, such as about 80%, with solitary adenomas?

Dr van Heerden: To answer Dr Clark's questions first: (1) All of these children were screened for benign familial hypocalciuric hypercalcemia and none of these children had benign familial hypocalciuric hypercalcemia. We believe very strongly in urine calcium level screening in these patients to rule out that rare but very troublesome misdiagnosis. (2) None of these children had had previous radiotherapy, which is interesting. (3) The pathological distribution was exactly the same. In adults, we know that 90% have adenomas, 9% hyperplasia, and 1% cancer. We had no cancers in this study, 1 patient was subsequently found to have hyperplasia, but of these 33 patients, 31 had solitary adenomas and 1 had dual adenomas.

Norman Thompson raised 4 issues. First, thymectomy. I think this comes from a lot of experience, Norman. Thymectomy in children is much easier than the adult, isn't it? And one mustn't necessarily feel that because the child has a low anterior mediastinal tumor that a median sternotomy is required. It can be removed transcervically.

Secondly, as Dr Farley said, I think this disease is probably underdiagnosed in the pediatric population. Routine calcium levels are not obtained as a screening modality worldwide. We are probably seeing the tip of the iceberg only, and we need to think of this diagnosis more often in the pediatric age group.

Dr Thompson asked what would we do if we found a child with multiple gland disease. I think whenever you find multiple gland disease, you need to think of familial non-MEN disease or MEN type 1, which sets a definite protocol into operation. Today we have the genetic screening for MEN type 1 and that should certainly be done, not only in the child but in the family members. Secondly, long-term follow-up is vitally important.

Thirdly, Norman raised the issue of thallium-technetium sestamibi scanning. We continue not to advise routine preoperative localizing modalities, be it ultrasound, CT, or thallium-technetium sestamibi in the nonoperated adult neck. We have suggested in this paper, though, that in these patients perhaps we should, and I think when we can make a point for routine localization in the pediatric age group only. I don't feel we need to start with a thallium-technetium sestamibi scan, which is expensive, but perhaps we should start with a cervical ultrasound and if that is unequivocally positive, I don't think you need any other localizing modalities. The very fact that 12% of these children had mediastinal tumors behooves us to think about localizing modalities.

In summary, what our group has shown is that this diagnosis is delayed and therefore the pathologic findings are more advanced and there was a high failure rate. If you take our failure rate (2 patients), plus the 5 patients who came to us as failures, that adds up to a failure rate of almost 20%, which is in contrast to 1% in the adult population. That is unacceptable. Because of that we feel localization is justifiable.

Thirdly and somewhat anecdotally, in our large experience with patients with primary hyperparathyroidism, I have only seen 2 patients with pancreatitis whose pancreatitis could be directly attributable to primary hyperparathyroidism. I think there is something different about these kids. Two patients in my experience were both pediatric patients, and they both had severe primary hyperparathyroidism. I have never seen an adult patient in whom I could unequivocally attribute the pancreatitis to primary hyperparathyroidism.