ORIGINAL ARTICLE

Laparoscopic Posterior Adrenalectomy

Technical Considerations

Allan E. Siperstein, MD; Eren Berber, MD; Kristen L. Engle, MD; Quan-Yang Duh, MD; Orlo H. Clark, MD

Hypothesis: Although laparoscopic posterior adrenalectomy (LPA) offers a more direct access to the adrenal gland, it is not as popular as laparoscopic transabdominal adrenalectomy, and the worldwide experience has been limited. We hypothesized that LPA is a safe and efficacious procedure that could best serve certain patients with adrenal tumors.

Design: Case series of patients undergoing laparoscopic adrenalectomy in a single institution.

Setting: University teaching hospital.

Patients: Medical records of 31 patients with 33 tumors who underwent LPA were reviewed. Indications for operation included hormone secretion in 23 patients (74%), suspected or known malignant neoplasms in 7 patients (23%), and local symptoms in 1 patient (3%).

Intervention: The LPAs were performed with the patients in prone position. Preoperative ultrasonography localized the adrenal tumor and kidney to guide balloon trocar placement for the creation of a working retroperitoneal space. The LPAs were performed with three 10-mm trocars using laparoscopic ultrasound to localize the tumor and the harmonic scalpel to perform the dissection.

Main Outcome Measures: Demographic data, type and size of tumor, operative time, blood loss, intraoperative and postoperative complications, and hospital stay were analyzed.

Results: All operations were successfully completed without conversion. Excluding the bilateral cases, the mean±SD operative time was 176±104 minutes. Estimated blood loss averaged 32 mL (range, 10-200 mL). There were no intraoperative complications. The mean±SD tumor size was 3.2±1.8 cm (range, 0.8-7.0 cm). Pathological evaluation revealed benign tumors in 25 patients (81%) and malignant tumors in 6 patients. The average hospital stay was 1.4 days (range, 1-3 days). There were no deaths.

Conclusions: Although technically more demanding, LPA should be considered in patients with tumors less than 6 cm, bilateral tumors, or extensive previous abdominal surgery.

Arch Surg. 2000;135:967-971

From the Department of Surgery, University of California, San Francisco/Mount Zion Medical Center. Drs Siperstein and Berber are now with the Department of General Surgery, Cleveland Clinic Foundation, Cleveland, Ohio.

THE FIRST laparoscopic adrenalectomy was performed transabdominally by Gagner et al[1] in 1992. One year later, Mercan et al[2] developed a technique for laparoscopic posterior adrenalectomy (LPA), which they described in 1995.

With decreased operative blood loss, reduced narcotic requirements, and shorter hospital stay and convalescence compared with open procedures, laparoscopic adrenalectomy is becoming the procedure of choice for nonmalignant adrenal tumors.[3-7] Although most surgeons prefer the transabdominal technique, LPA offers a more direct access to the adrenal gland, minimizing the need for intra-abdominal dissection. However, technical considerations, safety, and efficacy of this technique have not been fully defined because of the small number of patients in the reported series.[2,8-10]

We report the largest experience with LPA in the current literature to address these issues.

RESULTS

All patients (16 women and 15 men) underwent successful LPAs. Twenty patients (65%) were American Association of Anesthesiologists status 2, 10 patients (32%) were status 3, and 1 patient was status 1. Mean patient age was 49 years (range, 27-81 years). Tumors were located on the left side in 17 patients (55%) and on the right side in 12. Two patients (6%) had bilateral tumors. Indications for operation included

©2000 American Medical Association. All rights reserved.
Downloaded From: http://archsurg.jamanetwork.com/ on 04/01/2015

PATIENTS AND METHODS

Between April 1994 and January 1998, 123 patients with adrenal tumors were managed laparoscopically at the University of California, San Francisco. Hospital records of 31 consecutive patients with 33 tumors undergoing LPA by one surgeon (A.E.S.) were reviewed. Demographic data, American Association of Anesthesiologists status, type and size of tumor, operative anesthesia and operating room time, blood loss, intraoperative complications, postoperative complications, and hospital stay were analyzed. Statistical analysis was performed using the *t* test, 2-tailed analysis of variance, and Pearson correlation coefficient as appropriate with Statview 4.51 software (SAS, Cary, NC). Statistical significance was reached at $P<.05$. Data are expressed as mean ± SD.

All patients underwent complete endocrinologic workup preoperatively. Radiologic studies consisted of abdominal computed tomography (n=27), magnetic resonance imaging (n=3), or both (n=1). Two patients with suspected pheochromocytoma had meta-iodobenzylguanidine localization scans, and 1 patient with Cushing syndrome and normal-sized glands apparent on magnetic resonance imaging had an iodocholesterol scan. Twelve patients (39%) had previous intra-abdominal operations (5 patients had a single operation; 7 patients had 2 operations).

The technical aspects of the procedure have been modified somewhat from the original description by Mercan et al.[2] The patient is taken to the operating room, and general endotracheal anesthesia is administered on the gurney. Pneumatic sequential compression stockings are applied. The patient is then transferred to the operating table in the prone position, with the chest and abdomen supported laterally by a Wilson frame or parallel bolsters. This allows the abdominal contents to fall anteriorly so that during the procedure a minimum of carbon dioxide insufflation is required, since the posterior rib cage forms a rigid dome under which to work. The table is flexed in a jackknife position with the back level. This serves to open up the space between the posterior costal margin and the pelvis.

Transcutaneous ultrasonography is then performed with a standard 3.5-MHz transabdominal transducer. The outline of the underlying kidney and adrenal mass, as determined by the ultrasound examination, is then drawn onto the skin of the back to direct placement of the trocars into Gerota's space (**Figure 1**). The outline of the 12th rib is drawn by palpation. Such a mapping of the kidney is important, since the location of the kidney relative to the 12th rib is variable, especially in tall individuals (**Figure 2**). It is also important to do the ultrasound examination with the patient properly positioned for surgery, since these structures shift in position with changes in posture.

The back is then sterilely prepared and draped. Local anesthesia is used at the trocar sites. A 1.5-cm incision is made 2 cm inferior and parallel to the 12th rib, positioned laterally at the level of the lower pole of the kidney. A 12-mm trocar (Optivue; Ethicon Endo Surgery, Cincinnati, Ohio) with inserted 0° laparoscope is then used to enter Gerota's space under direct vision by dilating the fascial and muscle layers of the posterior abdominal wall until Gerota's space is entered, as confirmed by perinephric fat seen superiorly and the renal capsule inferiorly. A gentle side-to-side motion is made to further develop this space, and the trocar is advanced to the level of the superior pole of the kidney. This trocar is then replaced with a 10-cm-diameter spherical dissecting balloon (Origin Medical Systems; USSC, Norwalk, Conn), and while viewing within the balloon using a 0° laparoscope, the balloon is manually inflated using a hand pump to create a potential space within Gerota's fascia (**Figure 3**). Using anatomic orientation, this space is bounded anteriorly by the kidney, superiorly by the diaphragm, and posteriorly by the rib cage.

The 12-mm trocar is then reinserted into this space, and 10 to 15 mm of carbon dioxide insufflation is applied. A 45° laparoscope is used to perform the procedure. If the creation of the working space is done properly, then the adrenal gland is directly visible at this point. Two additional 12-mm trocars are placed under direct vision, one on either side of the initial port. More recent cases have been performed with one 12-mm trocar and two 5-mm trocars. Laparoscopic ultrasonography is then performed to confirm the location and extent of the adrenal mass. Most adrenal neoplasms appear as a hypoechoic mass, and the normal adrenal tissue may be hard to distinguish from the surrounding fat (**Figure 4**). The relationship of the adrenal gland to surrounding vessels and other structures is useful to guide the dissection. The harmonic scalpel (laparoscopic coagulating shears, 10 mm or 5 mm) is used to perform essentially the entire dissection, with an atraumatic grasper used for countertraction. There is minimal instrument switching during the procedure. The dissection typically begins at the superior margin of the adrenal gland, separating it from the diaphragm. With division of the superior adrenal artery, the gland may then be displaced inferiorly to facilitate mobilization. The lateral side is dissected next, followed by the inferior border with the kidney. The medial border is dissected last, with the adrenal vein or veins controlled with clips (**Figure 5**). The gland is then placed in a specimen retrieval bag and withdrawn through the abdominal wall with morcellation if needed. Fascial and skin closure is done in the usual manner.

hormone secretion in 23 patients (74%), suspected or known malignant neoplasms in 7 patients (23%), and local symptoms in 1 patient (3%) (**Figure 6**).

Sixteen patients (52%) had hyperaldosteronism. Of the 5 patients with Cushing syndrome, a cortisol secreting adenoma was the cause in 3 (60%), whereas bilateral macronodular hyperplasia and bilateral micronodular hyperplasia were present in 1 patient each. One patient had pheochromocytoma, and another patient with von Recklinghausen disease had mixed pheochromocytoma and neuroblastoma.

Six patients (19%) had malignant neoplasms. Four of these patients had metastatic adrenal lesions (2 patients with renal cell carcinoma and 2 patients with lung cancer). One patient with acquired immunodeficiency syndrome had adrenal leiomyosarcoma, whereas another patient had adrenal cortical carcinoma. Pathological examination revealed nonfunctional adrenocortical adenoma in one patient and cortical nodular hyperplasia in another (**Table**).

The average tumor size was 3.2 ± 1.8 cm (range, 0.8-7.0 cm). The average tumor size was 3.9 ± 1.6 cm for the malignant lesions vs 2.8 ± 1.7 cm for benign lesions ($P<.05$).

Excluding the bilateral cases, the mean operative time was 176 ± 104 minutes (range, 71-531 minutes), whereas

©2000 American Medical Association. All rights reserved.
Downloaded From: http://archsurg.jamanetwork.com/ on 04/01/2015

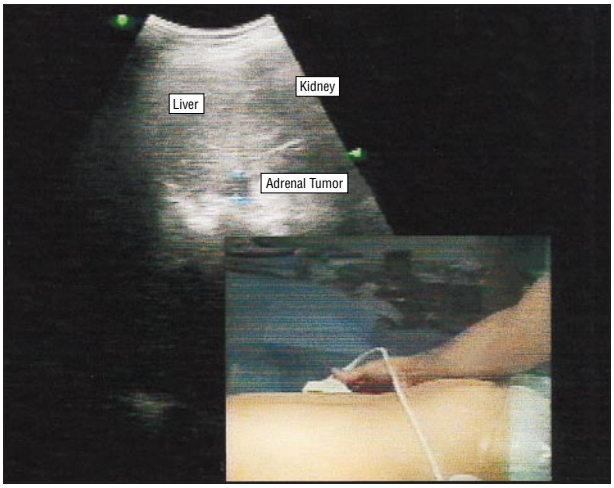

Figure 1. *Transcutaneous ultrasonography is used to draw the outline of the underlying kidney and adrenal mass to guide the placement of trocars.*

Figure 3. *View through the balloon during creation of a potential space within the Gerota's fascia.*

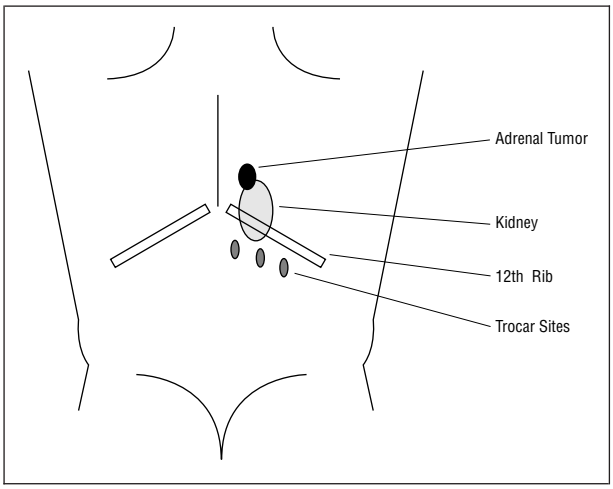

Figure 2. *Three trocars are inserted below the costal margin guided by the localization of the kidney and the adrenal gland with transcutaneous ultrasonography.*

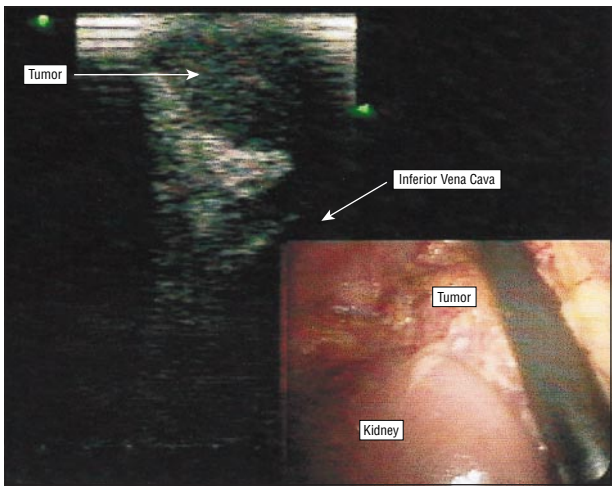

Figure 4. *Laparoscopic ultrasonography shows a hypoechoic adrenal mass and defines its relationship to the inferior vena cava in a 52-year-old woman with right-sided aldosteronoma.*

the mean anesthesia time was 248±103 minutes (range, 130-635 minutes). Operating room time averaged 223±104 minutes (range, 123-609 minutes). Bilateral procedures took an average of 479 minutes. There was no difference between right-sided and left-sided lesions regarding operative time (161±74 minutes vs 152±63 minutes, respectively, $P>.05$). There was no correlation between tumor size and operative time ($r=0.129$, $P>.05$). An analysis of 3 different periods (before 1996, during 1996, and after 1996) that excluded bilateral cases failed to reveal a difference among groups regarding operative time (n=12, 179.0±66.5 minutes; n=7, 129.3±39.8 minutes; n=10, 146.5±77.9 minutes; respectively; $P>.05$, **Figure 7**).

The estimated blood loss averaged 32 mL (range, 10-200 mL). There were no intraoperative complications.

The average hospital stay was 1.4 days (range, 1-3 days). There were 3 postoperative complications (10%): 1 patient operated on for pheochromocytoma with preoperative anemia received 2 units of red blood cells in the postoperative period. Two patients with Cushing syndrome had transient left-sided nerve root pain for 3 months, which was thought to be related to the trocar sites. There was no mortality.

COMMENT

The adrenal gland is particularly amenable to laparoscopic approach because of its small size, the benign nature of most adrenal tumors, and the difficulty in reaching the organ via open means.[4] Both the transabdominal and the retroperitoneal laparoscopic approaches represent a significant benefit in terms of patient recovery as opposed to open surgery. We have previously reported the preliminary results of the LPA technique with comparison to the laparoscopic transabdominal approach.[3] This report confirms the safety and feasibility of LPA in a wide range of adrenal tumors.

The posterior approach simplifies the laparoscopic procedure because it minimizes the amount of dissection: the first structure identified in this procedure is, in fact, the adrenal gland. Furthermore, it offers the advantage of the dissection without the interference of the intra-abdominal organs. It is not necessary to mobilize the liver

©2000 American Medical Association. All rights reserved.
Downloaded From: http://archsurg.jamanetwork.com/ on 04/01/2015

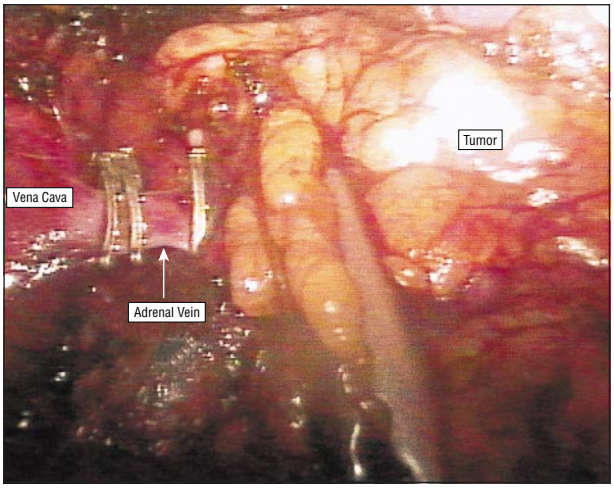

Figure 5. *The adrenal vein is clipped in a 45-year-old man with right-sided aldosteronoma.*

Summary of Pathological Findings

Pathological Finding	No. of Patients
Aldosteronoma	16
Cushing syndrome	
Adenoma	3
Bilateral macronodular hyperplasia	1
Bilateral micronodular hyperplasia	1
Malignant neoplasm	
Lung cancer metastasis	2
Renal cancer metastasis	2
Leiomyosarcoma	1
Cortical carcinoma	1
Pheochromocytoma	1
Mixed pheochromocytoma and neuroblastoma	1
Nonfunctional adenoma	1
Cortical nodular hyperplasia	1

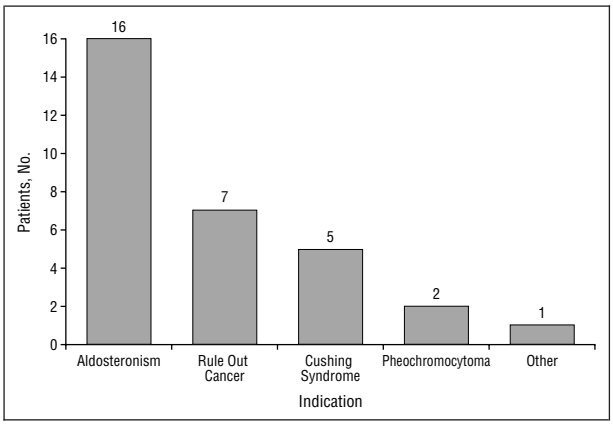

Figure 6. *Indications for posterior laparoscopic adrenalectomy. "Other" indicates cortical nodular hyperplasia and nonfunctional adenoma in 1 patient each.*

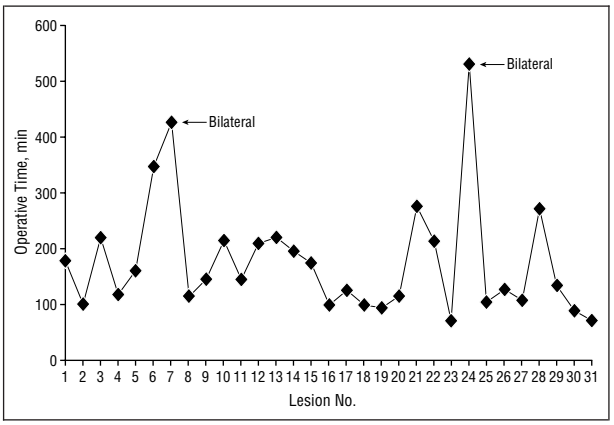

Figure 7. *Change in operative time. Cases are presented in chronologic order. There was no difference in operating time in different periods in the study. Lesions 7 and 24 are bilateral cases, and the respective operative times represent the total time used for bilateral adrenalectomy.*

by sectioning the right triangular ligament for right adrenalectomy, and for the left adrenalectomy, mobilization of the spleen and splenic flexure of the colon are avoided.[5] This approach also facilitates dissection in the individual with previous intra-abdominal surgery by avoiding adhesions. Of the patients in our study, 39% had previous abdominal operations. Furthermore, there is no need to reposition the patient for bilateral tumors except to convert to an open procedure. The patient is already in the prone position, so bilateral adrenalectomy can be performed without repositioning. We performed 2 bilateral adrenalectomies in this series.

The disadvantage of LPA has been reported to be the limited space, which determines the size of the tumor removed.[6] The largest diameter of the tumor removed in this series was 7 cm. Diameters of the tumors removed by LPA in other studies[2,5,11] range from 1.5 to 8 cm. The inability to visualize the intra-abdominal cavity to assess for the possibility of malignancy has been regarded to be a drawback of LPA, but with the currently available advanced imaging techniques and laparoscopic ultrasound, we do not believe that this can be considered a disadvantage. Although we mainly used computed tomography for preoperative imaging, other diagnostic methods were also used when necessary.

Laparoscopic ultrasound has been reported to be valuable to transabdominal laparoscopic adrenalectomy, effecting a change in management in 68% of the patients.[12] We have found laparoscopic ultrasound to be especially valuable in locating the gland and determining its relationship with major vascular structures and surrounding tissues without adding more than a few minutes to the operative time. The harmonic scalpel is a new surgical tool that enables focused dissection and excellent hemostasis by safely coapting vessels up to 3 mm in diameter.[13] We have used it in our last 17 cases and found it to be effective and simpler than clips for dissecting the connective tissue and securing blood vessels. Nevertheless, we continue to place clips on the adrenal vein. The use of the harmonic scalpel saved an average of 36 minutes compared with bipolar scissors.

The average operative time in our study was 177 minutes. Other studies[2,5,11] have reported an average time of 75 to 150 minutes for the same procedure. The longer operative time in our study might be related to the fact that we are a dedicated teaching institution and that resi-

©2000 American Medical Association. All rights reserved.
Downloaded From: http://archsurg.jamanetwork.com/ on 04/01/2015

dents are actively taking part in the operations. There are subtle differences in technical difficulty between right and left laparoscopic adrenalectomy. In open surgery, the procedure is more difficult to perform on the right side because of the short right adrenal vein. However, the magnified right adrenal vein is easier to identify in laparoscopic surgery, and the right adrenal vein has a more fixed anatomic location on the cava, facilitating its localization. Laparoscopically, the procedure is more difficult to perform on the left adrenal gland, especially in an obese patient, because the location of the gland is more variable. The use of laparoscopic ultrasound can overcome this problem. Although we did not note a difference between right- and left-sided lesions, Mercan et al[2] reported that the operative time for right-sided lesions was shorter compared with left-sided lesions (115 vs 180 minutes). Bilateral adrenalectomy took an average of 479 minutes in our study, whereas operative time for bilateral LPA in other studies[2,5] ranged from 300 to 305 minutes. An analysis of operative time did not reveal a difference between different periods of the present study. This probably reflects that fact that LPA is a straightforward procedure for experienced laparoscopic surgeons and that a major learning curve with regard to operative time is not manifest with this technique.

There were no intraoperative complications in our study. A pleural and peritoneal tear occurred in 1 patient each; however, this did not affect the progress of the operation. Likewise, Bonjer et al[11] have reported that, although a peritoneal tear occurred in 6 of their 12 patients during LPA, retraction of the peritoneum with either a fan retractor or an endoscopic clamp sufficed to maintain a good view of the operative field.

The estimated blood loss in our study was 32 mL, which compares favorably with the 20 to 180 mL reported in other series.[5,11]

Postoperative complications, including anemia requiring transfusion and transient neuralgia, were observed in 10% of the patients in our study. Self-limiting subcutaneous emphysema has also been reported as a complication of LPA.[2] There was no mortality in our series. Similarly, none of the LPA series in the literature has reported any mortality.[2,5,11] This low morbidity of LPA compares favorably with the 6% to 12% complication rate reported for the laparoscopic transabdominal approach.[4,7,14]

Malignant adrenal tumors have been considered to be a contraindication for laparoscopic resection. Proposed cutoff tumor diameters for laparoscopic adrenalectomy vary from 6 to 10 cm.[15-18] In case of malignancy, a potential for peritoneal and port site seeding has been reported to exist with laparoscopic adrenalectomy.[6] Nevertheless, reduced tumor handling afforded by the use of atraumatic grasping forceps, which decreases the chance of capsule damage, and removal of the specimen intact in an organ retrieval bag have been used to eliminate this risk.[18] We have removed 6 malignant adrenal lesions in this series. Two thirds of these lesions were metastatic, and tumor sizes ranged from 2 to 6.8 cm. Frozen section in these tumors confirmed the absence of tumor cells at surgical margins.

Although the indication for laparoscopic resection of pheochromocytoma was initially considered to be less definite, the ability to diagnose, localize, and alpha block these patients before surgery, as well as control their intraoperative hemodynamics, has reached a level sufficient to permit a safe laparoscopic approach.[17,19] In 2 patients, we resected the pheochromocytoma via the posterior approach and did not have any complications. Similarly, Bonjer et al[11] have treated 3 patients with pheochromocytoma with LPA but had to convert to the open procedure in 1 patient with a pheochromocytoma 3 cm in diameter, with dense vascular adhesions to surrounding tissues.

None of the operations in our study was converted to an open procedure. Reported conversion rates in the literature vary from 0% to 10%.[2,5,11] The average hospital stay was 1.4 days in our study, which compares favorably with the 2 to 4 days reported in other studies.[2,5,11]

A number of studies have compared the retroperitoneal approach with the transabdominal laparoscopic approach. Some have found similar outcomes with both techniques,[3,6] whereas others have reported a shorter operative time, decreased blood loss, decreased analgesia, and shorter hospital stay with LPA compared with transabdominal laparoscopic adrenalectomy.[11]

In conclusion, LPA is a safe and efficacious technique for removing a wide range of adrenal tumors. Although technically more demanding, LPA should be considered for patients with tumors less than 6 cm, bilateral tumors, or extensive previous abdominal surgery.

Reprints: Allan E. Siperstein, MD, Department of General Surgery, Cleveland Clinic Foundation, 9500 Euclid Ave, Cleveland, OH 44195 (e-mail: sipersa@ccf.org).

REFERENCES

1. Gagner M, Lacroix A, Bolte E. Laparoscopic adrenalectomy in Cushing syndrome and pheochromocytoma. *N Engl J Med.* 1992;327:1003-1006.
2. Mercan S, Seven R, Ozarmagan S, Tezelman S. Endoscopic retroperitoneal adrenalectomy. *Surgery.* 1995;118:1071-1076.
3. Duh Q, Siperstein A, Clark O, et al. Laparoscopic adrenalectomy: comparison of the lateral and posterior approaches. *Arch Surg.* 1996;131:870-876.
4. Gagner M, Pomp A, Heniford BT, Pharand D, Lacroix A. Laparoscopic adrenalectomy: lessons learned from 100 consecutive procedures. *Ann Surg.* 1997; 226:238-247.
5. Fernandez-Cruz L, Saenz A, Benarroch G, Astudillo E, Taura P, Sabater L. Laparoscopic unilateral and bilateral adrenalectomy for Cushing syndrome: transperitoneal and retroperitoneal approaches. *Ann Surg.* 1996;224:727-736.
6. Staren ED, Prinz RA. Adrenalectomy in the era of laparoscopy. *Surgery.* 1996; 120:706-711.
7. Thompson GB, Grant CS, van Heerden JA, et al. Laparoscopic versus posterior adrenalectomy: a case-control study of 100 patients. *Surgery.* 1997;122:1132-1136.
8. Proye CA, Huart JY, Cuvillier XD, Assez NM, Gambardella B, Carnaille BM. Safety of the posterior approach in adrenal surgery: experience in 105 cases. *Surgery.* 1993;114:1126-1131.
9. Fahey T Jr, Reeve TS, Dellbridge L. Adrenalectomy: expanded indications for the extraperitoneal approach. *Aust N Z J Surg.* 1994;64:494-497.
10. Nash PA, Leibovitch I, Donohue JP. Adrenalectomy via the dorsal approach: a benchmark for laparoscopic adrenalectomy. *J Urol.* 1995;154:1652-1654.
11. Bonjer HJ, Lange JF, Kazemier G, Herder WW, Steyerberg EW, Bruining HA. Comparison of three techniques for adrenalectomy. *Br J Surg.* 1997;84:679-682.
12. Heniford BT, Iannitti DA, Hale J, Gagner M. The role of intraoperative ultrasonography during laparoscopic adrenalectomy. *Surgery.* 1997;122:1068-1074.
13. Rothenberg SS. Laparoscopic splenectomy using the harmonic scalpel. *J Laparoendosc Surg.* 1996;6(suppl 1):S61-S63.
14. Rutherford JC, Stowasser M, Tunny TJ, Klemm SA, Gordon RD. Laparoscopic adrenalectomy. *World J Surg.* 1996;20:758-761.
15. Fernandez-Cruz L. Laparoscopic adrenal surgery. *Br J Surg.* 1996;83:721-723.
16. Gagner M. Laparoscopic adrenalectomy. *Surg Clin North Am.* 1996;76:523-537.
17. Jacobs JK, Goldstein RE, Geer RJ. Laparoscopic adrenalectomy: a new standard of care. *Ann Surg.* 1997;225:495-502.
18. Deans GT, Kappadia R, Wedgewood K, Royston CMS, Brough WA. Laparoscopic adrenalectomy. *Br J Surg.* 1995;82:994-995.
19. Orchard T, Grant C, van Heerden J, et al. Pheochromocytoma: continuing evolution of surgical therapy. *Surgery.* 1993;114:1153-1159.

©2000 American Medical Association. All rights reserved.
Downloaded From: http://archsurg.jamanetwork.com/ on 04/01/2015