

# Repair of Pectus Excavatum Deformities in Children

## A New Perspective of Treatment Using Minimal Access Surgical Technique

Peter C. Wu, MD; Eric M. Knauer, MD; George E. McGowan, MD; Donald W. Hight, MD

**Hypothesis:** Minimally invasive correction of pectus excavatum (PE) deformities of the anterior chest wall in children is safe and effective.

**Design:** Prospective cohort study.

**Setting:** Tertiary pediatric referral center.

**Patients:** Between February 1996 and July 2000, 36 patients underwent minimally invasive repair (MIR) of PE deformities, and 6 patients had traditional Ravitch repairs (RR).

**Main Outcome Measures:** Morbidity, operating time, estimated blood loss, days to tolerating a regular diet, and length of hospital stay.

**Results:** Thirty-six children underwent MIR for moderate to severe chest wall deformities, with a mean opera-

tive time of 1.6 hours, a mean blood loss of 22 mL, a mean time to tolerating a regular diet of 2.9 days, no intensive care unit admissions, and a mean length of hospital stay of 5.5 days. Six children had RR procedures performed for moderate to severe deformity, with a mean operative time of 5.2 hours, a mean blood loss of 222 mL, a mean time to tolerating a regular diet of 3.3 days, 2 patients admitted to the intensive care unit, and a mean length of hospital stay of 4.5 days. Complications for both procedures consisted mainly of postoperative pneumothorax.

**Conclusions:** The MIR technique for PE is less invasive, less morbid, and better tolerated than traditional open RR of this common pediatric chest wall deformity. Elective surgical reconstruction can be safely performed in children rather than limiting repair to only symptomatic patients with severe deformities.

*Arch Surg.* 2001;136:419-424

From the Department of Surgery, University of Connecticut Health Center, Farmington (Drs Wu and Knauer), and the Department of Pediatric Surgery, Connecticut Children's Medical Center, Hartford (Drs Gowan and Hight).

**P**ECTUS EXCAVATUM (PE), commonly referred to as "funnel chest," accounts for 90% of congenital chest wall deformities, with an incidence of 1 in 300 live births.<sup>1</sup> This chest wall defect has been observed to strongly affect psychological and social development in children.<sup>2</sup> Severe deformities can affect cardiopulmonary function by cardiac displacement or reduction in lung volume resulting in easy fatigability, decreased stamina, and diminished exercise tolerance.<sup>3-6</sup> Surgical corrective repair, as first described by Sauerbruch<sup>7</sup> in 1931, involved complete resection of deformed ribs and sternum (chondrosternal resection). The procedure later evolved into limited cartilage resection and sternal osteotomy as proposed by Ravitch<sup>8</sup> in 1949, with later modifications using various forms of internal bracing.<sup>9,10</sup> A minimally invasive technique with long-term follow-up was recently described by Nuss et al,<sup>11</sup> and it involves the placement of a transthoracic

retrosternal stainless steel bar to correct the chest wall defect and avoid the need for cartilage incision or resection.

We describe our experience with this new minimally invasive technique, combined in selected cases with thoracoscopy, and we compare these results with previous Ravitch-type repairs. The aim of this article is to report our institutional results of minimally invasive surgical correction of PE.

### RESULTS

Patient demographics shown in **Table 1** demonstrate comparable patient groups for both procedures in terms of age, weight, and chest wall defect. The majority of both groups (66%) had severe chest wall deformities (>3-cm defects) without cardiopulmonary symptoms. Among the 36 patients undergoing MIR, 10 underwent thoracoscopic-assisted procedures because they had severe defects greater than 3 cm and significant cardiac displacement.

## PATIENTS AND METHODS

### PATIENTS

Between February 1996 and July 2000, 42 children underwent corrective repair of PE deformities by 2 pediatric surgeons (G.E.M. and D.W.H.). Patients were classified as having moderate to severe deformity based on depth of the chest wall defect and related cardiopulmonary symptoms. Prior to December 1997, 6 patients (4 girls, 2 boys; mean age, 11.4 years) underwent traditional Ravitch repair (RR). Since December 1997, a total of 36 patients (28 boys, 8 girls; mean age, 12.3 years) had minimally invasive repairs (MIRs), including 10 patients who underwent thoracoscopic-assisted procedures. Long-term follow-up was derived from a prospective database. Medical records and operative reports were reviewed to evaluate outcome measures, including operative time, estimated blood loss, intensive care unit admission, time to tolerating a regular diet, length of hospital admission, and postoperative morbidity. Data are presented as means  $\pm$  SD, and statistical significance was determined by the Mann-Whitney *U* test.

### OPERATIVE TECHNIQUE

Informed consent for surgery is obtained from the patient's family with the use of photographs to illustrate the procedure (**Figure 1A, B**). Preoperative chest radiography and pulmonary function tests are performed on patients with PE-related respiratory symptoms. All patients are admitted on the day of surgery, and prophylactic antibiotics are administered. Procedures are performed with general endotracheal anesthesia, and epidural catheters are placed for postoperative pain management. Chest wall measurements are

obtained (**Figure 1C**) to determine adequate sternal bar length (Walter Lorenz Surgical, Jacksonville, Fla). A template bar is placed over the chest at the level of greatest sternal depression to properly position and size the sternal strut (**Figure 2A**). The strut is shaped with customized benders to ensure proper size and fit. Small, bilateral midaxillary incisions are carried down to the chest wall. A specially designed passer is inserted into the right side of the chest through the anterior intercostal space overlapping the planned strut position. At this point, a 5-mm trocar and thoracoscope can be inserted into the left hemithorax to visualize the mediastinum when inserting the transthoracic passer. The passer is then carefully placed through the anterior mediastinum and into the left hemithorax, using thoracoscopic guidance when indicated, and exited through the corresponding left anterior intercostal space. Two umbilical tapes are then tied to the passer and withdrawn through the mediastinum. One of the tapes is tied to the strut, which is then pulled, with the convex side down, into the left hemithorax, through the mediastinum, and out the opposite side (**Figure 2B**). The second tape is used as a back-up. The strut is then rotated 180° into position so that the convexity pushes out the sternum and chest wall, thus correcting the deformity. The strut is then secured to the chest wall using a large absorbable suture. Lateral stabilization bars (Walter Lorenz Surgical) are attached to both strut ends to minimize bar displacement. Residual air is then evacuated from both chest cavities using small chest tubes with positive end expiratory pressure. The tubes are withdrawn as the skin incisions are closed in multiple layers (**Figure 2C**). The patient is extubated and brought to the recovery room, and a portable chest radiograph is taken to rule out significant pneumothorax and confirm bar position.

Overall, the group of patients undergoing MIR (n=36) had significantly shorter operative times compared with those patients having open RR (n=6) (1.6 hours vs 5.2 hours, respectively;  $P < .001$ ). The MIR group also had less intraoperative blood loss than the RR group (22 mL vs 222 mL, respectively;  $P = .001$ ), and no patient required blood transfusion. All 6 patients who underwent RR had postoperative drainage catheters placed using Hemovac closed drains. Three (50%) of these patients required intraoperative chest tube thoracostomy. Only 5 patients (14%) undergoing MIR required intraoperative chest tube thoracostomy, and none had drainage catheters placed. None of the MIR procedures were converted to open repair, and satisfactory cosmetic results were achieved in all cases.

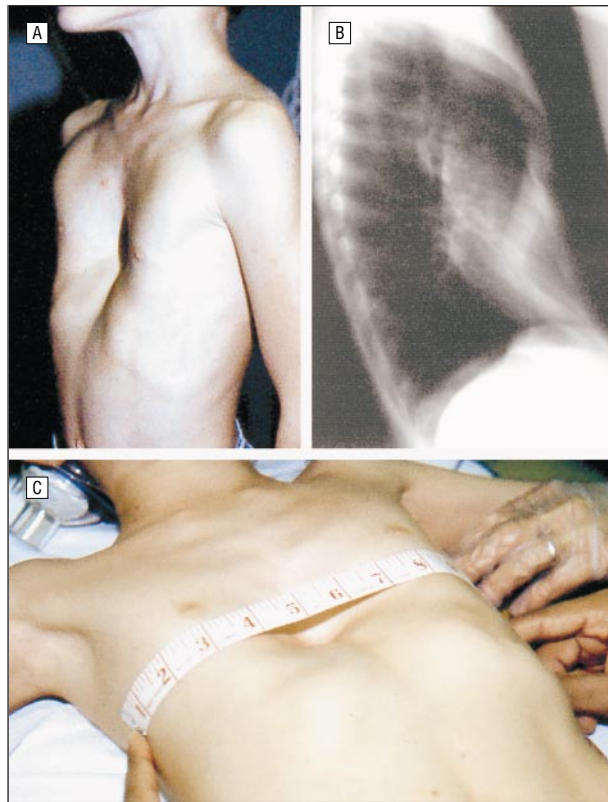
All MIR procedures used the retrosternal stainless steel bar (Walter Lorenz Surgical) ranging from 25.4 to 35.6 cm. In 7 cases (19%), 2 bars were placed to correct larger defects. After the first 6 operations were performed, lateral stabilization bars (footplates) were routinely used to minimize complications of sternal bar displacement.

All MIR patients were admitted to the surgical floor for postoperative recovery, while 2 RR patients (33%) required monitoring in the intensive care unit. None of the patients who underwent either corrective procedure received postoperative blood transfusions. There was no statistical difference between MIR and RR techniques in time

to tolerating a regular diet (2.9 days vs 3.3 days, respectively) and hospital stay (5.5 days vs 4.5 days, respectively) (**Table 2**). All patients were managed by the anesthesiology pain service for postoperative pain control using a standard protocol of epidural catheter, intravenous patient-controlled analgesia, and oral narcotics.

Postoperative complications (**Table 3**) consisted mainly of pneumothorax, which occurred in 6 MIR patients (17%) and in 1 RR patient (17%). One MIR patient required bilateral thoracic Heimlich catheter placement, while the remaining 5 patients had self-resolving apical pneumothoraces requiring no intervention. Other MIR complications included pleural effusion (n=3 patients [8.3%]), pectus bar displacement (n=1 patient, [2.8%]), and epidural catheter-related morbidity (n=1 patient, [2.8%]). The routine application of footplates to the retrosternal Walter Lorenz support bar has minimized complications of bar displacement that others have reported.<sup>11-13</sup> One patient required reoperation for a shifted footplate that necessitated removal. No patients required nutritional support for prolonged intestinal ileus.

Patients are evaluated at 6-month intervals to assess chest wall appearance, support bar migration, physical activity, and patient satisfaction (**Figure 3A**). At 2 years' follow-up, 4 patients had undergone bar removal without complication in the ambulatory surgery setting (**Figure 3B, C**). There have been no recurrences, and both



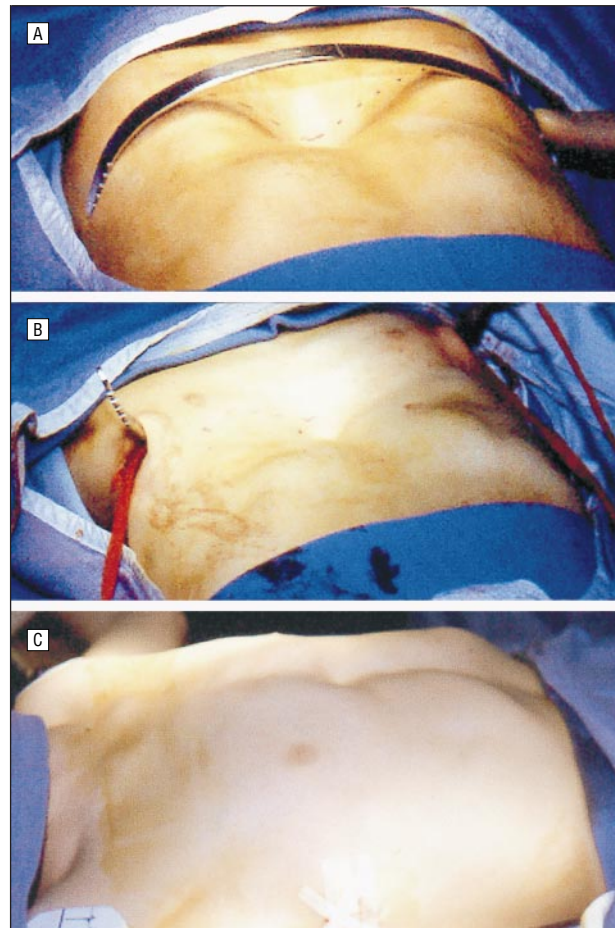
**Figure 1.** Preoperative evaluation of pectus excavatum chest wall deformity. A, Severe pectus excavatum deformity. B, Preoperative chest radiograph. C, Chest wall measurement for strut sizing.

patients and their families have expressed high satisfaction with both immediate postoperative and long-term results.

#### COMMENT

Pectus excavatum represents the most common congenital chest wall deformity seen in children.<sup>1,14,15</sup> Patients are often asymptomatic but can suffer significant psychological disorders ranging from social anxiety to severe depressive reactions related to the cosmetic fault.<sup>2</sup> Cardiopulmonary symptoms can occur with more severe sternal defects.<sup>4</sup> The Ravitch procedure has evolved into the “gold standard” of surgical management of PE. It involves incision and removal of deformed cartilages, sternal mobilization, transverse osteotomy, and various forms of internal bracing with excellent outcomes and low recurrence rates.<sup>15-19</sup> However, repair is often avoided in younger children since restrictive lung disease may develop owing to chest wall hypertrophy, and impaired rib growth following thoracic repair.<sup>20</sup> An alternative approach originally proposed by Nuss et al<sup>11</sup> uses the minimally invasive technique described in this article.

The decision to proceed with corrective surgery for PE prior to the introduction of MIR had been difficult because of the lack of reliable studies to document specific physiological limitations caused by the deformity. Similarly, conflicting studies failed to clearly establish whether significant improvement occurred following radical surgery.<sup>3-6</sup> Few centers compiled a large surgical experience



**Figure 2.** Minimally invasive repair of pectus excavatum. A, Shaped stainless steel strut prior to placement. B, Strut passed across mediastinum in retrosternal position. C, Postoperative chest wall appearance following strut placement.

**Table 1. Characteristics of 42 Patients Undergoing Corrective Repair of Pectus Excavatum**

| Characteristic             | Minimally Invasive Repair | Ravitch Repair |
|----------------------------|---------------------------|----------------|
| No. of patients            | 36                        | 6              |
| Sex, M/F                   | 28/8                      | 2/4            |
| Mean ± SD age, y           | 12.3 ± 4.1                | 11.4 ± 4.3     |
| Mean ± SD weight, kg       | 43.2 ± 15                 | 40.4 ± 23      |
| Pectus excavatum depth, cm | 3.1 ± 0.7                 | 3.1 ± 0.2      |
| Asymptomatic/symptomatic   | 24/12                     | 4/2            |

**Table 2. Outcome Measures of Corrective Surgery for Pectus Excavatum\***

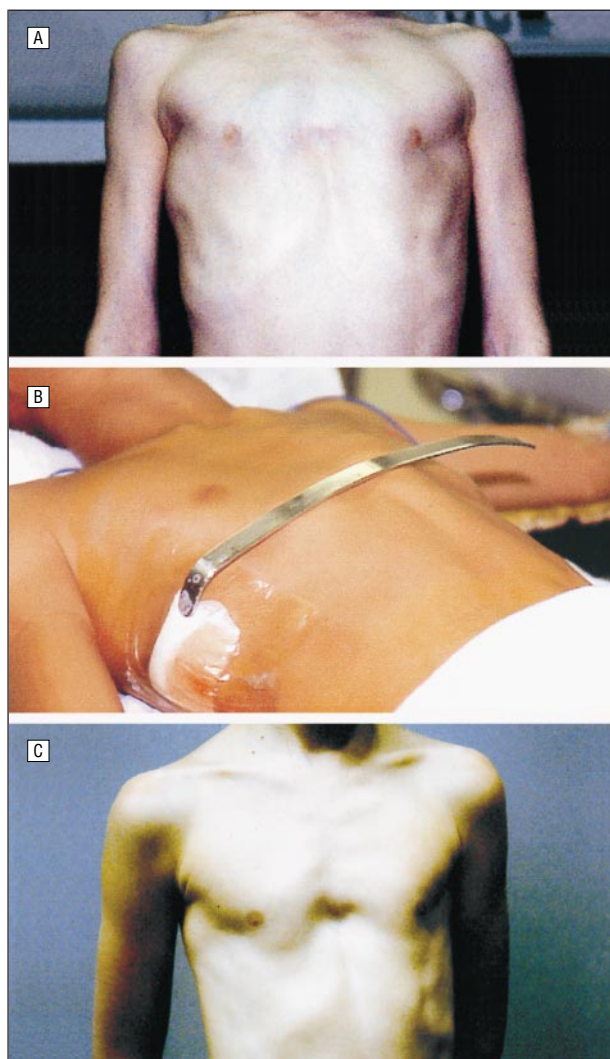
| Outcome Measure                     | Minimally Invasive Repair | Ravitch Repair |
|-------------------------------------|---------------------------|----------------|
| Operative time, h                   | 1.6 ± 0.6                 | 5.2 ± 1.8      |
| Intraoperative blood loss, mL       | 22.1 ± 44.7               | 222 ± 142      |
| No. (%) of patients admitted to ICU | 0 (0)                     | 2 (33)         |
| Days to tolerating regular diet     | 2.9 ± 1.9                 | 3.3 ± 0.5      |
| Length of hospital stay, d          | 5.5 ± 2.2                 | 4.5 ± 1.1      |

\*All data are mean ± SDs, unless otherwise indicated. ICU indicates intensive care unit.

**Table 3. Postoperative Complications Associated With Pectus Excavatum Repair\***

| Complications                    | Minimally Invasive Repair |                | Ravitch Repair |
|----------------------------------|---------------------------|----------------|----------------|
|                                  | Invasive Repair           | Ravitch Repair |                |
| Pneumothorax/required chest tube | 6 (17)/2 (5.6)            | 1 (17)/0 (0)   |                |
| Pleural effusion                 | 3 (8.3)                   | 0 (0)          |                |
| Pectus bar displacement          | 1 (2.8)                   | 0 (0)          | ...            |
| Epidural catheter-related        | 1 (2.8)                   | 0 (0)          |                |
| Infectious complications         | 0 (0)                     | 0 (0)          |                |

\*All data are numbers (percentages). Ellipsis indicates not applicable.



**Figure 3.** Follow-up after minimally invasive pectus excavatum repair. A, Six-month result. B, Strut removed at 2-year follow-up. C, Postoperative chest wall appearance after strut removal.

with PE resulting in confusion among pediatric caregivers regarding whether to recommend corrective surgery. The introduction of a simple minimally invasive procedure that is well tolerated and has excellent cosmetic results and minimal complications has refocused attention toward surgical repair of this common deformity.

Modifications to the original minimally invasive procedure, including thoracoscopic guidance and stabilization footplates, have lessened many of the complica-

tions reported during early experience with this procedure. Although the incidence of small pneumothorax during MIR is relatively high owing to entry into the pleural space, the majority of cases resolve spontaneously without the need for tube thoracostomy. Pleural air trapping can be minimized by positive end expiratory pressure during closure. Several prior studies reported the complication of sternal bar displacement, which has been minimized in our experience with the routine use of the lateral stabilization bars.<sup>11-13</sup> The frequency of postoperative pleural effusions is low and rarely requires tube thoracostomy drainage. The routine use of prophylactic antibiotics, sterile technique, aggressive pain control, and incentive spirometry has prevented infectious complications related to MIR.

Results of this study demonstrate that MIR is less invasive, less morbid, and better tolerated than Ravitch-type repairs. Immediate postoperative and long-term outcomes are excellent, with few complications. Further prospective studies are needed to assess patient age limitations, associated connective tissue disorders, and long-term complications. This new technique has gained increased popularity because of its simplicity, minimal incisions, short hospital stay, excellent cosmetic results, and high patient satisfaction. Minimally invasive repair offers an acceptable alternative to more radical procedures allowing pediatric health professionals to favorably recommend early surgical correction of this common childhood deformity.

Presented at the 81st Annual Meeting of the New England Surgical Society, Boston, Mass, October 6, 2000.

Corresponding author: Donald W. Hight, MD, Department of Pediatric Surgery, Connecticut Children's Medical Center, 282 Washington St, Hartford, CT 06106 (e-mail: Dhight@ccmckids.org).

## REFERENCES

- Sabiston D Jr, Heinle J. Congenital deformities of the chest wall. In: Sabiston, ed. *Textbook of Surgery*. 15th ed. Philadelphia, Pa: WB Saunders Co; 1997:1888-1893.
- Einsiedel E, Clauser A. Funnel chest: psychological and psychosomatic aspects in children, youngsters, and young adults. *J Cardiovasc Surg (Torino)*. 1999;40:733-736.
- Zhao L, Feinberg M, Gaides M, Issahar B. Why is exercise capacity reduced in subjects with pectus excavatum? *J Pediatr*. 2000;136:163-167.
- Quigley P, Haller J, Jelus K, Loughlin G, Marcus C. Cardiorespiratory function before and after corrective surgery in pectus excavatum. *J Pediatr*. 1996;128(pt 1):638-643.
- Shamberger R. Cardiopulmonary effects of anterior chest wall deformities. *Chest Surg Clin N Am*. 2000;10:245-252.
- Haller JA Jr, Loughlin G. Cardiorespiratory function is significantly improved following corrective surgery for severe pectus excavatum: proposed treatment guidelines. *J Cardiovasc Surg (Torino)*. 2000;41:125-130.
- Sauerbruch F. Operative beseitigung der angeborenen trichterbrust. *Dtsch Z Chir*. 1931;234:760-764.
- Ravitch M. Operative technique of pectus excavatum repair. *Ann Surg*. 1949;129:429-444.
- Haller JA Jr. History of the operative management of pectus deformities. *Chest Surg Clin N Am*. 2000;10:227-235.
- de Agustin-Asensio J, Banuelos C, Vazquez J. Titanium miniplates for the surgical correction of pectus excavatum. *J Am Coll Surg*. 1999;188:455-458.
- Nuss D, Kelly RE Jr, Croitoru DP, Katz M. A 10-year review of a minimally invasive technique for the correction of pectus excavatum. *J Pediatr Surg*. 1998;33:545-552.

12. Engum S, Rescorla F, West K, Rouse T, Scherer LR, Grosfeld J. Is the grass greener? early results of the Nuss procedure. *J Pediatr Surg.* 2000;35:246-251.
13. Hebra A, Swoveland B, Egbert M, et al. Outcome analysis of minimally invasive repair of pectus excavatum: review of 251 cases. *J Pediatr Surg.* 2000;35:252-258.
14. Sawin R. Pediatric chest lesions. *Pediatr Clin North Am.* 1998;45:861-874.
15. Willekes C, Backer C, Mavroudis C. A 26-year review of pectus deformity repairs, including simultaneous intracardiac repair. *Ann Thorac Surg.* 1999;67:511-518.
16. Kowalewski J, Brocki M, Zolynski K. Long-term observation in 68 patients operated on for pectus excavatum: surgical repair of funnel chest. *Ann Thorac Surg.* 1999;67:821-824.
17. Fonkalsrund E, Dunn J, Atkinson J. Repair of pectus excavatum deformities: 30 years of experience with 375 patients. *Ann Surg.* 2000;231:443-448.
18. Robicsek F. Surgical treatment of pectus excavatum. *Chest Surg Clin N Am.* 2000;10:277-296.
19. Robicsek F. Surgical correction of pectus excavatum and carinatum. *J Cardiovasc Surg (Torino).* 1999;40:725-731.
20. Haller JA Jr, Colombani P, Humphries C. Chest wall construction after too extensive and too early operations for pectus excavatum. *Ann Thorac Surg.* 1996;61:1618-1625.

## DISCUSSION

**Daniel Doody, MD, Boston, Mass:** The authors' experience in patients with pectus excavatum defect and the use of the minimally invasive repair has been similar to our own. Although our experience is more recent and the numbers smaller, we have been equally impressed by the shortened operative time, the minimal blood loss, and the strength of the pectus bar, which results in a dramatic correction of the relatively severe musculoskeletal defect. Dr Wu addressed some of the questions I was going to pose, but I will ask them anyway.

The hospital stay for patients following the Nuss repair is slightly longer than the hospital stay of patients with the more standard Ravitch and Welch repairs. I was hoping that Dr Wu might expand a little bit on the older patients in whom we are also seeing more pain and a longer hospital stay because of this.

While subjectively feeling better following the standard pectus repair, many children do not improve pulmonary performance as measured by pulmonary function tests, and in some reports there is worsening of the restrictive defect. I was hoping the authors would comment if they have found differences in the preoperative and postoperative pulmonary function measurements following this minimally invasive repair.

Dr Wu briefly mentioned this, but I would ask him to comment about the age of their patients. Are they recommending the minimally invasive repair primarily in younger children or do they have experience with older adolescents or young adults in their series? Finally, all of our patients are evaluated by CT [computed tomographic] scan rather than just simple chest x-ray, and we have been impressed and often surprised by the severity of the pectus defect and the degree of cardiac displacement as determined by CT imaging, as compared to standard chest x-ray imaging. I was hoping the authors might comment on the role of CT in the evaluation of chest wall defects and if they are using the Haller index or another index to select patients for repair.

**John Seashore, MD, New Haven, Conn:** Most of us would agree that patients with very severe pectus deformities may be symptomatic due to exercise intolerance and probably should be repaired. Perhaps, however, in those with milder defects, it is primarily a cosmetic issue, and there is much more debate about the wisdom of repair. One of the concerns I have with this new technique, which seems simpler and certainly has less scarring, is whether we will see a rapid expansion of the possible indications for doing this and perhaps be operating on patients who in the past did not get operated on and may not indeed have needed surgery. What is your reaction to that statement? And specifically looking at that, how many patients were operated on at your institution during the same pe-

riod, 3 years just prior to converting to the minimally invasive technique using open technique. In other words, from 1994 to 1997, how many patients had this repair?

**Robert Shamberger, MD, Boston:** Dr Wu did an excellent job of presenting his series. We need to take some caution, however, when we embrace new procedures and we must be very cautious to analyze all complications that occur. We must also be very watchful when procedures or their results are extrapolated from one age group or cohort of patients to another. Dr Nuss's series was large, but it must be recognized that it was performed on fairly young patients with a median age of 4 years. After his report, the use of the Nuss procedure has been expanded to an older population, and quite different results have been identified by various centers in that group of patients.

I was interested to know if the authors would specify on which patients they used thoracoscopy. One of the complications that have been reported with the Nuss procedure has been penetration of the heart when the clamp goes behind the sternum. Various centers have adopted methods of avoiding this. I would like you to state how you identify which patients receive thoracoscopy.

In older patients, increased pain, as has already been mentioned, is a major issue. You commented in your conclusion that the procedure was better tolerated than the standard operation, yet your data would conflict with that statement. In fact, the Indiana center in Indianapolis did a review of concurrently performed procedures and found that the patients who had the Nuss procedure actually ended up staying in the hospital longer and requiring, in some cases, intravenous pain medicine as well as epidural catheters. So when this is billed as a minimally invasive procedure, we have to be careful of that analysis.

Have you been using this technique on patients that have an asymmetric deformity? This has been also identified as a problem in the older patients when the asymmetric lesions are corrected with this repair.

You stated that you have had good results as far as "long-term" follow-up. If only 5 of the patients have had the struts removed (and we know that many patients with pectus excavatum can develop recurrence of their pectus 5 to 10 years after repair), you have to be cautious about how you assess recurrence, and your series is far too new to make any conclusive statement.

I would be interested if any of your patients have had either pericardial effusions or thoracic outlet syndrome, which have been reported with the Nuss procedure as well.

**William A. Cook, MD, Andover, Mass:** I remember a paper that was presented at the Wilford Hall Air Force Base perhaps 25 years ago at about the same time that they were beginning to do breast implant surgery. The authors of that paper had decided that the thing to do was to fill in the hole with something like a breast implant, because in their testing (and they used very sophisticated testing on all the cardiac and pulmonary parameters in these flyers) they were absolutely unable to demonstrate that the patients with severest pectus excavatum developed any real physiologic effects. Everybody always whizzes over the part about how we all know that there are great physiologic effects from this deformity. I happen to know one young man with a really bad case who is an Olympic-class swimmer, so I am not so sure that we know that.

Having previously performed the procedure during which the surgeon flips the sternum over, the sternal inversion technique, I remember that that sternal piece was so stiff that I had to cut into it in order to get it to fall down flat, and I do not understand how putting this bar in there can move that fixed bone in the older patient. I can see where it would happen in a child, but I do not understand it in a grown adult.

**Dennis Lund, MD, Madison, Wis:** I, too, share some of these reservations. I think that this is a technique that is going

to need to be reserved for certain selected cases. The Indiana University group in Indianapolis has really published some very thoughtful work on their complications, and they have had a 35% bar disruption rate that they noted with their early cases. These have been corrected with some modifications of the bar, but it is a fairly substantial complication rate.

Since the older patients are the ones who really have the most pain, is there an age at which you will not recommend using this technique?

Nuss recommends 24 months for the bars to be in. Most of us who use other types of chest wall supports for pectus excavatum repairs leave them in for about 6 months. Do you allow children who have these struts in place to play contact sports while the bar is in place?

**Dr Wu:** I will begin first by addressing issues concerning the physiologic effects and exercise intolerance related to pectus excavatum [PE] deformities. These are major areas of study and debate when evaluating surgical repair of PE defects. Despite numerous published studies on the physiologic effects and measurements of physiologic parameters in PE deformity, there has been no significant correlation established between the severity of PE deformity and the level of exercise intolerance. How this applies to evaluating patients with severe defects is difficult to determine. In a recent study appearing in the *Journal of Pediatrics*, 13 patients with severe PE deformities were evaluated for exercise intolerance. This study concluded that diminished exercise intolerance seemed to be greatest in patients exercising in the supine position, and patients were least affected by exercise in the prone position.

This may be an explanation for the apparent minimal impact of PE in an Olympic-class swimmer reported by Dr Cook. Additionally, studies reported in the cardiothoracic literature have consistently reported on improved cardiopulmonary function following surgical repair of PE.

The role of minimally invasive repair [MIR] in older patients is challenging. Our oldest patient undergoing MIR was 17 years of age. We have observed among our patients undergoing MIR, that the older patients have higher postoperative analgesic requirements and resultant longer hospital stays. The data was skewed by several of the older patients requiring extended hospital stays reaching 12 days for pain management issues. In fact, the majority of patients were able to be dis-

charged in 4 to 5 days, similar to patients undergoing traditional Ravitch repair. We currently utilize a standardized postoperative pain management protocol incorporating epidural analgesia, conversion to parenteral PCA [patient-controlled analgesia] combined with oral narcotics and nonsteroidals. Despite the longer hospital stays in our older patients, these patients were among the most satisfied with their postoperative results. This is an important point since the psychosocial impact of PE deformities cannot be overemphasized. Also, many of the older patients had broad defects requiring the placement of multiple bars to correct the deformity. Complications of bar disruption have been drastically reduced with the routine use of lateral stabilization footplates to secure bar positioning. To avoid the risk of bar displacement, we advise our patients to avoid contact sports prior to bar removal.

To address the issue of whether MIR is a better tolerated procedure, I point out that other parameters, including shorter operative times, minimal blood loss, and a short learning curve make this procedure an acceptable alternative to traditional costosternoplasty-type repairs. We have certainly observed in our practice an increase in patient referral from our pediatric community with the introduction of this minimally invasive technique.

We do not routinely use preoperative CT imaging and index scoring since we have found no definitive correlation between the severity of PE defect and physiologic impairment. We perform MIR with thoracoscopic assistance in those patients with severe defects and mediastinal shift to avoid drastic complications such as cardiac laceration.

There has been a major complication reported with the Ravitch repair. There have been no cases of asphyxiating thoracic dystrophy reported by the original Nuss series or by others, that have been previously associated with costosternoplasty repair. It is postulated that the more pliant hyaline cartilage is replaced by stiff fibrocartilage. The MIR technique may avoid this complication by eliminating the need for cartilage incision.

Currently, over 60% of polled pediatric surgeons in this country utilize minimally invasive repair in patients with pectus excavatum deformities. This attests to the overwhelming support for a new and less invasive procedure introduced less than 2 years ago by Dr Nuss for treatment of this challenging pediatric disease.

#### Correction

**Error in Text.** In the Original Article by Fourneau et al titled "An Improved Model of Acute Liver Failure Based on Transient Ischemia of the Liver," published in the October issue of the ARCHIVES (2000;135:1183-1189), errors occurred in the abstract and the text. On page 1183, in the "Results" section of the abstract, the first sentence should have read as follows: "When occluded for 10 hours, all pigs in group 2 (n=5) died between 12 and 17 hours after the induction of ischemia." On page 1184, in the "Results" section, under "Survival," the third sentence should have read as follows: "In group 2, all animals (n=5) subjected to 10 hours of occlusion of the hepatic artery and the common bile duct died within 17 hours after the induction of ischemia." The journal regrets these errors.