ORIGINAL ARTICLE

The Laparoscopic Approach to Abdominal Hydatid Cysts

A Prospective Nonselective Study Using the Isolated Hypobaric Technique

Amitai Bickel, MD; Norman Loberant, MD; Jonathan Singer-Jordan, MD; Moshe Goldfeld, MD; George Daud, MD; Arie Eitan, MD

Hypothesis: The laparoscopic isolated hypobaric technique that we developed and use is safe and feasible for almost all kinds of hepatic and extrahepatic abdominal hydatid cysts.

Design: A case series.

Patients: Between August 1992 and December 1999, 31 patients with no selection criteria underwent 32 consecutive laparoscopic operations for 52 symptomatic hydatid cysts located in the liver (49), spleen (1), and pelvis (2). Eleven patients underwent surgery for between 2 to 5 cysts.

Interventions: The main surgical maneuvers (puncture, parasite neutralization, and complete evacuation) were performed through an assembled transparent cannula, in which a vacuum was created, while its tip adhered firmly to the cyst wall. Following evacuation of the cyst contents, we attempted to perform partial pericystectomy, omentoplasty, and closed-suction drainage.

Main Outcome Measures: Surgical complications and postoperative disease recurrence.

Results: Mean cyst diameter was 8.4 cm (range, 3.5-25 cm). Seven cysts were subdiaphragmatic, and 6 were on the posterior (hidden) aspect of the liver. Mean postoperative follow-up was 49 months. Forty-one cysts contained live parasites, and 11 were secondarily infected. Twenty-four cysts were complex. Perioperative complications occurred in 5 patients, including 1 patient who died 1 month after surgery owing to *Candida* sepsis. Mean hospital stay was 6 days. No evidence of recurrence was recorded during follow-up.

Conclusions: The isolated hypobaric laparoscopic technique described provides a safe and efficacious approach to almost all types of abdominal hydatid cysts and takes advantage of the recognized benefits of the laparoscopic approach.

Arch Surg. 2001;136:789-795

From the Departments of Surgery (Drs Bickel, Daud, and Eitan) and Radiology (Drs Loberant, Singer-Jordan, and Goldfeld), Western Galilee Hospital, Nahariya, Israel, affiliated with the Rappaport School of Medicine, the Technion, Israel Institute of Technology, Haifa.

HYDATIDOSIS is a zoonotic infection with a worldwide distribution and is endemic in many cattle-raising regions of the Mediterranean, Middle and Far East, South America, Australia, and in certain areas in North America.[1-5] Most cases are caused by the cestode tapeworm *Echinococcus granulosus* that is found in the small bowel of carnivores.[1-4] In the human, which serves as an intermediate host (by ingestion of the ova), the parasite exists only in its larval form, consisting of a slow-growing cyst containing countless larvae (scolices) and germinal layers. Cysts are most frequently located in the liver, followed by the lung, and less often in other organs following hematogenous spread.

Complications include cyst rupture with intraperitoneal dissemination of disease, anaphylactic reaction, pressure on contiguous organs, secondary infection, and penetration of daughter cysts into the biliary tree causing obstructive jaundice.[1,3] The standard approach in treatment of liver cysts, especially large cysts, is open surgery; the principles and various techniques have been extensively reviewed.[1,6-14] In recent years, laparoscopic surgical techniques to treat hydatid cysts of the liver have been gradually introduced.[15-24] Although reported to be successful, the series are still relatively small, and no explicit method has been reported of preventing spillage during laparoscopic aspiration and evacuation of the cystic cavity.

The open conservative surgical approach is the most accepted approach for giant cysts and consists of neutralization of the parasite, evacuation of cystic germinal components, and management of the pericystic cavity. Using the same principles, we developed a laparoscopic approach based on the creation of an isolated hypobaric system, through which the cysts can be managed without spillage of their content.[25,26] Our technique combines the effectiveness of open surgery with the advantages of the laparoscopic approach. To our knowledge, this is the only technique that has been

©2001 American Medical Association. All rights reserved.
Downloaded From: http://archsurg.jamanetwork.com/ on 12/27/2014

PATIENTS, MATERIALS, AND METHODS

PATIENTS

Our study population consisted of 31 patients with abdominal hydatid cysts. All patients underwent laparoscopic surgery between August 1992 and December 1999. All patients received a detailed explanation about the procedure and signed informed consent. There were 21 women and 10 men, ranging in age from 7 to 70 years (mean ± SD, 40.0 ± 18.2 years). Most of the patients were Arab inhabitants of western Galilee villages.

The 31 patients underwent 32 operations: 15 performed urgently and 17 on an elective basis. The most frequent indications for urgent operations were fever, acute right upper abdominal pain, vomiting, and nausea (**Table 1**). The main indication for elective operation was abdominal pain. Abnormal laboratory tests included leukocytosis (8), liver enzyme abnormalities (7), eosinophilia (5), hyperbilirubinemia (3), and hyperamylasemia (2). Preoperative imaging included abdominal ultrasound and thoracoabdominal computed tomography in all patients. Preoperative endoscopic retrograde cholangiopancreatography (ERCP) was performed in the 3 patients with jaundice. In 1 patient, a nasobiliary drain was inserted for marked hyperbilirubinemia and pancreatitis, although there were no hepatic intraductal findings. In the second case, hydatid daughter cysts were found and extracted from the bile ducts, and papillotomy was performed. In the third patient, ERCP findings were normal. Five patients had concurrent cardiovascular disease, 4 had type 2 diabetes, and 1 was 5 months postpartum. All patients were treated with albendazole (400 mg twice a day, or 12 mg/kg when weight was <60 kg) prior to operation (1-4 weeks), and with perioperative antibiotics (usually third-generation cephalosporins).

CYST LOCATION AND CHARACTER

Fifty-two parasitic cysts in the 31 patients were treated laparoscopically by a senior surgeon (A.B.) with no selection criteria regarding the cysts. Twenty-one of the patients had solitary hepatic cysts. Seven patients had 2 cysts, 2 patients were treated for 4 cysts, and 2 patients for 5 cysts. Echinococcal cyst diameter ranged from 3.5 to 25 cm (mean diameter, 8.36 ± 4.18 cm). Thirteen cysts were located in the left lobe of the liver (2 in a posterior position). Thirty-six cysts were located in the right lobe: 2 behind the gallbladder; 7, subdiaphragmatic; 8, in a lateral position; 15, in various anterior locations; and 4, in the posterior hidden aspect of the liver. We treated 3 extrahepatic cysts—two 10-cm cysts were located in the pelvis, between the rectum and the urinary bladder, and the third was in the spleen. All of these were associated with additional hepatic cysts.

SURGICAL TECHNIQUES

We have previously described the technique of the laparoscopic isolated hypobaric management of echinococcal cysts in experimental and clinical settings.[25-27] The abdominal cavity is insufflated with carbon dioxide, carefully explored, and the cysts identified. The principle of the technique, in brief, is to puncture, aspirate, irrigate, and evacuate the contents of the parasitic cyst through a large-diameter transparent cannula, which enables supervision from outside. The cannula has a beveled tip that is apposed firmly to the surface of the cyst by suction applied through its lateral stopcock, to create a "vacuum" (hypobaric) atmosphere inside the cannula, which then serves as an isolated working unit. When we use a long, 12-mm cannula (Ethicon Endo-Surgery Ltd, Cincinnati, Ohio) with holes near its tip, these are occluded by transparent tape. To treat very large complex cysts, our team assembled special long transparent 18- and 30-mm cannulas (**Figure 1**). The hermetic attachment of the cannula to the cyst wall is a prerequisite for our approach. For extra safety we use an additional aspirator in proximity to the "working unit" and sometimes use a long strip of dressing material (a swab) soaked with hypertonic sodium chloride solution around the cyst. Between 3 and 6 cannulas were required for each operation (3 cannulas in 7 operations, 4 in 18 operations, 5 in 6 operations, and 6 in 1 operation). We used a long, 12-mm cannula as the main working unit in 20 cases; a long assembled 18-mm cannula in 12 cases, and 30- and 10-mm cannulas in 1 case each (sometimes 2 main cannulas were required).

Following the evacuation of its contents, the cystic cavity was inspected meticulously through the laparoscope to exclude residual daughter cysts, bile leaks, or other findings. The treatment of the residual pericystic cavity following its evacuation and laparoscopic exploration included several techniques, depending on the number, size, and location of the cysts. Generally we performed partial pericystectomy of the protruding walls, closed-suction drainage, and omentoplasty (placement of an omental flap inside the pericyst) (**Table 2**). In 23 patients, subhepatic or perihepatic closed-suction drains were also used.

successfully evaluated both experimentally and theoretically that solves the problem of possible spillage during laparoscopic cyst evacuation.[27] Consequently, we applied our laparoscopic technique in a prospective, nonselective trial without considering criteria such as the size, location, or complexity of the cyst.

We present our cumulative experience with this technique for the years 1992 through 1999. Our series of patients treated laparoscopically is notable for the prospective nature of the study, the nonselective patient population, the relatively long follow-up period, and the approach to nonhepatic cysts. In addition, we present new technical modifications that we have developed.

RESULTS

INTRAOPERATIVE FINDINGS, HOSPITAL STAY, AND SURGICAL TECHNIQUES

Fifty-two echinococcal cysts were managed laparoscopically; 11 were secondarily infected, and 41 contained live parasites (larvae). Twenty-four cysts were complex, multilocular, or multiseptated, containing numerous daughter cysts. Their location is detailed in the "Patients, Materials, and Methods" section. Acute cholecystitis was found in 1 case. Following operation, hospital stay ranged between 3 and 12 days (average, 6 ± 2.7 days). Fifty-five percent of the

©2001 American Medical Association. All rights reserved.
Downloaded From: http://archsurg.jamanetwork.com/ on 12/27/2014

SPECIFIC TYPES OF CYSTS AND PROCEDURES

Multiple Cysts and Complex Cysts

In those patients with 2 or more cysts, we managed each cyst successively, according to the technique described in the previous section. In cases of cysts containing numerous daughter cysts and septae, although the technique is identical, it took more time and demanded meticulous exploration to evacuate all of the daughter cysts. This was accomplished by the introduction of a large-bore suction tube into the pericystic cavity, together with copious irrigation (**Figure 2**).

Infected Cysts

For secondarily infected cysts, following evacuation through the isolated working cannula, we left a closed-suction drain inside the pericystic cavity for several days and administered broad spectrum antibiotics (parenteral initially and enteral afterwards).

Subdiaphragmatic Cysts

We treated subdiaphragmatic cysts following mobilization of the liver by division of the triangular ligaments to expose the bare area. Seven patients were successfully treated using this approach.

Cysts Located Behind the Gallbladder, Pelvic Cysts, and Splenic Cysts

Cysts located behind the gallbladder were exposed and evacuated following cholecystectomy, or, in case of penetration to the gallbladder, en bloc with the gallbladder. Pelvic cysts were treated using the same technical principles, following Trendelenburg positioning and retraction of bowel. We treated 1 patient with a splenic cyst, which was large and secondarily infected. To preserve splenic tissue, we performed laparoscopic evacuation and partial pericystectomy with spleen salvage.

Transcystic Evacuation

Sometimes it is possible to approach one cyst through an anteriorly located second cyst, either for definitive treatment or for instillation of scolicidal agent followed by delayed staged operation (see the following section). We have used transcystic treatment for 3 posteriorly located cysts.

Staged Approach

This term refers to delayed completion of the surgical evacuation of echinococcal cysts that could not be accomplished during the initial laparoscopic operation. We have used this approach in patients harboring multiple cysts when there is a posteriorly located cyst that could not be approached easily and safely using transcystic evacuation. After the anterior cyst is treated, we instill hypertonic sodium chloride solution into the posterior cyst and may perform partial evacuation as described in a previous section. The patient then receives prolonged oral treatment with albendazole prior to completing the staged procedure, either laparoscopically or by percutaneous transhepatic aspiration. We have used a time interval of several months to allow for partial or complete disappearance of the treated pericystic cavities, and an effective scolicidal influence on the remaining cyst. This approach eliminates the need for large open surgery, which is of importance, especially for young women.

CYST ANALYSIS

The cystic contents underwent parasitological, bacteriological, and histopathological analysis. Tests were performed for viability of scolices (larvae) according to standard protocols (microscopic examination and vital dye staining tests).[28,29]

OUTCOME AND FOLLOW-UP

Patient follow-up ranged from 9 months to more than 8 years. After discharge and complete convalescence, patients were evaluated in the outpatient clinic every 6 months for the first 2 years and every year thereafter. Evaluation included physical examination, abdominal sonography, and liver function tests. In case of an evolving fluid collection in proximity to the operative site, image-guided percutaneous aspiration was performed (transhepatically if possible), and the fluid was centrifuged and then examined for bacteria and parasites. Operative mortality was defined as death during hospitalization or within 1 month after surgery.

STATISTICAL ANALYSIS

Statistical evaluation of the data was performed using the Fisher exact test and Goodman and Kruskal τ test. Results are expressed as median ± SD. Differences were considered significant at $P<.05$.

patients were discharged by the fifth day of hospitalization. All 52 cysts were approached laparoscopically as described. Total pericystectomy or hepatic resections were not performed owing to the large size and location of the cysts. The management of the pericystic cavity is given in Table 2.

POSTOPERATIVE ERCP

Postoperative ERCP was necessary in 1 patient, who was treated for 2 liver cysts (3.5 and 5 cm in diameter). The patient developed pancreatitis 3 weeks following hospital discharge. The ERCP and papillotomy were performed, and hydatid daughter cysts were extracted via the papilla.

CONVERSION TO OPEN LAPAROTOMY

Conversion to open laparotomy was performed in 1 patient who had 2 large hydatid cysts and abnormal liver function tests. One cyst (15 cm) was located in the left lobe of the liver and was successfully treated laparoscopically. The second cyst (7 × 10 cm, not included among the 52 cysts) was located posterior to the liver and anterior to the stomach and could not be identified with certainty laparoscopically, necessitating laparotomy. Following an intraoperative cholangiogram, choledochotomy was performed, daughter cysts extracted, and a T tube inserted.

©2001 American Medical Association. All rights reserved.
Downloaded From: http://archsurg.jamanetwork.com/ on 12/27/2014

Table 1. Indications for Elective and Urgent Operations for Hydatid Cysts

Indication	No. of Patients: Elective Surgery	No. of Patients: Urgent Surgery
Right upper quadrant abdominal pain	17	12
Nausea and vomiting	0	8
Right abdominal tenderness	4	6
Fever	0	5
Obstructive jaundice	0	3
Pancreatitis	0	1
Suspect acute cholecystitis	0	2
Ruptured cyst	0	1
Recent cyst enlargement	0	1
Incidental finding	2	0
Unresponsive to medical treatment	1	0
Pruritus	3	0
Palpable mass	1	0

Figure 1. A large germinal membrane and the assembled 30-mm transparent cannula through which it had been completely extracted.

ASSOCIATED OPERATIONS

Cholecystectomy was performed in 9 cases. Indications included acute cholecystitis (1), obstructive jaundice (2), biliary colic and cholelithiasis (3), biliary pancreatitis (1), and gallbladder proximity to the echinococcal cyst (2). In the latter cases, the gallbladder was resected because of technical reasons and to rule out its involvement in the parasitic process.

STAGED APPROACH

Delayed staged operation was performed in 1 patient who had 4 huge cysts. One cyst was posteriorly located (hidden) and could not be treated completely. Following hypertonic sodium chloride solution instillation and prolonged albendazole treatment, incomplete percutaneous drainage was performed and followed 7 months later by complete laparoscopic evacuation of a complex huge cyst. Convalescence was uneventful.

Table 2. Laparoscopic Treatment of Residual Pericystic Cavity

Procedure*	No. of Cysts (Omentoplasty)
Cystostomy (puncture) only	6 (1)
Cystostomy with intracystic closed suction drainage	3 (0)
Partial pericystectomy without drainage	14 (5)
Partial pericystectomy with drainage	29 (11)
Total	**52 (17)**

*Twenty-eight additional drains were used, either perihepatic or subhepatic.

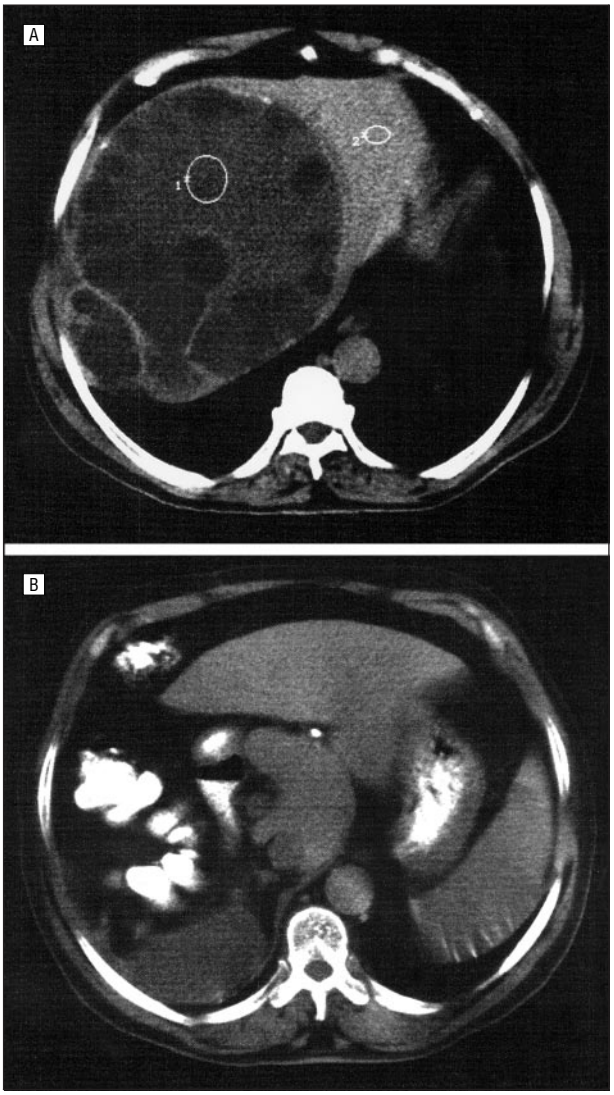

Figure 2. Axial computed tomographic slices of the upper abdomen of a patient before and after laparoscopic surgery. A, huge complex hydatid cyst (25-cm maximum diameter) of the right hepatic lobe. This patient also had a 10-cm complex pelvic cyst (not shown). B, Several months after surgery, a loop of large bowel occupies the space vacated by the huge cyst and right lobe of the liver.

Staged percutaneous transhepatic evacuation of a large posterior asymptomatic infected pericystic remnant was performed in 1 patient who had been treated laparoscopically for 5 large cysts 9 months previously.

©2001 American Medical Association. All rights reserved.
Downloaded From: http://archsurg.jamanetwork.com/ on 12/27/2014

A 20F drainage catheter was inserted to evacuate all of the infected debris and maintained for 5 weeks. Secondary pericystic cavity infection followed after 4 weeks, which required continuous lavage and suction until obliteration of all cavities.

COMPLICATIONS

Operative complications are presented in **Table 3**. Bile peritonitis occurred after 2 operations for large cysts (6.25%). In both operations, no drain had been left inside the pericystic cavity, and omentoplasty had been performed in one of them. The bile peritonitis was treated laparoscopically (lavage and pericystic drainage) in 1 patient, and the second underwent laparotomy. Bile peritonitis occurred in 2 (18%) of 11 operations without postoperative intrapericystic drainage, and in none of the 20 operations in which such a drain was left. In those 11 operations, 17 cysts were treated, of which 6 pericystic cavities were treated by pericystostomy only (no peritonitis) and 11 by partial pericystectomy (including the 2 cases mentioned; $P = .51$ by the Fisher test, $P = .28$ by the Goodman test).

Intraoperative anaphylactic reaction occurred in 1 patient, treated for 2 cysts. While we assembled the transparent cannula over the protruding 3.5-cm cyst, its thin membrane ruptured, and anaphylaxis developed within a few minutes. The patient was successfully treated with fluids, ephedrine, and dopamine. Postoperative convalescence was uneventful.

Atelectasis and pneumonia occurred in 2 patients and drug-induced fever in 1. One patient died following surgery. He was known to have 2 large complex cysts and had been admitted because of obstructive jaundice. He was treated preoperatively by nasobiliary drainage. Postoperative complications included bilateral pneumonia and biliary peritonitis, followed by multiorgan failure. He underwent 2 additional operations, with no evidence of echinococcal dissemination (negative findings on bacteriological and parasitological analyses) and died 1 month postoperatively of *Candida* sepsis.

FOLLOW-UP (CLINICAL OUTCOME)

In addition to 2 patients who underwent delayed-staged (planned) procedures, 4 patients underwent percutaneous drainage (2 of these were transhepatic) of a suspicious cavity that developed after the operation at 6, 8, 48, and 48 months. The aspirated fluid was carefully analyzed, but no evidence of parasitic recurrence or bacterial superinfection was found. At present, no evidence of recurrence has been proven after 9 to 97 months of follow-up (mean, 49 months).

Table 3. Intraoperative and Perioperative Complications in 32 Operations

Complication	No. of Cases	Percentage of Operations
Bile peritonitis	2	6.2
Anaphylactic reaction	1	3.1
Atelectasis and pneumonia	2	6.2
Drug-induced fever	1	3.1
Mortality (*Candida* sepsis)	1	3.1
Total No. of Patients	**5**	15.6

COMMENT

In the present study we have demonstrated our laparoscopic approach to be appropriate in the treatment of various kinds of abdominal hydatid cysts. This is the only technique to our knowledge in which all surgical maneuvers to penetrate the cyst and neutralize and evacuate its contents are performed safely through a transparent cannula that serves as a hypobaric working unit. The cyst and its contents were thus isolated from the hyperbaric peritoneal cavity (pneumoperitoneum). We began our study in 1992 after we were convinced that the technique was sound and safe. In our theoretical model, based on premises from physics, we evaluated various aspects of laparoscopy as they would relate to the treatment of hydatid cysts. We showed that the creation of pneumoperitoneum should not increase the risk of spillage, and may, in fact, increase safety by establishing a pressure gradient, which promotes the drainage of cystic contents into our apparatus rather than into the peritoneal cavity.[27] These experiments, using a goat hydatid cyst model, established the rationality and safety of our technique. We then embarked on our clinical trial, in a prospective and nonselective manner, including various hydatid cysts: extrahepatic cysts, the laparoscopic treatment of which has not been described in the literature to our knowledge; multiple hepatic cysts (up to 5 in 1 patient); complex cysts harboring numerous daughter cysts; and secondarily infected cysts.

The main goals of surgery are to neutralize and evacuate the cyst contents, while avoiding spillage into the peritoneal cavity, with the danger of anaphylaxis and dissemination.[1,7-10] Control of spillage is well established during open surgery, but necessitates a relatively large abdominal incision. Control of spillage during laparoscopic surgery poses a considerable challenge, especially since cyst contents are often under pressure. In the few previously published laparoscopic series, no definitive and safe solution was suggested to prevent spillage during the initial cyst puncture and evacuation. It has been suggested to position an aspirator near the point of penetration to evacuate any possible visible cystic leakage[16,17,19,23]; however, this cannot prevent minor spillage, nor can it help in case of sudden rupture of the cyst wall during penetration. The combination of filling the right subdiaphragmatic suprahepatic space with scolicidal fluid (cetrimide) and Trendelenburg positioning has been described during the treatment of right anterior lobe cysts, but this approach cannot prevent a sudden jet of fluid contents from escaping the cyst. In addition, since cetrimide is not allowed to fill the peritoneal cavity because of known adverse effects,[21-23] this approach is not useful for posterior hepatic or extrahepatic cysts. The technique that we describe in the current study allows safe access to hepatic cysts in almost any location, including subdiaphragmatic, posterior, and extrahepatic cysts. Safe needle aspiration of hydatid cysts using our concept was recently reported, but since only fluid from simple hy-

©2001 American Medical Association. All rights reserved.
Downloaded From: http://archsurg.jamanetwork.com/ on 12/27/2014

datid cysts can be evacuated with a needle, our technique is the only one in which complex cyst content can be evacuated safely.[24]

Percutaneous transhepatic drainage of hepatic hydatid cysts has been found to be effective in large numbers of patients.[30-35] The procedure of needle aspiration, injection of a scolicidal agent, and catheter drainage has advantages, including relatively short hospitalization, good cosmetic results, and the possibility of performing the procedure using local anesthesia. However, most studies included only uncomplicated Gharbi type A and B cysts.[36] Despite the promising results, there are a number of concerns about this technique, some of which include the potential of spillage of cyst contents, the difficulty of eradicating complicated cysts (types C and D), the lack of accessibility to extrahepatic cysts, and limitations in treating cysts in proximity to major blood vessels.[32-34]

In our study, we used percutaneous image-guided aspiration of cyst contents for 2 purposes: (1) to drain and analyze an enlarging postoperative fluid collection in proximity to the original operative site (to rule out recurrence), and (2) to complete our staged approach for a partially treated cystic cavity. Image-guided aspiration in patients who have already undergone an initial laparoscopic procedure is safer than aspiration in a patient whose cyst has not been treated, because the former operative site is isolated owing to the presence of adhesions and dense scar tissue.

In our study, there were no recurrences either in the original operative site or in a new site. The follow-up period (mean, 49 months), the modalities for cyst detection (ultrasound and computed tomography), our close postoperative follow-up, and the methods to detect postoperative fluid accumulation were satisfactory to fulfill the requirements for recurrence assessment.[37,38] Previously published recurrence rates vary from 0% to 20%, and a range of 5% to 10% is considered acceptable.[1,8-10,12,37,38] Total pericystectomy has been reported in laparoscopic procedures and clearly helps to prevent recurrence in selected cases of cysts located in the lateral aspects of the liver.[15,18,20] The use of scolicidal agents during surgery is still not settled. Points still to be decided include the optimal solution, its use in complex cysts, and the potential adverse effects of some of these materials.[1,10,39,40] We used hypertonic sodium chloride solution (20% and 3%) for intracystic injection, for pericystic lavage and for soaking the swabs that were placed laparoscopically around the cysts in several cases.

Four of our patients (12.9%) had 1 or more postoperative complications. This rate is acceptable compared with large series of open operations.[1,4,5,8-10] It is difficult to compare other studies using the laparoscopic approach with our study since other series have either been smaller, selective in nature, or with a much shorter period of follow-up. We encountered no major bile leaks; our 2 cases of bile peritonitis occurred in patients not treated with closed external drainage for large cysts. We therefore recommend external closed-tube drainage for every large cystic cavity, although this has not been proven statistically. We have used external closed-tube drainage for the past 3 years and during this time have had no case of bile peritonitis.

One patient (3.1%) died 1 month postoperatively. We might speculate whether intracystic drainage might have prevented this outcome. We are convinced that the laparoscopic approach was not the cause of death; hydatid disease is potentially lethal even if surgically treated, and such mortality rates (or higher) have been reported. One patient (3.1%) had an intraoperative complication, developing an anaphylactic reaction. However, this occurred before we assembled our "working unit" over the cystic surface and not during laparoscopic manipulations. Our hypobaric working unit allowed us to perform our study on a nonselective basis, since it enabled accessibility to almost all cysts, even in extrahepatic locations. In patients who had both a pelvic and a hepatic cyst, conventional open technique would demand a very large abdominal incision.

The well-known advantages of laparoscopic cholecystectomy are also relevant to laparoscopic operations for hepatic cysts. The superiority of laparoscopy is strengthened in light of the need for a much larger upper-abdominal incision for open hydatid surgery. Hospital stay for open surgery for hydatid cysts is reported to be in the range of 9 to 20 days and is much shorter in published selective laparoscopic series.[1,4-8,21,23-25] In our nonselective study, hospital stay (range, 3-12 days; average, 6 days) was significantly shorter as well.

The staged procedure expands our ability to avoid open operation, even for difficult cases. Although an additional procedure is required, we believe that such an approach is superior to prolonged open operation with a large abdominal incision, prolonged hospital stay, and other related potential complications. We should emphasize that cooperation between the surgeon and interventional radiologist is critical in the planning and execution of image-guided percutaneous procedures.

A criticism that might be leveled at our study is that the patients were not randomized into laparoscopic and open procedures and that the population is relatively small. The main reason for the nonrandomized character of our study is that we realized early on that our laparoscopic approach was superior to open surgery, and we therefore have virtually abandoned the open approach.

In summary, we have presented our successful prospective nonselective experience to treat a broad spectrum of hydatid cysts based on the concept of a hypobaric isolated working unit that is introduced intraperitoneally. We think that this approach will continue to gain in popularity for the benefit of patients who suffer from abdominal hydatid cyst disease.

Presented at the 7th International World Congress of Endoscopic Surgery, May 28 to June 4, 2000, Singapore.

Corresponding author and reprints: Amitai Bickel, MD, Department of Surgery, Western Galilee Hospital, PO Box 21, 22100 Nahariya, Israel.

REFERENCES

1. Milicevic M. Hydatid disease. In: Blumgart LH, ed. *Surgery of the Liver and Biliary Tract.* London, England: Churchill Livingston; 1994:1121-1150.
2. Langer B. Surgical treatment of hydatid disease of the liver. *Br J Surg.* 1987;74: 237-238.

©2001 American Medical Association. All rights reserved.
Downloaded From: http://archsurg.jamanetwork.com/ on 12/27/2014

3. Lewis JW, Koss N, Kerstein MD. A review of echinococcal disease. *Ann Surg*. 1975;181:390-396.
4. Langer JC, Rose DB, Keystone JS, Taylor BR, Langer B. Diagnosis and management of hydatid disease of the liver: a 15-year North American experience. *Ann Surg*. 1984;199:412-417.
5. Pitt NA, Korzelius J, Tompkins RK. Management of hepatic echinococcosis in South California. *Am J Surg*. 1986;152:110-115.
6. Doty JE, Tompkins RK. Management of cystic disease of the liver. *Surg Clin North Am*. 1989;69:285-295.
7. Sayek I, Yalin R, Sanac Y. Surgical treatment of hydatid disease of the liver. *Arch Surg*. 1980;115:847-850.
8. Dugalic D, Djukic V, Milicevic M, Stevovic D, Knezevic J, Pantic J. Operative procedures in the management of liver hydatidoses. *World J Surg*. 1982;6:115-118.
9. Morel P, Robert J, Rohner A. Surgical treatment of hydatid disease of the liver: a survey of 69 patients. *Surgery*. 1988;104:859-862.
10. Magistrelli P, Masetti R, Coppola R, Messia A, Nuzzo G, Picciocchi A. Surgical treatment of hydatid disease of the liver: a 20-year experience. *Arch Surg*. 1991; 126:518-523.
11. Belli L, Aseni P, Rondinara GF, Bertini M. Improved results with pericystectomy in normothermic ischemia for hepatic hydatidosis. *Surg Gynecol Obstet*. 1986; 163:127-132.
12. Demirci S, Eraslan S, Anadol E, Bozalti L. Comparison of the results of different surgical techniques in the management of hydatid cysts of the liver. *World J Surg*. 1989;13:88-91.
13. Ekrami Y. Surgical treatment of hydatid disease of the liver. *Arch Surg*. 1976; 111:1350-1352.
14. Wu X, Tan JZ, Yang JH, Shi TH, Zhou SN. Open method versus capsulorrhaphy without drainage in the treatment of children with hepatic hydatid disease. *Br J Surg*. 1992;79:1184-1186.
15. Katkhouda N, Fabiani P, Benizri E, Mouiel J. Laser resection of a liver hydatid cyst under videolaparoscopy. *Br J Surg*. 1992;79:560-561.
16. Mompean JAL, Paricio PP, Campas RR, Ayllon JG. Laparoscopic treatment of a liver hydatid cyst. *Br J Surg*. 1993;80:907-908.
17. Yucel O, Talu M, Unalmiser S, Ozdede S, Gurkan A. Videolaparoscopic treatment of a liver hydatid cyst with partial cystectomy and omentoplasty. *Surg Endosc*. 1996;10:434-436.
18. Guilbert L, Gayral F. Laparoscopic pericystectomy of a liver hydatid cyst. *Surg Endosc*. 1995;9:442-443.
19. Alper A, Emre A, Acarli K, Bilge O, Ozden I, Ariogul O. Laparoscopic treatment of hepatic hydatid disease. *J Laparoendosc Surg*. 1996;6:29-33.
20. Sever M, Skapin S. Laparoscopic pericystectomy of liver hydatid cyst. *Surg Endosc*. 1995;9:1125-1126.
21. Khoury G, Jabbour-Khoury S, Bikhazi K. Results of laparoscopic treatment of hydatid cysts of the liver. *Surg Endosc*. 1996;10:57-59.
22. Massoud WZ. Laparoscopic excision of a single hepatic hydatid cyst. *Int Surg*. 1996;81:9-13.
23. Ertem M, Uras C, Karahasanoglu T, Erguney S, Alemdaroglu K. Laparoscopic approach to hepatic hydatid disease. *Dig Surg*. 1998;15:333-336.
24. Berberoglu M, Taner S, Dilek ON, Demir A, Sari S. Gasless vs laparoscopy in the treatment of hepatic hydatid disease. *Surg Endosc*. 1999;13:1195-1198.
25. Bickel A, Loberant N, Shtamler B. Laparoscopic treatment of hydatid cyst of the liver: initial experience with a small series of patients. *J Laparoendosc Surg*. 1994; 4:127-133.
26. Bickel A, Eitan A. The use of a large, transparent cannula with a beveled tip, for safe laparoscopic management of hydatid cysts of liver. *Surg Endosc*. 1995;9: 1304-1305.
27. Bickel A, Daud G, Urbach D, Lefler E, Barasch EF, Eitan A. Laparoscopic approach to hydatid liver cysts: is it logical? physical, experimental and practical aspects. *Surg Endosc*. 1998;12:1073-1077.
28. Smyth JD, Barrett NJ. Procedures for testing the viability of human hydatid cysts following surgical removal, especially after chemotherapy. *Trans R Soc Trop Med Hyg*. 1980;74:649-652.
29. Tsimoyiannis EC, Siakas P, Moutesidou KJ, Karaianni M, Kontoyiannis DS, Gossios KJ. Perioperative benzimidazole therapy in human hydatid liver disease. *Int Surg*. 1995;80:131-133.
30. Giorgio A, Tarantino L, Francica G, et al. Unilocular hydatid liver cysts: treatment with US-guided, double percutaneous aspiration and alcohol injection. *Radiology*. 1992;184:705-710.
31. Salama H, Abdel-Rahab MF, Strickland GT. Diagnosis and treatment of hepatic hydatid cysts with the aid of echo-guided percutaneous cyst puncture. *Clin Infect Dis*. 1995;21:1372-1376.
32. Serami F, McNamara TO. Hydatid cysts of the liver: long-term results of percutaneous treatment using a cutting instrument. *AJR Am J Roentgenol*. 1995;165: 1163-1167.
33. Ustunsoz B, Akham O, Kamiloglu MA, Somuncu I, Ugurel MS, Cetiner S. Percutaneous treatment of hydatid cysts of the liver: long-term results. *AJR Am J Roentgenol*. 1999;172:91-96.
34. Men S, Hekimoglu B, Yucesoy C, Arda IS, Baran I. Percutaneous treatment of hepatic hydatid cysts: an alternative to surgery. *AJR Am J Roentgenol*. 1999; 172:83-89.
35. Khuroo MS, Wani NA, Javid G, et al. Percutaneous drainage compared with surgery for hepatic hydatid cysts. *N Engl J Surg*. 1997;337:881-887.
36. Gharbi HA, Hassine W, Brauner MW, Dupuch K. Ultrasound examination of the hydatid liver. *Radiology*. 1981;139:459-463.
37. Little JM, Hollands MJ, Ekberg H. Recurrence of hydatid disease. *World J Surg*. 1988;12:700-704.
38. Mottaghian H, Saidi F. Postoperative recurrence of hydatid disease. *Br J Surg*. 1978;65:237-242.
39. Garcia JIL, Alonso E, Gonzales-Uriarte J, Romano DR. Evaluation of scolicidal agents in an experimental hydatid disease model. *Eur Surg Res*. 1997;29:202-208.
40. Belghiti J, Benhamou JP, Houry S, Grenier P, Huguier M, Fekete F. Caustic sclerosing cholangitis: a complication of the surgical treatment of hydatid disease of the liver. *Arch Surg*. 1986;121:1162-1165.

©2001 American Medical Association. All rights reserved.
Downloaded From: http://archsurg.jamanetwork.com/ on 12/27/2014