

# Surgical Resection for Metastatic Melanoma to the Liver

## *The John Wayne Cancer Institute and Sydney Melanoma Unit Experience*

D. Michael Rose, MD; Richard Essner, MD; T. Michael D. Hughes, MBBS; Paul C. Y. Tang, MBBS; Anton Bilchik, MD; Leslie A. Wanek, DrPH; John F. Thompson, MD; Donald L. Morton, MD

**Hypothesis:** Metastatic melanoma to the liver is not incurable; complete surgical resection can achieve long-term survival in selected patients.

**Background:** Metastases to the liver are diagnosed in 10% to 20% of patients with American Joint Committee on Cancer stage IV melanoma. Surgical resection has not been generally accepted as a therapeutic option, as most patients will have other sites of disease that limit their survival to a median of only 4 to 6 months. However, there is little information on outcomes following resection in those patients with disease limited to the liver.

**Patients and Methods:** Review of the prospective melanoma databases at the John Wayne Cancer Institute, Santa Monica, Calif, and the Sydney Melanoma Unit, Sydney, Australia, identified 1750 patients with hepatic metastases, of whom 34 (2%) underwent exploration with intent to resect the metastases. Prognostic factors within the group of patients who underwent resection were examined by univariate and multivariate analysis, and median disease-free survival (DFS) and overall survival (OS) were calculated.

**Results:** Of 34 patients undergoing exploratory celiotomy, 24 (71%) underwent hepatic resection and 10 (29%) underwent exploration but not resection. Eighteen patients (75%) underwent complete surgical resection, while the remaining 6 underwent palliative or debulking procedures with incomplete resection. The

operative resections included lobectomy (n=14), segmentectomy (4), nonanatomic resection (5), and extended lobectomy (1). The median number of resected lesions was 1, and median lesion size was 5 cm (range, 0.7-22 cm). The median disease-free interval between initial diagnosis of melanoma and development of hepatic metastases was 58 months (range, 0-264 months). Median DFS and OS estimates in the 24 patients who underwent surgical resection were 12 months (range, 0-147 months) and 28 months (range, 2-147 months), respectively. Five-year DFS and OS in this group were 12% and 29%. Macroscopically, complete resection of disease ( $P=.001$ ) and histologically negative resection margins ( $P=.03$ ) significantly improved DFS by univariate analysis. Patients rendered surgically free of disease also tended to have improved OS ( $P=.06$ ). Median OS was 28 months for patients who underwent surgical resection compared with 4 months for patients who underwent exploration only ( $P<.001$ ).

**Conclusions:** Resection of metastatic melanoma to the liver may improve DFS and OS in selected patients, similar to resection of other metastatic sites. Therefore, patients with limited metastatic sites, including the liver, who can be rendered free of disease should be considered for complete surgical resection, as their prognosis is otherwise dismal.

*Arch Surg.* 2001;136:950-955

From the John Wayne Cancer Institute at Saint John's Health Center, Santa Monica, Calif (Drs Rose, Essner, Bilchik, Wanek, and Morton); and Sydney Melanoma Unit, Royal Prince Alfred Hospital, and the Department of Surgery, University of Sydney, Sydney, Australia (Drs Hughes, Tang, and Thompson).

**T**HE PROGNOSIS of patients with American Joint Committee on Cancer (AJCC) stage IV melanoma is dismal, with a median survival of 4 to 6 months and an actuarial 5-year survival of 6%.<sup>1</sup> The optimal treatment for advanced melanoma remains in evolution, as neither chemotherapy nor immunotherapy have yet been shown to alter outcome. There is increasing evidence to support the judicious use of surgical resection in appropriately selected patients. Depending on the anatomic site, median overall survival (OS) rates between 24 and 49 months have been re-

ported following complete resection of pulmonary,<sup>2-7</sup> gastrointestinal,<sup>7-10</sup> and adrenal metastases.<sup>11,12</sup> Some patients have had prolonged survival following repeated metastasectomy, suggesting that there is even a smaller subgroup of patients with advanced disease who can be salvaged by surgery.<sup>13</sup>

### *See Invited Critique at end of article*

The role of surgical resection for hepatic metastases remains poorly defined. Hepatic metastases are diagnosed in only 10% to 20% of patients

## PATIENTS AND METHODS

The prospectively collected melanoma databases of the John Wayne Cancer Institute, Santa Monica, Calif, and the Sydney Melanoma Unit, Sydney, Australia, were reviewed to identify patients who underwent treatment for melanoma metastases to the liver. Between 1971 and 1999, 26204 patients were evaluated at the 2 centers, and 1750 (6.7%) had hepatic metastases. Thirty-four patients (2%) underwent surgical exploration for attempted hepatic resection. Patients undergoing intraoperative biopsy of the liver to confirm a diagnosis of metastatic melanoma were excluded from the study. All patients underwent preoperative staging to determine eligibility for surgery, including computed tomographic scans of the chest, abdomen, and pelvis, magnetic resonance imaging of the brain, and bone scans as clinically indicated. <sup>18</sup>Fluorodeoxyglucose positron emission tomographic (<sup>18</sup>FDG-PET) scanning has been used in the past 7 years as a tool to stage cancer in melanoma patients.

Factors analyzed for survival differences included patient age, sex, initial tumor stage and characteristics, disease-free interval (calculated as the time from the operation for the primary melanoma to the development of hepatic metastases), anatomic extent and location of recurrences, operative details of hepatic resection, pathologic findings, adjuvant therapy, recurrence following resection, and follow-up times. Primary disease staging was performed according to AJCC guidelines.<sup>17</sup>

Disease-free survival (DFS) was calculated in months from the time of hepatic resection to the first recurrence of disease. Overall survival (OS) was determined from the time of development of hepatic metastases until the time of last follow-up or death. Overall and DFS curves were calculated by the Kaplan-Meier method. Univariate and multivariate survival analyses were performed using the log-rank test and Cox proportional hazards modeling, respectively. Statistical significance was defined as  $P < .05$ .

with stage IV melanoma, yet most patients will be found to have liver disease on postmortem examination.<sup>14</sup> Patients with hepatic metastases as their initial site of metastatic disease are generally thought to have a very poor prognosis with a median survival of only 4.4 months.<sup>1</sup> There are only a few reports of long-term survivors following hepatic resection.<sup>15,16</sup> Owing to the paucity of cases, few series have been dedicated to the surgical management of metastatic melanoma to the liver alone. Prognostic factors in these patients have not been previously evaluated. We examined the combined experience of 2 large international melanoma referral centers to identify patients treated by surgical resection for metastatic melanoma to the liver and to determine if any factors would be useful for identifying patients who should be treated with surgery.

**Table 1. Clinicopathologic Features of 24 Patients Undergoing Hepatic Resection for Metastatic Melanoma**

Feature	No. (%)
Age, y, median (range)	57 (26-71)
Sex, M/F	12/12
American Joint Committee on Cancer stage at initial presentation <sup>17</sup>	
I/II	15 (63)
III	3 (12)
IV	4 (17)
Unknown	2 (8)
Disease-free interval from initial stage, mo, median (range)	58 (0-264)
Hepatic resection	
Nonanatomic resection	5 (21)
Segmentectomy	4 (17)
Lobectomy	14 (58)
Extended lobectomy	1 (4)
No. of metastases	
1	18 (75)
2	4 (17)
>2	2 (8)
Synchronous extrahepatic metastases	12 (50)
Free of disease following resection	18 (75)

## RESULTS

### PATIENT DEMOGRAPHICS

Of the 34 patients who underwent surgery for attempted resection, 10 patients (29%) had extensive intra-abdominal disease identified at exploratory celiotomy and therefore did not undergo resection. The remaining 24 patients (71%) underwent partial or complete resection of hepatic metastases. Patient demographic factors, operative details, and pathologic findings are summarized in **Table 1**. Synchronous extrahepatic metastases were found at celiotomy in 12 (50%) of the 24 patients.

### OPERATIVE PROCEDURES AND FINDINGS

All patients underwent formal exploratory celiotomy and complete mobilization of the liver. In more recent cases, intraoperative ultrasound was used to evaluate the number and extent of hepatic lesions. No operative deaths occurred in this series. One patient died owing to multi-system organ failure 2 months following a right hepatic lobectomy. A second patient had a fatal cerebrovascular accident 3 months following a right hepatic lobectomy. Autopsy revealed no evidence of intracranial metastatic disease. Both of these patients were free of melanoma at the time of death.

The preoperative intent of exploration was curative resection in 18 (75%) of the 24 patients and palliative debulking in 6 patients (25%). Surgical removal of all identified metastatic disease was achieved in 18 of the patients (75%) (**Table 2**). Two patients underwent a second hepatic resection at 21 and 37 months following their initial metastasectomy. The second of these patients remains alive and free of disease 76 months following the first resection. A third patient underwent resection of recurrent disease involving the diaphragm 1 year follow-

**Table 2. Features and Outcomes of 18 Patients Undergoing Complete Resection of Hepatic Metastases\***

Patient	EHD Sites Resected at Operation	Recurrence Sites	DFS, mo	OS, mo	Status
1	Diaphragm	...	147	147	NED
8	None	Lung	24	82	DOD
2	None	Liver†	37	76	NED
6	None	Liver	15	70	AWD
3	Soft tissue	...	55	55	NED
9	None	Liver, lung	34	44	DOD
10	Mesenteric LN	Liver, mesenteric LN	21	38	DOD
4	None	...	32	32	NED
11	None	GI	15	28	DOD
12	None	Unknown	19	19	DOD
7	Soft tissue	Soft tissue	3	17	AWD
5	None	Diaphragm†	12	16	NED
13	GI, mesenteric LN	Liver, lung	6	15	DOD
14	None	Brain	4	9	DOD
15	LN	Bone	4	8	DOD
16	None	Liver, omentum	3	7	DOD
17	None	...	3	3	DOC (CVA)
18	Periportal LN	...	2	2	DOC (MSOF)

\*EHD indicates extrahepatic disease; DFS, disease-free survival following resection; OS, overall survival following resection; ellipses, not applicable; NED, alive with no evidence of disease; DOD, dead of disease; AWD, alive with disease; LN, lymph nodes; GI, gastrointestinal metastases; DOC, dead of other causes; CVA, cerebrovascular accident; and MSOF, multisystem organ failure.

†Patients subsequently rendered NED following a second resection.

**Table 3. Features and Outcomes of 6 Patients Undergoing Incomplete Resection of Hepatic and Extrahepatic Metastases\***

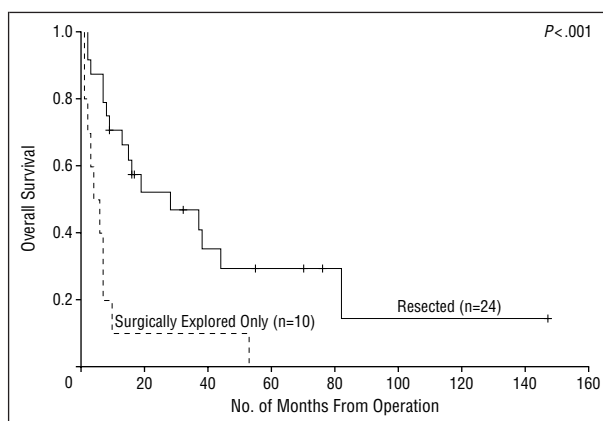
Patient	EHD Sites at Time of Operation	OS, mo	Status
1	None	37	DOD
2	Lung, omentum	16	DOD
3	Lung, soft tissue	13	DOD
4	GI, omentum, adrenal	7	AWD
5	Mesentery, soft tissue	7	DOD
6	Celiac lymph nodes	2	DOD

\*EHD indicates extrahepatic disease; OS, overall survival following resection; DOD, dead of disease; GI, gastrointestinal metastases; and AWD, alive with disease.

ing hepatic resection and remains free of disease at 16 months' follow-up. Seven patients (39%) had synchronous hepatic and extrahepatic metastases, all of which were completely resected at hepatic resection. Thirteen patients (72%) developed recurrent melanoma following hepatic resection. The liver was the most common site of recurrence, occurring in 6 patients (33%). Six of the 24 patients had residual hepatic and/or extrahepatic metastatic disease following hepatic resection (**Table 3**).

#### DISEASE-FREE AND OVERALL SURVIVAL

Median, 3-, and 5-year estimated OS rates for the entire group of 34 patients undergoing exploration and attempted resection were 10 months, 36%, and 20%, respectively. The median DFS in the 24 resected patients was 12 months (range, 0-147 months), with a median OS of 28 months (range, 2-147 months). Overall survival at 3 and 5 years of the patients who underwent re-



**Figure 1.** Overall survival of patients undergoing resection of hepatic melanoma metastases compared with patients undergoing exploration alone. Resected patients had a significantly improved survival ( $P < .001$ ).

section was 41% and 29%, respectively. The 10 patients undergoing exploration alone had a median survival of 4 months. Overall median survival in the 899 patients with hepatic metastases treated nonoperatively was 6 months with a 5-year survival of 4%. Patients undergoing resection had a significantly improved survival when compared with those undergoing exploration alone ( $P < .001$ , **Figure**). Factors associated with an improved DFS by univariate analysis included macroscopically complete resection ( $P = .001$ ) and histologically negative resection margin ( $P = .03$ , **Table 4**). Patients rendered surgically free of disease had a trend toward an improved OS ( $P = .06$ , **Table 5**). Demographic factors, initial tumor characteristics, and the use of any adjuvant therapy did not have a significant impact on survival. In addition, no prognostic factor achieved statistical significance for either disease-free or OS on multivariate analysis.

The greatest experience with hepatic resection has been for the treatment of colorectal metastases. The growing acceptance of hepatic resection as an appropriate treatment for colon metastases has been owing to improvements in operative and anesthetic technique and better selection of patients, resulting in a significant number of long-term survivors (up to 30% or 40% at 5 years) and relatively low operative morbidity and mortality rates (<5%).<sup>18</sup> To optimize these results, several investigators have tried to select criteria on which to base the decision for surgery. Fong et al<sup>19</sup> have made specific recommendations based on the number and size of metastases, disease-free interval from primary tumor to metastases, presence of lymph node positivity, and preoperative carcinoembryonic antigen levels.

There is a smaller number of reports on hepatic resection for noncolorectal malignant neoplasms; however, several series suggest similar prognostic factors, including curative resection, long disease-free interval, lack of extrahepatic disease, and primary tumor type.<sup>20-23</sup> The data available on hepatic resection for metastatic melanoma largely result from the analysis of subsets of more expanded series of noncolorectal metastases, which makes it difficult to determine if hepatic resection is useful for melanoma (**Table 6**).<sup>5,21-29</sup> In 1978, Foster<sup>30</sup> reported a series of 72 patients undergoing liver resections for metastatic disease. He collected all the available contemporary reports and personally visited 98 hospitals on a "liver tumor survey" to collect data on hepatic resections. Only 13 patients (18%) underwent hepatic resection for metastatic melanoma. The median survival of these patients was 10 months, with a 5-year survival of 8%. In other reports, the median survival following surgery has been reported to be between 10 and 20 months, with an occasional long-term survivor of up to 184 months.<sup>22,23,26,27,29</sup> Long-term survival remains the exception, however, as most DFS and OS times are limited, as seen in the current series with a median DFS of 12 months.

Several unifying concepts have been identified in the examination of prognostic factors following resection of metastatic melanoma at other sites. Longer disease-free interval, resection of all apparent tumor, and lower tumor burden at the time of resection have all been associated with improved outcomes.<sup>2-12</sup> Similar findings were found in the current series with macroscopically complete metastasectomy, a histologically negative resection margin, the liver as the only initial site of metastatic disease, and absence of extrahepatic disease at the time of resection being associated with improved survival. Not surprisingly, patients undergoing complete surgical resection had a statistically better survival ( $P < .001$ ) than those undergoing exploration alone, and those undergoing complete resection tended to have an improved survival ( $P = .06$ ) compared with patients not rendered free of disease.

This retrospective series reflects the experience of 2 major referral centers for the treatment of melanoma. Individually, these centers have 2 of the largest prospectively collected melanoma databases in the world. Despite this, only 24 patients undergoing resection were

**Table 4. Statistical Analysis of the Disease-Free Survival (DFS) of 24 Patients Undergoing Hepatic Resection**

Factor	Median DFS, mo	Univariate <i>P</i>
Operative results		.001
Surgically free of disease (n=18)	19	
Persistent disease (n=6)	0	
Resection margin		.03
Negative (n=21)	19	
Positive (n=3)	0	
Initial sites of stage IV disease		.47
Hepatic only (n=12)	21	
Hepatic and extrahepatic (n=12)	4	
Extrahepatic disease at resection		.43
Absent (n=12)	19	
Present (n=12)	4	
Hepatic metastases		.34
Single (n=18)	19	
Multiple (n=6)	4	

**Table 5. Statistical Analysis of the Overall Survival (OS) of 24 Patients Undergoing Hepatic Resection**

Factor	Median OS, mo	Univariate <i>P</i>
Operative results		.06
Surgically free of disease (n=18)	38	
Persistent disease (n=6)	13	
Resection margin		.15
Negative (n=21)	37	
Positive (n=3)	13	
Initial sites of stage IV disease		.20
Hepatic only (n=12)	38	
Hepatic and extrahepatic (n=12)	15	
Extrahepatic disease at resection		.51
Absent (n=12)	37	
Present (n=12)	15	
Hepatic metastases		.66
Single (n=18)	28	
Multiple (n=6)	27	

identified (1.4% of all patients identified with hepatic metastases in the databases). These patients thus represent an extremely select group with a resultant low statistical power. However, the presence of favorable operative factors, particularly the ability to render a patient free of disease, increased OS at least 2- to 3-fold (Table 5). The importance of complete resection of all disease has also been noted in the report from Lang et al<sup>24</sup> on hepatic resection of 140 noncolorectal nonneuroendocrine metastases. The authors suggest that the possibility of a complete resection has potentially greater prognostic significance than the presence of extrahepatic tumor. Findings from the current series suggest that selection criteria for hepatic resection of metastatic melanoma should be similar to criteria used in patients with metastatic colorectal carcinoma or patients with nonhepatic melanoma metastases.

A retrospective study does not readily allow identification of all factors influencing the selection of patients for potential resection. Nevertheless, it seems that 2 factors did characterize the selected patients. First, it

**Table 6. Reported Outcomes Following Hepatic Resection for Metastatic Melanoma**

Source, y	Noncolorectal Metastases, No.	Melanoma Metastases, No.	Melanoma Metastases*		
			Median OS, mo	OS Range, mo	5-Year Survival, %
Foster, <sup>30</sup> 1978	72	13	10	2-72	8
Iwatsuki et al, <sup>25</sup> 1983	19	1	...	...	...
Papachristou et al, <sup>26</sup> 1983	...	3	16	...	...
Ekberg et al, <sup>27</sup> 1986	8	3	19	5-72	...
Olak et al, <sup>28</sup> 1986	30	1	...	...	...
Stehlin et al, <sup>29</sup> 1988	30	4	13	3-52	...
Wolf et al, <sup>20</sup> 1991	10	1	...	...	...
Karakousis et al, <sup>5</sup> 1994	2	2	...	...	...
Harrison et al, <sup>21</sup> 1997	96	7	...	...	...
Lindell et al, <sup>22</sup> 1998	32	3	51	5-184	33
Elias et al, <sup>23</sup> 1998	147	10	20	...	<20
Lang et al, <sup>24</sup> 1999	140	10	...	...	22
Current series, 2001	...	24	28	2-147	29

\*OS indicates overall survival.

is notable that our patients had a 58-month median disease-free interval prior to presenting with hepatic disease. In contrast, the median disease-free interval of the 899 patients with hepatic metastases who were treated nonoperatively at the John Wayne Cancer Institute database was 35 months. Second, the patients in this series had relatively limited hepatic disease; 92% had only 1 or 2 hepatic metastases. It is important to note that 7 (39%) of the 18 patients who were successfully rendered free of disease at hepatic resection underwent concurrent complete resection of additional extrahepatic disease. Extrahepatic disease, in of itself, is therefore not an absolute contraindication to hepatic resection, as long as the disease is resectable.

Selection of appropriate patients for hepatic resection of metastatic melanoma must be individualized and should include an extensive evaluation of the extent of disease. Current evaluation at the John Wayne Cancer Institute includes computed tomographic scans of the chest, abdomen, and pelvis, magnetic resonance imaging of the brain, and whole-body <sup>18</sup>FDG-PET scanning. In addition, we favor a more aggressive operative approach to patients with longer disease-free intervals prior to the development of hepatic metastases, as this has been previously identified as an independent prognostic factor in patients with AJCC stage IV melanoma.<sup>1</sup> We currently recommend that healthy patients with limited metastatic disease who can be rendered surgically free of disease be considered for potential hepatic resection. Clearly, most of these patients will have disease recurrence over time; however, this approach does offer the possibility of long-term survival to a select group. Prospective studies analyzing prognostic factors in patients with hepatic metastases are needed to further define the appropriate role of resection.

Repeated metastasectomy has been advocated in selected patients with AJCC stage IV melanoma if the patient can be rendered surgically free of disease.<sup>13</sup> Scattered reports of repeated hepatic resection for metastatic melanoma have been published in the literature, with a suggestion of long-term benefit in selected patients.<sup>31</sup> Two patients in this series underwent repeated hepatic resection for isolated recurrent metastatic disease within the

liver. The hepatic recurrences appeared 21 and 37 months following initial resections. One patient lived an additional 17 months before dying of systemic disease, while the second patient is currently free of disease 3 years following the second hepatic surgery. However, caution should be used in extrapolating from these cases into everyday clinical practice. As with repeated hepatic resection for metastatic colorectal cancer, repeated resection can be performed, and survival may be improved; however, the likelihood of cure is low.<sup>32</sup> Careful selection of individuals with isolated recurrent disease is mandatory prior to consideration of repeated resection.

In conclusion, we report the experience of the John Wayne Cancer Institute and the Sydney Melanoma Unit with surgical resection for metastatic melanoma to the liver. Similar to findings in resection of melanoma metastases from other sites, patients with limited disease who can be rendered surgically free of disease tend to have improved survivals. Some patients will achieve excellent long-term results; however, most will have disease that progresses and eventually die of melanoma. Careful screening and realistic expectations of surgical resection are necessary to achieve optimal outcomes. With the overall lack of effective systemic therapy presently, healthy individuals with appropriate prognostic factors should be considered for an aggressive surgical approach.

*This study was supported by California Cancer Research Program grant 2PF0166 (Dr Essner), grant CA12582 from the National Cancer Institute (Dr Morton), and funding from the Wrather Family Foundation (Los Angeles, Calif), and the Saban Family Foundation (Los Angeles).*

*Corresponding author and reprints: Richard Essner, MD, John Wayne Cancer Institute, 2200 Santa Monica Blvd, Santa Monica, CA 90404 (e-mail: essnerr@jwci.org).*

## REFERENCES

- Barth A, Wanek LA, Morton DL. Prognostic factors in 1521 melanoma patients with distant metastases. *J Am Coll Surg.* 1995;181:193-201.
- Wong JH, Euhus DM, Morton DL. Surgical resection for metastatic melanoma to the lung. *Arch Surg.* 1988;123:1091-1095.

3. Tafra L, Dale PS, Wanek LA, Ramming KP, Morton DL. Resection and adjuvant immunotherapy for melanoma metastatic to the lung and thorax. *J Thorac Cardiovasc Surg.* 1995;110:119-129.
4. Ollila DW, Morton DL. Surgical resection as the treatment of choice for melanoma metastatic to the lung. *Chest Surg Clin North Am.* 1998;8:183-196.
5. Karakousis CP, Velez A, Driscoll DL, Takita H. Metastectomy in malignant melanoma. *Surgery.* 1994;115:295-302.
6. La Hei ER, Thompson JF, McCaughan BC, Petersen-Schaefer K, Ramanaden D, Coates AS. Surgical resection of pulmonary metastatic melanoma: a review of 83 thoracotomies. *Asia Pacific Heart J.* 1996;5:111-114.
7. Lejeune FJ, Lienard D, Sales F, Badr-el-din H. Surgical management of distant melanoma metastases. *Semin Surg Oncol.* 1992;8:381-391.
8. Ollila DW, Essner R, Wanek LA, Morton DL. Surgical resection for melanoma metastatic to the gastrointestinal tract. *Arch Surg.* 1996;131:975-979.
9. Mosimann F, Fontollet C, Genton A, Gertsch P, Pettavel J. Resection of metastases to the alimentary tract from malignant melanoma. *Int Surg.* 1982;67:257-260.
10. Khadra MH, Thompson JF, Milton GW, McCarthy WH. The justification for surgical treatment of metastatic melanoma of the gastrointestinal tract. *Surg Gynecol Obstet.* 1990;171:413-416.
11. Haigh PI, Essner R, Wardlaw JC, Stern SL, Morton DL. Long-term survival after complete resection of melanoma metastatic to the adrenal gland. *Ann Surg Oncol.* 1999;6:633-639.
12. Branum GD, Epstein RE, Leight GS, Seigler HF. The role of resection in the management of melanoma metastatic to the adrenal gland. *Surgery.* 1991;109:127-131.
13. Ollila DW, Hseuh EC, Stern SL, Morton DL. Metastectomy for recurrent stage IV melanoma. *J Surg Oncol.* 1999;71:209-213.
14. Meyers ML, Balch CM. Diagnosis and treatment of metastatic melanoma. In: Balch CM, Houghton AN, Sober AJ, Song S-J, eds. *Cutaneous Melanoma.* 3rd ed. St Louis, Mo: Quality Medical Publishing Inc; 1998:325-372.
15. Schwartz SI. Hepatic resection for noncolorectal nonneuroendocrine metastases. *World J Surg.* 1995;19:72-75.
16. Foster JH, Lundy J. Liver metastases. *Curr Prob Surg.* 1981;18:160-202.
17. Malignant melanoma of the skin. In: Fleming ID, Cooper JS, Henson DE, et al, eds. *AJCC Cancer Staging Manual.* 5th ed. Philadelphia, Pa: Lippincott-Raven; 1997:163-167.
18. Fong Y, Salo J. Surgical therapy of hepatic colorectal metastasis. *Semin Oncol.* 1999;26:514-523.
19. Fong Y, Fortner J, Sun RL, Brennan MF, Blumgart LH. Clinical score for predicting recurrence after hepatic resection for metastatic colorectal cancer: analysis of 1001 consecutive cases. *Ann Surg.* 1999;230:309-318.
20. Wolf RF, Goodnight JE, Krag DE, Schneider PD. Results of resection and proposed guidelines for patient selection in instances of noncolorectal hepatic metastases. *Surg Gynecol Obstet.* 1991;173:454-460.
21. Harrison LE, Brennan MF, Newman E, et al. Hepatic resection for noncolorectal nonneuroendocrine metastases: a 15-year experience with 96 patients. *Surgery.* 1997;121:625-632.
22. Lindell G, Ohlsson B, Saarela A, Andersson R, Tranberg K-G. Liver resection of noncolorectal secondaries. *J Surg Oncol.* 1998;69:66-70.
23. Elias D, Cavalcanti de Albuquerque A, Eggenspieler P, et al. Resection of liver metastases from a noncolorectal primary: indications and results based on 147 monocentric patients. *J Am Coll Surg.* 1998;187:487-493.
24. Lang H, Nussbaum K-T, Weimann A, Raab R. Liver resection for noncolorectal, nonneuroendocrine hepatic metastases [in German]. *Chirurg.* 1999;70:439-446.
25. Iwatsuki S, Shaw BW, Starzl TE. Experience with 150 liver resections. *Ann Surg.* 1983;197:247-253.
26. Papachristou DN, Fortner JJ. Surgical treatment of metastatic melanoma confined to the liver. *Int Surg.* 1983;68:145-148.
27. Ekberg H, Tranberg K-G, Andersson R, Jeppsson B, Bengmark S. Major liver resection: perioperative course and management. *Surgery.* 1986;100:1-7.
28. Olak J, Wexler MJ, Rodriguez J, McLean AP. Hepatic resection for metastatic disease. *Can J Surg.* 1986;29:435-439.
29. Stehlin JS, de Ipolyi PD, Greeff PJ, McGaff CJ, Davis BR, McNary L. Treatment of cancer of the liver: twenty years' experience with infusion and resection in 414 patients. *Ann Surg.* 1988;208:23-35.
30. Foster JH. Survival after liver resection for secondary tumors. *Am J Surg.* 1978;135:389-394.
31. Mondragon-Sanchez R, Barrera-Franco JL, Cordoba-Gutierrez H, Meneses-Garcia A. Repeat hepatic resection for recurrent metastatic melanoma. *Hepato-gastroenterol.* 1999;46:459-461.
32. Fong Y, Blumgart LH, Cohen A, Fortner J, Brennan MF. Repeat hepatic resections for metastatic colorectal cancer. *Ann Surg.* 1994;220:657-662.

### Invited Critique

This article is clearly and carefully presented in exquisite detail. The authors have succinctly shown that there are occasional patients who benefit from an aggressive approach to stage IV melanoma owing to metastatic disease isolated to the liver. This article must be carefully read to understand how meticulously these patients were selected. Although 5-year disease-free survival and overall survival was 12% and 29% in the group undergoing resection, this represents only 0.3% of the 1750 patients who were evaluated and found to have hepatic metastasis and 18% of those going through a rigorous screening process and thought to be potential resection candidates. It is also important at this time, when the technical capability of performing percutaneous liver ablation exists, to note that 30% of patients were excluded by findings noted only at the time of laparotomy.

The authors are to be commended for their careful approach to a disease with a generally dismal outcome and, by so doing, insuring long-term survival for a few highly selected patients. With outcomes this poor, minimization of complications is imperative. In that sense, procedures that lessen the risk of surgery, such as limited segmental resections or radio-frequency destruction, would seem to be optimal techniques applicable in many patients. Unfortunately, many of our surgical and radiology colleagues will view the results of this study without appreciating the thoughtful evaluation, extensive imaging, and cautious approach that led to these singular results.

Fewer than 0.5% of patients with stage IV melanoma involving the liver will be long-term survivors, and application of surgery or interstitial destruction, by whatever means, must be conducted only after careful staging, with a view toward the minimization of risk and a sober understanding by all concerned that patients in this situation face very high odds against long-term survival.

*Philip D. Schneider, MD, PhD  
Sacramento, Calif*