ORIGINAL ARTICLE

Partial Recovery of Peristalsis After Myotomy for Achalasia

More the Rule Than the Exception

Sabine Roman, MD, PhD; Peter J. Kahrilas, MD; François Mion, MD, PhD; Thomas B. Nealis, MD; Nathaniel J. Soper, MD; Gilles Poncet, MD, PhD; Frédéric Nicodème, MD; Eric Hungness, MD; John E. Pandolfino, MD

Importance: Although successful treatment of achalasia depends on alleviating the obstruction at the esophagogastric junction, the postintervention contractile and pressurization pattern may also play a role in outcome.

Objective: To determine whether myotomy that alleviates the esophagogastric junction outflow obstruction in achalasia might improve peristalsis.

Design: Retrospective study from August 1, 2004, through January 30, 2012.

Setting: Two tertiary care hospitals in Chicago and Lyon.

Patients: We included 30 patients (18 male; mean age [range], 43 [17-78] years), of whom 8 had type 1 (26.6%), 17 had type 2 (56.7%), and 5 (16.7%) had type 3 achalasia according to the Chicago classification.

Interventions: Esophageal high-resolution manometry before and after laparoscopic or endoscopic myotomy.

Main Outcomes Measure: The integrity of peristalsis, characterized as intact, weak contractions; frequent failed peristalsis; or premature contractions.

Results: Although peristaltic fragments were evident only in patients with type 3 achalasia before treatment, intact, weak, or frequent failed peristalsis was encountered in 5 patients with type 1 (63%), 8 with type 2 (47%), and 4 with type 3 (80%) achalasia after myotomy. One patient with type 3 achalasia had distal esophageal spasm after treatment. In patients with a postmyotomy integrated relaxation pressure of less than 15 mm Hg, only 10 (40%) had persistent absent peristalsis. Panesophageal pressurization disappeared after myotomy in 16 of 19 patients. In the 5 patients with postmyotomy integrated relaxation pressure of more than 15 mm Hg, 4 had weak peristalsis and 1 had absent peristalsis.

Conclusions and Relevance: Reduction or normalization of the esophagogastric junction relaxation pressure achieved by myotomy in achalasia is associated with partial recovery of peristalsis in some patients, suggesting that the disease process progresses from the esophagogastric junction to the esophageal body. Whether the return of peristalsis is predictive of an improved therapeutic outcome requires further study.

JAMA Surg. 2013;148(2):157-164

Author Affiliations: Departments of Digestive Physiology (Drs Roman and Mion) and Surgery (Dr Poncet), Edouard Herriot Hospital, Hospices Civils de Lyon, Lyon I University, Lyon, France; and Departments of Gastroenterology (Drs Kahrilas, Nealis, Nicodème, and Pandolfino) and Surgery (Drs Soper and Hungness), Northwestern University, Chicago, Illinois.

Achalasia is characterized by impaired esophagogastric junction (EGJ) relaxation, absence of normally propagated peristaltic contractions, and absence of a structural explanation for these abnormalities.[1] The pathogenesis of achalasia involves inflammation and dysfunction of the myenteric plexus within the lower esophageal sphincter (LES) and esophagus, particularly among postganglionic inhibitory neurons.[2] This reduction in inhibition is responsible for impaired LES relaxation and may contribute to the peristaltic abnormalities also seen with this disorder.

Esophageal manometry is essential for the diagnosis of achalasia, with the hallmark features being impaired deglutitive LES relaxation and the absence of normal peristalsis. The introduction of high-resolution manometry (HRM) with esophageal pressure topography (EPT) has improved the sensitivity for diagnosis of achalasia by improving the accuracy of measurement and reducing confounding recording artifacts, particularly esophageal shortening and pseudorelaxation.[3] Moreover, owing to EPT, we know that the defining criterion of absent normal peristalsis need not equate to the absence of pressurization in the esophagus. Rather, 3 clinically relevant subtypes of achalasia

See Invited Critique at end of article

©2013 American Medical Association. All rights reserved.

Downloaded From: http://archsurg.jamanetwork.com/ on 10/13/2015

Table 1. Patient Characteristics

Characteristic	Data[a]
Age, mean (range), y	43 (17-78)
Sex, No. male/female	18/12
Baseline symptoms	
Dysphagia	29 (97)
Chest pain	9 (30)
Regurgitation	12 (40)
Achalasia subtypes	
Type 1	8 (27)
Type 2	17 (57)
Type 3	5 (17)
Radiographic stage of esophagus[b]	
Nondilated	9 (41)
Dilated	13 (59)
Sigmoid	0
Treatment	
Laparoscopic Heller myotomy with fundoplication	16 (53)
Laparoscopic Heller myotomy without fundoplication	9 (30)
Peroral endoscopic myotomy	5 (17)

[a] Unless otherwise indicated, data are expressed as number (percentage) of patients. Percentages have been rounded and might not total 100.
[b] Results were available in 22 patients.

were recognized from the pattern of esophageal contractility and pressurization associated with impaired deglutitive EGJ relaxation.[4] Type 1 is characterized by the absence of contractile activity and pressurization; type 2, by panesophageal pressurization; and type 3, by premature contractions. Logistic regression analysis found that type 2 was associated with a good treatment response, whereas type 3 was predictive of a relatively poor treatment response. These findings have been subsequently confirmed by other investigators.[5,6]

Because no treatment can restore normal function of the myenteric plexus, achalasia treatment aims to relieve dysphagia by alleviating EGJ obstruction.[7] Surgically, this goal can be achieved by laparoscopic myotomy or, more recently, by peroral endoscopic myotomy with promising results.[8,9] Although myotomy is intended to eliminate EGJ outflow obstruction, its effect on distal esophageal contractility is less defined. Older literature suggests that peristalsis may return in some cases after achalasia treatment.[10-12] For instance, Parrilla et al[10] reported the return of peristalsis in the midesophagus in 24% and in the distal esophagus in 9% of patients after myotomy, especially with a more acute onset of dysphagia, less preoperative esophageal dilatation, and more contractility of the esophageal body. However, this issue has always been controversial. Patti et al[11] reported no relationship between the return of peristalsis and the timing of surgery. Moreover, this issue has not been addressed with respect to EPT and achalasia subtypes. Certainly, one would anticipate that reducing EGJ outflow obstruction markedly by means of myotomy would modify achalasia subtyping in some cases and result in patients no longer meeting diagnostic criteria for achalasia in others. The demonstration of type 2 achalasia, for instance, depends on the existence of an EGJ outflow resistance of at least 30 mm Hg, a condition that should not often occur after myotomy. Hence, the aim of this study was to characterize postmyotomy esophageal contractility in patients with achalasia grouped according to their pretreatment achalasia subtype.

METHODS

PATIENTS

We identified 30 patients with idiopathic achalasia who underwent HRM studies before and after myotomy from a consecutive series of clinical EPT studies conducted from August 1, 2004, through January 30, 2012, at 2 tertiary care centers (Northwestern University, Chicago, and Edouard Herriot Hospital, Lyon). We included 20 patients from Chicago and 10 from Lyon. None of the patients had received any endoscopic or surgical treatment for achalasia before the first HRM. Patients were treated with Heller myotomy with or without fundoplication or peroral endoscopic myotomy. Patient characteristics at baseline are summarized in **Table 1**. A second HRM study was performed with a median delay of 2.4 (range, 1-32) months after myotomy. We performed a retrospective review of the EPT studies and patients' medical records.

The study protocol for the retrospective analysis of EPT findings was approved by the Northwestern University institutional review board (obtained by J.E.P.). No ethical committee approval was required in France.

EPT PROTOCOL

The EPT studies were performed with a solid-state assembly (outer diameter, 4.2 mm) with 36 circumferential sensors spaced at 1-cm intervals (Given Imaging). Before recording, transducers were calibrated at 0 and 300 mm Hg using externally applied pressure. Studies were performed with the patient in a supine position after at least a 6-hour fast. The manometry catheter was placed transnasally and positioned to record from the hypopharynx to the stomach with approximately 3 intragastric sensors. The catheter was fixed in place by taping it to the nose. The manometry protocol included at least a 30-second assessment of basal sphincter pressure and ten 5-mL water swallows.

EPT ANALYSIS

We analyzed the EPT studies using commercially available software (ManoView; Given Imaging) before and after myotomy. The EGJ pressures were analyzed during the resting period without swallowing for mean and expiratory pressure. Esophagogastric junction relaxation pressure was evaluated using the integrated relaxation pressure (IRP)[13] and nadir pressure. The IRP quantifies EGJ relaxation in completeness and persistence, reporting the mean EGJ pressure for the 4 seconds of most complete relaxation in the 10-second window after swallowing. The upper limit of the reference range for the IRP with this instrumentation is less than 15 mm Hg.[13]

Peristalsis distal to the transition zone was characterized by the integrity of the 20–mm Hg isobaric contour.[14] In premyotomy studies, peristalsis was considered to have failed if minimal (<3 cm) or absent 20–mm Hg isobaric contour integrity was found. In instances when esophageal contractile activity was present distal to the transition zone, distal latency was measured from the upper esophageal sphincter relaxation to the contractile deceleration point, demarcating the onset of contraction just proximal to the sphincter.[15,16] Panesophageal pressurization was defined as uniform 30–mm Hg pressurization extending from the upper esophageal sphincter to the EGJ.[17] Type 1 (classic) achalasia was defined by a mean IRP of greater

©2013 American Medical Association. All rights reserved.
Downloaded From: http://archsurg.jamanetwork.com/ on 10/13/2015

Table 2. Pretreatment and Posttreatment Characterization of EGJ[a]

	Pretreatment, mm Hg	Posttreatment, mm Hg	Decrease, %	*P* Value[b]
Resting pressure, expiratory	24 (18-31)	9 (5-12)	66 (47-77)	<.001
Mean resting pressure	40 (28-48)	18 (11-24)	55 (27-70)	<.001
IRP	25 (20-31)	9 (7-14)	60 (37-70)	<.001
Nadir relaxation pressure	19 (13-26)	7 (3-11)	63 (39-85)	<.001

Abbreviations: EGJ, esophagogastric junction; IRP, integrated relaxation pressure.
[a] Unless otherwise indicated, data are expressed as median (25th-75th percentile).
[b] Calculated by means of the paired *t* test.

than 15 mm Hg and 100% failed peristalsis; type 2 (achalasia with compression), a mean IRP of greater than 15 mm Hg, no normal peristalsis, and panesophageal pressurization with at least 20% of swallows; and type 3, a mean IRP of greater than 15 mm Hg, no normal peristalsis, and rapid or premature (spastic) contractions with at least 20% of swallows.[4] Although a mean IRP of less than 15 mm Hg was the threshold for diagnosis, achalasia was diagnosed with an IRP of less than 15 mm Hg if other investigative findings (barium swallow and endoscopy) were consistent with achalasia.

In postmyotomy studies, distal esophageal contractile activity was assessed similarly according to the integrity of the 20–mm Hg isobaric contour. Peristalsis was characterized as absent with less than 3 cm of integrity, as having a large defect if a break of greater than 5 cm was found in the 20–mm Hg isobaric contour, as having a small defect if a break of greater than 2 cm but less than 5 cm was found, and as intact if no break or a break of less than 2 cm was found. When contractile activity was present, the distal contractile integral[18] and contractile front velocity[16] were measured. The distal contractile integral summarizes the contractile vigor of the distal esophagus and is calculated as the product of the mean amplitude (>20 mm Hg) and the area of a box drawn to contain the distal contraction, expressed as millimeters of mercury times seconds times centimeter.[19] The contractile front velocity, the velocity at which the contraction progresses in the distal esophagus, was estimated as the slope of a tangent drawn to skirt the contractile segment between the transition zone and the contractile deceleration point.[16] The criterion for panesophageal pressurization was that it be present in at least 20% of swallows. Finally, the Chicago classification was applied to the postmyotomy EPT findings.[17]

CLINICAL DATA AND MYOTOMY

Preoperative symptoms were collected by the surgeons during the preoperative visit. Preoperative barium esophagrams were available for 22 patients and graded as a nondilated, dilated, or sigmoid esophagus.

Heller myotomy was performed laparoscopically in 24 patients and as an open procedure in 1 patient who had undergone previous abdominal surgery. Partial fundoplication (Dor or Toupet) was coupled with the myotomy in 16 patients (15 from Chicago and 1 from Lyon), whereas no fundoplication was performed in 9 patients from Lyon. Peroral endoscopic myotomy was performed in 5 patients from Chicago.

STATISTICAL ANALYSIS

Data are expressed as median (interquartile range) unless otherwise specified. We compared premyotomy and postmyotomy data using the paired *t* test. Categorical data among groups were compared using the χ^2 test, and continuous data were compared using the Mann-Whitney or the Kruskal-Wallis test. A *P* value of less than .05 was considered significant.

RESULTS

EGJ CHARACTERIZATION

Premyotomy and postmyotomy EGJ pressures are shown in **Table 2**. At baseline, the resting expiratory EGJ pressure was greater in the Chicago patients (29 [23-33] vs 20 [15-22] mm Hg; *P* = .02), whereas the other EGJ pressure metrics, including IRP and nadir pressures, were similar between the 2 centers. At baseline, the IRP was elevated (>15 mm Hg) in all but 4 patients (2 with type 1, 1 with type 2, and 1 with type 3 achalasia).

After myotomy, the resting expiratory EGJ pressure decreased in all patients, whereas the mean resting EGJ pressure increased by 18% and 16% in 2 patients with type 2 achalasia whose Heller myotomy was associated with a fundoplication. Postmyotomy IRP was less than 15 mm Hg in all but 5 patients. The IRP and nadir EGJ relaxation pressure decreased after myotomy in all patients. The decrease of EGJ pressures (resting or relaxation) did not differ significantly among achalasia subtypes and treatment modalities (*P* > .05, Kruskal Wallis test).

ESOPHAGEAL CONTRACTILITY

Before myotomy, esophageal contractility was present in the distal two-thirds of the esophagus only in the 5 patients with type 3 achalasia. In 3 of these patients, this contractile activity exhibited a reduced distal latency (<4.5 seconds); in the other 2, the latency could not be measured because the contraction did not extend to the most distal esophagus.

After myotomy, esophageal contractile activity was observed in the distal two-thirds of the esophagus in 17 patients (57%), including 5 with type 1 (63%), 8 with type 2 (47%), and 4 with type 3 (80%) achalasia. **Figure 1** illustrates examples of premyotomy and postmyotomy EPT studies of one patient with type 2 achalasia and another with type 3 achalasia. Examples of different patterns of postoperative contractile activity are illustrated in Figure 1 and **Figure 2**. In the context of Chicago classification terms, these contractile patterns included failed peristalsis, weak contractions with large breaks in the 20–mm Hg isobaric contour, and premature contractions. The median failed peristalsis per subject was 65% (interquartile range, 0%-100%) and the median for swallows with weak contractions and large breaks in the 20–mm Hg iso-

©2013 American Medical Association. All rights reserved.
Downloaded From: http://archsurg.jamanetwork.com/ on 10/13/2015

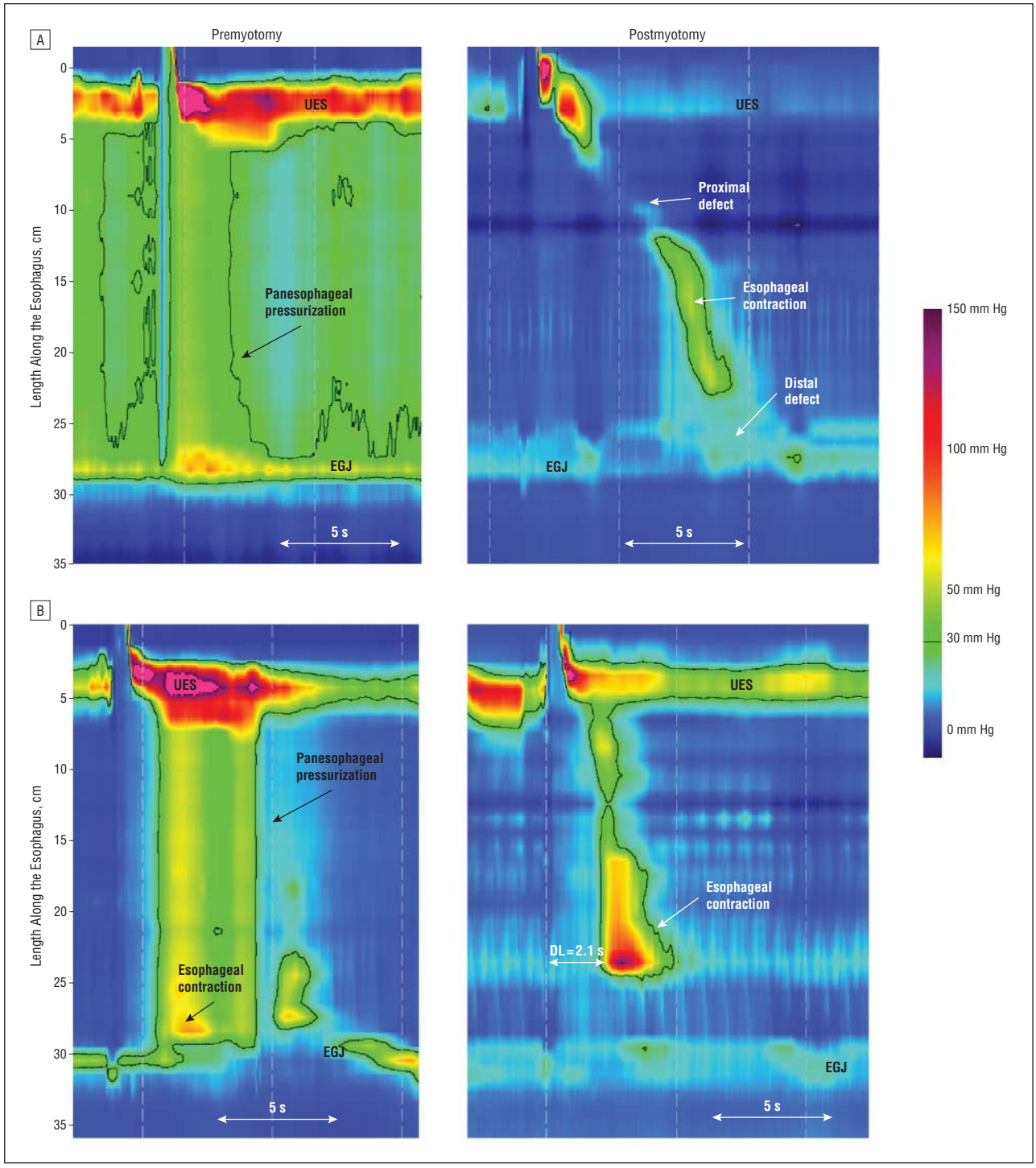

Figure 1. Esophageal pressure topography studies before (left) and after (right) myotomy. A, Patient with type 2 achalasia. B, Patient with type 3 achalasia. Pressures are recorded along the esophagus from the upper esophageal sphincter (UES) to the esophagogastric junction (EGJ). Horizontal arrows represent the time elapsed. Pressure amplitudes are coded by color as scaled on the right. The patient with type 2 achalasia was characterized by impaired EGJ relaxation (mean integrated relaxation pressure [IRP], 45 mm Hg) and panesophageal pressurization. After peroral endoscopic myotomy, he had some instances of weak peristalsis characterized by proximal and distal defects in the contraction front. His postmyotomy EGJ pressure was extremely low. The patient with type 3 achalasia was characterized by impaired EGJ relaxation (mean IRP, 30 mm Hg) and premature contraction (distal latency [DL], <4.5 seconds). After myotomy, the EGJ pressure significantly decreased but premature contractions persisted (DL, <4.5 seconds).

baric contour was 5% (0%-73%). Breaks were predominantly localized in the distal esophagus, likely reflecting the proximal extent of the myotomy on the distal esophagus. Two patients had premature contractions: one with type 1 achalasia treated with Heller and fundoplication exhibited a single premature contraction, and the other had premature contractions with 50% of test swallows (type 3 achalasia treated with a Heller myotomy and fundoplication). When a postmyotomy contraction was present, the average distal contractile integral velocity per

©2013 American Medical Association. All rights reserved.
Downloaded From: http://archsurg.jamanetwork.com/ on 10/13/2015

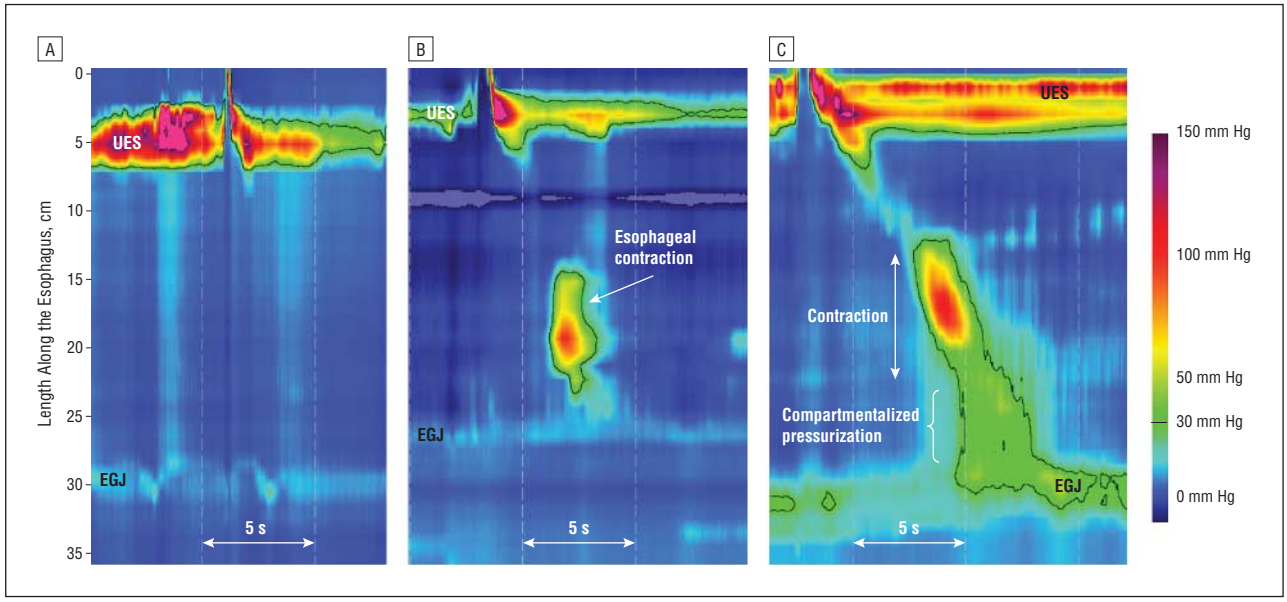

Figure 2. Patterns of postmyotomy contractility. A, Failed peristalsis in a patient with type 2 achalasia treated with Heller myotomy without fundoplication. B, Weak contraction with a large break in the 20–mm Hg isobaric contour in a patient with type 2 achalasia treated with Heller myotomy with Toupet fundoplication. The contraction had proximal and distal defects. In both patients, the pressure at the level of the esophagogastric junction (EGJ) is very low and no high-pressure zone was identified. C, Compartmentalized esophageal pressurization in a patient with type 2 achalasia treated with Heller myotomy and Dor fundoplication. The postoperative mean integrated relaxation pressure was 17 mm Hg, thereby meeting the criterion for EGJ outflow obstruction. A weak contraction with a large break in the 20–mm Hg isobaric contour was also noted. UES indicates upper esophageal sphincter. Horizontal arrows represent the time elapsed.

patient was 309 (200-487) mm Hg × s × cm. Having a dilated esophagus on the preoperative esophagram was not predictive of postmyotomy absent peristalsis (3 of 9 patients with nondilated esophagus [33%] vs 5 of 13 with dilated esophagus [38%] had absent peristalsis; $P = .58$).

PANESOPHAGEAL PRESSURIZATION

Before treatment, panesophageal pressurization was observed in all patients with type 2 achalasia and concurrently with the defining contractile activity in 2 patients with type 3 achalasia. After treatment, only 3 patients exhibited panesophageal pressurization. One patient treated with Heller myotomy without fundoplication exhibited panesophageal pressurization with 50% of swallows before and after myotomy. He had a postmyotomy IRP of 7.5 mm Hg, 40% of swallows with weak contractions (large breaks), 40% failed peristalsis, and 20% weak contractions with small breaks. The second patient, treated with Heller myotomy with fundoplication, had 90% of swallows with panesophageal pressurization after treatment vs 100% before. The postmyotomy IRP was 16.3 mm Hg, and 100% of swallows were associated with weak contractions (large breaks). The third patient, treated with a Heller myotomy without fundoplication, had 30% of swallows with panesophageal pressurization after treatment vs 100% before myotomy, a postmyotomy IRP of 18.8 mm Hg, 50% of swallows with weak contractions (large breaks), and 50% with failed peristalsis. With the caveat that only 3 patients had postmyotomy panesophageal pressurization, posttreatment mean EGJ pressure was greater in patients with persistent panesophageal pressurization than in patients without (median, 28 vs 17; $P = .02$). Expiratory EGJ pressure, IRP, and nadir EGJ relaxation pressure were not different in patients with or without panesophageal pressurization. The presence of a fundoplication did not influence the occurrence of panesophageal pressurization. Finally, none of the patients without panesophageal pressurization before treatment had panesophageal pressurization after myotomy.

CLASSIFICATION OF POSTMYOTOMY ESOPHAGEAL MOTILITY

Postmyotomy motility was typed according to the Chicago classification.[17] If the postmyotomy IRP was greater than 15 mm Hg, patients were classified as having an achalasia subtype or EGJ outflow obstruction pattern. The patients with IRP of less than 15 mm Hg but panesophageal pressurization were classified as having EGJ outflow obstruction. The distribution of postmyotomy esophageal motility is shown in **Table 3**. The pattern of postmyotomy motility disorders was not associated with a specific modality of treatment as evidenced in **Table 4**.

COMMENT

The aim of this study was to characterize the effect of surgical or endoscopic myotomy on the esophageal contractility of achalasia patients who had undergone subtyping before treatment according to the Chicago classification. More than half the 30 patients undergoing analysis exhibited some intact peristaltic contractions or some remnants of distal esophageal peristalsis in their posttreatment EPT study. Whether these findings resulted in their posttreatment classification as having frequent failed peristalsis or weak peristalsis rather

©2013 American Medical Association. All rights reserved.
Downloaded From: http://archsurg.jamanetwork.com/ on 10/13/2015

Table 3. Posttreatment Motility According to Pretreatment Achalasia Subtype[a]

Motility	Achalasia Subtype, No. of Patients		
	Type 1	Type 2	Type 3
EGJ outflow obstruction	1	2	2
Type 1 achalasia	0	1	0
Premature contraction	0	0	1
Frequent failed peristalsis	2	1	0
Weak peristalsis	2	5	1
Absent peristalsis	3	8	1

Abbreviation: EGJ, esophagogastric junction.
[a] Absent peristalsis was the most frequent pattern observed in patients with type 2 achalasia before myotomy, whereas weak or frequent failed peristalsis was more frequently observed in type 1 patients. All but 1 patient with pretreatment type 3 achalasia had persistent contractile activity after myotomy.

Table 4. Posttreatment Motility According to Treatment Modality[a]

Motility	Treatment Modality, No. of Patients		
	Heller Myotomy With Fundoplication	Heller Myotomy Without Fundoplication	Peroral Endoscopic Myotomy
EGJ outflow obstruction	2	2	1
Type 1 achalasia	1	0	0
Premature contraction	1	0	0
Frequent failed peristalsis	1	0	2
Weak peristalsis	5	2	1
Absent peristalsis	6	5	1

Abbreviation: EGJ, esophagogastric junction.
[a] All patterns of contractile activity were observed with each treatment modality.

than EGJ outflow obstruction depended on how effectively the EGJ was obliterated by the myotomy. These findings suggest that EGJ outflow obstruction might play a role in occurrence of failed peristalsis in some achalasia patients.

Recovery of esophageal peristalsis after relieving EGJ obstruction provides an interesting perspective on achalasia pathogenesis. Degeneration of the myenteric plexus is a pathological feature of achalasia.[20] This degeneration involves neurons localized at the LES and in the smooth-muscle esophagus. However, the pattern and intensity of inflammation are variable, and the observation of functional recovery in the distal esophagus after myotomy suggests that neuronal dysfunction limited to the LES might dominate in some achalasia patients. Short-segment achalasia had been reported before the advent of HRM with EPT,[21] but findings from the present study suggest that this condition might be more common than previously recognized. In these cases, the absent peristalsis observed before myotomy would be a consequence of EGJ obstruction. This phenomenon has been demonstrated by Mittal et al[22] in an animal model by placing calibrated ligatures around the LES of cats, causing failed peristalsis with increasing degrees of outflow obstruction. In another cat model, Schneider et al[23] observed a prompt return of peristalsis after ligature removal. In humans, laparoscopic placement of an adjustable gastric band might represent an analogous model of EGJ obstruction. Manometric features of achalasia have been observed in patients after implanting this device, and normal peristalsis has been restored in some cases after band deflation or removal,[24,25] making another argument for the reversible effect of EGJ obstruction on esophageal peristalsis.

The persistence of absent peristalsis rather than partial recovery might indicate progressive stages of the disease process of achalasia. Supportive evidence for this hypothesis can be found in a pathological study by Goldblum et al.[20] In what is still the most definitive analysis of achalasia neuropathology, those investigators reported that, with vigorous achalasia (preserved esophageal contractility), myenteric inflammation was associated with a normal number of ganglion cells without neural fibrosis. On the other hand, patients with classic achalasia had few or no ganglion cells with neural fibrosis. They concluded that inflammation was an early change in the evolution of the disease, eventually followed by the loss of ganglion cells and neural fibrosis. Within this construct, recovery of peristalsis after myotomy might indicate myenteric plexus inflammation in the distal esophagus, whereas persistent absent peristalsis might be observed in patients who had progressed toward or achieved aganglionosis. In support of this hypothesis, although demonstrable, postmyotomy peristalsis was usually characterized as weak with large breaks in the 20–mm Hg isobaric contour and a low distal contractile integral.

The pretreatment achalasia subtype also had some bearing on the observed pattern of postmyotomy contractility. All but 1 of the patients with type 3 achalasia exhibited some intact peristalsis or premature contractions after myotomy. On the other hand, only 3 of 17 patients with type 2 and 3 of 8 with type 1 achalasia exhibited any posttreatment intact peristalsis. Although the numbers are small, these observations suggest that the patients with type 3 achalasia have a different pattern of neuropathology that is more limited to the LES and leading to some intact peristalsis after myotomy or is more specifically selectively targeting inhibitory ganglionic neurons and leading to distal esophageal spasm after myotomy.

Another consequence of myotomy was the complete disappearance of the type 2 pattern of achalasia. Panesophageal pressurization, the hallmark feature of type 2 achalasia, occurs secondary to contraction of the muscularis propria longitudinal muscle[26] in association with EGJ outflow obstruction leading to substantial intrabolus pressure spanning from the upper esophageal sphincter to the LES. A similar pattern of contraction may persist after myotomy but, if so, this pattern would be associated with the requisite 30–mm Hg intrabolus pressure in rare instances to qualify as panesophageal pressurization in the Chicago classification because of the decreased EGJ pressure. Ascertaining whether that is the case and whether patients with types 1 and 3 achalasia exhibit a similar motor pattern would require further investigation.

This study has some important limitations. Owing to its retrospective design, we could not determine whether

©2013 American Medical Association. All rights reserved.
Downloaded From: http://archsurg.jamanetwork.com/ on 10/13/2015

recovery of peristalsis was associated with an improved symptomatic outcome because no systematic preoperative and postoperative symptom evaluations were performed. A study using impedance manometry showed that patients with some restoration of peristalsis after myotomy exhibited improved bolus clearance, suggesting that symptoms might have improved.[27] Future studies are planned to address this issue. Finally, we did not observe an influence of preoperative esophageal dilatation or of surgical procedure on the return of esophageal contractile activity. However, the numbers of patients in each group were small; these findings will need to be reassessed in a larger series.

CONCLUSIONS

This study demonstrated that some degree of peristaltic contraction, not manometrically evident before myotomy, was frequently demonstrable in postmyotomy achalasia. The degree to which this condition is observed might reflect unique pathogenetic features, especially in type 3 achalasia, or might reflect the extent to which the neurodegenerative process has progressed. Alternatively, in some patients, the disease process may uniquely target the LES such that recovery of peristalsis is a consequence of relieving the outflow obstruction. Whether partial or complete recovery of peristalsis is associated with an improved therapeutic outcome will require further research using a prospective study design with systematic symptom evaluation using disease-specific validated instruments, and that remains to be accomplished.

Accepted for Publication: July 25, 2012.
Correspondence: Sabine Roman, MD, PhD, Department of Digestive Physiology, Edouard Herriot Hospital, Pavillon H, 5 place d'Arsonval, 69437 Lyon, CEDEX 03, France (roman.sabine@gmail.com).
Author Contributions: *Study concept and design:* Roman, Kahrilas, Mion, and Pandolfino. *Acquisition of data:* Roman, Kahrilas, Mion, Nealis, Soper, Poncet, and Nicodème. *Analysis and interpretation of data:* Roman, Kahrilas, Mion, Nealis, Poncet, Hungness, and Pandolfino. *Drafting of the manuscript:* Roman, Kahrilas, and Mion. *Critical revision of the manuscript for important intellectual content*: Roman, Kahrilas, Mion, Nealis, Soper, Poncet, Nicodème, Hungness, and Pandolfino. *Statistical analysis:* Roman and Hungness. *Obtained funding:* Kahrilas. *Administrative, technical, and material support:* Kahrilas, Mion, Soper, and Nicodème. *Study supervision:* Kahrilas, Mion, and Pandolfino.
Conflict of Interest Disclosures: Drs Roman and Pandolfino report having served as consultants for Given Imaging.
Funding/Support: This study was supported by grants R01 DK56033 (Dr Kahrilas) and R01 DK079902 (Dr Pandolfino) from the National Institutes of Health.
Previous Presentations: This paper was presented in part as a poster at Digestive Disease Week; May 19, 2012; San Diego, California.

REFERENCES

1. Pandolfino JE, Kahrilas PJ; American Gastroenterological Association. AGA technical review on the clinical use of esophageal manometry. *Gastroenterology*. 2005; 128(1):209-224.
2. Gockel I, Bohl JR, Eckardt VF, Junginger T. Reduction of interstitial cells of Cajal (ICC) associated with neuronal nitric oxide synthase (n-NOS) in patients with achalasia. *Am J Gastroenterol*. 2008;103(4):856-864.
3. Clouse RE, Staiano A, Alrakawi A, Haroian L. Application of topographical methods to clinical esophageal manometry. *Am J Gastroenterol*. 2000;95(10):2720-2730.
4. Pandolfino JE, Kwiatek MA, Nealis T, Bulsiewicz W, Post J, Kahrilas PJ. Achalasia: a new clinically relevant classification by high-resolution manometry. *Gastroenterology*. 2008;135(5):1526-1533.
5. Pratap N, Kalapala R, Darisetty S, et al. Achalasia cardia subtyping by high-resolution manometry predicts the therapeutic outcome of pneumatic balloon dilatation. *J Neurogastroenterol Motil*. 2011;17(1):48-53.
6. Salvador R, Costantini M, Zaninotto G, et al. The preoperative manometric pattern predicts the outcome of surgical treatment for esophageal achalasia. *J Gastrointest Surg*. 2010;14(11):1635-1645.
7. Boeckxstaens GE, Annese V, des Varannes SB, et al; European Achalasia Trial Investigators. Pneumatic dilation versus laparoscopic Heller's myotomy for idiopathic achalasia. *N Engl J Med*. 2011;364(19):1807-1816.
8. Inoue H, Minami H, Kobayashi Y, et al. Peroral endoscopic myotomy (POEM) for esophageal achalasia. *Endoscopy*. 2010;42(4):265-271.
9. von Renteln D, Inoue H, Minami H, et al. Peroral endoscopic myotomy for the treatment of achalasia: a prospective single center study. *Am J Gastroenterol*. 2012;107(3):411-417.
10. Parrilla P, Martinez de Haro LF, Ortiz A, Morales G, Garay V, Aguilar J. Factors involved in the return of peristalsis in patients with achalasia of the cardia after Heller's myotomy. *Am J Gastroenterol*. 1995;90(5):713-717.
11. Patti MG, Galvani C, Gorodner MV, Tedesco P. Timing of surgical intervention does not influence return of esophageal peristalsis or outcome for patients with achalasia. *Surg Endosc*. 2005;19(9):1188-1192.
12. Zaninotto G, Costantini M, Anselmino M, Boccù C, Ancona E. Onset of oesophageal peristalsis after surgery for idiopathic achalasia. *Br J Surg*. 1995;82(11): 1532-1534.
13. Ghosh SK, Pandolfino JE, Rice J, Clarke JO, Kwiatek M, Kahrilas PJ. Impaired deglutitive EGJ relaxation in clinical esophageal manometry: a quantitative analysis of 400 patients and 75 controls. *Am J Physiol Gastrointest Liver Physiol*. 2007; 293(4):G878-G885.
14. Roman S, Lin Z, Kwiatek MA, Pandolfino JE, Kahrilas PJ. Weak peristalsis in esophageal pressure topography: classification and association with dysphagia. *Am J Gastroenterol*. 2011;106(2):349-356.
15. Roman S, Lin Z, Pandolfino JE, Kahrilas PJ. Distal contraction latency: a measure of propagation velocity optimized for esophageal pressure topography studies. *Am J Gastroenterol*. 2011;106(3):443-451.
16. Pandolfino JE, Leslie E, Luger D, Mitchell B, Kwiatek MA, Kahrilas PJ. The contractile deceleration point: an important physiologic landmark on oesophageal pressure topography. *Neurogastroenterol Motil*. 2010;22(4):395-400, e90. doi: 10.1111/j.1365-2982.2009.01443.x.
17. Bredenoord AJ, Fox M, Kahrilas PJ, Pandolfino JE, Schwizer W, Smout AJ; International High Resolution Manometry Working Group. Chicago classification criteria of esophageal motility disorders defined in high resolution esophageal pressure topography. *Neurogastroenterol Motil*. 2012;24(suppl 1):57-65.
18. Pandolfino JE, Fox MR, Bredenoord AJ, Kahrilas PJ. High-resolution manometry in clinical practice: utilizing pressure topography to classify oesophageal motility abnormalities. *Neurogastroenterol Motil*. 2009;21(8):796-806.
19. Ghosh SK, Pandolfino JE, Zhang Q, Jarosz A, Shah N, Kahrilas PJ. Quantifying esophageal peristalsis with high-resolution manometry: a study of 75 asymptomatic volunteers. *Am J Physiol Gastrointest Liver Physiol*. 2006;290(5):G988-G997.
20. Goldblum JR, Rice TW, Richter JE. Histopathologic features in esophagomyotomy specimens from patients with achalasia. *Gastroenterology*. 1996;111 (3):648-654.
21. Hirano I, Tatum RP, Shi G, Sang Q, Joehl RJ, Kahrilas PJ. Manometric heterogeneity in patients with idiopathic achalasia. *Gastroenterology*. 2001;120(4): 789-798.
22. Mittal RK, Ren J, McCallum RW, Shaffer HA Jr, Sluss J. Modulation of feline esophageal contractions by bolus volume and outflow obstruction. *Am J Physiol*. 1990; 258(2, pt 1):G208-G215.
23. Schneider JH, Peters JH, Kirkman E, Bremner CG, DeMeester TR. Are the motility abnormalities of achalasia reversible? an experimental outflow obstruction in the feline model. *Surgery*. 1999;125(5):498-503.

©2013 American Medical Association. All rights reserved.
Downloaded From: http://archsurg.jamanetwork.com/ on 10/13/2015

24. Cruiziat C, Roman S, Robert M, et al. High resolution esophageal manometry evaluation in symptomatic patients after gastric banding for morbid obesity. *Dig Liver Dis.* 2011;43(2):116-120.
25. Khan A, Ren-Fielding C, Traube M. Potentially reversible pseudoachalasia after laparoscopic adjustable gastric banding. *J Clin Gastroenterol.* 2011;45(9):775-779.
26. Hong SJ, Bhargava V, Jiang Y, Denboer D, Mittal RK. A unique esophageal motor pattern that involves longitudinal muscles is responsible for emptying in achalasia esophagus. *Gastroenterology.* 2010;139(1):102-111.
27. Tatum RP, Wong JA, Figueredo EJ, Martin V, Oelschlager BK. Return of esophageal function after treatment for achalasia as determined by impedance-manometry. *J Gastrointest Surg.* 2007;11(11):1403-1409.

INVITED CRITIQUE

Partial Recovery of Peristalsis After Myotomy for Achalasia

Rethinking the Rule

In this study,[1] 30 patients with achalasia underwent evaluation with high-resolution manometry and esophageal pressure topography before and after myotomy. Myotomies were laparoscopic, open, or peroral endoscopic procedures in 24, 1, and 5 patients, respectively. Before treatment, patients were classified into 3 groups according to the Chicago classification. Type 1 elicited no peristalsis or pressurization (8 [27%]), type 2 elicited panesophageal pressurization only (17 [57%]), and type 3 showed premature contractions (5 [17%]). Only type 3 patients demonstrated peristalsis before treatment; however, after myotomy, peristaltic activity was noted in 63%, 47%, and 80% of types 1, 2, and 3 patients, respectively.

The authors make several observations that could challenge our thinking on achalasia dramatically. Historically, achalasia was characterized by absence of esophageal peristalsis and failure of the lower esophageal sphincter (LES) to relax. A second, less common, variant is vigorous achalasia with noncontractile, high-pressure waves and failure of LES relaxation. In both cases, the goal of treatment was to relieve the obstruction at the LES by myotomy. Pretreatment absent peristalsis was thought to be permanent. Poor posttreatment outcomes were blamed on inadequate myotomy. This study suggests (1) achalasia can be subclassified based on the presence and pattern of peristalsis and panesophageal pressurization; (2) absent peristalsis need not equate to absent esophageal pressure; (3) LES obstruction may contribute to loss of peristalsis but not be linked to it; and (4) myotomy results in return of peristalsis in most patients with types 1, 2, and 3 achalasia.

We do not know whether the different subtypes represent different time courses in the same disease process or distinct achalasia types. The findings were not correlated to clinical outcomes, and the series did not include patients with sigmoid esophagus. However, the stage is set for future studies to answer these questions.

Richard F. Heitmiller II, MD

Author Affiliations: Medstar Union Memorial Hospital, Baltimore, Maryland.
Correspondence: Dr Heitmiller, Medstar Union Memorial Hospital, Johnston Professional Building, Ste 610, 3333 N Calvert St, Baltimore, MD 21218 (richard.heitmiller@medstar.net).
Conflict of Interest Disclosures: None reported.

1. Roman S, Kahrilas PJ, Mion F, et al. Partial recovery of peristalsis after myotomy for achalasia: more the rule than the exception. *JAMA Surg.* 2013; 148(2):157-164.

©2013 American Medical Association. All rights reserved.
Downloaded From: http://archsurg.jamanetwork.com/ on 10/13/2015