Image of the Month

Harvey L. Bumpers, MD; Sheryl Gabram-Mendola, MD; Joel Okoli, MD; Monica Rizzo, MD

A 50-YEAR-OLD AFRICAN AMERICAN FEMALE patient presented to the emergency department with a complaint of severe shortness of breath and a swollen right hand. On admission, she was unable to walk. She gave no past medical history of diabetes mellitus or of treatments for other pathologies. A physical examination was significant for severe edema in the right upper extremity accompanied by excoriation and necrosis of the skin and soft tissue of the limb and the right chest wall. A chest radiograph showed a massive pleural effusion with near complete collapse of the right lung. A photograph of the patient (**Figure 1**) and a computed tomographic scan of the chest (**Figure 2**) are shown.

What Is the Diagnosis?

A. Caustic burn injury
B. Locally advanced breast cancer
C. Iatrogenic high-dose radiation injury
D. Necrotizing fasciitis

Author Affiliations: Department of Surgery, College of Human Medicine, Michigan State University, Lansing (Dr Bumpers); Department of Surgery, Emory University School of Medicine (Drs Gabram-Mendola and Rizzo), Department of Surgery, Morehouse School of Medicine (Dr Okoli), and Georgia Cancer Center for Excellence, Grady Hospital (Drs Gabram-Mendola, Okoli, and Rizzo), Atlanta.

Figure 1. Photograph of a 50-year-old African American female patient at initial presentation.

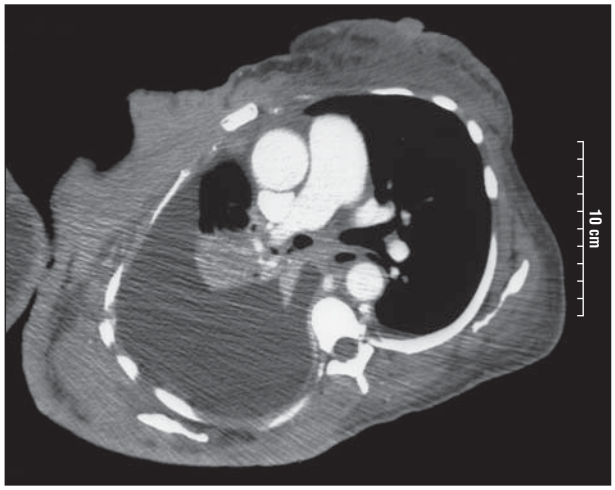

Figure 2. Computed tomographic scan of the chest of a 50-year-old African American female patient showing a massive pleural effusion with near complete collapse of the right lung.

©2013 American Medical Association. All rights reserved.

Downloaded From: http://archsurg.jamanetwork.com/ on 10/13/2015