ORIGINAL ARTICLE

Hydatid Disease of the Liver

A Continuing Surgical Problem

Michael C. Safioleas, MD, PhD; Evangelos P. Misiakos, MD; Maria Kouvaraki, MD; Michael K. Stamatakos, MD; Christine P. Manti, MD; Evangelos S. Felekouras, MD

Hypothesis: To study the results of different surgical strategies in the treatment of liver hydatid disease.

Design: A retrospective study of 287 patients.

Setting: A university hospital in Athens, Greece.

Patients: Two hundred eighty-seven patients with liver hydatid cysts treated surgically 1977-2004. The cysts were located in the right hepatic lobe in 192 cases, in the left lobe in 66 cases, and in both lobes in 29 cases. Eleven patients had concomitant cysts in other organs and 12 patients had multiple intra-abdominal cysts.

Results: All patients were treated surgically. Surgical procedures included external drainage, simple closure, marsupialization, partial cystectomy with omentoplasty, radical procedures, laparoscopic drainage, and radiofrequency ablation. The first 3 techniques carried a higher complication rate (36.5%) compared with the other techniques (17.85%; $P<.05$). However, omentoplasty and external drainage carried a higher recurrence rate (7.42% overall), as compared with radical procedures (3.22%).

Conclusion: Omentoplasty and radical procedures carry a lower complication rate compared with the formerly used marsupialization and external drainage. Conservative techniques, such as omentoplasty and/or other procedures, offer an effective control of hepatic hydatidosis and are preferred over radical procedures, when possible.

Arch Surg. 2006;141:1101-1108

Author Affiliations: 2nd Department of Propedeutic Surgery (Drs Safioleas, Kouvaraki, and Stamatakos); Apolloneion Medical Center (Dr Misiakos); Aglaia Kyriakou Children's Hospital, Department of Microbiology (Dr Manti); and the 1st Department of Surgery, University of Athens, School of Medicine, Athens, Greece (Dr Felekouras).

HYDATID DISEASE IS ENdemic mainly in the Mediterranean countries (particularly Greece), the Middle East, the Baltic areas, South America, India, northern China, and other sheep-raising areas[1,2]; however, owing to increased travel and tourism all over the world, it can be found anywhere, even in developed countries. Hydatid disease is a zoonotic infection caused by adult or larval stages of the cestode *Echinococcus granulosus*. Two types of *E granulosus* life cycle patterns have been described in Europe, Asia, and North America: domestic and sylvatic.[3,4] The former involves domestic ungulates, mainly sheep, as intermediate hosts and dogs as definitive hosts. The latter life cycle involves wolves, dogs, and cervids, such as moose and reindeer, and occurs in higher latitudes. However, in other endemic areas, such as Australia and New Zealand, there is an unusual cycle with wild dogs as the definitive host, and macropods (kangaroos and wallabies) and feral pigs as intermediate hosts.[5,6] The adult tapeworm grows in the small bowel of its definitive host, the dog, attached to the mucosa by hooklets. Humans become infected via ingestion of eggs as a result of direct contact with infected dogs that shed proglottids or through the ingestion of vegetables spoiled with dog feces containing eggs. When ingested, the eggs liberate their larvae in the duodenum of the intermediate host (sheep or human). The larvae cross the intestinal wall and via the portal system migrate to the liver, where they are transformed into cysts (**Figure 1**). Thus, the liver is the organ most frequently infected by this parasite (50%-90%).[2,7,8] Some larvae may pass through the liver and settle in the lungs and other organs (central nervous system, bones).

Once in the human liver, cysts grow as much as 1 cm during the first 6 months and 2 to 3 cm every year thereafter, depending on the host's physical resistance.[9,10] The liver cysts may be asymptomatic for years, and occasionally spontaneous regression has been noted. More commonly the disease is slowly progressive and symptoms as well as complications may arise.[7] Without treatment, the cysts grow and may form fistulas into adjacent organs or rupture into the

©2006 American Medical Association. All rights reserved.
Downloaded From: http://archsurg.jamanetwork.com/ on 11/29/2015

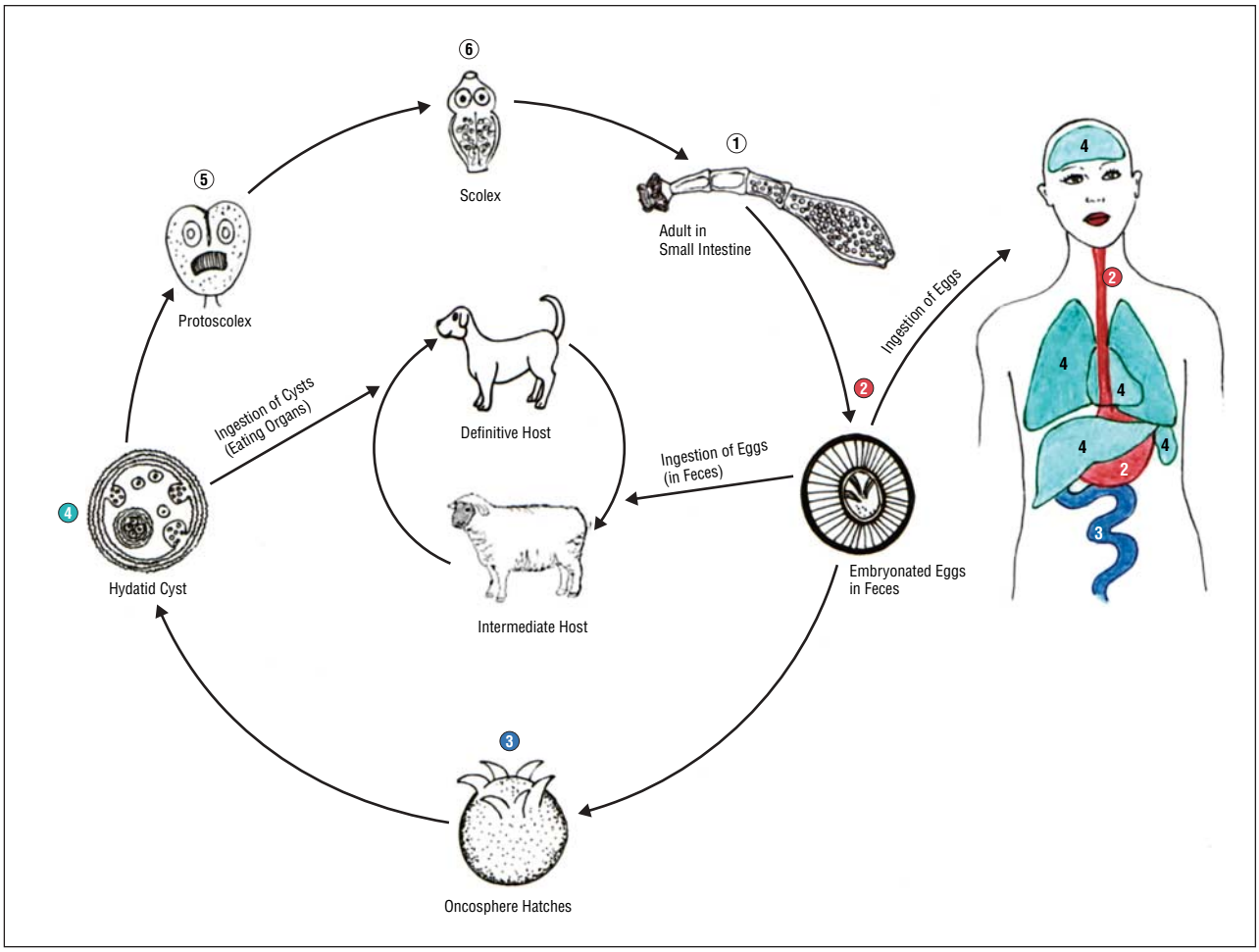

Figure 1. Life cycle of the parasite in the intermediate (sheep, human) and definitive (dog) host.

peritoneal cavity. Older cysts tend to form exogenous daughter cysts, a significant factor for recurrence of the disease after surgery.[11,12]

When the results of medical therapy for hydatid disease are not satisfactory, surgery remains the mainstay of treatment. Several surgical techniques have been proposed for liver disease, like classic open surgical techniques including cyst ablation, unroofing of the cyst with omentoplasty, cyst drainage, marsupialization, pericystectomy, and liver resection for large cysts.[2,7,12-14] Resection of small superficial cysts may be a simple and fast procedure; however, in the case of large cysts, cystectomy involves a major liver resection with its associated operative risk.[12,15] Conservative procedures, such as cyst drainage or omentoplasty on the residual cavity, are easier to perform, but they carry a considerable morbidity and recurrence rate.[16,17] More recently, minimally invasive procedures, such as percutaneous aspiration of cysts and laparoscopic surgery, have been included in our armamentarium against this disease.[18,19] The choice of surgical therapy depends on the patient's general condition, the number and localization of cysts, and the surgeon's expertise.

This article deals with retrospectively reviewed and long-term results of different surgical procedures performed in 287 patients treated for liver hydatid disease in our center during a 28-year period.

METHODS

Between January 1977 and June 2004, 287 patients were treated surgically for liver hydatidosis at the 2nd Department of Propedeutic Surgery of the University of Athens, Athens, Greece. The study group consisted of 129 men (45%) and 158 women (55%). Ages ranged from 29 to 88 years (mean age, 55.4 years). All patients were infected by *E granulosus* and were of Greek origin. The most common complaints were dull pain at the right upper quadrant and epigastrium, and a palpable mass, which were present in 70% and 28% of cases respectively. The less common symptoms were dyspepsia, fever, jaundice, urticaria, and hydatidemesis as presented in **Table 1**. Eleven percent of the patients were asymptomatic and the disease was discovered during a medical check-up.

The diagnosis was established by combining the physical findings and results of the laboratory tests. The hematological tests had a very low sensitivity, with eosinophilia present only in 35% of the patients. Liver function test results were abnormal in 43% of the patients, the elevation of serum alkaline phosphatase being the most common finding. The Casoni skin test has been abandoned as a diagnostic tool since 1980, because of its low diagnostic value and the allergic reactions that it occasionally caused. Among the serological tests, counter immunoelectrophoresis had a high sensitivity, being positive in 92% of patients.

Plain abdominal x-ray films, ultrasonography, and computed tomography were used to support the diagnosis. Ab-

©2006 American Medical Association. All rights reserved.
Downloaded From: http://archsurg.jamanetwork.com/ on 11/29/2015

Table 1. Baseline Features of the Patients

Characteristic	
Age, y	
Mean	55.4
Range	29-88
Sex, M/F	129/158
Symptoms, No. (%)	
Abdominal pain	201 (70)
Palpable mass	80 (28)
Fever	29 (10)
Jaundice	40 (14)
Urticaria	11 (4)
Hydatidemesis	2 (0.7)
Asymptomatic	32 (11)

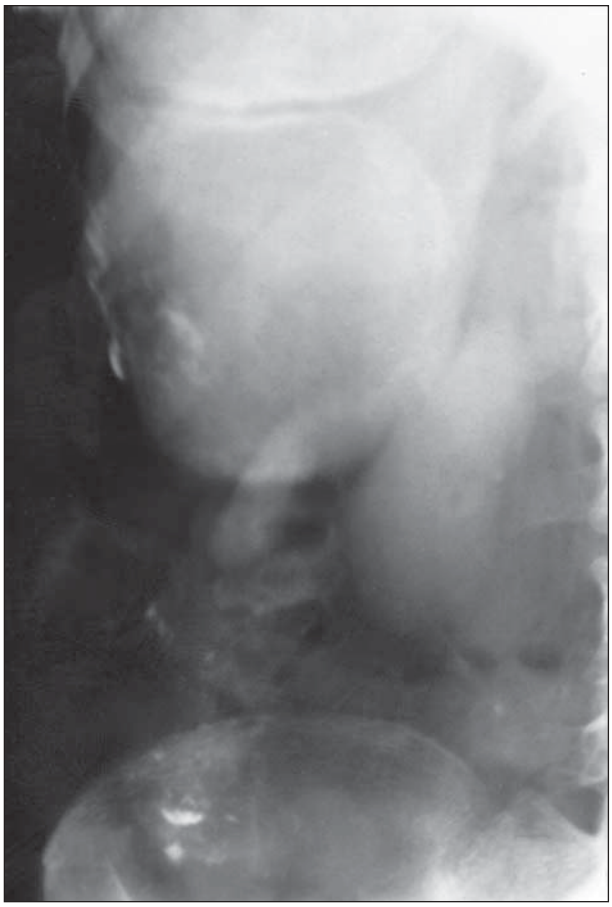

Figure 2. Plain abdominal x-ray film showing a large hydatid cyst located in the right hepatic lobe.

dominal radiographs (**Figure 2**) showed calcification of the cyst wall in 114 patients (40%), elevation of the right hemidiaphragm in 63 cases (22%), and displacement of the stomach to the left in 28 cases (9.8%). Liver scintigraphy was being used for the diagnosis until 1980, but it was replaced by ultrasonography and computed tomography.[2,20] Ultrasonography was diagnostic in 180 of 196 patients in whom it had been used (sensitivity, 92%). Computed tomography (**Figure 3**) was diagnostic in 187 of 192 patients in whom it was used (sensitivity, 97.4%).

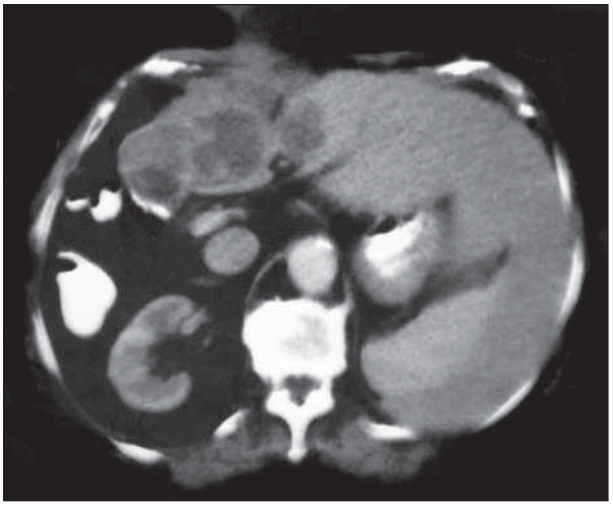

Figure 3. Computed tomography of a patient with recurrent hydatid cysts in the remaining right hepatic lobe. The patient had undergone a right lobectomy for a huge hydatid cyst 2 years earlier. The left lobe appears hypertrophic.

Table 2. Operative Findings

Characteristic	No. (%) of Patients
No. of cysts	
Single	189 (65.8)
Multiple	98 (34.14)
Localization	
Right lobe	192 (67)
Left lobe	66 (23)
Both lobes	29 (10)
Size of the cavity, cm	
Mean	11.6
Range	1.3-36
Biliary communication	42 (14.6)
Bronchial communication	3 (1)

The latter imaging studies revealed that liver cysts were single in 189 cases (65.8%) and multiple in 98 cases (34.14%). Cysts were found in the right lobe in 192 cases (67%), the left lobe in 66 cases (23%), and in both lobes in 29 cases (10%) (**Table 2**). Eleven patients (3.8%) had concomitant hydatid cysts in other organs: 3 in the spleen, 2 in the kidney, and 6 in the lung. Twelve patients had disseminated intra-abdominal disease with multiple cysts located in the abdominal wall and intestinal wall, the omentum, the mesentery, the mesocolon, the retroperitoneal space, or the pelvis. The diameter of the cysts ranged from 1.3 to 36 cm, with a mean size of 11.6 cm. Seventeen patients (5.9%) had infected cysts. Communication of the cyst with the biliary tree was documented in 42 cases (14.6%); migration of the daughter cysts in the common bile duct occurred in 18 cases (6.3%). Hepatobronchopleural fistula was present in 3 cases (1%), and rupture of a liver cyst into the right pleural space that resulted in pleuritis occurred in 2 patients (0.7%).

Follow-up performed at 6-month intervals included a history, physical examination, liver function tests, serological tests, and ultrasonography. Computed tomography of the abdomen was obtained every year. Thirty-three patients were lost to follow-up. For the remaining patients, follow-up ranged from 6 months to 17 years (median, 4.8 years).

Statistical analysis was done using the χ^2 test and the Fisher exact test ($P<.05$ was considered significant).

©2006 American Medical Association. All rights reserved.
Downloaded From: http://archsurg.jamanetwork.com/ on 11/29/2015

Table 3. Types of Surgery, Complications, Mortality, and Recurrence

Types of Surgery	No. of Patients (%)	No. of Complications (%)	Mortality (1 mo)	No. of Recurrences (%)
Group A				
External drainage	42 (14.6)	17 (40.5)	1	2 (4.76)
Evacuation + primary closure	9 (3.1)	2 (22.2)		0
Marsupialization	12 (4.2)	4 (33.3)	1	1 (8.33)
Total	63	23 (36.5)*		3
Group B				
Partial cystectomy + omentoplasty	153 (53.3)	23 (15)	2	11 (7.2)
Combinations of procedures	36 (12.5)	8 (22.2)	1	5 (13.8)
Pericystectomy	17 (5.9)	8 (47)		0
Cyst excision	10 (3.5)	0		
Liver resection	4 (1.4)	1 (25)		1
Laparoscopic drainage	2 (0.7)	0		0
Radiofrequency ablation	2 (0.7)	0		0
Total	224	40 (17.85)*		16

*Statistically significant difference; $P = .02$ (Fisher exact test).

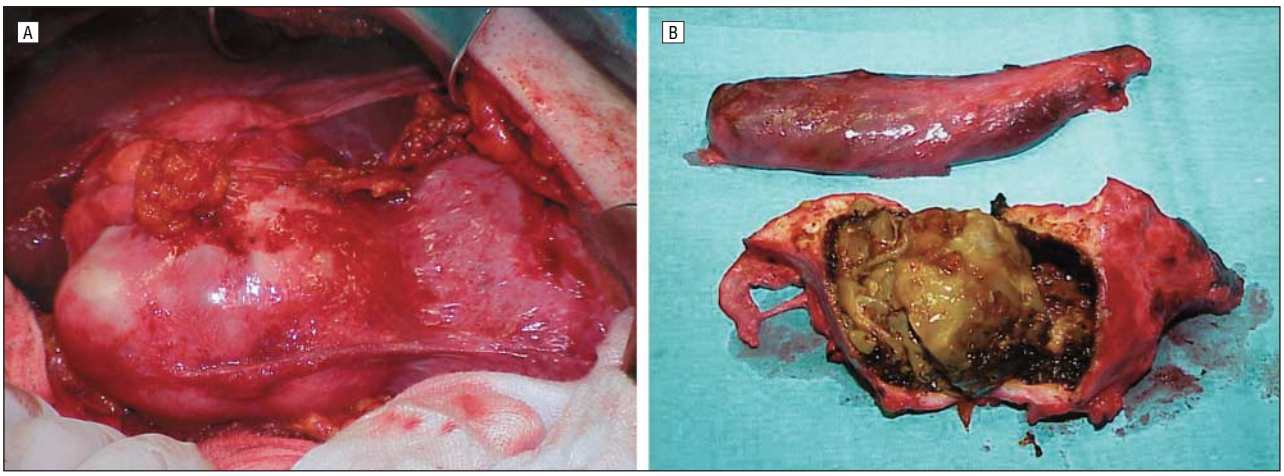

Figure 4. A, A huge hydatid cyst is demonstrated in the operative field, protruding from the lower surface of the right hepatic lobe. B, In this case total pericystectomy was performed. The surgical specimen including the cyst containing daughter cysts and debris. The gallbladder is also shown.

RESULTS

Treatment was surgical in all of the cases. To facilitate the study of the results, patients were classified into 2 groups according to type of surgical procedure (**Table 3**). Group A comprised 63 patients who had undergone external drainage (42 patients with infected cysts, 16.3%), marsupialization (12 patients, 4.6%), or simple closure of the cyst (9 patients, 3.5%). Group B comprised 224 patients who had undergone a variety of procedures: partial cystectomy with omentoplasty was performed in 153 patients (53.3%); pericystectomy was performed in 17 cases (5.9%) with superficial cysts (**Figure 4**A and Figure 4B), whereas in 3 patients with solitary cysts located in the left hepatic lobe, left lateral segmentectomy was performed. In 1 case with a large cyst located at the right lobe, a segment of the diaphragm was used as flap, and in another case with a cyst in the IV_B segment, a sheath of the rectus abdominis muscle was used. A right hepatectomy was required in 1 case with a huge cyst occupying the largest part of the right hepatic lobe. In 2 recent cases (0.7%) with small superficial cysts, laparoscopic drainage of the cysts was carried out successfully. In 2 other cases (0.7%) with small cysts located deep in the hepatic parenchyma—1 case with a 4-cm cyst located in the VI hepatic segment and 1 case with a 6- to 7-cm cyst occupying the II and III hepatic segment—radiofrequency ablation was used to eliminate the cysts (**Figure 5**). In the remaining 36 cases (10.8%) with 2 or more cysts, a combination of procedures was performed, such as omentoplasty combined with cyst excision or external drainage. Most of the intraperitoneal cysts were excised. In 3 patients with concomitant cysts in the spleen, splenectomy was also performed.

In 42 cases with cystobiliary communications, a cholecystectomy with common bile duct exploration was performed, followed by a T-tube insertion in 18 cases because of daughter cysts present in the common bile duct. Cystobiliary communications were closed with fine absorbable sutures, the residual cavity was filled with an omental pedicle, and a drainage tube was left in situ in the cavity. In 2 cases the common bile duct was dilated because it contained hydatid debris and choledochoduodenostomy was carried out.

©2006 American Medical Association. All rights reserved.
Downloaded From: http://archsurg.jamanetwork.com/ on 11/29/2015

Figure 5. Surgical specimen of a resected part of the liver containing recurrent hydatid cysts after partial right hepatectomy performed with radiofrequency ablation technique.

Three patients with hepatobronchopleural fistulas underwent evacuation and irrigation of the bronchial tree during bronchoscopy. Rupture of the cyst into the thoracic cavity was managed using a thoracophrenolaparotomy. Communication was limited to the pleural space only in 2 cases and was managed with removal of hydatid debris, closure of the diaphragmatic defect, and temporary drainage of the pleural cavity.

The postoperative course in the majority of patients was satisfactory. Mean hospital stay was 17±9.2 days. Postoperative complications consisted mainly of septic complications, such as hepatic abscess in 10 patients, wound infection in 15 patients, and pneumonia in 11 patients. All these complications were managed as anticipated except for 2 cases with hepatic abscess, which required surgical drainage, and 2 cases with severe wound infection, which required surgical cleansing. Three patients with severe septic complications developed generalized sepsis and died of septic shock 2 to 3 weeks postoperatively. Five patients who had undergone pericystectomy developed postoperative hemorrhage immediately after surgery, which was managed expectantly, except for 1 case in which surgical exploration was required with ligation of the bleeding vessel. One patient who had undergone a right hepatectomy developed a hematoma at the site of the resected lobe, which was managed conservatively. Two patients with cystobiliary communications developed a bile fistula and 14 others required prolonged tube drainage, which lasted for a mean period of 4±2.3 months. Three patients developed deep vein thrombosis in the early postoperative period, and 1 had a lethal pulmonary embolism a few days later. Two patients had an episode of postoperative bowel obstruction and 1 patient required reexploration (**Table 4**).

If the complications are reviewed according to type of procedure, one realizes that group A patients had a significantly higher complication rate (36.5%) compared with group B patients (17.85%) ($P<.05$). Thus patients who underwent the formerly used procedures, such as marsupialization, simple closure, and external drainage, were more prone to serious complications (Table 4).

During long-term follow-up, 19 patients had recurrent liver cysts (6.6%) (Figure 3). Eleven patients had undergone partial excision of the cyst with omentoplasty. There was 1 marsupialization, 2 external drainages, and a combination of the procedures in the remaining 5 patients (Figure 5). Three of the latter had recurrent peritoneal cysts; most cysts were excised, and the remaining were neutralized. One patient who had undergone a right lobectomy for a huge hydatid cyst had recurrent cysts in the remaining segment of the right lobe. This patient underwent an atypical liver resection including the cysts (Figure 5). If we review the recurrence rate according to type of procedure, we may conclude that conservative techniques with or without omentoplasty (256 cases) had a high recurrence rate (19 recurrent cysts overall; rate, 7.42%) as compared with radical procedures (31 cases), ie, complete cyst resection with or without resection of a hepatic segment, which had a low recurrence rate (1 recurrence overall; rate, 3.22%; $P=.41$).

Table 4. Postoperative Complications

Complication	No. (%) of Patients
Hepatic abscess	10 (3.48)
Wound infection	15 (5.23)
Pneumonia	11 (3.83)
Hemorrhage	5 (1.7)
Hematoma	1 (0.35)
Bile fistula	2 (0.7)
Prolonged tube drainage	14 (4.9)
Deep vein thrombosis	3 (1)
Bowel obstruction	2 (0.7)
Total	**63 (21.9)**

COMMENT

Hydatid disease remains a continuous public health problem in endemic countries. According to our experience, the liver is the most common site for hydatid disease (75% of cases), followed by the lungs (15%), the spleen (5%),[21] and other organs (5%),[2,22,23] being in accordance with other studies.[1,14,24] Although the disease is asymptomatic for many years because of the slow growth of the cyst, it is progressive, may cause life-threatening complications, and has the tendency to recur.[12,14] The hydatid cyst gradually enlarges in the liver parenchyma and may cause symptoms such as dull pain in the right upper quadrant, hepatomegaly, and formation of a palpable mass.[20] Daughter cyst formation may develop from the inner germinal layer in the cyst cavity or exogenously.[12] This may explain why there are 2 or more cysts in the livers of certain patients. The cyst may also rupture into the bile ducts and release daughter cysts, resulting in biliary colic and jaundice[25]; this occurred in 6.3% of our patients. Infection is another complication, which occurs when both the pericyst and the endocyst perforate, allowing bacteria to pass easily into the cyst. Infection usually manifests as a hepatic abscess.[9,26] Rarely, the cyst ruptures into the bronchial tree causing hydatidemesis,[20] which occurred in 3 of our patients. The presence of intraperitoneal hydatidosis accompanying hepatic disease, as was the case of 12 of our patients, is usually due to microperforations or contamination during previous surgery. However, direct perforation of a liver cyst

©2006 American Medical Association. All rights reserved.
Downloaded From: http://archsurg.jamanetwork.com/ on 11/29/2015

into the peritoneal cavity may occur, resulting in acute abdominal pain and systemic anaphylactic reactions.[27]

Diagnosis of liver hydatid disease is made with ultrasonography and computed tomography. Both studies show large cystic lobulated structures containing multiple daughter vesicles or membranes, septa, and hydatid sand. The cyst wall may appear partially or heavily calcified. Partial calcification of the cyst does not always indicate death of the parasite, whereas densely calcified cysts are considered inactive. However, even without calcification, a hydatid cyst usually demonstrates a high attenuated wall on unenhanced computed tomography.[9,10] In our experience, ultrasonography and computed tomography had a sensitivity of more than 90%. The disease is confirmed by a high antibody titer to hydatid antigen using the counter immunoelectrophoresis test.[2,20,28] Counter immunoelectrophoresis results were positive among our patients in 92%, and was a diagnostic tool of great reliability and sensitivity. Enzyme-linked immunosorbent assay, with a 56.7% to 70% sensitivity rate,[29] is considered highly specific for the diagnosis of human echinococcosis, especially when used for locations other than the liver or the lung, or for calcified cysts.[30] Other laboratory tests, such as hematological tests and biochemical liver tests, are considered less sensitive, although some authors suggest that determination of absolute and relative eosinophil count is important.[29] In this series, eosinophilia was present in 35% of patients, and abnormal liver function was found in 43% of patients. The Casoni skin test has been abandoned since 1980 because of its low sensitivity and its allergic complications in several cases.[1,2,14] Fine-needle aspiration cytology is also proposed as a useful diagnostic method, because it does not cause any complications and can help in the diagnosis.[29,31,32]

Medical treatment of hydatid liver cysts, primarily induced in the 1970s, is based on benzoimidazole carbamates, such as mebendazole and albendazole. It has been proposed that these agents contribute to clinical improvement of the disease by diminishing the size of the cysts and preventing distal metastasis. The factors for success seem to be the ability of the drug to penetrate the cyst wall and the persistence of adequate levels of the active metabolites. Albendazole seems to be more effective owing to better penetration and absorption.[33,34] These agents have actually been used in several studies as a conservative treatment, leading to some decrease or stabilization of the cyst size, especially in cases with small cysts.[31,33,34] However, their clinical efficacy still remains doubtful.[12,30,33,35] They are used mainly for disseminated systemic disease, inoperable cases, and—combined with surgery—to prevent postoperative recurrence.[7,12,33,36] In all cases, follow-up with ultrasound examinations is necessary, because the disease progress does not produce specific symptoms in most cases.[29]

Considering the relative insufficiency of medical therapy, surgery remains the primary treatment for liver hydatidosis. However the choice of the appropriate operating method still constitutes a controversial issue. The main principle of surgical treatment is to evacuate the cyst while avoiding spillage of cyst contents, neutralization of the cyst, and obliteration of the residual cavity.[15,16,20,30] During evacuation it is highly important to prevent spillage of daughter cysts in the peritoneal or pleural cavity. Different scolicidal agents have been used to irrigate the cyst cavity together with abdominal packing or suturing of a plastic drape to the cyst wall. The use of formaldehyde solution for irrigation has been abandoned because of serious complications, such as sclerosing cholangitis and acute pancreatitis.[7,12,20,37,38] The same complications, but to a less perilous level, may appear by using hypertonic saline solution. There have been some cases of severe hypernatremia after acute absorption of sodium chloride in high concentrations.[2,39] Despite some authors' objections,[7,40] hypertonic saline solution has been widely used, as well as in this study, without any severe complications.[2,15,40] Several other precautions have been suggested to prevent intraoperative contamination of the peritoneal cavity during evacuation: partial decompression of the cyst before opening the cyst wall and the use of wide-tubing suckers, as cyst contents frequently block the suction devices during evacuation.[12,41]

Adequate drainage and obliteration of the remaining cavity is a necessary procedure to minimize the possibility of serum or blood accumulation or liver abscess formation.[30,36] These situations, along with biliary leakage, constitute the main postoperative complications and the principal reasons for morbidity and mortality among these patients.[7,12,30] Conservative techniques consist of external drainage or marsupialization and internal drainage,[1] evacuation and capitonnage,[2] or omentoplasty.[16,20,42] In previous studies, it has been shown that there is a remarkably lower morbidity and mortality rate among patients treated with cyst excision and omentoplasty.[1,16,20,42-44] Furthermore, in the current study omentoplasty and radical procedures had a significantly lower complication rate than external drainage, simple closure, and marsupialization. Drainage procedures in particular may cause severe complications such as hepatic abscess, biliary leakage, and fistulas, leading to a prolonged hospital stay.[13,45] During our study period, partial excision with omentoplasty was widely used, and was applied in 53.3% of patients, leading to better postoperative results. There was a trend to abandon marsupialization, practiced only in 4.6% of the early cases of the study. Different serious complications were observed with the application of this method, such as biliary leakage, vessel injuries and hemorrhage, sepsis, cholangitis, and allergic shock.[13,15,45] External drainage is unavoidable for complicated cases (16.3%), such as infected cysts or cystobiliary communications.[15] Uncomplicated cysts located deep in the liver parenchyma can be managed with internal drainage.

Recent studies indicate that evacuation of the cyst content can be carried out successfully using a laparoscopic trocar. It seems that this method has a better yield for posterior cysts and it generally diminishes the risk of spillage into the peritoneal cavity and the rate of recurrence.[46,47] In addition, it is a simple and universally applicable technique, with better aesthetic results, and minimizes the length of hospital stay. This procedure has been performed successfully in 2 of our recent cases with superficial cysts close to the liver capsule.

Radical techniques, such as total pericystectomy, when feasible, provide better results, because they minimize

©2006 American Medical Association. All rights reserved.
Downloaded From: http://archsurg.jamanetwork.com/ on 11/29/2015

the risk of postoperative complications and recurrence.[7,48,49] Indeed, in our study, the recurrence rate after radical procedures was very low. These techniques reduce the incidence of biliary leakage and minimize the chance for exogenous cyst formation.[12] Among the radical procedures, total pericystectomy is the treatment of choice, because it does not carry the risk of liver function compromise caused by resection of hepatic tissue.[12,48] In our institute, pericystectomy was performed in 17 cases (5.9%) with superficial liver cysts or peritoneal cysts.

Hepatic lobectomy should be applied only to large or multiple cysts displacing the parenchyma of a liver lobe. Smaller cysts can also be managed by segmentectomies or atypical liver resections.[14]

All radical procedures carry the risk of intraoperative or postoperative bleeding, owing to the absence of a true surgical cleavage with the liver parenchyma.[2,12] This risk is much larger for cysts adherent to the hepatic veins, inferior vena cava, or hepatic hilum.[50] In our study, there was a 29.4% rate of postoperative hemorrhage among patients who underwent pericystectomy.

The most common complications during management of liver hydatidosis are ruptures into the biliary tract or the thoracic cavity.[30,51,52] In cases with rupture into the biliary tract, exploration of the biliary tract and removal of the hydatid debris with cholecystectomy and placement of a T-tube for drainage is necessary.[15,36,42] Prolonged tube drainage in cases with cystobiliary communications may increase the postoperative hospital stay.[2,12,15,36] In our study, cholecystectomy with exploration of the common bile duct and omentoplasty was performed in all cases with cystobiliary communications. This procedure leads to more satisfactory control of biliary leakage for fistulas greater than 5 mm in diameter.[16] Cases with common bile duct dilatation and retained hydatid cysts in the bile duct, especially when there is jaundice, are managed with choledochoduodenostomy or endoscopic sphincterotomy.[15,51-53] Endoscopic retrograde cholangiopancreatography with sphincterotomy is an alternative method of treatment in cases with cholangitis secondary to hydatid disease.[53]

Thoracic involvement occurs in 0.6% to 16% of cases of hepatic hydatid disease.[9,54,55] It is managed with the transthoracic approach and thoracotomy if the biliary tract is intact. If biliary leakage is involved, the abdominal approach becomes necessary for drainage to be done. Pulmonary resection or lobectomy may be required in some cases.[30,54] When both liver and lung hydatidosis are present, a thoracic transpleural approach seems to be the method with best results. This technique carries a particular indication for cysts located in the right lobe and the upper pole of the liver.[2] Alternatively, bronchoscopy can be used for evacuation and irrigation of the bronchial tree.

The morbidity rate after surgery for hepatic hydatidosis has been reported to range from 6% to 47%.[17,36,42,48] In this study the overall morbidity rate was 21.9%, with main complications being the septic and prolonged tube drainage in patients with cystobiliary communications. Preoperative complications, comorbidity, and infection in the residual cavity are considered the main causes of death in hepatic hydatid surgery ranging from 1% to 3% according to various studies[42,48] (1% in our study).

Recurrence of hydatid disease in the liver parenchyma constitutes a main concern in these patients' postoperative course. It usually results from spillage of hydatid fluid containing daughter cysts during the operation or incomplete resection of the cyst following conservative procedures, leaving residual vesicles in place.[7,12,56] It has been reported that recurrence rates range from 6% to 25% when omentoplasty is used.[2,17,57] In this study the total recurrence rate was 6.6%. In regards to cases treated with omentoplasty, recurrence has been the main problem; 7.2% of the patients managed with this procedure developed local recurrence. However, the recurrence rate after radical procedures was very low, but not zero. This fact shows that even by using radical procedures for the treatment of hydatid disease, the possibility of recurrence always remains.

The lack of symptoms in most cases with recurrence make long-term follow-up after surgery a necessity. It is suggested that patients are followed up with ultrasonography every 6 months or with computed tomography annually for at least 3 years, as most recurrences are observed in this time period. When revealed, recurrent cysts should be managed by percutaneous drainage or radical surgery combined with albendazole therapy.[30,57]

In conclusion, conservative techniques offer an effective control of hepatic hydatidosis and they can replace unnecessary radical procedures when possible. In all cases, when the operative strategy is chosen after consideration of multiple factors referring to the patient's particular medical situation, such as the size and location of the cyst, existing complications, and other diseases, the ideal result can be achieved with a minimal risk of postoperative morbidity or recurrence.

Accepted for Publication: September 13, 2005.
Correspondence: Michael C. Safioleas, MD, PhD, Cyprou 7 Avenue, Filothei, Athens 152 37, Greece (geosiam@yahoo.com).
Author Contributions: *Study concept and design:* Safioleas, Misiakos, and Felekouras. *Acquisition of data:* Safioleas, Misiakos, Stamatakos, and Manti. *Analysis and interpretation of data:* Safioleas, Misiakos, and Manti. *Critical revision of the manuscript for important intellectual content*: Safioleas, Misiakos, and Felekouras. *Statistical analysis:* Misiakos, Kouvaraki, and Stamatakos. *Administrative, technical, and material support:* Safioleas, Misiakos, Kouvaraki, and Felekouras. *Study supervision:* Safioleas.
Financial Disclosure: None reported.

REFERENCES

1. Doty JE, Tompkins RK. Management of cystic disease of the liver. *Surg Clin North Am.* 1989;69:285-295.
2. Safioleas M, Misiakos EP, Kakisis J, et al. Surgical treatment of human echinococossis. *Int Surg.* 2000;85:358-365.
3. Thompson RCA, McManus DP. Aetiology: parasites and life cycles. In: Eckert J, Gemmell MA, Meslin FX, Pawllowski ZS, eds. *Manual on Echinococcosis in Humans and Animals: A Public Health Problem of Global Concern.* Paris, France: WHO/OIE, 2001:1-19.
4. McManus DP, Zhang L, Castrodale LJ, Le TH, Pearson M, Blair D. Short report: molecular genetic characterization of an unusually severe case of hydatid dis-

©2006 American Medical Association. All rights reserved.
Downloaded From: http://archsurg.jamanetwork.com/ on 11/29/2015

ease in Alaska caused by the cervid strain of *Echinococcus granulosus*. *Am J Trop Med Hyg*. 2002;67:296-298.
5. Schwartz PM, Chai J, Craig PS, et al. Epidemiology and control of hydatid disease. In: Thompson RCA, Lymbery AJ, eds. *The Biology of Echinicoccus and Hydatid Disease*. Wallingford, England: CAB International; 1995:233-302.
6. Thompson RC, Lymbery AJ, Hobbs RP, Elliot AD. Hydatid disease in urban areas of Western Australia: an unusual cycle involving western grey kangaroos (*Macropus fuliginosus*), feral pigs and domestic dogs. *Aust Vet J*. 1988;65:188-190.
7. Chautems R, Buhler L, Gold B, Chilcott M, Morel P, Mentha G. Long term results after complete or incomplete surgical resection of liver hydatid disease. *Swiss Med Wkly*. 2003;133:258-262.
8. Amr SS, Amr ZS, Jitawi S, Annab H. Hydatidosis in Jordan: an epidemiological study of 306 cases. *Ann Trop Med Parasitol*. 1994;88:623-627.
9. Pedrosa I, Saiz A, Arrazola J, Ferreiros J, Pedrosa CS. Hydatid disease: radiologic and pathologic features and complications. *Radiographics*. 2000;20:795-817.
10. Lewall DB. Hydatid disease: biology, pathology, imaging and classification. *Clin Radiol*. 1998;52:863-874.
11. Guntz M. Les bases anatomo-pathologiques du traitement chirurgical du kyste hydatique du foie. *Minerva Chir*. 1973;28:708-716.
12. Magistrelli P, Masetti R, Coppola R, Messia A, Nuzzo G, Piciocchi A. Surgical treatment of hydatid disease of the liver: a 20-year experience. *Arch Surg*. 1991; 126:518-522.
13. Filippou DK, Kolimpiris C, Anemodouras N, Rizos S. Modified capitonage in partial cystectomy performed for liver hydatid disease: report of 2 cases. *BMC Surg*. 2004;4:8.
14. Langer JC, Rose DB, Keystone JS, Taylor BR, Langer B. Diagnosis and management of hydatid disease of the liver: a 15-year North American experience. *Ann Surg*. 1984;199:412-417.
15. Balik AA, Basoglu M, Celebi F, et al. Surgical treatment of hydatid disease of the liver: review of 304 cases. *Arch Surg*. 1999;134:166-169.
16. Dziri C, Paquet JC, Hay JM, et al. Omentoplasty in the prevention of deep abdominal complications after surgery for hydatid disease of the liver: a multicenter, prospective, randomized trial. *J Am Coll Surg*. 1999;188:281-289.
17. Vagianos CE, Karavias DD, Kakkos SK, et al. Conservative surgery in the treatment of hepatic hydatidosis. *Eur J Surg*. 1995;161:415-420.
18. Men S, Hekimoglu B, Yucesoy C, Arda IS, Baran I. Percutaneous treatment of hepatic hydatid cysts: an alternative to surgery. *AJR Am J Roentgenol*. 1999; 172:83-89.
19. Bickel A, Daud G, Urbach D, et al. Laparoscopic approach to hydatid liver dysts: Is it logical? Physical, experimental, and practical aspects. *Surg Endosc*. 1998; 12:1073-1077.
20. Safioleas M, Misiakos E, Manti C, Katsikas D, Skalkeas G. Diagnostic evaluation and surgical management of hydatid disease of the liver. *World J Surg*. 1994; 18:859-865.
21. Safioleas M, Manti C, Misiakos E. Surgical treatment for splenic hydatidosis. *World J Surg*. 1997;21:374-377.
22. Safioleas M, Stamoulis I, Theocharis S, Moulakakis K, Makris S, Kostakis A. Primary hydatid disease of the gallbladder: a rare clinical entity. *J Hepatobiliary Pancreat Surg*. 2004;11:352-356.
23. Safioleas MC, Moulakakis KG, Manti C, Kostakis A. Clinical considerations of primary hydatid disease of the pancreas. *Pancreatology*. 2005;5:457-461.
24. Tsaroucha AK, Polychronidis AC, Lyrantzopoulos N, et al. Hydatid disease of the abdomen and other locations. *World J Surg*. 2005;29:1161-1165.
25. Ovnat A, Peiser J, Avinoah E, Barki Y, Charuzi I. Acute cholangitis caused by ruptured hydatic cyst. *Surgery*. 1984;95:497-500.
26. Marti-Bonmati L, Menor Serrano F. Complications of hepatic hydatid cysts: ultrasound, computed tomography, and magnetic resonance diagnosis. *Gastrointest Radiol*. 1990;15:119-125.
27. Sozuer EM, Ok E, Arslan M. The perforation problem in hydatid disease. *Am J Trop Med Hyg*. 2002;66:575-577.
28. Papaioannides D, Papagianni A, Akritides N. Hydatid disease of the liver. *Postgrad Med J*. 1999;75:462.
29. Niscigorska J, Sluzar T, Marczevska M, et al. Parasitic cysts of the liver: practical approach to diagnosis and differentiation. *Med Sci Monit*. 2001;7:737-741.
30. Dziri C. Hydatid disease: continuing serious public health problem. *World J Surg*. 2001;25:1-3.
31. Haddad MC, Al-Awar G, Huwaijah SH, Al-Kutoubi AO. Echinococcal cysts of the liver: a retrospective analysis of clinico-radiological findings and different therapeutic modalities. *Clin Imaging*. 2001;25:403-408.
32. Yaghan RJ. Hydatid disease of the breast: a case report and literature review. *Am J Trop Med Hyg*. 1999;61:714-715.
33. Aktan AO, Yalin R. Preoperative albendazole treatment for liver hydatid disease decreases the viability of the cyst. *Eur J Gastroenterol Hepatol*. 1996;8:877-879.
34. Blanton RE, Wachira TM, Zeyhle EE, Njoroge EM, Magambo JK, Schantz PM. Oxfendazole treatment for cystic hydatid disease in naturally infected animals. *Antimicrob Agents Chemother*. 1998;42:601-605.
35. Teggi A, Lastilla MG, De Rosa F. Therapy of human hydatid disease with mebendazole and albendazole. *Antimicrob Agents Chemother*. 1993;37:1679-1684.
36. Agaoglu N, Turkyilmaz S, Arslan MK. Surgical treatment of hydatid cysts of the liver. *Br J Surg*. 2003;90:1536-1541.
37. Khodadadi DJ, Kurgan A, Schmidt B. Sclerosing cholangitis following the treatment of echinococcosis of the liver. *Int Surg*. 1981;66:361-362.
38. Karavias DD, Vagianos CE, Bouboulis N, Rathosis S, Androulakis J. Improved techniques in the surgical treatment of hepatic hydatidosis. *Surg Gynecol Obstet*. 1992;174:176-180.
39. Wanninayake HM, Brough W, Bullock N, Calne RY, Farman JV. Hypernatraemia after treatment of hydatid. *BMJ*. 1982;284:1302-1303.
40. Kayaalp C, Balkan M, Aydin C, et al. Hypertonic saline in hydatid disease. *World J Surg*. 2001;25:975-979.
41. Grosdidier J, Boissel P, Bresler L, Nessler JPh, Guirlet MN. Etude retrospective d' une serie de 62 cas de kystes hydatiques du foie. *J Chir (Paris)*. 1985;122: 163-169.
42. Sayek I, Yalin R, Sanac Y. Surgical treatment of hydatid disease of the liver. *Arch Surg*. 1980;115:847-850.
43. Mentes A, Yuzer Y, Ozbal O, Coker A, Ilter T, Musoglu A. Omentoplasty versus introflection for hydatid liver cysts. *J R Coll Surg Edinb*. 1993;38:82-85.
44. Uravic M, Stimac D, Lenac T, et al. Diagnosis and treatment of liver hydatid disease. *Hepatogastroenterology*. 1998;45:2265-2269.
45. Demirci S, Eraslan S, Anadol E, Bozatli L. Comparison of the results of different surgical techniques in the management of hydatid cyst of the liver. *World J Surg*. 1989;13:88-90.
46. Kayaalp C. Evacuation of hydatid cysts using laparoscopic trocar. *World J Surg*. 2002;26:1324-1327.
47. Bensaadi H, Champault G. Laparoscopic hand-assisted surgery for hydatid cysts of the liver. *Surg Laparosc Endosc Percutan Tech*. 2004;14:91-92.
48. Alfieri S, Doglietto GB, Pacelli F, et al. Radical surgery for liver hydatid disease: a study of 89 patients. *Hepatogastroenterology*. 1997;44:496-500.
49. Nardo B, Patrici A, Piazzese E, et al. Radical surgical treatment of recurrent hepatic hydatidosis. *Hepatogastroenterology*. 2003;50:1478-1481.
50. Belli L, Aseni P, Rondinara GF, Bertini M. Improved results with pericystectomy in normothermic ischemia for hepatic hydatidosis. *Surg Gynecol Obstet*. 1986; 163:127-132.
51. Kayaalp C, Bostanci B, Yol S, Akoglu M. Distribution of hydatid cysts into the liver with reference to cystobiliary communications and cavity-related complications. *Am J Surg*. 2003;185:175-179.
52. Iscan M, Duren M. Endoscopic sphincterotomy in the management of postoperative complications of hepatic hydatid disease. *Endoscopy*. 1991;23:282-283.
53. Yorganci K, Sayek I. Surgical treatment of hydatid cysts of the liver in the era of percutaneous treatment. *Am J Surg*. 2002;184:63-69.
54. Kilani T, El Hammami S, Horchani H, et al. Hydatid disease of the liver with thoracic involvement. *World J Surg*. 2001;25:40-45.
55. Safioleas M, Misiakos EP, Dosios T, Manti C, Lambrou P, Skalkeas G. Surgical treatment for lung hydatid disease. *World J Surg*. 1999;23:1181-1185.
56. Pitt HA, Korzelius J, Tompkins RK. Management of hepatic echinococcosis in Southern California. *Am J Surg*. 1986;152:110-113.
57. Sielaff TD, Taylor B, Langer B. Recurrence of hydatid disease. *World J Surg*. 2001; 25:83-86.

©2006 American Medical Association. All rights reserved.
Downloaded From: http://archsurg.jamanetwork.com/ on 11/29/2015