ORIGINAL ARTICLE

Comparison of Percutaneous and Surgical Approaches for Radiofrequency Ablation of Small and Medium Hepatocellular Carcinoma

Muhammad Rizwan Khan, MBBS; Ronnie T. P. Poon, MS; Kelvin K. Ng, PhD; Albert C. Chan, MBBS; Jimmy Yuen, MBBS; Helen Tung, MBBS; Jason Tsang, MBBS; Sheung Tat Fan, MS, MD, PhD, DSc

Hypothesis: Radiofrequency ablation (RFA) for hepatocellular carcinoma (HCC) can be performed by percutaneous or surgical approach. Tumor size is an important consideration while deciding the treatment approach.

Design: Case series with prospective data collection.

Setting: A tertiary referral center.

Patients: A total of 228 patients who underwent RFA of small (≤3 cm; n=155) and medium (3.1-5 cm; n=73) HCC by percutaneous or surgical approach.

Main Outcome Measures: Complete ablation rate, post-RFA complications, treatment-related mortality, and overall and disease-free survival.

Results: In patients with small HCC, the complete ablation rate was 95% with both approaches ($P>.99$). Complication rate ($P<.001$) and hospital stay ($P<.001$) were higher with the surgical approach. One-year and 3-year survival rates were 91% and 71%, respectively, in the percutaneous group, and 89% and 57%, respectively, in the surgical group ($P=.30$). In patients with medium HCC, the complete ablation rate was similar between the surgical and the percutaneous groups (92% vs 95%; $P=.48$), and the complication rate was also comparable ($P=.17$). The 1-year and 3-year survival rates were 92% and 68%, respectively, in the surgical group, significantly superior to the corresponding rates of 81% and 42% in the percutaneous group ($P=.03$).

Conclusions: In patients with small HCC, the percutaneous approach achieved similar tumor control with lower morbidity compared with the surgical approach and should be the preferred approach provided that tumor location is suitable. For medium HCC, the surgical approach seems to achieve better overall survival and may be a preferred option.

Arch Surg. 2007;142(12):1136-1143

Hepatocellular carcinoma (HCC) is the fifth most common malignancy in the world.[1,2] Although HCC is more prevalent in Asia and Africa, its incidence is on the rise in the Western countries.[3,4] The resectability rate of HCC is limited to only 20% to 37% because of various factors, including multifocal and bilobar disease and poor liver function reserve as a result of underlying cirrhosis.[5,6] Liver transplantation is an alternative curative treatment for small unresectable HCC, but organ shortage limits its applicability.[7,8] Hence, various locoregional therapies have been developed for unresectable HCC.[9]

Radiofrequency ablation (RFA) is one of the most recent local ablative therapies for unresectable HCC, with a high complete ablation rate of 85% to 95% for HCCs 3 cm or less in diameter.[10-14] Recent advances in RFA technology, such as the development of an internally cooled cluster electrode, have enabled ablation of medium and large tumors.[15] Recent studies have demonstrated the safety and feasibility of RFA for medium and large lesions.[16-20] Radiofrequency ablation has been shown to have a significant impact on the management of HCC in specialized centers[21] and even has been proposed as an alternative to surgical resection for liver tumors in patients who have had prior live resection.[22]

See Invited Critique at end of article

Radiofrequency ablation was initially started by radiologists as a percutaneous treatment,[23,24] but surgeons started to use RFA by surgical approach for patients with tumors at locations difficult for the percutaneous procedure. Given the absence of randomized trials, there is no consensus about which route is the best,[25] and a limited number of studies have reported controversial results.[26-28] In a recent meta-

Author Affiliations: Departments of Surgery (Drs Khan, Ng, Chan, and Fan and Mr Poon) and Radiology (Drs Yuen, Tung, and Tsang), Centre for the Study of Liver Disease, The University of Hong Kong, Pokfulam, Hong Kong, China.

©2007 American Medical Association. All rights reserved.
Downloaded From: http://archsurg.jamanetwork.com/ on 10/25/2014

analysis of 5224 liver tumors treated by RFA, the treatment approach was found to be a significant independent factor for local recurrence, and the authors recommended the open surgical approach because of its superior local tumor control.[29] However, the impact of the analysis is limited by the fact that tumors with different pathologic diagnoses with variable biological behavior were combined and various types of electrodes and techniques were used in different studies. In the current study, we compare the outcome of the percutaneous approach with that of the surgical approach of RFA for HCC in relation to the tumor size in a series of patients treated by a team of radiologists and surgeons in a standardized fashion.

METHODS

Between May 1, 2001, and September 30, 2005, 258 patients with HCC underwent RFA treatment at Queen Mary Hospital, Hong Kong, China. Patients who had RFA performed with a palliative intention (n=3), as an emergency procedure for hemostasis of ruptured HCC (n=15), or with a tumor size greater than 5 cm (n=12) were excluded from this study. The other 228 patients with a tumor size 5 cm or less and 3 or fewer tumor nodules who underwent elective RFA with a curative intent were the subjects of this study. These patients were divided into 2 groups depending on the largest tumor size according to a recent international proposal[30]: group 1 had a tumor size 3 cm or less in diameter (small HCC; n=155), and group 2 had a tumor size 3.1 to 5 cm (medium HCC; n=73). Groups 1 and 2 included 55 and 25 patients, respectively, who had resectable HCC but were treated with RFA in a prospective randomized trial in which resection and RFA for HCC 5 cm or less in diameter were being compared. The other patients were not candidates for surgical resection because of poor hepatic function reserve (n=118), bilobar tumors (n=16), or high surgical risk (n=6). Another 8 patients elected RFA as a treatment modality despite having resectable disease. General criteria for exclusion from RFA in our center include extrahepatic disease, more than 4 tumor nodules, tumor larger than 8 cm, Child-Pugh class C liver cirrhosis, and refractory ascites. Patients with Child-Pugh class B cirrhosis who had significant portal hypertension as reflected by a platelet count of less than $50 \times 10^3/\mu L$ (to convert to $\times 10^9/L$, multiply by 1) or significant ascites were also excluded from RFA. The diagnosis of HCC was suggested by imaging findings and α-fetoprotein levels and confirmed by fine-needle aspiration cytologic or core biopsy.

All RFA procedures were performed by a dedicated team of hepatobiliary surgeons and interventional radiologists (R.T.P.P., K.K.N., J.Y., H.T., J.T., S.T.F.), with a standard protocol using a cool-tip RFA system (Radionics Inc, Burlington, Massachusetts). A single electrode with a 2-cm or 3-cm exposed tip was used for small tumors, and a cluster electrode consisting of 3 parallel electrodes was used for medium tumors. The ablation was performed using an automatic impedance control mode. Each ablation cycle lasted for 6 to 12 minutes. The cluster electrode can produce an ablation zone with a maximum diameter of 5 cm.[31] In general, multiple overlapping ablations were required for tumors greater than 3 cm in diameter, but the use of multiple overlapping ablation also depends on morphology of the tumor. We aimed at ablation of all tumors with a curative intent, with a margin of 1 cm if feasible, in a single session of RFA.

Each patient was discussed in a team meeting before the appropriate approach was decided. Patients with tumors located in a position amenable to percutaneous RFA were treated by this approach. Surgical approach was offered in the following circumstances: tumor morphology required multiple ablations even with the cluster electrode; tumors located near the dome of the liver, for which percutaneous ablation might cause pneumothorax or damage to the diaphragm; or tumors located near the visceral organs such as the gallbladder, colon, or stomach. In select patients who had not undergone a previous upper abdominal operation, a laparoscopic approach was used if tumor position was favorable. Because only 20 patients were treated by the laparoscopic approach, these patients were grouped with open RFA for the purpose of comparison in this study.

Percutaneous RFA was performed in 117 patients by interventional radiologists, under ultrasonographic guidance in most cases, after the patient had received local anesthesia and intravenous sedation. Six patients underwent a computed tomographic (CT)–guided RFA for lesions not visible on ultrasonography. Surgeons performed open (n=91) or laparoscopic (n=20) RFA under intraoperative or laparoscopic ultrasonographic guidance. The Pringle maneuver was not used. Bile duct cooling with cold saline was performed in 22 patients for tumors located near the hilum to prevent thermal injury of the hepatic ducts. On laparoscopy or laparotomy, additional tumor nodules not shown in preoperative imaging were found in 5 patients (4.5%), and larger tumor size (>0.5-cm difference) compared with preoperative imaging was found in 20 patients (18%). None of the patients were found to have extrahepatic disease that precluded RFA.

Clinical data were collected prospectively. The treatment protocol and data collection were approved by the institutional review board of our institution. The clinical data and treatment outcome in the 2 groups of patients with 2 different treatment approaches were compared. The outcome measures were complete ablation rate, post-RFA complications, treatment-related mortality, and disease-free and overall survival. Response to RFA was assessed by helical CT scan 1 month after RFA. Complete ablation was defined as the absence of any peripheral enhancement in the arterial phase at the ablation site. A complication was defined as any adverse event after RFA, excluding pain or transient febrile response. Treatment mortality was defined as any death within 30 days after RFA.

All patients were monitored with measurement of serum α-fetoprotein level, chest radiography, and CT scan every 3 months for any intrahepatic recurrence or distant metastasis. Local recurrence was defined as recurrence within or at the periphery of the ablated lesion on subsequent CT scans after complete ablation was documented on the first post-RFA CT scan. Distant intrahepatic recurrence was defined as a new tumor that appeared in the liver separate from the ablated area. Extrahepatic metastasis refers to any recurrence outside the liver.

Continuous data were expressed as mean (SD). Groups were compared using the χ^2 test (or Fisher exact test when appropriate) for nominal variables. The *t* test was used for continuous variables in a parametric fashion, whereas the Mann-Whitney *U* test was used for nonparametric data. Survival was estimated using the Kaplan-Meier method and compared using the log-rank test. All statistical analyses were performed using the SPSS 11.5 for Windows statistical package (SPSS Inc, Chicago, Illinois). A *P* value of <.05 was considered statistically significant.

RESULTS

Outcome after RFA by either percutaneous or surgical approach was compared in 155 patients with small HCC and 73 patients with medium HCC.

PATIENT CHARACTERISTICS

Table 1 shows the baseline characteristics of 155 patients with small HCC who underwent percutaneous (n=92) or surgical (n=63) RFA. The 2 groups were similar in age, sex,

©2007 American Medical Association. All rights reserved.
Downloaded From: http://archsurg.jamanetwork.com/ on 10/25/2014

Table 1. Characteristics of 155 Patients With Small HCC With RFA by Percutaneous or Surgical Approach

Characteristic	Percutaneous Approach (n=92)	Surgical Approach (n=63)	*P* Value
Sex, M/F, No. (%)	70 (76)/22 (24)	42 (67)/21 (33)	.20
Age, y, mean (SD)	58 (10.9)	61 (10.3)	.09
Cirrhosis, No. (%)	68 (74)	60 (95)	<.001
Positive for hepatitis B surface antigen, No. (%)	78 (85)	50 (79)	.19
Positive for hepatitis C virus antibody, No. (%)	7 (7)	10 (16)	.22
Child-Pugh class, No. (%)			.12
A	87 (95)	54 (86)	
B	5 (5)	8 (13)	
C	0	1 (1)	
Comorbid illness, No. (%)[a]	39 (42)	20 (32)	.23
Previous hepatic resection, No. (%)	33 (36)	12 (19)	.03
Previous chemoembolization, No. (%)	27 (29)	8 (17)	.19
Multiple tumors, No. (%)	17 (18)	12 (19)	.92
AFP level, ng/mL, mean (SD)	193 (531)	776 (2713)	.05
Albumin level, g/dL, mean (SD)	3.8 (0.4)	3.8 (0.7)	.57
Bilirubin level, mg/dL, mean (SD)	0.9 (0.4)	1.0 (0.6)	.07
Platelet count, $\times 10^3$/uL, mean (SD)	132 (56)	116 (53)	.08
Indocyanine green retention rate at 15 min, %, mean (SD)	19.4 (13.5)	23.2 (17.3)	.14

Abbreviations: AFP, α-fetoprotein; HCC, hepatocellular carcinoma; RFA, radiofrequency ablation.

SI conversion factors: To convert albumin to grams per liter, multiply by 10; bilirubin to micromoles per liter, multiply by 17.104; and platelet count to $\times 10^9$/L, multiply by 1.

[a] Includes diabetes mellitus and chronic cardiovascular, respiratory, and renal diseases.

Table 2. Characteristics of 73 Patients With Medium HCC With RFA by Percutaneous or Surgical Approach

Characteristic	Percutaneous Approach (n=25)	Surgical Approach (n=48)	*P* Value
Sex, M/F, No. (%)	20 (80)/5 (20)	43 (90)/5 (10)	.29
Age, y, mean (SD)	65 (9.9)	57 (11.6)	<.001
Cirrhosis, No. (%)	22 (88)	44 (92)	.68
Positive for hepatitis B surface antigen, No. (%)	18 (72)	46 (96)	<.001
Positive for hepatitis C virus antibody, No. (%)	5 (20)	4 (8)	.30
Child-Pugh class, No. (%)			.35
A	22 (88)	45 (94)	
B	3 (12)	2 (4)	
C	0	1 (2)	
Comorbid illness, No. (%)[a]	8 (32)	15 (31)	>.99
Previous hepatic resection, No. (%)	5 (20)	6 (12.5)	.49
Previous chemoembolization, No. (%)	8 (32)	7 (15)	.07
Multiple tumors, No. (%)	2 (8)	11 (23)	.21
AFP level, ng/mL, mean (SD)	1091 (4544)	1317 (3275)	.80
Albumin level, g/dL, mean (SD)	3.5 (0.6)	3.8 (0.4)	.05
Bilirubin level, mg/dL, mean (SD)	1.1 (0.7)	0.8 (0.4)	.04
Platelet count, $\times 10^3$/uL, mean (SD)	128 (69)	139 (57)	.48
Indocyanine green retention rate at 15 min, %, mean (SD)	23.9 (16.8)	18.4 (12.8)	.15

Abbreviations: See Table 1.

SI conversion factors: See Table 1.

[a] Includes diabetes mellitus and chronic cardiovascular, respiratory, and renal diseases.

positive results for hepatitis B and C serologic testing, and comorbid illnesses. Cirrhosis was more prevalent in the surgical group. The distribution of Child-Pugh class was similar, and the majority of the patients had Child-Pugh class A cirrhosis in both groups. A significantly higher proportion of patients in the percutaneous group had recurrent HCC after previous hepatic resection. Serum total bilirubin level, indocyanine green retention at 15 minutes, and serum α-fetoprotein level tended to be higher, whereas platelet counts were lower in patients who underwent surgical RFA, but the difference were not significant. Serum albumin level was similar in the 2 groups.

Table 2 shows the baseline characteristics of 73 patients with medium HCC who underwent percutaneous (n=25) or surgical (n=48) RFA. The sex distribution was similar, but patients in the percutaneous group were significantly older. The prevalence of hepatitis B viral infection was higher in patients with the surgical approach, but the distribution of hepatitis C viral infection, underlying cirrhosis, Child-Pugh class, and comorbid illnesses was not statistically different between the 2 groups. Patients in the surgical group tended to have a higher incidence of multiple tumors (23% vs 8%), but the difference was not statistically significant. Serum total bilirubin level was significantly higher in the percutaneous group, but serum albumin level and indocyanine green retention at 15 minutes were comparable in both groups.

TREATMENT DATA, MORBIDITY, AND MORTALITY

Table 3 depicts the treatment data for patients with small HCC. Percutaneous RFA was performed under ultrasonographic guidance in 86 patients and under CT guidance in 6 patients. In the surgical group, 16 patients underwent a laparoscopic RFA, while 47 patients had laparotomy.

The proportion of patients with 1 tumor was similar, but the proportion of patients with 3 tumors was significantly lower in the percutaneous group. Mean tumor size was also significantly smaller in the percutaneous group. Hepatic function in terms of day-7 albumin and bilirubin levels after RFA was significantly worse in the surgical group. The incidence of postoperative complications (21% vs 5.4%) was significantly higher in the surgical group. In the percutaneous group, 5 patients had a total of 8 complications, including thrombosis of the main lobar portal vein (n=1), ascites requiring treatment (n=1), skin burn at the RFA site (n=1), pleural effusion (n=1), severe abdominal pain (n=1), prolonged ileus (n=1), and urinary tract infection (n=2). In the surgical group, 13 patients had 16 complications, including intrahepatic hepatic artery pseudoaneurysm (n=1), thrombosis of the main lobar portal vein (n=1), ascites requiring treatment (n=3), cardiac arrhyth-

©2007 American Medical Association. All rights reserved.
Downloaded From: http://archsurg.jamanetwork.com/ on 10/25/2014

Table 3. Treatment Data, Morbidity, and Mortality for Small HCC

Characteristic	Percutaneous Approach (n=92)	Surgical Approach (n=63)	*P* Value
No. of tumors ablated, No. (%)			.02
1	75 (82)	51 (80)	
2	16 (17)	6 (10)	
3	1 (1)	6 (10)	
Tumor size, cm, mean (SD)	1.9 (0.6)	2.2 (0.6)	.01
Total ablation duration, min, mean (SD)	16 (8)	19 (13)	.15
Day 7 post-RFA albumin level, g/dL, mean (SD)	3.6 (0.4)	3.3 (0.5)	<.001
Day 7 post-RFA bilirubin level, mg/dL, mean (SD)	1.1 (0.5)	1.4 (0.8)	.01
Day 7 post-RFA indocyanine green retention rate at 15 min, %, mean (SD)	20.4 (17.2)	22.6 (15.4)	.45
Postoperative complication, No. (%)	5 (5.4)	13 (21)	<.001
ICU stay, d, No. (%)	0	4 (6)	.04
Hospital stay, d, mean (SD)	2.8 (2.0)	6.5 (4.8)	<.001
Hospital mortality, No. (%)	0	0	NA

Abbreviations: HCC, hepatocellular carcinoma; ICU, intensive care unit; NA, not applicable; RFA, radiofrequency ablation.

SI conversion factors: To convert albumin to grams per liter, multiply by 10; bilirubin to micromoles per liter, multiply by 17.104.

Table 4. Treatment Data, Morbidity, and Mortality for Medium HCC

Characteristic	Percutaneous Approach (n=25)	Surgical Approach (n=48)	*P* Value
No. of tumors ablated, No. (%)			.21
1	23 (92)	37 (77)	
2	2 (8)	7 (15)	
3	0	4 (8)	
Tumor size, cm, mean (SD)	3.6 (0.4)	3.9 (0.5)	.03
Total ablation duration, min, mean (SD)	17 (11)	22 (15)	.10
Day 7 post-RFA albumin level, g/dL, mean (SD)	3.3 (0.4)	3.3 (0.5)	.68
Day 7 post-RFA bilirubin level, mg/dL, mean (SD)	1.6 (0.9)	1.9 (4.1)	.72
Day 7 post-RFA indocyanine green retention rate at 15 min, %, mean (SD)	27.7 (16.6)	20.8 (16.0)	.16
Postoperative complication, No. (%)	6 (24)	5 (10.4)	.17
ICU stay, d, No. (%)	1 (4)	3 (6)	.85
Hospital stay, d, mean (SD)	3.3 (4.3)	6.5 (3.7)	<.001
Hospital mortality, No. (%)	0	0	NA

Abbreviations: See Table 3.

SI conversion factors: See Table 3.

mias (n=2), chest infection (n=3), pleural effusion (n=2), atelectasis (n=1), renal failure (n=1), unexplained sepsis (n=1), and wound infection (n=1). There was no treatment-related mortality in either group. The proportion of patients requiring intensive care admission was significantly higher and overall hospital stay was significantly longer in the surgical group.

Table 4 shows the treatment data for patients with medium HCC. Percutaneous RFA was performed under ultrasonographic guidance in all patients, whereas 4 patients underwent laparoscopic RFA in the surgical group.

More patients had multiple tumors ablated in the surgical group, and mean tumor size was also significantly larger compared with the percutaneous group. Postoperative day-7 hepatic function, intensive care admission, and the incidence of postoperative complications were comparable in the 2 groups. In the percutaneous group, 6 patients had 1 complication each, including acute myocardial infarction (n=1), renal failure (n=1), chest infection (n=1), loculated infected collection at the ablation site (n=2), and skin burn at the RFA site (n=1). In the surgical group, 5 patients had 1 complication each, including bile duct stricture (n=1), ascites requiring treatment (n=1), pleural effusion (n=1), atelectasis (n=1), and unexplained chest pain (n=1). There was no treatment-related mortality in either group. Overall hospital stay was significantly longer in the surgical group.

COMPLETE ABLATION RATE AND FOLLOW-UP RESULTS

Table 5 shows the follow-up data of patients with small HCC. Overall, complete tumor ablation was achieved in 95% of patients in both the percutaneous and surgical groups after a single session of RFA. In the percutaneous group, 4 patients had residual tumors at the ablated site detected by 1-month post-RFA CT scan and were considered to have had incomplete tumor ablation. In addition, another 8 patients had new tumors distant from the ablation site at 1 month post-RFA CT scan; the tumors were either missed by imaging at the time of initial ablation or represented disease progression post-RFA. These patients were retreated with RFA (n=8) or chemoembolization (n=3), except for 1 patient with multiple tumors deemed not suitable for further treatment. Similarly, 3 patients in the surgical group had incomplete tumor ablation, while another 5 patients had new tumors at 1 month post-RFA CT scan. Retreatment was performed in 7 patients, including RFA in 3 patients and chemoembolization in 4 patients. One patient could not be treated further because of poor liver function.

Table 5. Complete Ablation Rate, Recurrence, and Follow-up in Patients With Small HCC[a]

Characteristic	Percutaneous Approach (n=92)	Surgical Approach (n=63)	*P* Value
Complete ablation rate	88 (95)	60 (95)	>.99
Recurrence during follow-up	33 (36)	26 (41)	.50
Intrahepatic recurrence	32 (35)	26 (41)	.49
Local	12 (13)	6 (9.5)	
Distant	24 (26)	24 (38)	
Extrahepatic metastasis	3 (3.2)	7 (11)	.17
Lungs	3 (3.2)	5 (8)	
Bone	0	1 (1.6)	
Lymph node	0	1 (1.6)	

[a] Data are expressed as number of patients (percentage).

After a mean follow-up of 19 months, 33 patients (36%) in the percutaneous group and 26 patients (41%) in the

©2007 American Medical Association. All rights reserved.
Downloaded From: http://archsurg.jamanetwork.com/ on 10/25/2014

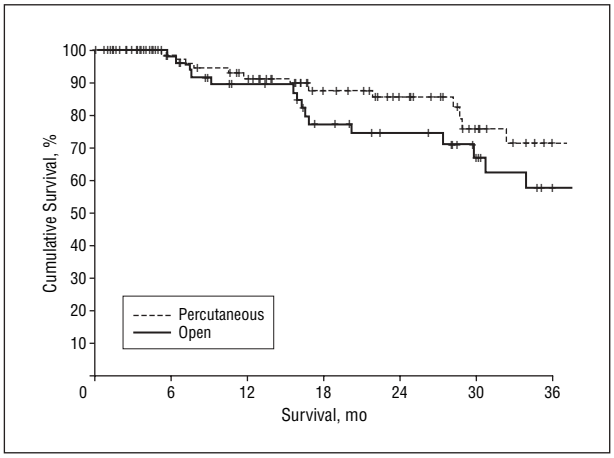

Figure 1. Overall survival for small hepatocellular carcinoma (tumor size ≤3 cm) (*P*=.30).

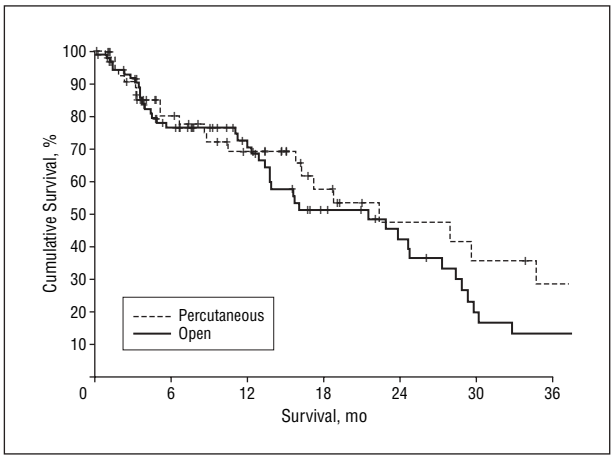

Figure 2. Disease-free survival for small hepatocellular carcinoma (tumor size ≤3 cm) (*P*=.21).

Table 6. Complete Ablation Rate, Recurrence, and Follow-up in Patients With Medium HCC[a]

Characteristic	Percutaneous Approach (n=25)	Surgical Approach (n=48)	*P* Value
Complete ablation rate	24 (95)	44 (92)	.65
Recurrence during follow-up	13 (52)	23 (48)	.46
Intrahepatic recurrence	13 (52)	21 (44)	.62
Local	2 (8)	6 (12.5)	
Distant	13 (52)	17 (35)	
Extrahepatic metastasis	3 (12)	3 (6)	.11
Lungs	2 (8)	1 (2)	
Bone	1 (4)	1 (2)	
Adrenal gland	0	1 (2)	

Abbreviation: HCC, hepatocellular carcinoma.
[a] Data are expressed as number of patients (percentage).

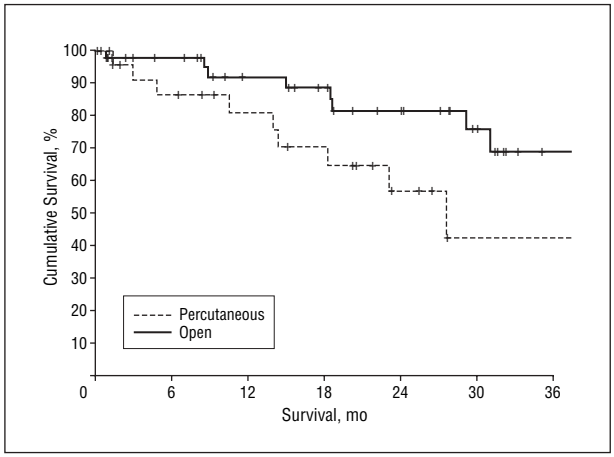

Figure 3. Overall survival for medium hepatocellular carcinoma (tumor size 3.1-5 cm) (*P*=.03).

surgical group developed recurrence (*P*=.50). Table 5 shows similar distribution of recurrent HCC in both groups.

The 1-year and 3-year overall survival rates were 91% and 71%, respectively, in the percutaneous group, and 89% and 57%, respectively, in the surgical group (*P*=.30) (**Figure 1**). The 1-year and 3-year disease-free survival rates were 52% and 33%, respectively, in the percutaneous group and 52% and 22%, respectively, in the surgical group (*P*=.21) (**Figure 2**).

Table 6 shows the follow-up data of patients with medium HCC. The complete tumor ablation rate was 95% in the percutaneous group and 92% in the surgical group after a single session of RFA (*P*=.65). One patient in the percutaneous group had incomplete ablation of the initial tumor, whereas another 3 patients had new tumors at 1 month post-RFA CT scan. Further treatment of residual tumors was offered in 3 patients and consisted of repeated RFA in 1 patient and chemoembolization in 2 patients. The remaining patient was not treated because of poor liver function. Similarly, 4 patients in the surgical group had incomplete tumor ablation, while another patient was found to have a new tumor. All patients underwent retreatment with repeated RFA (n=2), chemoembolization (n=1), hepatic resection (n=1), or ethanol injection (n=1).

After a mean follow-up of 18 months, 13 patients (52%) in the percutaneous group and 23 patients (48%) in the surgical group developed recurrence (*P*=.46). There was a trend toward a higher incidence of intrahepatic recurrence (52% vs 44%) and distant metastases (12% vs 6%) with percutaneous RFA, but the difference was not statistically significant. Table 6 shows the distribution of recurrent HCC in both groups.

The 1-year and 3-year overall survival rates were 81% and 42%, respectively, in the percutaneous group, significantly worse than those of 92% and 68%, respectively, in the surgical group (*P*=.03) (**Figure 3**). There was also a trend toward higher 1-year and 3-year disease-free survival rates in the surgical group (54% and 19%, respectively) compared with the percutaneous group (29% and 0%, respectively) (*P*=.35) (**Figure 4**).

COMMENT

Radiofrequency ablation has gained much enthusiasm in the modern management of unresectable liver tumors. The main advantages of RFA include low morbidity and mortality, effective tumor ablation in few treatment sessions, and preservation of maximal normal liver paren-

©2007 American Medical Association. All rights reserved.
Downloaded From: http://archsurg.jamanetwork.com/ on 10/25/2014

chyma. This is particularly important for patients with HCC, who often have limited functional liver reserve as a result of underlying cirrhosis. Radiofrequency ablation has been shown by prospective randomized trials to be superior to ethanol injection for treatment of HCC.[31-33]

Radiofrequency ablation for HCC can be performed by percutaneous or surgical approaches, with advantages and disadvantages to each approach. The percutaneous approach is the least invasive, and it can be performed as an outpatient procedure with a short hospital stay and low cost. However, it is associated with lower accuracy in cancer staging, poor accessibility in certain areas of the liver, and risk of injury to surrounding organs. The advantages of the open surgical approach include better cancer staging with intraoperative ultrasonography, accessibility to tumors in all areas, and avoidance of adjacent organ injury. The ability to palpate the tumor and mobilize the liver to allow an optimum position for electrode insertion are also advantages of the open approach that might increase the accuracy of ablation. The main limitations of the open approach are its invasiveness, with increased morbidity and longer hospital stay and recovery time. The laparoscopic approach is less invasive but it achieves similar objectives as the open approach. Hence, we included a small number of cases of laparoscopic RFA in the surgical group for analysis. Currently, available laparoscopic ultrasound probes and RFA electrodes are not adequately flexible. Technical difficulty in treating tumors at the dome and in deep locations limited the use of the laparoscopic approach to a small proportion of patients in our series.

A recent meta-analysis suggests that open RFA may be superior in achieving local tumor control compared with the percutaneous approach.[29] However, the authors did not consider the approach performed in relation to the size of the tumor. In the present study, we analyzed the impact of the RFA approach in relation to tumor size in patients with HCC.

The first large clinical experience with RFA was reported by Rossi et al.[34] They used the percutaneous RFA approach for patients with HCC, including some with resectable tumors. Their results in 39 patients were encouraging: only 1 minor complication, 5% local recurrence, and 40% 5-year survival. A growing body of literature in recent years suggests that RFA is a safe and effective approach for small unresectable HCC.[10-14] The results of our current study also suggest that in patients with small HCC, a similar complete tumor ablation rate, overall survival, and disease-free survival can be achieved by either the percutaneous or surgical approaches. However, the incidence of postoperative complications, postoperative hepatic dysfunction, intensive care unit stay, and duration of total hospital stay were significantly higher with the surgical approach. These results indicate that the "trauma of access" is a significant factor of morbidity in patients with small HCC. For patients with small HCC, our data suggest that the percutaneous approach is preferred, and the surgical approach should be selected only when the percutaneous route is not feasible.

Recent advances in RFA technology have enabled clinicians to use RFA for larger tumors.[18-20] There is controversy regarding the choice of approach for HCC larger than 3 cm in diameter.[25,29] Many recent studies have suggested

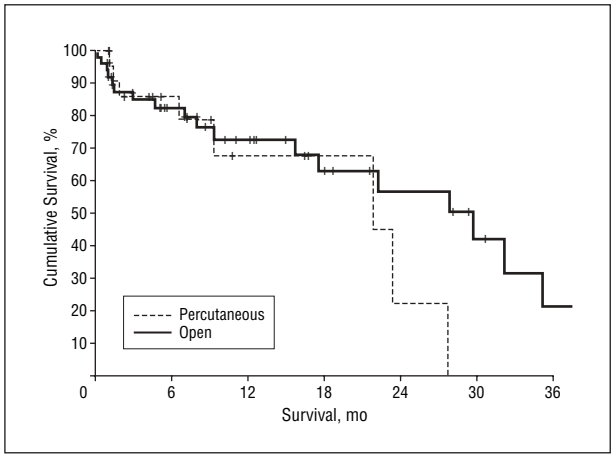

Figure 4. Disease-free survival for medium hepatocellular carcinoma (tumor size 3.1-5 cm) (P=.35).

that percutaneous RFA is safe and technically feasible for medium and large HCC, but there is a lack of data on the long-term survival of patients with HCC treated with percutaneous RFA in comparison with the surgical approach. In a study by Livraghi et al,[18] 114 patients with medium or large HCC underwent percutaneous RFA using cool-tip electrodes. Despite a low incidence of major complications, the complete tumor ablation rate was only 47%. Tumor size and morphology were the determinants of treatment failure in that study. In a similar study by Guglielmi et al,[19] 53 patients with HCC underwent percutaneous ultrasonography-guided RFA using expandable electrodes. Complete tumor ablation after a single session was 74% and 34% for medium and large HCC, respectively, and was significantly lower than that for small HCC (91%). In a previous study from our institution,[20] the complete ablation rate was 94% for small HCC and 91% for medium and large HCC, but the majority of patients with medium and large HCC received surgical RFA.

In the current study, the complete tumor ablation rate was 95% with the percutaneous approach and 92% with the surgical approach in patients with medium HCC. During the follow-up, there was a trend toward a higher intrahepatic recurrence as well as extrahepatic metastases in the percutaneous group compared with the surgical group. The most important aspect of our results is the long-term survival. The overall 1-year and 3-year survival rates were significantly superior in the surgical group. There was also a trend toward a higher disease-free survival rate in the surgical group.

While the result of the surgical group seemed to be better than the percutaneous group, the disease-free survival for either RFA approach for medium HCC was far from satisfactory. Some of the patients who underwent RFA in this study were potential candidates for liver transplantation. However, they opted for RFA because a cadaveric graft is rarely available in Hong Kong, and the patients either refused to accept a live-donor transplant or they did not have voluntary live donors. In Western countries where cadaveric grafts are more readily available, liver transplantation is definitely a preferred treatment with superior survival results.[8] Instead, RFA may be useful as a bridge therapy for tumor control before a cadaveric graft is available. In this

©2007 American Medical Association. All rights reserved.
Downloaded From: http://archsurg.jamanetwork.com/ on 10/25/2014

study, we included some patients with resectable HCC who were randomized to RFA treatment. The RFA approach in these patients was selected according to tumor site, similar to those with unresectable HCC. Whether RFA can replace resection for small HCC is currently a controversial issue. A nonrandomized prospective study suggested that resection is superior to RFA in long-term survival.[35] However, a recently reported randomized trial showed that RFA can achieve similar long-term overall and disease-free survival compared with resection.[36] Further data from randomized trials, including one that our group is conducting, are needed to clarify the role of RFA vs resection.

The findings of our study are significant in view of the current controversy in the approach for RFA. Nearly all authors agree that tumor size is an important determinant of outcome after RFA, but there is no consensus on the treatment approach in relation to tumor size. There are several advantages of the surgical approach that might contribute to the superior outcome of patients with open RFA of medium HCC in our study. First, the surgical approach allows placement of electrodes without any restriction to ensure an adequate margin on all sides of the tumor, but this may not be feasible with the percutaneous approach because of a narrow intercostal space, as reported by Livraghi et al.[18] Second, even with cluster electrodes, multiple overlapping ablation zones may still be required for medium HCC to ensure an adequate margin, which might be difficult to achieve with a percutaneous approach. The surgical approach allows free insertion of the electrode at different angles, with mobilization of the liver, if necessary. Third, accurate placement of the needle tip in the deep margin of the tumor can sometimes be aided by palpation in superficial tumors in the open approach. Finally, larger tumors more frequently have irregular borders and satellite nodules as compared with small tumors,[18] and these might be better delineated by intraoperative ultrasonography as compared with preoperative imaging.[29,37] All these factors might contribute to a better long-term survival after open RFA even though the initial complete ablation rate appeared similar to that of percutaneous RFA. In the present study, we have not evaluated the efficacy of open vs percutaneous RFA for tumors greater than 5 cm. The indication for RFA for such large tumors is still controversial, and our experience with RFA in HCC greater than 5 cm is limited to 12 cases, all performed using the open approach. The low complete ablation rate for percutaneous RFA for such tumors reported in the literature[18,19] suggests that RFA should be performed using the surgical approach.

The results of our study suggest that tailoring the appropriate surgical approach on a patient-by-patient basis in relation to tumor size, number, anatomical location, and morphology is warranted. In the light of the results of our study, the percutaneous approach is still recommended for small HCC. For medium HCC, however, the surgical approach achieved a better long-term survival and may be the preferred approach if patients can tolerate the trauma of surgical access. The incidence of postoperative complications and hepatic dysfunction after RFA with the surgical approach was comparable with that of the percutaneous approach in patients with medium HCC, indicating that trauma of access becomes less important as the volume of tumor ablation increases. The search for minimally invasive techniques is laudable, especially if it improves the short-term outcome without compromising cure. However, in patients with malignant diseases, long-term survival and cure are more important than invasiveness and immediate morbidity. This should also be the guiding principle in choosing an RFA approach for patients with HCC.

Our current study is not a randomized trial, and the results of our study should be viewed in terms of their weaknesses. Among the patients with medium HCC, the surgical group was younger than the percutaneous group and the mean tumor size was significantly higher in the surgical group, reflecting a selection bias. Nonetheless, despite having bigger tumor size, the surgical group had better long-term survival, suggesting that this approach achieves superior tumor control. To our knowledge, this is the first study that highlights the impact of treatment approach in relation to tumor size on the long-term survival of patients with HCC.

In conclusion, our study suggests that the percutaneous route is the preferred approach for RFA for small HCC. It results in a similar complete tumor ablation rate and overall and disease-free survival as the surgical approach but with a lower complication rate and shorter hospital stay. For medium HCC, the surgical approach seems to achieve better tumor control and overall survival and may be the preferred approach if the patient can safely tolerate the procedure. Further studies with randomized trials are required to validate the results of our current study.

Accepted for Publication: June 3, 2006.
Correspondence: Ronnie T. P. Poon, MS, Department of Surgery, The University of Hong Kong, Queen Mary Hospital, 102 Pokfulam Rd, Hong Kong, China (poontp@hkucc.hku.hk).
Author Contributions: *Study concept and design:* Khan, Poon, Ng, Chan, Yuen, Tung, Tsang, and Fan. *Acquisition of data:* Khan and Poon. *Analysis and interpretation of data:* Khan and Poon. *Drafting of the manuscript:* Khan. *Critical revision of the manuscript for important intellectual content:* Poon, Ng, Chan, Yuen, Tung, Tsang, and Fan. *Statistical analysis:* Khan. *Study supervision:* Poon and Fan.
Financial Disclosure: None reported.
Funding/Support: This study was supported by Sun C. Y. Research Foundation for Hepatobiliary and Pancreatic Surgery of the University of Hong Kong.

REFERENCES

1. Bosch FX, Ribes J, Borras J. Epidemiology of primary liver cancer. *Semin Liver Dis.* 1999;19(3):271-285.
2. Di Bisceglie AM, Rustgi VK, Hoofnagle JH, Dusheiko GM, Lotze MT. NIH conference: hepatocellular carcinoma. *Ann Intern Med.* 1988;108(3):390-401.
3. El-Serag HB, Mason AC. Rising incidence of hepatocellular carcinoma in the United States. *N Engl J Med.* 1999;340(10):745-750.
4. Taylor-Robinson SD, Foster GR, Arora S, Hargreaves S, Thomas HC. Increase in primary liver cancer in the UK, 1979-94. *Lancet.* 1997;350(9085):1142-1143.
5. Poon RT, Fan ST, Lo CM, et al. Improving survival results after resection of hepatocellular carcinoma. *Ann Surg.* 2001;234(1):63-70.
6. Fong Y, Sun RL, Jarnagin W, Blumgart LH. An analysis of 412 cases of hepatocellular carcinoma at a Western center. *Ann Surg.* 1999;229(6):790-799.
7. Ota K, Teraoka S, Kawai T. Donor difficulties in Japan and Asian countries. *Transplant Proc.* 1995;27(1):83-86.
8. Bismuth H, Majno PE, Adam R. Liver transplantation for hepatocellular carcinoma. *Semin Liver Dis.* 1999;19(3):311-322.

©2007 American Medical Association. All rights reserved.
Downloaded From: http://archsurg.jamanetwork.com/ on 10/25/2014

9. Poon RT, Fan ST, Tsang FH, Wong J. Locoregional therapies for hepatocellular carcinoma. *Ann Surg*. 2002;235(4):466-486.
10. Rossi S, Buscarini E, Garbagnati F, et al. Percutaneous treatment of small hepatic tumors by an expandable needle electrode. *AJR Am J Roentgenol*. 1998; 170(4):1015-1022.
11. Livraghi T, Goldberg SN, Lazzaroni S, Meloni F, Solbiati L, Gazelle GS. Small hepatocellular carcinoma. *Radiology*. 1999;210(3):655-661.
12. Francica G, Marone G. Ultrasound-guided percutaneous treatment of hepatocellular carcinoma by radiofrequency hyperthermia with a 'cooled-tip needle': a preliminary clinical experience. *Eur J Ultrasound*. 1999;9(2):145-153.
13. Buscarini L, Buscarini E, Di Stasi M, Vallisa D, Quaretti P, Rocca A. Percutaneous radiofrequency ablation of small hepatocellular carcinoma: long term results. *Eur Radiol*. 2001;11(6):914-921.
14. Lin SM, Shen CH, Lin DY, et al. Cytologic changes in small hepatocellular carcinomas after radiofrequency ablation. *Acta Cytol*. 2002;46(3):490-494.
15. Goldberg SN, Solbiati L, Hahn PF, et al. Large-volume tissue ablation with radio frequency by using a clustered, internally cooled electrode technique: laboratory and clinical experience in liver metastasis. *Radiology*. 1998;209(2):371-379.
16. Lau WY, Leung TW, Yu SC, Ho SK. Percutaneous local ablative therapy for hepatocellular carcinoma. *Ann Surg*. 2003;237(2):171-179.
17. McGhana JP, Dodd GD III. Radiofrequency ablation of the liver: current status. *AJR Am J Roentgenol*. 2001;176(1):3-16.
18. Livraghi T, Goldberg SN, Lazzaroni S, et al. Hepatocellular carcinoma: radiofrequency ablation of medium and large lesions. *Radiology*. 2000;214(3):761-768.
19. Guglielmi A, Ruzzenente A, Battocchia A, Tonon A, Fracastoro G, Cordiano C. Radiofrequency ablation of hepatocellular carcinoma in cirrhotic patients. *Hepatogastroenterology*. 2003;50(50):480-484.
20. Poon RT, Ng KK, Lam CM, Ai V, Yuen J, Fan ST. Effectiveness of radiofrequency ablation for hepatocellular carcinomas larger than 3 cm in diameter. *Arch Surg*. 2004;139(3):281-287.
21. Lam CM, Ng KK, Poon RT, Ai V, Yuen J, Fan ST. Impact of radiofrequency ablation on the management of patients with hepatocellular carcinoma in a specialized centre. *Br J Surg*. 2004;91(3):334-338.
22. Elias D, De Baere T, Smayra T, Ouellet JF, Roche A, Lasser P. Percutaneous radiofrequency thermoablation as an alternative to surgery for treatment of liver tumour recurrence after hepatectomy. *Br J Surg*. 2002;89(6):752-756.
23. Rossi S, Fornari F, Pathies C, Buscarini L. Thermal lesions induced by 480 KHz localized current field in guinea pig and pig liver. *Tumori*. 1990;76(1):54-57.
24. Buscarini L, Fornari F, Rossi S. Interstitial radiofrequency hyperthermia in the treatment of small hepatocellular carcinoma: percutaneous US guidance of an electrode needle. In: Anderegg A, Despland PA, Otto R, Henner H, eds. *Ultraschall Diagnostik 91*. Berlin, Germany: Springer; 1992:218-222.
25. Tanabe KK, Curley SA, Dodd GD, Siperstein AE, Goldberg SN. Radiofrequency ablation: the experts weigh in. *Cancer*. 2004;100(3):641-650.
26. Bernardi G, Roveda L, Trotta F, et al. Radio-frequency thermal ablation of primary hepatic tumors. *Surg Endosc*. 2002;16(suppl 1):S185.
27. Suh S, Won J, Lee D, et al. Radio-frequency ablation of liver metastases: comparison of percutaneous ablation and intraoperative ablation. *J Vasc Interv Radiol*. 2004;15(suppl):S219.
28. Bleicher RJ, Allegra DP, Nora DT, Wood TF, Foshag LJ, Bilchik AJ. Radiofrequency ablation in 447 complex unresectable liver tumors: lessons learned. *Ann Surg Oncol*. 2003;10(1):52-58.
29. Mulier S, Ni Y, Jamart J, Ruers T, Marchal G, Michel L. Local recurrence after hepatic radiofrequency coagulation. *Ann Surg*. 2005;242(2):158-171.
30. Goldberg SN, Charboneau JW, Dodd GD, et al. Working group on image-guided tumor ablation—image-guided tumor ablation: proposal for standardization of terms and reporting criteria. *Radiology*. 2003;228(2):335-345.
31. Ng KK, Lam CM, Poon RT, et al. Porcine liver: morphologic characteristics and cell viability at experimental radiofrequency ablation with internally cooled electrodes. *Radiology*. 2005;235(2):478-486.
32. Shiina S, Teratani T, Obi S, et al. A randomized controlled trial of radiofrequency ablation with ethanol injection for small hepatocellular carcinoma. *Gastroenterology*. 2005;129(1):122-130.
33. Lin SM, Lin CJ, Lin CC, Hsu CW, Chen YC. Randomised controlled trial comparing percutaneous radiofrequency thermal ablation, percutaneous ethanol injection, and percutaneous acetic acid injection to treat hepatocellular carcinoma of 3 cm or less. *Gut*. 2005;54(8):1151-1156.
34. Rossi S, Di Stasi M, Buscarini E, et al. Percutaneous RF interstitial thermal ablation in the treatment of hepatic cancer. *AJR Am J Roentgenol*. 1996;167(3):759-768.
35. Vivarelli M, Guglielmi A, Ruzzenente A, et al. Surgical resection versus percutaneous radiofrequency ablation in the treatment of hepatocellular carcinoma on cirrhotic liver. *Ann Surg*. 2004;240(1):102-107.
36. Chen MS, Li JQ, Zheng Y, et al. A prospective randomized trial comparing percutaneous local ablative therapy and partial hepatectomy for small hepatocellular carcinoma. *Ann Surg*. 2006;243(3):321-328.
37. Wood TF, Rose DM, Chung M, Allegra DP, Foshag LJ, Bilchik AJ. Radiofrequency ablation of 231 unresectable hepatic tumors: indications, limitations, and complications. *Ann Surg Oncol*. 2000;7(8):593-600.

INVITED CRITIQUE

Khan et al are to be commended for their results using RFA, either percutaneously or surgically, for the treatment of small (≤3 cm) and medium (3.1-5 cm) HCC. Their local ablation rate of 92% to 95% using either approach is a testimony to their experience with this modality. They demonstrate that RFA using either approach is equally effective for small lesions, in line with the experience of other groups.[1,2] However, notwithstanding their improved results using a surgical approach, it remains to be seen whether RFA will be as effective for medium tumors. The treatment of HCC requires a multidisciplinary team, such as the Khan et al group, that can provide multimodal forms of therapy, including liver transplantation, an option that, although limited in availability, offers the best chance for a cure in patients with early-stage HCC. Despite the best efforts of Khan et al, their 3-year disease-free survival rates for both techniques, 22% to 33% and 0% to 19% for small and medium lesions, respectively, clearly demonstrate that RFA alone is not an effective primary treatment for HCC. The problem, of course, is not due to treatment failures but rather the development of new lesions elsewhere in the liver or metastasis, indicating that even in the setting of early HCC, RFA addresses neither the problem of new lesions developing in a background of chronic liver inflammation or cirrhosis nor the inherent biological potential of most lesions to spread hematogenously. The role of RFA in the treatment of early-stage HCC continues to be defined (there are ongoing prospective randomized studies assessing whether RFA is just as effective as hepatic resection for small tumors) and evolve, but its use must be guided by the sobering reality that HCC is almost never just a localized disease.

Michael E. deVera, MD
James W. Marsh, MD
T. Clark Gamblin, MD

Correspondence: Dr deVera, Starzl Transplant Institute, University of Pittsburgh, UPMC Montefiore, 7 S 3459 Fifth Ave, Pittsburgh, PA 152113 (deverame@upmc.edu).
Financial Disclosure: None reported.

1. Lin S-M, Lin C-J, Lin C-C, Hsu C-W, Chen Y-C. Randomised controlled trial comparing percutaneous radiofrequency thermal ablation, percutaneous ethanol injection, and percutaneous acetic acid injection to treat hepatocellular carcinoma of 3 cm or less. *Gut*. 2005;54(8):1151-1156.
2. Shiina S, Teratani T, Obi S, et al. A randomized controlled trial of radiofrequency ablation with ethanol injection for small hepatocellular carcinoma. *Gastroenterology*. 2005;129(1):122-130.

©2007 American Medical Association. All rights reserved.
Downloaded From: http://archsurg.jamanetwork.com/ on 10/25/2014