SECTION EDITOR: GRACE S. ROZYCKI, MD

Image of the Month

Bang-Bin Chen, MD; Yu-Wen Tien, MD, PhD; Jaw-Town Lin, MD, PhD; Kao-Lang Liu, MD

A 41-YEAR-OLD OTHERWISE HEALTHY WOMAN had a 1-year history of fatigue and 10-kg weight gain. Her biochemical laboratory study results were normal, and the physical examination findings were unremarkable. Abdominal ultrasonography showed a 3-cm mass in the pancreatic tail. On abdominal magnetic resonance (MR) imaging, a 3 × 2-cm well-demarcated mass was identified within the pancreatic tail revealing hypointensity on T1-weighted and hyperintensity on T2-weighted images compared with the pancreas. After dynamic gadopentetate dimeglumine enhancement, the mass showed heterogeneity and hypervascularity with gradual homogeneous and persistent enhancement (**Figure 1**). The patient opted for removal of the potentially malignant neoplasm and underwent distal pancreatectomy and splenectomy. At surgery, a solid and noninvasive mass embedded within the pancreatic tail was found (**Figure 2**).

Author Affiliations: Departments of Medical Imaging (Drs Chen and Liu), Surgery (Dr Tien), and Internal Medicine (Dr Lin), National Taiwan University Hospital and National Taiwan University College of Medicine, Taipei.

What Is the Diagnosis?

A. Islet cell tumor
B. Solid pseudopapillary tumor of the pancreas
C. Pancreatic adenocarcinoma
D. Intrapancreatic ectopic spleen

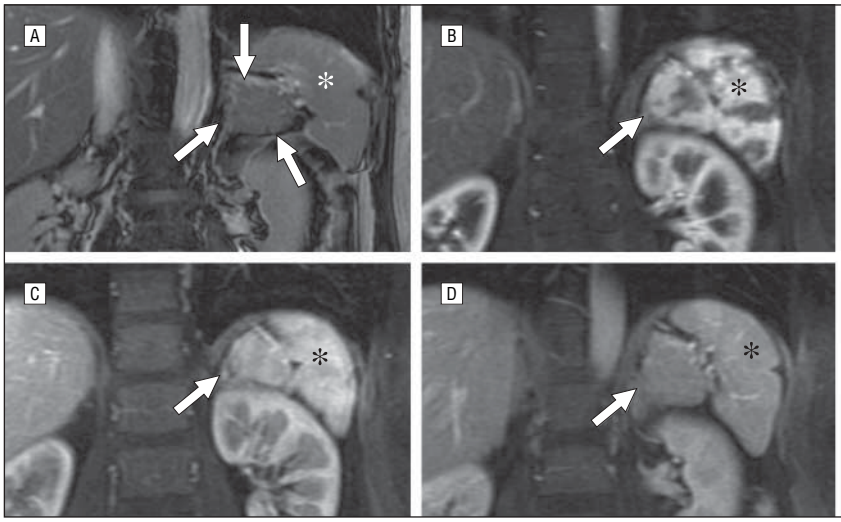

Figure 1. Magnetic resonance imaging findings. A, T2-weighted, balanced, steady-state free precession sequence (repetition time, 4.3 milliseconds; echo time, 2.1 milliseconds; and flip angle, 72°) shows a mass lesion at the pancreatic tail (arrows), with signal intensity similar to that of the surrounding spleen. B-D, Three-dimensional spoiled gradient-echo sequence (repetition time, 3.15 milliseconds; echo time, 1.25 milliseconds; and flip angle, 15°) for a triphasic dynamic enhancement study with administration of gadopentetate dimeglumine reveals the same enhanced pattern of the mass (arrows) and the spleen (*).

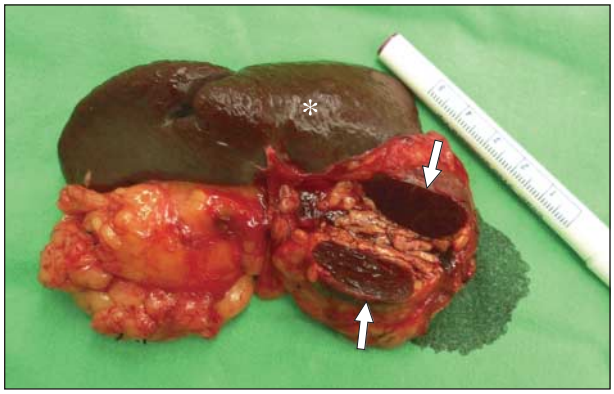

Figure 2. A pathologic specimen obtained by distal pancreatectomy and splenectomy shows the spleen (*), mass (arrows), and pancreatic tail. Ruler is in centimeters.

©2008 American Medical Association. All rights reserved.
Downloaded From: http://archsurg.jamanetwork.com/ on 05/06/2015