ORIGINAL ARTICLE

A Single-Institution Prospective Study of Laparoscopic Pancreatic Resection

Antonio Sa Cunha, MD; Alexandre Rault, MD; Cedric Beau, MD; Cristophe Laurent, MD; Denis Collet, MD; Bernard Masson, MD

Hypothesis: Laparoscopic pancreatic resection can safely duplicate all of the open pancreatic procedures.

Design: A prospective evaluation of laparoscopic pancreatic resection. Surgical procedure, postoperative course, and follow-up data were collected.

Setting: Department of Abdominal Surgery at Haut-Lévêque Hospital, Centre Hospitalier Universitaire de Bordeaux, Bordeaux, France.

Patients: Sixty patients with presumed pancreatic neoplasms. Final diagnoses were benign disease in 57 patients (95%) and malignant pancreatic disease in 3 patients (5%).

Main Outcome Measures: Complication and success rates of resections.

Results: Twenty percent of procedures were switched to open laparotomy. Laparoscopically successful procedures included 20 distal pancreatectomies with spleen preservation, 5 distal splenopancreatectomies, 16 enucleations, 5 medial pancreatectomies, 1 pancreatoduodenectomy, and 1 total pancreatectomy. Postoperative death occurred in 1 patient (1.6%). The overall postoperative complication rate was 36%, including a 13% rate of clinical fistulae. In successful laparoscopic operations, the mean (SD) postoperative hospital stay was 12.7 (6) days. Multivariate, stepwise analysis identified pancreatic consistency and pancreatic resection that required anastomosis as independent factors of postoperative complication ($P = .02$ and $P = .002$, respectively). The 3 patients operated on for pancreatic malignancies were still alive at follow-up (median, 23 months); all patients with benign disease were alive at long-term follow-up.

Conclusions: This series demonstrates that laparoscopic pancreatic resection is not only feasible but also safe. Our study suggests that the best indications for a laparoscopic approach are presumably benign pancreatic tumors not requiring pancreaticoenteric reconstruction.

Arch Surg. 2008;143(3):289-295

THE LAPAROSCOPIC APPROACH has been widely developed and has become the standard technique for several surgical procedures.[1-7] Initially, laparoscopic pancreatic operations were used for staging and palliative treatment of pancreatic neoplasms.[8] In recent years, advances in laparoscopic techniques have allowed surgeons to approach the pancreas and to treat pancreatic lesions laparoscopically. However, laparoscopic pancreatic operations are still uncommon because of the location of the pancreas, technical difficulties of pancreatic resection, the relative rarity of surgical pancreatic disorders, and the need for highly experienced laparoscopic and pancreatic surgeons. The total number of laparoscopic pancreatic resections performed is still small, and reports are often based on limited experience (few series have >10 patients).[9-18] A recently published multi-institutional study described 127 pancreatic resections performed in 27 European centers.[16] In our study, the individual experience of each participating surgeon remained limited. The aim of our prospective study was to determine the feasibility, limitations, safety, and outcome of laparoscopic pancreatic resection in a large single-institution study.

See Invited Critique at end of article

Author Affiliations: Department of Abdominal Surgery, Haut-Lévêque Hospital, Centre Hospitalier Universitaire de Bordeaux, Bordeaux, France.

METHODS

PATIENTS

From January 1999 to February 2006, we performed a prospective evaluation of laparoscopic pancreatic resections in the Depart-

©2008 American Medical Association. All rights reserved.
Downloaded From: http://archsurg.jamanetwork.com/ on 08/20/2014

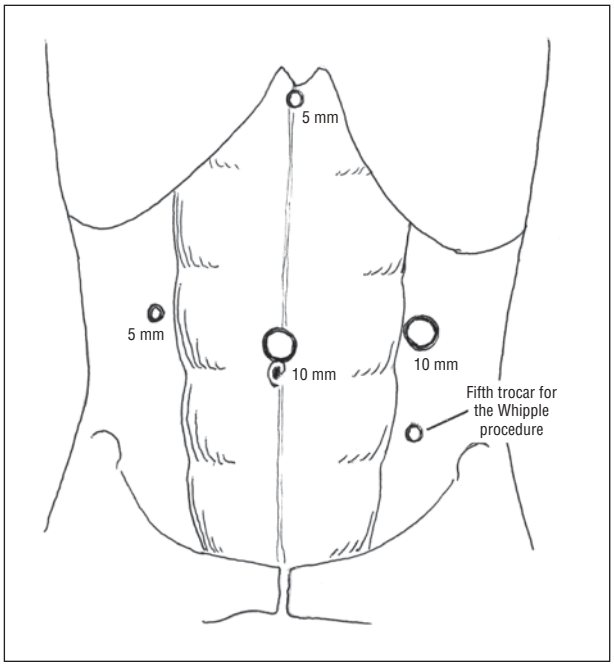

Figure. Trocar placement and incision size for laparoscopic pancreatic resection.

ment of Abdominal Surgery at Haut-Lévêque Hospital, Centre Hospitalier Universitaire de Bordeaux, Bordeaux, France. Sixty patients were included. The inclusion criterion for the laparoscopic approach was having a benign lesion located in the body and/or tail of the pancreas. When lesions were located in the head of the pancreas, laparoscopic approach was planned if an enucleation was possible, according to preoperative assessment. Indications for the laparoscopic approach included presumably benign lesions (56 patients) and malignant lesions (4 patients). Of the 4 patients with malignant lesions, 1 had adenocarcinoma of the ampulla; 1 had a malignant endocrine tumor with bilobar metastases; 1 had metastatic renal cell carcinoma or endocrine tumor (preoperative diagnosis); and 1 had pancreatic ductal adenocarcinoma not confirmed by preoperative biopsies (preoperative diagnosis). Indications for operation were based on clinical symptoms, clinical biochemistry, and radiologic and endoscopic investigation. Preoperative assessment included ultrasonography, computed tomography (CT), magnetic resonance imaging, and endoscopic ultrasonography for characterization and localization of the lesions. For patients with a suspected insulinoma, hyperinsulinism was diagnosed on the basis of the clinical presentation of hypoglycemia, the determination of glucose and insulin serum levels during prolonged fasting up to 72 hours, and the determination of serum C-peptide levels. Factitious causes of hyperinsulinism were ruled out in all patients. For localization of insulinomas, standard preoperative imaging was performed, including CT, magnetic resonance imaging, endoscopic ultrasonography, and octreotide scintigraphy. For patients with suspected endocrine tumors, the preoperative workup was extended to include measures of chromogranin A and serum hormone concentrations.

SURGICAL TECHNIQUE

All the operations were performed by 3 senior surgeons (B.M., A.S., C.L.). Patients are placed supine in a lithotomy position. The surgeon stands between the legs of the patient, with the first assistant and the nurse on the right and left sides of the patient, respectively. Laparoscopic approach requires 4 trocars (**Figure**). First, the body and the tail of the pancreas are exposed through a large window in the gastrocolic ligament by lifting the curvature of the stomach using the trocar close to the xiphoid process. The window may be created using scissors with an electrocautery or ultrasonic device. The window must be large enough to allow inspection beyond the gastroduodenal artery to the hilum of the spleen. For lesions located in the head of the pancreas, a left semilateral decubitus and a fifth trocar is employed. The head of the pancreas can be exposed by dissection of the pancreatic head from the mesocolic and dorsal gastric attachments. The posterior aspect of the head can be inspected after a Kocher maneuver. Then, an ultrasonic examination of the pancreas is performed with a laparoscopic 7-MHz probe. The main use of laparoscopic ultrasonography is 2-fold: to identify the lesion and to plan the placement of the surgical stapler to obtain an acceptable resection margin.

Enucleation

Ultrasonic examination of the pancreas is essential to localize tumors totally covered by a thin layer of pancreatic tissue and to determine if the tumor is close to the pancreatic duct. The dissection is carried out with a 5-mm bipolar electrocoagulation instrument with cautery between the healthy parenchyma and the tumor itself. The vessels of the tumor are secured with clips. The enucleated tumors were located in the body (n=10), tail (n=5), and head (n=3) of the pancreas.

Distal Pancreatectomy

In distal pancreatectomies, the pancreas is dissected from right to left in all patients. The anterior surface of the pancreas is exposed from the neck to the splenic hilum. Then, the inferior and superior edges of the pancreas are dissected to control the splenic vein and artery, respectively. Transection of the pancreatic parenchyma is achieved by endoscopic linear stapling. Selective suture closure of the pancreatic duct is not performed. When planned, we performed a spleen-preserving distal pancreatectomy with or without splenic vessel preservation (a technique invented by Warshaw[19]). In the Warshaw technique, the splenic artery is transected after the pancreas transection; after mobilization of the gland, the splenic artery and vein are clipped and divided as they emerge from the pancreatic tail and enter the splenic hilum. The spleen is kept vascularized through the short gastric vessels and the left gastroepiploic vessels. The last step is the ligation and section of the splenic vein on the left side of the portal vein.

Medial Pancreatectomy

The pancreatic neck is freed from the superior mesenteric vein, the splenomesenteric confluence, and the portal vein. The pancreas is transected with a 60-mm linear stapler on the right side of the lesion. Depending on the extent and/or location of the disease, the pancreatic body can be separated from the splenic vessels by division of both arterial and venous branches. After transection of the pancreas with a bipolar electrocoagulation instrument, a 3- to 4-cm seromuscular incision is made on the posterior gastric wall. Then, the proximal end of the distal pancreatic remnant is anastomosed to the posterior wall of the gastric body in a single layer of 4-0 interrupted polydioxanone sutures, from the pancreatic parenchyma to the gastric seromuscular layer. No pancreatic duct stents were used in any patients. The splenic vessels and the spleen were preserved in all patients. All these steps are done by laparoscopy. Two silicon drains are left close to the ends of both proximal and distal pancreatic remnants in all patients.

©2008 American Medical Association. All rights reserved.
Downloaded From: http://archsurg.jamanetwork.com/ on 08/20/2014

Pancreatoduodenectomy

The dissection and transection phase of the pancreatoduodenectomy was performed laparoscopically in all the patients, whereas the reconstruction phase was accomplished laparoscopically in 1 patient (Whipple procedure) and in another patient (total pancreatectomy) through a minilaparotomy (8 cm). For the Whipple procedure, a pancreatogastrostomy is performed and the pancreatic remnant is anastomosed to the posterior wall of the gastric body in a single layer of 4-0 interrupted polydioxanone sutures, from the mucosal (pancreatic remnant) to the mucosal (gastric) layer. For the Whipple procedure and total pancreatectomy, hepaticojejunostomies were performed with posterior and anterior 5-0 monofilament absorbable suture lines.

In both techniques, the specimen is extracted in an endoscopic plastic bag via an enlarged trocar site. A silicon drain is left in the pancreatic bed to the left of the pancreatic stump. This drain is removed at postoperative day 10. Surgical drainage output is recorded daily, and serum amylase levels and amylase levels of drainage fluid are monitored on postoperative days 5 and 10.

Table 1. Characteristics of Patients Undergoing Pancreatic Resection[a]

Characteristic	No. (%)
Sex	
M	15 (25)
F	45 (75)
Mean age, y	49
ASA score	
I	28 (47)
II	23 (38)
III	9 (15)
Body mass index[b]	
< 25	38 (63)
≥ 25- < 30	17 (28)
≥ 30	5 (8)
Previous abdominal operation	15 (25)

Abbreviation: ASA, America Society of Anesthesiologists.
[a] Percentages may not add up to 100 owing to rounding.
[b] Calculated as weight in kilograms divided by height in meters squared.

DATA COLLECTION

Surgical procedure, postoperative course, and follow-up were examined. The following data were prospectively collected: type and details of the operative procedures, blood loss, postoperative complications, final histologic diagnosis, and hospital stay. Postoperative pancreatic complications were defined by at least 1 of the following criteria: higher than a 5-fold serum amylase level in surgical drainage fluid after postoperative day 5, fluid collection at the surgical margin, or an amylase-rich fluid collection on CT. Pancreatic fistulae were classified according to the new pancreatic classification.[20]

STATISTICAL ANALYSIS

Statistical differences were studied using the χ^2 test with Yates correction for small samples and the *t* test when indicated. Statistical significance was defined as $P < .05$. The effect of independent predictive factors of postoperative complications after laparoscopic pancreatectomy was tested by multivariate logistic regression. The following variables were assessed for significance: patient's age, sex, and American Society of Anesthesiologists physical status score; whether the procedure was performed before or after the first 25 pancreatic resections; pancreatic disease, size, localization, and consistency; type of procedure; procedure with or without anastomosis; operative time; and switch to open laparotomy.

RESULTS

From January 1999 to February 2006, 397 patients underwent pancreatic resection for pancreatic lesions, of whom 60 (15%) were enrolled for laparoscopic pancreatic resection. The mean (SD) patient age was 49 (14) years; 45 (75%) were female. Patient characteristics are reported in **Table 1**.

PATHOLOGY

All patients with serous cystadenoma were symptomatic or appeared macrocystic on preoperative imaging studies, suggesting mucinous cystadenoma. Laparoscopic pancreatic resection for malignancy was planned in 4 patients: 1 patient with adenocarcinoma of the ampulla and 1 patient with malignant neuroendocrine tumor and liver metastases; in the other 2 patients, preoperative diagnoses (metastatic renal cell carcinoma and pancreatic ductal adenocarcinoma) were not confirmed by final histologic findings (endocrine tumor and localized pancreatitis, respectively). One patient (1.6%) had a presumably benign lesion that turned out to be malignant at final pathologic examination (a ductal adenocarcinoma, pT1). All patients with malignant diseases had a disease-free surgical margin at final histologic examination. The mean (SD) tumor size was 37 (37) mm. The lesions were located in the head (4 patients), neck (9 patients), and body and tail (46 patients) of the pancreas. One patient had an intraductal papillary mucinous neoplasm of the whole pancreas.

OPERATIVE FINDINGS

Twenty percent of the laparoscopic pancreatic resections were switched to open laparotomy after exploration. In 5 (8%) patients, laparoscopy was switched to open laparotomy because the surgeon was unable to localize the tumor (n=3) or because the tumor was suspected to be malignant (n=2). After the exploration, 55 laparoscopic procedures were planned, 12.7% of which were switched to open laparotomy. Type of procedures and reasons for conversion after exploration are reported in **Table 2**. One patient with a malignant neuroendocrine tumor and liver metastases had a distal splenopancreatectomy associated with left colonic flexure resection and had 3 tumorectomies and 2 radiofrequency ablations of liver metastases laparoscopically. In the group that underwent laparoscopic distal pancreatectomy without splenectomy, both splenic vessels were preserved in 7 patients. In the other 13 patients, the spleen remained vascularized by the short vessels.

The total median operative time was 210 (range, 60-570) minutes; for the successful laparoscopic opera-

©2008 American Medical Association. All rights reserved.
Downloaded From: http://archsurg.jamanetwork.com/ on 08/20/2014

Table 2. Pancreatic Procedures and Reasons for Switching From Laparoscopic to Open Approaches

Procedure	Procedures to be Performed Laparoscopically, No.	Switches to Open Procedure, No.	Reason for Switch	Successful Laparoscopic Pancreatic Procedures, No. (%)
Pancreatoduodenectomy	1	0		1 (100)
Total pancreatectomy	1	0		1 (100)
Distal pancreatectomy with spleen preservation	25	4	Bleeding (n = 2), length of procedure (n = 1), stapler problem (n =1)	20 (80)[a]
Distal splenopancreatectomy	6	2	Bleeding (n = 1), difficult dissection (n = 1)	5 (83)[a]
Medial pancreatectomy	6	1	Specimen lost	5 (83)
Enucleation	16	0		16 (100)
Total	55	7		48 (87)

[a] One laparoscopic distal pancreatectomy with spleen preservation was successfully switched to laparoscopic distal splenopancreatectomy.

Table 3. Details of Reoperations in Patients Who Underwent Pancreatic Resections

Procedure	Operative Approach	Pancreatic Disease	Cause of Reoperation	Reoperation Day	Death	Hospital Stay, d
Distal pancreatectomy	Open	Mucinous cystadenoma	Hematoma	10	No	50
Distal splenopancreatectomy	Laparoscopy	Insulinoma	Gastric perforation	2	No	24
Distal pancreatectomy	Open	Mucinous cystadenoma	Jejunal perforation	1	No	14
Enucleation	Laparoscopy	Intraductal papillary mucinous neoplasm	Mesenteric ischemia	3	Yes	
Distal pancreatectomy	Laparoscopy	Solid cystic pseudopapillary tumor	Splenic infarction	90	No	10

tions, it was 180 (range, 60-570) minutes; and for procedures switched to open laparotomy, it was 240 (range, 65-360) minutes (P=.007). In the group of totally laparoscopic operations, the median time was 110 (range, 60-228) minutes for enucleation, 200 (range, 90-350) minutes for distal pancreatectomy with spleen preservation, and 246 (range, 153-390) minutes for distal splenopancreatectomy. Operative time was 450 minutes for pancreatoduodenectomy (n=1) and 570 minutes for total pancreatectomy (n=1). The median blood loss was 100 (range, 50-750) mL. Blood loss exceeding 300 mL occurred in 9 patients (15%). Only 1 patient (1.6%) required blood transfusion for postoperative bleeding.

PERIOPERATIVE COMPLICATIONS

Postoperative death occurred in 1 case (1.6%) owing to mesenteric ischemia after tumor enucleation in an arteritic patient. The overall postoperative complication rate was 36%, which is not significantly different from the successful laparoscopic pancreatic resection rate (31%) and the rate of switched procedures (58%). The rate of pancreatic complications was 25% for the whole series (6% for enucleation [grade A, n=1], 45% for distal splenopancreatectomy [grade B, n=2; grade C, n=1], 83% for medial pancreatectomy [grade A, n=3; grade B, n=2], and 20% for distal pancreatectomy [grade A, n=2; grade B, n=2; grade C, n=1]), which is not significantly different from the rate of successful pancreatic resections (21%) and procedures switched from a laparoscopic to an open approach (41%); 1 grade A pancreatic fistula occurred after the Whipple procedure. Pancreatic fistulae were symptomatic in 8 (13%) patients (grade B, n=6; grade C, n=2). In 7 (11%) patients, pancreatic fistulae were asymptomatic (grade A) and were detected by routine assay of amylase level on drainage fluid.[20] For medial pancreatectomies, the origin of pancreatic fistulae was pancreatic proximal stump in 2 patients.

Splenic complications occurred in 3 (17.6%) patients after distal pancreatectomy with spleen preservation without splenic vessels preservation. Two patients presented with pain in the left upper quadrant of the abdomen early in the postoperative period, and CT scans showed partial splenic infarction. Both of these patients were treated with antibiotics. One of the patients was rehospitalized for clinical sepsis, and splenectomy was performed for necrosis of the spleen. The third patient was asymptomatic, and a splenic infarction was diagnosed by means of a routine CT scan. Thus, the final spleen-preservation rate was 88%.

The multivariate, stepwise analysis identified pancreatic consistency (hazard ratio, 0.15; 95% confidence interval, 0.05-0.26; P=.02, Cox proportional hazards regression) and pancreatic resection that required anastomosis (hazard ratio, 0.63; 95% confidence interval, 0.5-0.8; P=.002, Cox proportional hazards regression) as independent factors of postoperative complication. Reoperation was required in 5 (8%) patients (**Table 3**). Gastric perforation was caused by trauma to the posterior gastric wall by forceps. Jejunal perforation, probably due to electrocoagulation injury during dissection of the tumor, occurred after conversion to open laparotomy.

The median postoperative hospital stay was 13 (range, 4-50) days in the whole series. In successful laparoscopic operations, the mean (SD) postoperative hospi-

©2008 American Medical Association. All rights reserved.
Downloaded From: http://archsurg.jamanetwork.com/ on 08/20/2014

tal stay was 12.7 (6) days, which is significantly shorter than in patients requiring conversion to open pancreatectomy (mean [SD], 18.7 [10] days; $P=.02$). Postoperative hospital stay was significantly longer in patients who had pancreatic complications compared with patients without (mean [SD], 11.8 [5.2] days vs 20.3 [9.5] days; $P=.002$).

LONG-TERM OUTCOMES

All patients operated on for benign pancreatic disease were alive at follow-up (median, 20 [range, 2-108] months). One patient operated on for insulinoma still complains of hypoglycemia. In this case, the insulinoma could not be localized during laparoscopic exploration and an open distal pancreatectomy was finally performed owing to the results of preoperative localization tests. The pathologic findings showed nesidioblastosis without any tumor. The 3 patients operated on for pancreatic malignancies were still alive with a median follow-up of 23 (range, 19-28) months. There was a liver tumor recurrence in the patient operated on for malignant neuroendocrine tumor with liver metastases; she was treated with radiofrequency ablation.

COMMENT

Laparoscopic pancreatic resection requires considerable expertise in both pancreatic and laparoscopic surgery, and it seems unreasonable that even an experienced laparoscopist would be able to perform laparoscopic pancreatic resection outside of regular practice of open pancreatic surgery. That being the case, this series reflects the results of a surgical team with past experience in pancreatic and laparoscopic surgery.

The mortality and morbidity rates after either laparoscopic or open pancreatic resection in this series were similar to those reported in the literature.[10,11,13,15-18,21-24] Pancreatic fistulae continue to be a major complication after pancreatic resection, either laparoscopic or open. Pancreatic complications occurred in 25% of the patients in this series and in 19% of distal pancreatectomies and enucleations. Our pancreatic complication rate compares favorably with rates in the literature reported after pancreatic resection (either by laparotomy or laparoscopy), especially considering that 90% of our patients were high risk with soft and friable pancreata and 47% of pancreatic fistulae were grade A.[11,13,16,21,23-25] For medial pancreatectomies, our pancreatic fistula rate is higher than rates reported by others. However, 3 patients had grade A pancreatic fistulae and only 2 (33%) had grade B pancreatic fistulae. In the series of medial pancreatectomies, the definition of pancreatic fistulae is unclear and their occurrence ranges from 0% to 40%, with a global morbidity rate from 0% to 71%. Clearly, medial pancreatectomy is an attractive alternative to more radical resections; however, the current role of medial pancreatectomy remains unclear on account of the early associated morbidity, even by laparotomy.[23,26,27] In our series, pancreatic complications were associated with a significantly prolonged hospital stay; multivariate analysis showed that a pancreaticoenteric reconstruction is the most significant factor affecting the occurrence of postoperative complications. There is a strong argument to be made in favor of restricting laparoscopic pancreatic resection by requiring pancreaticoenteric reconstruction. In laparoscopic left pancreatectomies, the pancreas was most often transected with a stapler. Some authors argue that this could be a cause of pancreatic fistulae. A meta-analysis of the technique used for closing the pancreatic stump after distal pancreatectomy cannot conclusively determine which is best; nevertheless, there is a trend that favors the stapling technique.[28] In our series, the pancreatic stump after distal pancreatectomies was always dealt with by means of stapler application, and symptomatic pancreatic fistulae occurred in only 11% of patients. Therefore, transecting the pancreas by means of a stapler without closing the pancreatic duct appears to be an appropriate technique for distal pancreatectomies. The use of somatostatin analogues for preventing fistulae formation or accelerating this closure has been studied in 10 randomized clinical trials. Despite this, the role of these drugs remains unclear; only 5 studies showed a positive effect, 2 a selective effect, and 3 no benefit whatsoever.[24,28-36] However, a recent meta-analysis has shown that somatostatin analogues reduced morbidity and pancreatic complications.[37] We have never used somatostatin analogues preoperatively.

The median hospital stay in our series was 13 days longer than in other laparoscopic series.[11,13,16,21] This longer hospital stay is due to our policy to continue abdominal drainage until postoperative day 10. According to results of laparoscopic enucleations and distal pancreatectomies, drainage is now discontinued more rapidly to reduce hospital stays. In a previous study, we showed that hospital stays are significantly reduced in patients who underwent totally laparoscopic resections of insulinomas compared with patients who underwent open operations.[38]

In the literature, the most common indication for laparoscopic pancreatic resection was presumably benign pancreatic disease[10-16]; indeed, 95% of patients in our series had this indication. The most common indication was resection not requiring reconstruction (87%), especially resection of lesions on the left side (93% of resections). Enucleations and distal pancreatectomies represent 87% of the present series, with laparoscopic feasibility of 100% and 80%, respectively, in accordance with other series.[9,12,13,15,16,21] In our study, the first laparoscopic pancreatic resection requiring pancreaticoenteric reconstruction was performed after extensive experience with pancreatic resection without reconstruction (26 procedures); this acquired expertise probably explains our laparoscopic success rate of 100% for pancreatic resections with pancreaticoenteric reconstructions. We performed 7 pancreaticogastrostomies (6 medial pancreatectomies and 1 Whipple procedure); pancreatic fistulae due to anastomoses occurred in 4 patients (grade A, n=2; grade B, n=2). The laparoscopic approach remains to be validated in cases in which reconstruction is necessary. Nevertheless, lesions located in the head of the pancreas are harder to approach laparoscopically, often require reconstruction, and are most often malignant. The limited number of patients with pancreatic malignancies in the litera-

©2008 American Medical Association. All rights reserved.
Downloaded From: http://archsurg.jamanetwork.com/ on 08/20/2014

ture and in this series does not allow for determination of laparoscopy's role in the management of these tumors.[13,16,17] Nevertheless, the results of open operations in pancreatic adenocarcinomas suggest that the aim is to increase R0 resections and survival rather than to evaluate the role of laparoscopic surgery. In benign pancreatic diseases, the spleen and the pancreatic parenchyma should be preserved as much as possible.

The incidence of postsplenectomy sepsis is 0.28% to 1.9%, with a mortality rate of 2.2%, and the significance of spleen preservation has come to be recognized widely.[39] However, the question of spleen-preserving distal pancreatectomy is still controversial. In the literature, when a tumor is located in the body or tail of the pancreas, distal splenopancreatectomy has been the most frequently performed procedure. Recently, Lillemoe et al[24] reported the largest series of distal pancreatectomies for a variety of pancreatic disorders, including benign and malignant lesions, and only 16% of those patients had spleen preservation. The low rate of spleen preservation can be explained by (1) the relative technical simplicity of distal pancreatectomy with simultaneous splenectomy compared with procedures of spleen salvage and (2) a higher rate of pancreatic complications in patients who underwent distal pancreatectomy without splenectomy.[40]

According to the series from Memorial Sloan-Kettering Cancer Center,[41] which showed that postoperative complications, septic or not, were significantly more frequent in the splenectomy group (28% and 11%, respectively) compared with the spleen preservation group (9% and 2%, respectively). In our study, we performed open and laparoscopic spleen-preserving pancreatectomies to prevent the potential short- and long-term complications associated with splenectomy; the final spleen-preservation rate was 88%. There were 2 techniques of spleen preservation with or without splenic vessels preservation. The Warshaw[19] technique (without splenic vessels preservation) is faster and less technically demanding than splenic vessels preservation, but it is associated with splenic complications, which are usually managed conservatively.[21] In our study, splenic complications after the Warshaw technique occurred in 17.6% of patients, but only 1 (5%) patient required secondary splenectomy.

Enucleation and medial pancreatectomy are designed to preserve the parenchyma and surrounding structures (eg, duodenum, common bile duct, and spleen) to reduce early and late drawbacks to the operation without compromising long-term survival. Our study showed that parenchyma preservation can be achieved by laparoscopic procedures, demonstrating that medial laparoscopic pancreatectomy is as viable and safe as open operations.[23]

In conclusion, our study demonstrates that laparoscopic pancreatic resection is feasible and safe. However, the best indications for a laparoscopic approach were for presumably benign pancreatic tumors that required pancreatic resections without pancreaticoenteric reconstruction. For presumably benign lesions, the goal of spleen salvage and pancreatic preservation can and must be achieved laparoscopically. In addition, laparoscopy is associated with decreased postoperative pain, reduced trauma to the abdominal wall, smaller incisions, cosmetic advantage, and a quicker return to previous activity in patients. We believe that laparoscopy should become the standard approach in the future to enucleation and distal pancreatectomy of presumably benign lesions. The role of laparoscopy in cases of malignant and cephalic lesions, in light of technical difficulties, oncological results, and postoperative complications, remains undetermined.

Accepted for Publication: November 24, 2006.
Correspondence: Antonio Sa Cunha, MD, Department of Digestive Surgery, Centre Hospitalier Universitaire de Bordeaux, Avenue de Magellan, Pessac 33604, France (antonio.sa-cunha@chu-bordeaux.fr).
Author Contributions: *Study concept and design:* Sa Cunha, Collet, and Masson. *Acquisition of data:* Sa Cunha, Beau, and Laurent. *Analysis and interpretation of data:* Sa Cunha and Rault. *Drafting of the manuscript:* Sa Cunha, Rault, Beau, and Laurent. *Critical revision of the manuscript for important intellectual content:* Sa Cunha, Collet, and Masson. *Statistical analysis:* Sa Cunha and Rault. *Study supervision:* Collet and Masson.
Financial Disclosure: None reported.

REFERENCES

1. Lacy AM, Garcia-Valdecasas JC, Delgado S, et al. Laparoscopy-assisted colectomy versus open colectomy for treatment of non-metastatic colon cancer: a randomised trial. *Lancet*. 2002;359(9325):2224-2229.
2. Khaitan L, Holzman MD. Laparoscopic advances in general surgery. *JAMA*. 2002; 287(12):1502-1505.
3. Senagore AJ. Laparoscopic sigmoid colectomy for diverticular disease. *Surg Clin North Am*. 2005;85(1):19-24, vii.
4. Rullier E, Sa Cunha A, Couderc P, Rullier A, Gontier R, Saric J. Laparoscopic intersphincteric resection with coloplasty and coloanal anastomosis for mid and low rectal cancer. *Br J Surg*. 2003;90(4):445-451.
5. Lesurtel M, Cherqui D, Laurent A, Tayar C, Fagniez PL. Laparoscopic versus open left lateral hepatic lobectomy: a case-control study. *J Am Coll Surg*. 2003;196 (2):236-242.
6. Vibert E, Perniceni T, Levard H, Denet C, Shahri NK, Gayet B. Laparoscopic liver resection. *Br J Surg*. 2006;93(1):67-72.
7. Clinical Outcomes of Surgical Therapy Study Group. A comparison of laparoscopically assisted and open colectomy for colon cancer. *N Engl J Med*. 2004; 350(20):2050-2059.
8. John TG, Greig JD, Carter DC, Garden OJ. Carcinoma of the pancreatic head and periampullary region: tumor staging with laparoscopy and laparoscopic ultrasonography. *Ann Surg*. 1995;221(2):156-164.
9. Gagner M, Pomp A, Herrera MF. Early experience with laparoscopic resections of islet cell tumors. *Surgery*. 1996;120(6):1051-1054.
10. Park AE, Heniford BT. Therapeutic laparoscopy of the pancreas. *Ann Surg*. 2002; 236(2):149-158.
11. Gagner M, Inabnet WB, Biertho L, Salky B. Laparoscopic pancreatectomy: a series of 22 patients. *Ann Chir*. 2004;129(1):2-10.
12. Berends FJ, Cuesta MA, Kazemier G, et al. Laparoscopic detection and resection of insulinomas. *Surgery*. 2000;128(3):386-391.
13. Edwin B, Mala T, Mathisen O, et al. Laparoscopic resection of the pancreas: a feasibility study of the short-term outcome. *Surg Endosc*. 2004;18(3):407-411.
14. Masson B, Sa-Cunha A, Laurent C, et al. Laparoscopic pancreatectomy: report of 22 cases. *Ann Chir*. 2003;128(7):452-456.
15. Shimizu S, Tanaka M, Konomi H, Mizumoto K, Yamaguchi K. Laparoscopic pancreatic surgery: current indications and surgical results. *Surg Endosc*. 2004; 18(3):402-406.
16. Mabrut JY, Fernandez-Cruz L, Azagra JS, et al. Laparoscopic pancreatic resection: results of a multicenter European study of 127 patients. *Surgery*. 2005; 137(6):597-605.
17. Patterson EJ, Gagner M, Salky B, et al. Laparoscopic pancreatic resection: single-institution experience of 19 patients. *J Am Coll Surg*. 2001;193(3):281-287.
18. Dulucq JL, Wintringer P, Stabilini C, Feryn T, Perissat J, Mahajna A. Are major laparoscopic pancreatic resections worthwhile? a prospective study of 32 patients in a single institution. *Surg Endosc*. 2005;19(8):1028-1034.

©2008 American Medical Association. All rights reserved.
Downloaded From: http://archsurg.jamanetwork.com/ on 08/20/2014

19. Warshaw AL. Conservation of the spleen with distal pancreatectomy. *Arch Surg.* 1988;123(5):550-553.
20. Bassi C, Dervenis C, Butturini G, et al. Postoperative pancreatic fistula: an international study group (ISGPF) definition. *Surgery.* 2005;138(1):8-13.
21. Fernández-Cruz L, Martinez I, Gilabert R, Cesar-Borges G, Astudillo E, Navarro S. Laparoscopic distal pancreatectomy combined with preservation of the spleen for cystic neoplasms of the pancreas. *J Gastrointest Surg.* 2004;8(4):493-501.
22. Gagner M, Pomp A. Laparoscopic pancreatic resection: is it worthwhile? *J Gastrointest Surg.* 1997;1(1):20-26.
23. Sauvanet A, Partensky C, Sastre B, et al. Medial pancreatectomy: a multi-institutional retrospective study of 53 patients by the French Pancreas Club. *Surgery.* 2002;132(5):836-843.
24. Lillemoe KD, Kaushal S, Cameron JL, Sohn TA, Pitt HA, Yeo CJ. Distal pancreatectomy: indications and outcomes in 235 patients. *Ann Surg.* 1999;229(5):693-700.
25. Yeo CJ, Cameron JL, Lillemoe KD, et al. Pancreaticoduodenectomy with or without distal gastrectomy and extended retroperitoneal lymphadenectomy for periampullary adenocarcinoma, part 2: randomized controlled trial evaluating survival, morbidity, and mortality. *Ann Surg.* 2002;236(3):355-368.
26. Roggin KK, Rudloff U, Blumgart LH, Brennan MF. Central pancreatectomy revisited. *J Gastrointest Surg.* 2006;10(6):804-812.
27. Efron DT, Lillemoe KD, Cameron JL, Yeo CJ. Central pancreatectomy with pancreaticogastrostomy for benign pancreatic pathology. *J Gastrointest Surg.* 2004;8(5):532-538.
28. Knaebel HP, Diener MK, Wente MN, Büchler MW, Seiler CM. Systematic review and meta-analysis of technique for closure of the pancreatic remnant after distal pancreatectomy. *Br J Surg.* 2005;92(5):539-546.
29. Friess H, Beger HG, Sulkowski U, et al. Randomized controlled multicentre study of the prevention of complications by octreotide in patients undergoing surgery for chronic pancreatitis [erratum published in *Br J Surg.* 1996;83(1):126]. *Br J Surg.* 1995;82(9):1270-1273.
30. Gouillat C, Chipponi J, Baulieux J, Partensky C, Saric J, Gayet B. Randomized controlled multicentre trial of somatostatin infusion after pancreaticoduodenectomy. *Br J Surg.* 2001;88(11):1456-1462.
31. Spitz FR, Abbruzzese JL, Lee JE, et al. Preoperative and postoperative chemoradiation strategies in patients treated with pancreaticoduodenectomy for adenocarcinoma of the pancreas. *J Clin Oncol.* 1997;15(3):928-937.
32. Montorsi M, Zago M, Mosca F, et al. Efficacy of octreotide in the prevention of pancreatic fistula after elective pancreatic resections: a prospective, controlled, randomized clinical trial. *Surgery.* 1995;117(1):26-31.
33. Bassi C, Butturini G, Molinari E, et al. Pancreatic fistula rate after pancreatic resection: the importance of definitions. *Dig Surg.* 2004;21(1):54-59.
34. Sarr MG. The potent somatostatin analogue vapreotide does not decrease pancreas-specific complications after elective pancreatectomy: a prospective, multicenter, double-blinded, randomized, placebo-controlled trial. *J Am Coll Surg.* 2003;196(4):556-565.
35. Shan YS, Sy ED, Lin PW. Role of somatostatin in the prevention of pancreatic stump-related morbidity following elective pancreaticoduodenectomy in high-risk patients and elimination of surgeon-related factors: prospective, randomized, controlled trial. *World J Surg.* 2003;27(6):709-714.
36. Suc B, Msika S, Piccinini M, et al. Octreotide in the prevention of intra-abdominal complications following elective pancreatic resection: a prospective, multicenter randomized controlled trial. *Arch Surg.* 2004;139(3):288-295.
37. Connor S, Alexakis N, Garden OJ, Leandros E, Bramis J, Wigmore SJ. Meta-analysis of the value of somatostatin and its analogues in reducing complications associated with pancreatic surgery. *Br J Surg.* 2005;92(9):1059-1067.
38. Sa Cunha AB, Beau C, Rault C, Catargi A, Collet D, Masson B. Laparoscopic versus open approach for solitary insulinoma. *Surg Endosc.* 2007;21(1):103-108.
39. Holdsworth RJ, Irving AD, Cuschieri A. Postsplenectomy sepsis and its mortality rate: actual versus perceived risks. *Br J Surg.* 1991;78(9):1031-1038.
40. Benoist S, Dugue L, Sauvanet A, et al. Is there a role of preservation of the spleen in distal pancreatectomy? *J Am Coll Surg.* 1999;188(3):255-260.
41. Shoup M, Brennan MF, McWhite K, et al. The value of splenic preservation with distal pancreatectomy. *Arch Surg.* 2002;137(2):164-168.

INVITED CRITIQUE

Throughout the last decade, there have been 2 major trends observed in pancreatic surgery: (1) the increased frequency of detection of pancreatic "incidentalomas" owing to the widespread use of abdominal imaging and (2) the development and refinement of laparoscopic techniques for pancreatic resection. Fortunately, these 2 trends fit nicely together, allowing a minimal access option for the resection of the ever-increasing number of pancreatic neoplasms identified. Because most of these incidental lesions are benign or, at worst, premalignant and most of them occur in women, laparoscopic pancreatic surgery has been embraced at most high-volume pancreatic centers.

This study by Sa Cunha and colleagues is one of the largest series of laparoscopic pancreatic surgery yet reported. The authors describe 60 patients undergoing a variety of surgical resections, including distal pancreatectomy (with or without splenectomy), medial pancreatectomy, tumor enucleation, and even a pancreatoduodenectomy and a total pancreatectomy. Their results reflect both their own learning curve (20% conversion rate) and a relatively high rate of complications, which is comparable with reported series of open pancreatic procedures.

My view is that this series, and many others that have been or will be reported, makes it clear that distal pancreatic resection and enucleation are safe, practical, and offer the traditional advantages of minimal-access surgical techniques. I believe that this series, however, reinforces that resections that require a pancreatic anastomosis are still of questionable value owing to their unacceptably high risk of anastomotic leaks.

Finally, these authors, like others, have performed resections in selected patients with malignant pancreatic tumors. Although these uncontrolled results would appear satisfactory with respect to margin status and lymph node clearance, I hope that my fellow pancreatic surgeons will follow the example set by colorectal surgeons and apply the rigor of a prospective randomized multi-center trial before we get too enthralled with the potential advantages of these techniques for pancreatic malignancies.

Keith D. Lillemoe, MD

Correspondence: Dr Lillemoe, Department of Surgery, Indiana University School of Medicine, 545 Barnhill Dr, Room EH 203, Indianapolis, IN 46202 (klillemo@iupui.edu).
Financial Disclosure: None reported.

©2008 American Medical Association. All rights reserved.
Downloaded From: http://archsurg.jamanetwork.com/ on 08/20/2014