

Image of the Month

Renato Costi, MD, PhD; Nathalie Bataille, MD; Alain Cazaban, MD; Thierry Montariol, MD

AN OTHERWISE HEALTHY 68-YEAR-OLD WHITE man presented with a 4-day history of hyperthermia, a 6/10 dull pain (analogic pain scale) at the right superior abdominal quadrant, and nausea. Physical examination revealed a temperature of 40.1°C and mild right subcostal tenderness without rebound. Laboratory testing

showed a perturbation of hepatic enzymes, an alteration of renal function, and an elevated white blood cell count. Ultrasound revealed the presence of gallbladder stones and of a round hypoechoic image in the fourth hepatic segment 5 cm in diameter; a computed tomographic (CT) scan of the abdomen confirmed the presence of a hypodense image in the liver and revealed the presence of gas in the gallbladder (**Figure 1**).

Author Affiliations: Service de Chirurgie Viscérale Digestive, Urologique et Plastique, Centre Hôpitalier Intercommunal Poissy/Saint-Germain en Laye, site de St Germain-en-Laye, France (Drs Costi, Bataille, and Montariol); Dipartimento di Scienze Chirurgiche, Università di Parma, Parma, Italia (Dr Costi); and Service de Radiologie, CHI Poissy/Saint-Germain en Laye, site de St Germain-en-Laye, France (Dr Cazaban).

What Is the Diagnosis?

- Hepatocellular carcinoma infiltrating the intrahepatic biliary tree
- Cholecystocolonic fistula associated with hepatic abscess
- Echinococcus hydatid associated with acute cholecystitis by anaerobic bacteria
- Posttraumatic hepatic hematoma and pneumobilia

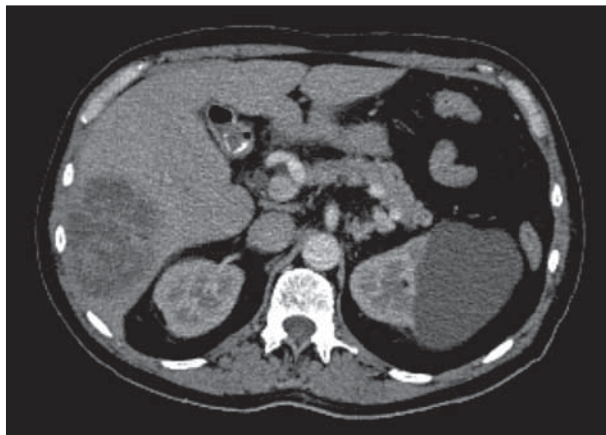


Figure 1. Computed tomographic scan (2-dimensional) of the abdomen shows a 5-cm abscess of fourth hepatic segment associated with pneumobilia.