PAPER

Major Blood Vessel Reconstruction During Sarcoma Surgery

Tae K. Song, MD; E. John Harris Jr, MD; Shyam Raghavan, BS; Jeffrey A. Norton, MD

Objective: To evaluate the outcomes of major vessel reconstruction as part of surgery to remove sarcomas.

Design: Retrospective review.

Setting: Tertiary academic medical center.

Patients: Fourteen patients (10 female) with retroperitoneal or extremity sarcomas and major blood vessel involvement who underwent surgery to remove the tumor and had blood vessel reconstruction between 2003 and 2008. Each patient underwent computed tomography angiography.

Main Outcome Measures: Early (<30 days) and late (>30 days) operative morbidity and mortality, freedom from disease, and graft patency.

Results: Seven patients had retroperitoneal sarcomas and 7, extremity sarcomas. Thirteen tumors were malignant (7 high grade and 6 low grade) and 1, benign (leiomyoma). Seven patients had replacement of artery and vein; 5, artery only; and 2, vein only. In all, 16 arteries were reconstructed (2 common femoral; 5 iliac; 2 superficial femoral; 1 brachial; 1 popliteal; and 2 aorta, one with implantation of both iliac arteries and the other with implantation of the left renal, superior mesenteric, and hepatic arteries). Eight patients (57%) had 9 veins reconstructed (3 external iliac, 3 superficial femoral, 2 vena cava, and 1 popliteal). Primary arterial patency was 58% and primary-assisted patency was 83%. Venous patency was 78%. Local recurrence occurred in 3 patients (21%). Five-year disease-free and overall survival were 52% and 68%, respectively. Limb salvage was achieved in 93%.

Conclusion: Involvement of vascular structures is not a contraindication for resection of sarcomas, but appropriate planning is necessary to optimize outcome.

Arch Surg. 2009;144(9):817-822

Surgical resection is the only potentially curative therapy for soft tissue sarcomas. For retroperitoneal sarcomas, involvement of major vessels has traditionally been a relative contraindication for resection because of poor prognosis and high surgical risk.[1,2] Likewise, historical local control of an extremity sarcoma was achieved by amputation.[3,4] More recently, standard therapy for resection of soft tissue sarcomas of the extremity is limb preservation surgery and radiotherapy.[3-6] The goal of resection is to obtain negative surgical margins.[3] Often the ability to completely remove the tumor is affected by its relationship to major blood vessels. This serves as a major factor in determining the "resectability" of sarcomas.

This study reviews our experience with blood vessel reconstruction as an integral part of surgery to remove soft tissue sarcomas. Further, venous reconstruction was a major component of the vascular reconstruction in this series. Very few previous studies have investigated the role of venous reconstruction in sarcoma surgery.[4,6] We hypothesize that arterial and venous involvement of soft tissue sarcomas is not a contraindication to sarcoma resection.

METHODS

This was a retrospective review at a tertiary academic medical center using a multidisciplinary team approach for the treatment of patients with soft tissue sarcomas. The team included a vascular surgeon, surgical oncologist, orthopedic surgeon, medical oncologist, and radiation oncologist. Fourteen consecutive, prospective patients (4 male, 10 female) were treated between September 2003 and December 2008. All patients with soft tissue sarcomas who required vascular reconstruction for curative resection and/or limb-preserving resection were included. Vascular reconstruction was necessary when a soft tissue sarcoma encased or invaded an adjacent major vessel. Each patient underwent a preoperative computed tomography angiogram and prospectively met with the vascular surgeon to assess resectability and plan vas-

Author Affiliations: Divisions of Vascular Surgery (Drs Song and Harris) and General Surgery (Dr Norton), Department of Surgery, and School of Medicine (Mr Raghavan), Stanford University, Stanford, California.

©2009 American Medical Association. All rights reserved.
Downloaded From: http://archsurg.jamanetwork.com/ on 10/26/2016

cular reconstruction. All patients had chest computed tomography to diagnose pulmonary metastases.

Main outcome measures were early (<30 days) and late (>30 days) operative morbidity and mortality, disease-free and overall survival, and assessment of graft patency. Secondary outcome measures included reinterventions.

Patients were seen in the vascular clinic at 4 weeks, 6 months, and yearly thereafter. In addition, patients were assessed in the oncology clinic as part of routine surveillance. Clinical examinations and duplex ultrasonography or computed tomography angiography/magnetic resonance angiography follow-up examinations evaluating tumor recurrence were used to assess patency of the arterial or venous reconstructions. Patient survival was confirmed through either clinic visits or direct communication by telephone.

Approval for this study was obtained from the Stanford University institutional review board. Statistical analysis was performed using Microsoft Excel software (Microsoft Inc, Redmond, Washington). Kaplan-Meier estimations were used to analyze overall and disease-free survival and arterial and venous patency from the time of surgery.

Table 1. Patient Demographics

Characteristic	No. (%) (N=14)
Male	4 (29)
Female	10 (71)
Age <50 y	8 (57)
ASA score <3	13 (93)
CAD	1 (7)
PVD	0
Retroperitoneal	7 (50)
Extremity	7 (50)
Tumor grade	
Low	6 (43)
Intermediate	1 (7)
High	6 (43)

Abbreviations: ASA, American Society of Anesthesiologists; CAD, coronary artery disease; PVD, peripheral vascular disease.

Table 2. Type of Vascular Reconstruction

	No. (%)		
Type	Extremity (n=7)	Retroperitoneal (n=7)	Total (N=14)
Artery and vein	5	2	**7** (50)
Artery	2	3	**5** (36)
Vein	0	2	**2** (14)

RESULTS

Fourteen patients (4 male, 10 female) with major vascular involvement were treated for soft tissue sarcomas of the extremity (7) or retroperitoneum (7) (**Table 1**). Median age was 45 years (range, 11-80 years). One patient had significant medical comorbid conditions (American Society of Anesthesiologists score < 3, 93%), 1 patient had coronary artery disease, and no patients had peripheral vascular disease. Preoperative median creatinine value was 0.75 mg/dL (to convert to micromoles per liter, multiply by 88.4) for all patients and 1.0 mg/dL for patients with retroperitoneal sarcomas. Symptoms were abdominal or extremity pain or an enlarging mass. Patients required replacement of both artery and vein (7), artery only (5), or vein only (2) at the time of sarcoma resection (**Table 2**).

Surgery was performed for a primary mass (9) or recurrent mass (5), with 2 patients having lung metastasis at the time of surgical resection. Average tumor size was 14 cm (range, 6-29 cm), with 10 patients (71%) having sarcomas more than 10 cm. Diagnoses included malignant fibrous histiocytoma (2), leiomyosarcoma (2), malignant peripheral nerve sheath tumor (1), liposarcoma (1), fibromyxoid sarcoma (1), synovial sarcoma (2), chondrosarcoma (1), and desmoid (3). One patient had a "benign" tumor that invaded the inferior vena cava (leiomyoma) (**Table 3**). Four patients with retroperitoneal sarcomas had positive margins and 2 with extremity sarcomas had close 1-mm margins (Table 3). Two patients with retroperitoneal sarcomas had intraoperative radiation. Two patients received upfront chemoradiation therapy prior to undergoing repeated surgery for a re-

Table 3. Sarcoma Characteristics and Adjuvant Treatment

Pathohistology	Size, cm	Site	Margin	Adjuvant Treatment
Malignant PNST	22	R	Positive	IORT[a]
Malignant fibrous histiocytoma	7	R	Negative	Chemotherapy
Malignant fibrous histiocytoma	15	E	Negative	None
Leiomyosarcoma	12.5	R	Negative[b]	Chemotherapy
Leiomyosarcoma	9.5	R	Positive[c]	IORT + Chemotherapy/XRT
Liposarcoma	29	R	Positive[c]	Chemotherapy/XRT[a]
Fibromyxoid sarcoma	18	R	Positive	None
Synovial sarcoma	15	E	Negative	Chemotherapy
Synovial sarcoma	6.5	E	Negative	None
Chondrosarcoma	6.8	R	Negative	Chemotherapy/XRT[a]
Desmoid	13	E	Negative	None
Desmoid	17	E	Negative[c]	None
Desmoid	12	E	Negative[b]	None
Leiomyoma	11	R	Negative	None

Abbreviations: E, extremity; IORT, intraoperative radiation therapy; PNST, peripheral nerve sheath tumor; R, retroperitoneal; XRT, radiation therapy.
[a] Planned but did not receive.
[b] Negative margins less than 1 mm.
[c] Recurrence.

©2009 American Medical Association. All rights reserved.
Downloaded From: http://archsurg.jamanetwork.com/ on 10/26/2016

Table 4. Vascular Reconstructions of Involved Vessels

Vessel	No. of Reconstructions (N=25)
Aorta	2
Viscera	3
Iliac	5
Common femoral artery	2
Superficial femoral artery	2
Popliteal artery	1
Brachial artery	1
Vena cava	2
Iliac vein	3
Femoral vein	3
Popliteal vein	1

Table 5. Conduits Used in Vascular Reconstructions

Type	No. (%) (N=29)
Primary	2 (7)
Saphenous vein	12 (41)
Femoral vein	3 (10)
Polyethylene terephthalate	8 (28)
PTFE	1 (3)
Allograft	3 (10)

Abbreviation: PTFE, polytetrafluoroethylene.

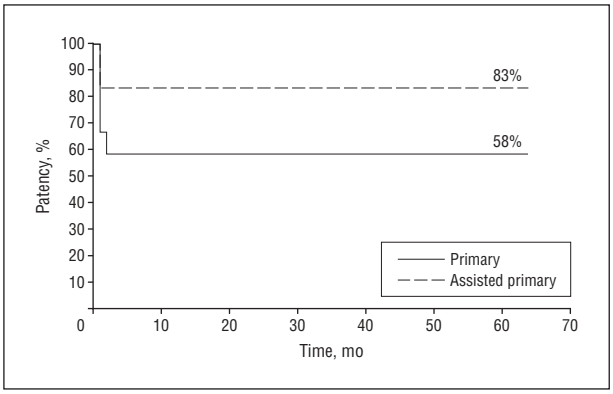

Figure 1. Primary and assisted-primary patency of arterial reconstructions.

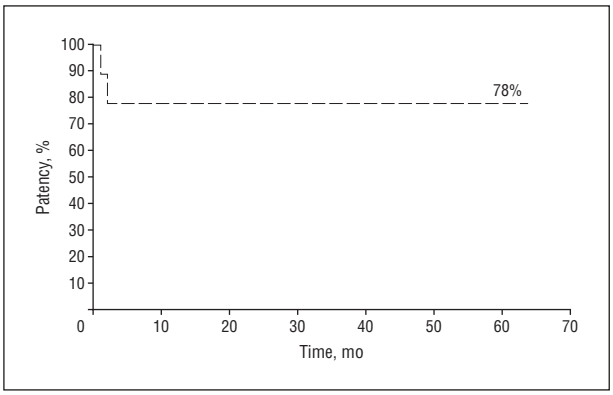

Figure 2. Patency of venous reconstructions.

current mass. Adjuvant chemoradiation therapy was planned for 7 patients (2 extremity and 5 retroperitoneal), of whom 3 patients did not receive therapy because of the presence of an open wound or death (2).

ARTERIAL RECONSTRUCTIONS

Twelve patients (86%) had reconstruction of a major artery and 2 patients (14%) required reconstruction of more than 2 arteries (**Table 4**). In all, 16 arteries were reconstructed (2 common femoral; 5 iliac; 2 superficial femoral; 1 brachial; 1 popliteal; and 2 aorta, one with implantation of both iliac arteries and the other with implantation of the left renal, superior mesenteric, and hepatic arteries) along with 3 repeated arterial interventions. The arteries were reconstructed using saphenous vein (8), polyethylene terephthalate (8), polytetrafluoroethylene (PTFE) (1), femoral vein (1), or primary repair (2) (**Table 5**). In general, autologous conduits were preferred to reduce infection and prior to intended chemoradiation therapy. Polyethylene terephthalate was often used in aortic or iliac reconstructions based on size compatibility and surgeon preference. Systemic heparinization was administered during vascular reconstruction but no additional postoperative anticoagulation other than aspirin was prescribed. Using Kaplan-Meier estimates, arterial primary patency was 58% and primary-assisted patency was 83% at 65 months (mean follow-up, 18.4 months; range, 3-64 months) (**Figure 1**).

VENOUS RECONSTRUCTIONS

Eight patients (57%) had major venous reconstruction. In all, 9 major veins were reconstructed (3 external iliac, 3 superficial femoral, 2 vena cava, 1 popliteal) (Table 4). The veins were reconstructed using saphenous vein (4), femoral vein (2), and allograft (3) (Table 5). There were 2 vena cava reconstructions. A large, high-grade liposarcoma (29 cm) was found to encase the inferior vena cava, right kidney, and right ureter, and there was thrombus extension in the cava to the level of the renal veins. En bloc resection was performed with venous reconstruction using an aortic homograft. Unfortunately, the patient experienced intra-abdominal bleeding in the immediate postoperative period requiring transfusion of blood products and the administration of factor VII. The vena cava reconstruction thrombosed as demonstrated on venogram and was not reintervened because well-established venous collaterals were present. The other vena cava reconstruction was performed for a benign leiomyoma with intracaval extension. The inferior vena cava was replaced using femoral vein and remained patent after 28 months with no recurrence. Also, a popliteal vein reconstruction thrombosed within 30 days and was not repaired. The remainder of the venous reconstructions remained patent. The Kaplan-Meier estimate of venous patency was 78% at 65 months (mean follow-up, 18.4 months; range, 3-64 months) (**Figure 2**).

MORBIDITY AND MORTALITY

Wound infection and dehiscence occurred in 5 patients with extremity sarcomas. Each of the wound dehiscences occurred in patients reconstructed with saphenous vein grafts.

©2009 American Medical Association. All rights reserved.
Downloaded From: http://archsurg.jamanetwork.com/ on 10/26/2016

Table 6. Morbidity

Type	No. (%)
Wound dehiscence	5 (36)
Graft infection	2 (14)
Graft thrombosis	4 (29)
Amputation	1 (7)
DVT	2 (14)
Pleural effusion	1 (7)

Abbreviation: DVT, deep venous thrombosis.

Table 7. Vascular Graft Occlusions

Vessel	Graft Type	Postoperative, mo	Outcome
Popliteal vein	Saphenous	<1	Stable without thrombectomy
Vena cava	Allograft	<1	Stable without thrombectomy
External iliac artery	Saphenous	<1	Replaced with PTFE
Brachial artery	Saphenous	<1	Graft replaced with saphenous vein graft and remains patent

Abbreviation: See Table 5.

One PTFE graft developed infection that led to removal and subsequent amputation. The second graft infection resulted from an iatrogenic bowel injury during closure of the fascia. Enteric fluid spillage led to a diverting colostomy and presumed infection of the polyethylene terephthalate iliofemoral artery bypass. A neoaortoiliac system using femoral vein was performed after removal of the infected polyethylene terephthalate graft. This repeated arterial bypass remained patent but required balloon angioplasty at 3 months to maintain patency. Other morbidities included lower extremity deep venous thrombosis (2) and symptomatic pleural effusion (1) (**Table 6**).

There were 4 early graft occlusions (**Table 7**) involving 2 veins (vena cava and popliteal vein) that were not repaired and 2 arteries that led to repeated arterial bypass using PTFE (external iliac artery) and saphenous vein (brachial artery). At the time of reoperation for a thrombosed iliofemoral bypass (saphenous vein) with a PTFE reconstruction, the previously ligated external iliac vein was reconstructed using saphenous vein (CryoVein; CryoLife, Kennesaw, Georgia). All graft occlusions occurred within 30 days.

Routine duplex ultrasonography surveillance detected elevated velocities within 3 arterial reconstructions. These were treated using percutaneous balloon angioplasty with resolution of the stenosis. Overall reinterventions included removal of the infected graft, repeated arterial bypass (2), vein bypass (1), balloon angioplasty (3), and amputation (1) (**Table 8**). Limb salvage was achieved in 93% of all patients.

Local tumor recurrence occurred in 3 patients (21%) at 3 months, 25 months, and 27 months. Recurrences involving retroperitoneal sarcomas (2) and extremity sarcomas (1) resulted in 1 patient who died following recurrence and metastasis to the lung, and the other recurrences were treated with surgical resection. Both of the retroperitoneal sarcoma recurrences had positive margins on histologic examination. The Kaplan-Meier estimate of freedom from disease was 52% at 65 months (**Figure 3**). At a mean follow-up of 18 months (range, 3-64 months), 11 patients (78%) were alive. Kaplan-Meier estimated survival was 68% at 65 months (Figure 3). There were no early deaths (<30 days) and 3 late deaths (21%) occurred at 3 months, 4 months, and 20 months due to metastatic disease.

COMMENT

This study reviews our experience with blood vessel reconstruction as an integral part of surgery to remove soft tissue sarcomas involving major blood vessels located in the extremities or the retroperitoneum. In this prospective cohort study, surgical resection required vascular reconstruction of 16 major arteries and 9 major veins in 14 patients with retroperitoneal or extremity sarcomas. Vascular involvement was not considered as a contraindication to sarcoma resection and whenever possible, venous reconstruction was performed.

A multidisciplinary team was essential to our surgical approach. The preoperative team approach allowed for better surgical planning, removal of previously thought inoperable tumors based on outside hospital evaluations, more effective reconstruction, and improved outcomes. Preoperatively, patients met separately with the surgeon (surgical oncology or orthopedic surgeon), vascular surgeon, medical oncologist, and radiation oncologist. An integral part of this evaluation process was the preoperative attainment of a computed tomography angiogram and meeting with a vascular surgeon to plan the vascular reconstruction and resection. Preoperative lower extremity vein mapping of the greater saphenous vein or femoral veins was routinely obtained. If the involved vein was chronically occluded, no efforts to reconstruct the vein were attempted unless the inferior vena cava was involved. Otherwise, we aggressively pursued venous reconstructions when feasible.

Because of the large size of the tumors and involvement of surrounding structures (particularly with retroperitoneal sarcomas), en bloc resection can improve the resectability rate.[7] In this cohort of 7 retroperitoneal sarcomas, en bloc resection necessitated removal of adjacent organs (57%) that included kidney (3), colon (3), spleen (2), small bowel (2), duodenum (1), and pancreas (1). In the case of the retroperitoneal sarcomas, the aorta or vena cava were encased by tumor on 4 occasions. Each of these retroperitoneal sarcomas was considered high risk and "unresectable."

Overall incidence of wound dehiscence was 36% involving 5 patients with extremity sarcomas. These findings are consistent with the 50% dehiscence noted by Adelani et al[4] when only the vessels were reconstructed with saphenous vein. Previous studies have suggested a lower incidence of wound infection and dehiscence with the use of autologous conduit.[4] In our series, all of the wound dehiscences occurred with the saphenous vein used to reconstruct the vessel. Only 1 patient received radiation

©2009 American Medical Association. All rights reserved.
Downloaded From: http://archsurg.jamanetwork.com/ on 10/26/2016

Table 8. Reinterventions

Vessel	Graft Type	Postoperative, mo	Outcome
External iliac artery	Saphenous	<1	Replaced with PTFE; later PTFE removed for infection
Brachial artery	Saphenous	3	Graft replaced with saphenous vein graft and remained patent
External iliac artery	Polyethylene terephthalate	1	Infected graft removed and replaced with femoral vein; remained patent
External iliac artery	PTFE	2	Infected graft removed for infection and amputation
External iliac artery	Saphenous	3	Balloon angioplasty; remained patent
Superficial femoral artery	Saphenous	4	Balloon angioplasty; remained patent
Superficial femoral artery	Saphenous	2	Balloon angioplasty; remained patent

Abbreviation: See Table 5.

therapy prior to resection. Perhaps contributing to the development of infection and wound breakdown was the large defect that resulted from the resection. Myocutaneous flap coverage was not routinely performed in conjunction with resection.[6]

The status of the wound affected the ability to proceed with planned adjuvant therapy. Three patients with planned chemoradiation therapy (total 7) had treatment postponed because of the status of the wound (Table 3). There were 2 graft infections (14%). A number of case series report a similar incidence of graft infections (10%-28%) in this setting.[4,5,8]

There were 4 early graft occlusions (16%) involving 2 veins (vena cava and popliteal vein) that were not reintervened and 2 arteries that led to repeated arterial bypass using PTFE (external iliac artery) and saphenous vein (brachial artery). No attempt was made to revise the venous reconstruction and no adverse sequelae resulted. None of these early occlusions occurred in patients undergoing postoperative radiation therapy. Adelani et al[4] reported a similar rate of graft occlusion (36) involving synthetic conduit. Schwarzbach et al[5] reported high levels of graft occlusion in both arterial (35%) and venous (42%) reconstructions for extremity sarcomas. There was a much lower frequency of graft thrombosis (7%) associated with resection in their series on retroperitoneal sarcomas.[7]

In this study, arterial primary patency was 58% and primary-assisted patency was 83% at 65 months. For retroperitoneal sarcomas, thrombosis occurred in 2 of 15 vessel reconstructions (13%). There is a continued need for long-term surveillance with duplex ultrasonography and clinical examination. Early detection of graft stenosis with findings on duplex ultrasonography of elevated velocities or a drop in serial ankle-brachial indexes indicate a need for reintervention. Reintervention can be performed with catheter-based balloon angioplasty without the need for a large operation while maintaining patency. Limb salvage was achieved in 93% of all patients. Efforts at venous reconstructions are more controversial in the literature. Tsukushi et al[6] reported a 2-year and 5-year venous reconstruction patency rate of 40% and 33%. The low patency rate of venous reconstructions occurred despite 48% concomitant myocutaneous flap coverage to promote venous collateral formation. Both Adelani et al[4] and Tsukushi et al[6] reported no added benefit in reducing edema by performing a venous reconstruction. Similar to the efforts of Baxter et al,[8] we have been

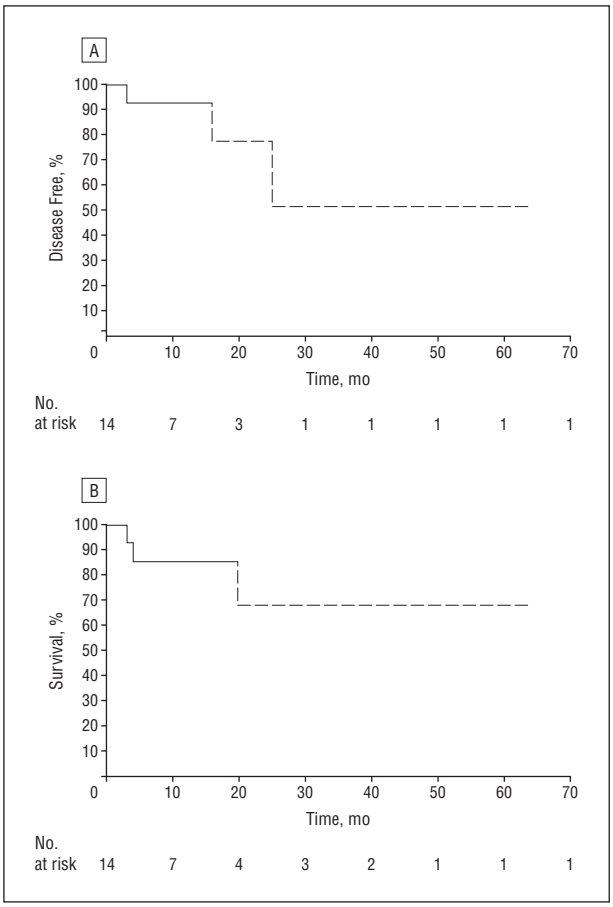

Figure 3. Disease-free survival and overall survival.

aggressive at venous reconstructions. In our series, there were 2 early venous graft occlusions that were managed nonoperatively. We did not reintervene because the patients had well-established venous collaterals. In our series, the Kaplan-Meier estimate of venous patency was 78% at 65 months. This high venous reconstruction patency rate suggests that despite venous collaterals, reconstruction is useful to maintain good outflow and tissue viability. Schwarzbach et al[5] showed a similar long-term venous patency of 54.9% at 5 years for extremity sarcomas and 93.8% for retroperitoneal sarcomas.[7]

All 3 deaths in this series occurred in the resection of retroperitoneal sarcomas. There were no early deaths (<30 days). Late mortality (>30 days) for retroperitoneal sarcomas was 43% due to metastatic disease. At a mean fol-

©2009 American Medical Association. All rights reserved.
Downloaded From: http://archsurg.jamanetwork.com/ on 10/26/2016

low-up of 18.4 months (range, 3-64 months), 11 patients (79%) remained alive. The Kaplan-Meier estimate of survival was 68% at 65 months. Fueglistaler et al[2] reported on 7 patients with malignancies (5 sarcoma) involving the aorta and vena cava in which no early operative deaths, 1 late death at 11 months, and a median survival of 14 months were reported. There was 27% thrombotic occlusion with a recurrence rate of 43% in their series.

Local recurrences occurred in 3 patients (21%) at 3 months, 25 months, and 27 months. The Kaplan-Meier estimate of disease-free survival was 52% at 65 months. Tumor recurrences were aggressively resected, which contributed to an excellent overall survival.

Involvement of major vascular structures is not a contraindication to resection of sarcomas, but appropriate planning is necessary to optimize outcome. Continued long-term surveillance is needed. As suggested by others,[4] a prospective registry of patients with sarcoma would allow for adequate numbers to evaluate long-term outcomes of treatment.

Accepted for Publication: April 23, 2009.
Correspondence: E. John Harris Jr, MD, Division of Vascular Surgery, Department of Surgery, Stanford University, 300 Pasteur Dr, H3600, Stanford, CA 94305-5642 (edjohn@stanford.edu).
Author Contributions: *Study concept and design:* Song, Harris, and Norton. *Acquisition of data:* Song, Harris, and Raghavan. *Analysis and interpretation of data:* Song, Harris, Raghavan, and Norton. *Drafting of the manuscript:* Song, Harris, and Raghavan. *Critical revision of the manuscript for important intellectual content:* Song, Harris, and Norton. *Statistical analysis:* Song and Raghavan. *Administrative, technical, and material support:* Song and Harris. *Study supervision:* Harris and Norton.
Financial Disclosure: None reported.
Previous Presentation: This paper was presented at the 80th Annual Meeting of the Pacific Coast Surgical Association; February 14, 2009; San Francisco, California; and is published after peer review and revision. The discussions that follow this article are based on the originally submitted manuscript and not the revised manuscript.

REFERENCES

1. Hueman MT, Herman JM, Ahuja N. Management of retroperitoneal sarcomas. *Surg Clin North Am*. 2008;88(3):583-597, vii.
2. Fueglistaler P, Gurke L, Stierli P, et al. Major vascular resection and prosthetic replacement for retroperitoneal tumors. *World J Surg*. 2006;30(7):1344-1349.
3. Hueman MT, Thornton K, Herman JM, Ahuja N. Management of extremity soft tissue sarcomas. *Surg Clin North Am*. 2008;88(3):539-557, vi.
4. Adelani MA, Holt GE, Dittus RS, Passman MA, Schwartz HS. Revascularization after segmental resection of lower extremity soft tissue sarcomas. *J Surg Oncol*. 2007;95(6):455-460.
5. Schwarzbach MH, Hormann Y, Hinz U, et al. Results of limb-sparing surgery with vascular replacement of soft tissue sarcoma in the lower extremity. *J Vasc Surg*. 2005;42(1):88-97.
6. Tsukushi S, Nishida Y, Sugiura H, Nakashima H, Ishiguro N. Results of limb-salvage surgery with vascular reconstruction for soft tissue sarcoma in the lower extremity: comparison between only arterial and arterovenous reconstruction. *J Surg Oncol*. 2008;97(3):216-220.
7. Schwarzbach MH, Hormann Y, Hinz U, et al. Clinical results of surgery for retroperitoneal sarcoma with major blood vessel involvement. *J Vasc Surg*. 2006;44(1):46-55.
8. Baxter BT, Mahoney C, Johnson PJ, et al. Concomitant arterial and venous reconstruction with resection of lower extremity sarcomas. *Ann Vasc Surg*. 2007;21(3):272-279.

DISCUSSION

Jeffrey L. Ballard, MD, Orange, California: This excellent presentation reinforces the fact that combining the expertise of surgical specialists results in better patient care. "Nonresectability" morphs into resectability, and thoughtful preoperative planning is the key to successful removal of soft tissue sarcomas that invade major blood vessels. You highlighted a number of important points about these very difficult cases. Your answers to the following questions will shed further light on the subject.

First, are you satisfied that preoperative CT [computed tomography] angiography is sensitive and specific enough to rule in or out major vessel invasion in all soft tissue sarcoma cases? Second, there was a fairly heterogeneous mix of vessel reconstruction conduits in your series. Could you tell us the criteria that you used to choose a suitable arterial or venous replacement conduit? Finally, all of the cases that you presented were well planned in advance of surgery. How many other times have you been called urgently into the operating room for blood vessel reconstruction or injury during a major oncologic tumor resection?

Dr Harris: Emergent calls to the OR [operating room] used to be more frequent before developing an association with Dr Norton. I am never called by him for an unplanned replacement of a blood vessel involved with a tumor. Our association has now expanded to include resection of pancreatic and duodenal tumors with mesenteric vein and superior mesenteric and hepatic artery replacements.

Preoperative CT scanning has been very helpful, and Dr Norton has come to use it in most of his patients, especially with some of the pancreatic tumors. Sometimes we can't tell the extent of vascular involvement, but we always plan that I will be there. I see these patients preoperatively, and we'll have imaged the patients in the vascular laboratory for assessment of their conduit, which gets to the question about conduit choice.

We try to use autogenous tissues if possible, but with some of these larger tumors, when you resect so much soft tissue, the support for some of our autogenous conduits is difficult, and some of our failures have been related to kinking once the retractors are removed and the graft now has a different course than it would with these structures in place. One of our failures for graft infection reflected the nature of these tumors requiring bowel resection, with unrecognized perforation. A Dacron [polyethylene terephthalate] conduit, which I would normally use in the iliac system, became infected, requiring autogenous replacement. So I perhaps would rethink that one particular case.

Financial Disclosure: None reported.

©2009 American Medical Association. All rights reserved.
Downloaded From: http://archsurg.jamanetwork.com/ on 10/26/2016