ORIGINAL ARTICLE

Laparoscopic Total Gastrectomy With D2 Lymph Node Dissection for Gastric Cancer

Toshihiko Shinohara, MD; Seiichiro Kanaya, MD; Keizo Taniguchi, MD; Tetsuji Fujita, MD; Katsuhiko Yanaga, MD; Ichiro Uyama, MD

Objective: To evaluate the safety and effectiveness of laparoscopic total gastrectomy with D2 lymphadenectomy for gastric cancer.

Design: Review of findings from a prospectively acquired institutional database.

Setting: University hospital.

Patients: Fifty-five consecutive patients operated on by the same surgeon between October 1997 and March 2008.

Main Outcome Measures: Blood loss, complication rate, and survival.

Results: All operations were accomplished without conversion to open laparotomy. The median operative time was 406 minutes. The median blood loss was 102 mL. A median of 46 lymph nodes were harvested. The TNM stages of the tumor were I in 17 patients (31%), II in 12 (22%), III in 16 (29%), and IV in 10 (18%). A total of 21 complications occurred in 18 patients (33%) with no postoperative mortality. At last follow-up, 44 of the 55 patients were alive without tumor recurrence and 3 with recurrence at a median follow-up of 16 months, whereas 8 had died of recurrence or another cause.

Conclusions: The mortality rate of zero and acceptable morbidity of our series indicate that laparoscopic total gastrectomy with D2 lymphadenectomy is technically feasible and safe in the hands of experienced surgeons. Long-term follow-up is mandatory to validate oncologic outcome.

Arch Surg. 2009;144(12):1138-1142

Laparoscopy-assisted distal gastrectomy has become the recognized procedure for early gastric cancer.[1-4] Its benefits over conventional open gastrectomy, such as improved cosmetics and reduced postoperative pain, have been well documented. However, it is uncertain whether surgeons can reasonably offer laparoscopic total gastrectomy to patients with gastric cancer in the upper third, the middle third, or the whole stomach.

See Invited Critique at end of article

Successful laparoscopy-assisted total gastrectomy for gastric cancer was first reported by Azagra et al[5] in 1999. Simultaneously, our group reported the first laparoscopic total gastrectomy with D2 lymphadenectomy for gastric cancer.[6] Since that time a number of small series advocating laparoscopy-assisted total gastrectomy for gastric cancer have appeared in the literature.[7,8] In addition, a multicenter study including 1294 patients with early gastric cancer indicated that laparoscopy-assisted gastrectomy with D1 lymphadenectomy for early gastric cancer can yield good short- and long-term outcomes.[9] However, there are few studies on the outcomes of laparoscopic total gastrectomy with D2 lymphadenectomy for gastric cancer because of technical difficulty in completing the procedures and concerns about long-term oncologic outcomes.

The application of laparoscopic total gastrectomy with D2 lymphadenectomy for gastric cancer raises 2 problems: whether and how to perform a concomitant splenectomy to completely retrieve station 10 lymph nodes and how to accomplish an intracorporeal anastomosis. The former is also a matter of debate for open surgery, and the latter is the key to success for a totally laparoscopic approach. The purpose of this study was to document the outcomes of our experience, which consists of 55 laparoscopic total gastrectomies with D2 lymphadenectomy performed by a single surgeon using an entirely laparoscopic approach.

Author Affiliations: Departments of Surgery, Fujita Health University School of Medicine, Aichi, Japan (Drs Shinohara, Kanaya, Taniguchi, and Uyama), and Jikei University School of Medicine, Tokyo, Japan (Drs Shinohara, Fujita, and Yanaga).

©2009 American Medical Association. All rights reserved.
Downloaded From: http://archsurg.jamanetwork.com/ on 05/03/2015

METHODS

PATIENTS

A computer-based database at Fujita Health University School of Medicine, Aichi, Japan, on each patient with gastric cancer was started in September 1997. Between October 1997 and March 2008, 654 patients underwent laparoscopic gastrectomy for gastric cancer. For this study we analyzed our first 55 consecutive patients who underwent laparoscopic total gastrectomy with D2 lymphadenectomy for gastric cancer located in the upper third, the middle third, or the whole stomach. Patients who underwent laparoscopy-assisted or a hand-assisted surgery requiring a minilaparotomy incision for anastomosis of the bowel and/or dissection of the lymph nodes along the splenic artery were excluded from the present study. All patients had histologically verified adenocarcinoma of the stomach. Patients who had histologic evidence of residual tumor and who had gross residual cancer during surgery were excluded. When free cancer cells were found in the lavage fluid during the operation, laparoscopic D1 palliative total gastrectomy was chosen for the treatment of such patients, whose data were also excluded from this study.

All patients underwent laparoscopic total gastrectomy and Roux-en-Y reconstruction with a stapled esophagojejunostomy. Twenty-four patients with cT1 or cT2 (without involvement to the greater curvature) gastric cancer underwent laparoscopic D2 lymph node dissections preserving the spleen and the distal pancreas. Among the remaining 31 patients, who were preoperatively diagnosed as having cT2, T3, or T4 gastric cancer, 28 underwent laparoscopic total gastrectomy with splenectomy, and 3 patients in whom the tumor appeared to adhere to the pancreas underwent distal pancreatectomy in addition to splenectomy.

All patients were treated by a single surgeon (I.U.) who had experience with more than 600 cases of laparoscopic gastrectomy. In addition, this study was regarded as a clinical trial that was approved by the institutional review board of our institution. All patients and their families were informed about the possible risks and benefits of the whole clinical trial of treatment for the disease, and written informed consent was obtained.

Demographic details, perioperative data such as operative time, estimated blood loss, presence or absence of postoperative complications, length of postoperative hospital stay, clinicopathological TNM stage (according to the International Union Against Cancer staging[10]), and distant follow-up were evaluated. Also, the details of postoperative complications were reviewed. Major postoperative complications were defined as surgical complications, including anastomotic leak, pancreatic fistula, and abdominal abscess. Other postoperative complications were defined as adverse events resulting in a delay in discharge from the hospital or readmission to the hospital within 30 days of discharge.

OPERATIVE TECHNIQUE OF D2 LAPAROSCOPIC TOTAL GASTRECTOMY WITH SPLENECTOMY

After the establishment of a pneumoperitoneum at 10 to 12 mm Hg, a flexible electrolaparoscope (LTF-VH; Olympus Medical Systems, Tokyo, Japan) was introduced through the intraumbilical port. The other 4 trocars, inserted under laparoscopic guidance, consisted of two 5-mm bilateral subcostal ports and two 12-mm bilateral low abdominal ports (**Figure 1**). At the beginning of each operation, the peritoneal cavity was carefully inspected and cytologic examination by peritoneal lavage was performed to detect macroscopic or microscopic peritoneal dissemination of tumor cells.

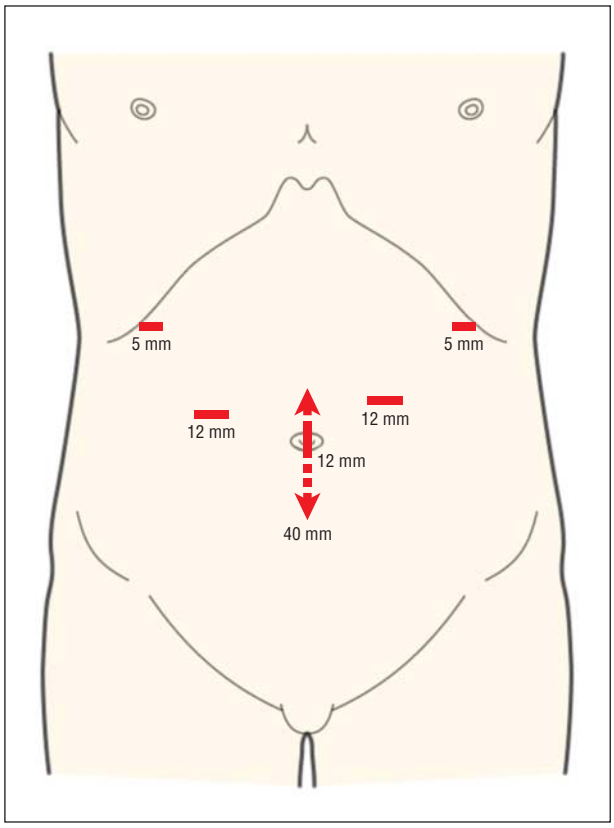

Figure 1. Placement of surgical ports. The intraumbilical port is used for the insertion of a flexible electrolaparoscope, and a 4-cm vertical incision is made for the retrieval of the resected specimen.

An avascular area of the gastrocolic ligament was divided toward the lower pole of the spleen by means of laparosonic coagulation shears (SONOSURG; Olympus Medical Systems) and all lymph nodes along the gastroepiploic vessels (stations 4d and 4sb) were dissected, and then the division was extended distally toward the pylorus by means of laparosonic coagulation shears. The right gastroepiploic vessels were exposed and divided with a single clip at their origins, thus allowing dissection of the infrapyloric lymph nodes (station 6) from the pancreatic head.

The peritoneum along the inferior pancreatic margin was incised with an electrocautery. The body of the gland was lifted from its bed and further mobilized as far as necessary, and the splenic vein and artery were isolated. The caudal gland of the pancreas was retracted gently downward by gauze traction so that the upper border of the pancreas was moved forward. The splenic artery was immediately identified through the lesser sac and was divided between clips distal to the origin of the dorsal pancreatic artery.

The lower esophagus was adequately mobilized and transected by means of a 45-mm endoscopic stapling device (ETS 45; Ethicon Endo-Surgery, Cincinnati, Ohio). The stumps of the excised portion of the esophagus were submitted for frozen-section examination with hematoxylin-eosin staining during the operation in patients with intraoperative suspected tumor invasion of the esophagus. The whole stomach and the body and tail of the pancreas, together with the spleen, were turned over to the right, exposing their posterior surfaces. The fatty connective tissue including lymph nodes around the splenic artery (stations 11p and 11d) was completely removed and the caudal splenic artery was divided with clips. The splenic vein was preserved on the whole length of the pancreas and divided between clips just distal to the point of entry to the pancreas tail.

©2009 American Medical Association. All rights reserved.
Downloaded From: http://archsurg.jamanetwork.com/ on 05/03/2015

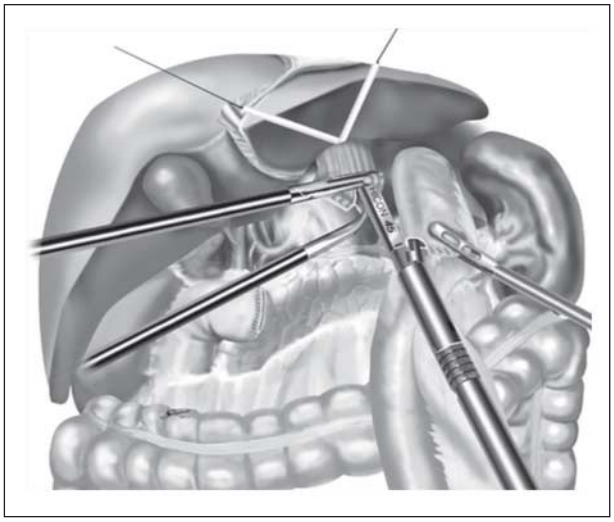

Figure 2. Schematic view of totally laparoscopic total gastrectomy. An endoscopic linear stapler was inserted and positioned to approximate the posterior wall of the distal esophagus and the antimesenteric side of the jejunal loop.

Table. Patient Characteristics

Characteristic	No. (%) of Patients (N=55)
Sex	
Male	41 (75)
Female	14 (25)
Age, mean (range), y	59 (29-80)
American Society of Anesthesiologists class	
1	32 (58)
2	20 (36)
3	3 (5)
Location	
Whole	4 (7)
Upper	22 (40)
Middle	29 (53)
Clinicopathological TNM stage[a]	
IA	12 (22)
IB	5 (9)
II	12 (22)
IIIA	11 (20)
IIIB	5 (9)
IV	10 (18)

[a] According to the International Union Against Cancer staging.[10]

The celiac and left gastric arteries were approached from the left and behind. The root of the left gastric artery was divided with double clips, followed by dissection of lymph nodes along the celiac artery (station 9) and the left gastric artery (station 7). The whole of the stomach was turned down and the duodenum was transected at 1 cm distal to the pylorus with the endoscopic stapling device. The hepatoduodenal ligament was dissected, and then the right gastric artery was exposed and divided at its origin, allowing dissection of the suprapyloric lymph nodes (station 5). The lymph nodes along the common hepatic (station 8a) and proper hepatic (station 12a) arteries were removed en bloc just anterior to the portal vein. Finally, the resected organs and lymph nodes were placed in a plastic bag (Endocatch II; United States Surgical, Norwalk, Connecticut) and extracted through the umbilical incision extended vertically for 40 mm.

After total gastrectomy, intracorporeal anastomosis was accomplished by the Roux-en-Y method with a functional side-to-side anastomotic technique (**Figure 2**). The ligament of Treitz was identified and the jejunum was divided at 20 cm distally. The distal limb of the jejunum was brought up in an antecolic fashion. An enterotomy was made by electrocautery in the antimesenteric side of the jejunum and the posterior side of the esophagus to allow passage of the 2 forks of the endoscopic stapling device. The stapling device was closed and fired to create the anastomosis. The connected stab incision was closed with 2 or 3 applications of the stapler. The side-to-side enteroenterostomy to the Roux limb was made at 50 cm below the esophagojejunostomy by means of the same stapling technique. Two soft tube drains were usually placed, one in the left subphrenic space and another near the esophagojejunostomy through separate bilateral ports, and left for 3 or 4 days.

RESULTS

There were 41 male and 14 female patients with a median age of 59 years (range, 29-80 years) (**Table**). Twenty patients (36%) had at least 1 comorbid medical disease. Fifteen patients (27%) had a history of previous laparotomy. The American Society of Anesthesiology classes of the patients and the locations and postoperative clinicopathological stages of the tumors are given in the Table.

All operations were accomplished by an entirely laparoscopic approach. The median operative time was 406 minutes (range, 200-865 minutes). The median blood loss was 102 mL (range, 20-694 mL). Three patients received blood transfusions during the operation. As previously mentioned, 24 patients (44%) had laparoscopic total gastrectomy with D2 lymphadenectomy without splenectomy, and a concurrent splenectomy was performed in 31 patients (56%). A tumor-free surgical margin was obtained in all patients. The median number of lymph nodes harvested per patient was 41 (range, 17-89) for the former group and 51 (range, 20-106) for the latter group (for the entire group, the median number of lymph nodes harvested was 46 [range, 17-106]), and positive lymph node metastasis was observed in 9 of the 24 patients without splenectomy and 21 of the 31 patients who underwent splenectomy. The median (range) times to postoperative ambulation and oral feeding were 2 days (1-3 days) and 3 days (3-6 days), respectively. The median duration of postoperative hospital stay was 17 days (range, 9-132 days) for the 55 patients. Of these, 37 patients (67%) had an uneventful course with a median postoperative hospital stay of 14 days (range, 9-25 days). The median postoperative hospital stay of the 18 patients with any postoperative complication was considerably longer than that of the group without such events. There was no 30-day or in-hospital mortality after laparoscopic total gastrectomy.

A total of 21 complications occurred in 18 patients (33%), of whom 11 patients had major postoperative complications and the other 7 developed nonsurgical complications. A pancreatic fistula developed in 7 patients (13%): 3 of 3 (100%) in the pancreaticosplenectomy group and 4 of 28 (14%) in the splenectomy group. Four pancreatic fistulas were treated conservatively with a drain placement during the initial operation and the other 3 fistulas required computed tomography–guided percu-

©2009 American Medical Association. All rights reserved.
Downloaded From: http://archsurg.jamanetwork.com/ on 05/03/2015

taneous drainage. Postoperative abdominal abscess was detected in 3 patients (5%), 2 of whom recovered after conservative treatment with a drain and 1 of whom required computed tomography–guided drainage. The amylase level in the drainage fluid was within normal limits in all patients. Two patients (4%) subjected to a concurrent splenectomy were found to have late minor anastomotic leakage, both of whom recovered without surgical intervention. Other complications included acute renal failure in 1 patient, chyloperitoneum in 1, postoperative adhesions in 1, partial splenic infarction in 1, and a respiratory problem in 2. Such complications resolved with conservative treatment. Three patients (5%) developed small-bowel obstruction due to internal hernia beneath the jejunal loop; all required reoperation via a laparoscopic approach and recovered without further complications.

Postoperative adjuvant chemotherapy was given in 30 patients (54%). At last follow-up, 44 of the 55 patients were alive without tumor recurrence and 3 patients had developed recurrences at a median follow-up of 16 months (range, 7-130 months), whereas the other 8 had died of recurrence (7 patients) or another cause (1 patient).

COMMENT

Laparoscopy-assisted distal gastrectomy for early gastric cancer has rapidly developed and is now widely accepted.[1-3] Recently, several studies on such a procedure have shown not only favorable short-term outcomes but also acceptable long-term oncologic safety.[9,11] In contrast to laparoscopic partial gastric resections for early gastric cancer, studies on laparoscopic total gastrectomy for gastric cancer are lacking.[7,8] Since the first report by our group in 1999 of laparoscopic total gastrectomy in patients with proximal gastric cancer,[6] we have successfully performed 55 laparoscopic total gastrectomies with a complete D2 lymph node dissection without conversion to open laparotomy. To the best of our knowledge, this is the first report on the outcomes of laparoscopic total gastrectomy in a relatively large series of patients with gastric cancer.

Like open resection, D2 total gastrectomy with splenectomy for gastric cancer is still debated.[12-17] The previous studies from Western centers have reported operative mortality rates ranging from 4.4% to 16.8% and overall morbidity rates ranging from 40.8% to 58.8% after splenectomy combined with D2 total gastrectomy.[12,16,18-20] In 2 European randomized control trials, splenectomy was strongly associated with increased mortality and morbidity after D2 total gastrectomy.[19,20] Hence, authors in Western countries have recommended that splenectomy be abandoned unless the tumor directly invades the spleen or involves the splenic hilar nodes. In Japan, on the contrary, splenectomy has not been considered an independent determinant of morbidity and mortality associated with D2 total gastrectomy.[21] In the present study, the hospital mortality rate was zero and the overall morbidity rate was 33%, which was comparable to the rates of 35.1% and 39.7% reported for large series of patients undergoing conventional open D2 total gastrectomy with splenectomy.[13,14] To date, although the survival benefit of splenectomy in potentially curative total gastrectomy is not yet established, this study suggests that the minimal risks of injury to the pancreatic parenchyma and the splenic vein during splenectomy may be attributable to the high quality of the laparoscopic view with excellent visualization.

Although total gastrectomy with partial pancreatectomy for gastric cancer can be conducted with the intent of curative resection,[22] it is likely to yield an increased risk of pancreatic fistula–related postoperative complications, which are prone to occur in patients with a soft pancreas.[23] In the present study, the pancreatic fistula rate in patients with splenectomy was 14%, but that in patients with partial pancreatectomy appeared to be 100%. In our experience, the pancreas was isolated at the left side of the superior mesenteric vein and divided with the linear stapler. As in open resections, management of the pancreatic stump is still challenging. It is hoped that further technical refinements will contribute to decreasing the rate of pancreatic fistula.

Lymph node metastasis of gastric cancer is frequently encountered around the suprapancreatic area such as at stations 7, 8, 9, and 11.[24] Moreover, complete dissection of this area is an important element of curative surgical treatment for gastric cancer.[17] Our technique consists of dissection of the suprapancreatic lymph nodes with initial mobilization of the pancreatic body and downward retraction of the caudal gland of the pancreas by gauze traction to look for the upper border of the pancreas. These steps have helped us to perform meticulous dissection of lymph nodes without injuring the pancreatic parenchyma by using an ultrasonic device or clips if needed. Consequently, the number of lymph nodes removed in our series exceeded 40, indicating that laparoscopic treatment has not jeopardized the quality of nodal dissection.[25]

One of the major concerns in conducting laparoscopic total gastrectomy with D2 lymphadenectomy was the prolonged operation time, which may increase morbidity. However, in our series, the hospital mortality rate was zero and there was acceptable morbidity. Because we believe this to be the first report on the outcomes of laparoscopic total gastrectomy with D2 lymphadenectomy for gastric cancer, we expect that this problem will be solved in the future by improvements in laparoscopic devices and techniques.

Although laparoscopic surgery has a clear benefit regarding postoperative hospital stay, in our series the hospital stay was relatively long: a median of 17 days overall and 14 days after uneventful recovery. In Japan, subacute care, such as that given in nursing facilities or rehabilitation centers, is not well developed, and most patients are discharged from the hospital when they have completely recovered. However, our patients experienced a fast recovery, with a median time to postoperative ambulation of 2 days and a median time to oral feeding of 3 days. This is consistent with the faster recovery noted for laparoscopy-assisted distal gastrectomy for early gastric cancer.[1-3] Therefore, it is possible that postoperative hospital stay will be shorter in the near future.

©2009 American Medical Association. All rights reserved.
Downloaded From: http://archsurg.jamanetwork.com/ on 05/03/2015

The most widespread technique for esophagojejunostomy is an anastomosis with a circular stapler prepared for open operation. However, for laparoscopic operation, this technique is complicated with technical difficulty, and a minilaparotomy or an extended auxiliary incision on the abdominal wall for insertion of the circular device may spoil the merit of the totally laparoscopic operation.[4] Our technique for intracorporeal esophagojejunostomy was derived from the application of the functional side-to-side technique to the anastomosis between the antimesenteric side of the distal limb of the jejunum and the posterior side of the esophagus.[6] By means of the described technique, intracorporeal esophagojejunostomy can be performed with the use of a 45-mm linear stapler through a 12-mm low abdominal port without forceful extraction of the surgical specimen. It has been demonstrated that intersecting staple lines do not reduce anastomotic blood flow to a critical level.[26] At present, physiologic function and the additional hospital cost of this technique have not been evaluated. We believe that intracorporeal esophagojejunostomy using an endoscopic linear stapler is a simple technique that does not reduce the advantages of laparoscopic gastric resection.

In summary, the mortality rate of zero and acceptable morbidity of our series demonstrate that laparoscopic total gastrectomy with D2 lymphadenectomy is technically feasible and is safe in the hands of experienced surgeons. Although setting a suitable control group for comparative analysis seems necessary to confirm this, the number of retrieved lymph nodes is sufficient for accurate pathological staging. Future studies are necessary to determine the long-term oncologic outcomes of laparoscopic total gastrectomy with D2 lymph node dissection for gastric cancer.

Accepted for Publication: January 2, 2009.
Correspondence: Toshihiko Shinohara, MD, Department of Surgery, Fujita Health University School of Medicine, 1-98 Dengakugakubo, Kutsukakecho, Toyoake, Aichi 470-1192, Japan (shinohara@jikei.ac.jp).
Author Contributions: *Study concept and design:* Shinohara and Uyama. *Acquisition of data:* Shinohara, Kanaya, and Taniguchi. *Analysis and interpretation of data:* Shinohara and Kanaya. *Drafting of the manuscript:* Shinohara. *Critical revision of the manuscript for important intellectual content:* Yanaga and Uyama. *Statistical analysis:* Shinohara and Fujita.
Financial Disclosure: None reported.

REFERENCES

1. Adachi Y, Shiraishi N, Shiromizu A, Bandoh T, Aramaki M, Kitano S. Laparoscopy-assisted Billroth I gastrectomy compared with conventional open gastrectomy. *Arch Surg*. 2000;135(7):806-810.
2. Kim MC, Kim KH, Kim HH, Jung GJ. Comparison of laparoscopy-assisted by conventional open distal gastrectomy and extraperigastric lymph node dissection in early gastric cancer. *J Surg Oncol*. 2005;91(1):90-94.
3. Uyama I, Sakurai Y, Komori Y, et al. Laparoscopic gastrectomy with preservation of the vagus nerve accompanied by lymph node dissection for early gastric carcinoma. *J Am Coll Surg*. 2005;200(1):140-145.
4. Kanaya S, Gomi T, Momoi H, et al. Delta-shaped anastomosis in totally laparoscopic Billroth I gastrectomy: new technique of intraabdominal gastroduodenostomy. *J Am Coll Surg*. 2002;195(2):284-287.
5. Azagra JS, Goergen M, De Simone P, Ibañez-Aguirre J. Minimally invasive surgery for gastric cancer. *Surg Endosc*. 1999;13(4):351-357.
6. Uyama I, Sugioka A, Fujita J, Komori Y, Matsui H, Hasumi A. Laparoscopic total gastrectomy with distal pancreatosplenectomy and D2 lymphadenectomy for advanced gastric cancer. *Gastric Cancer*. 1999;2(4):230-234.
7. Usui S, Yoshida T, Ito K, Hiranuma S, Kudo S, Iwai T. Laparoscopy-assisted total gastrectomy for early gastric cancer: comparison with conventional open total gastrectomy. *Surg Laparosc Endosc Percutan Tech*. 2005;15(6):309-314.
8. Topal B, Leys E, Ectors N, Aerts R, Penninckx F. Determinants of complications and adequacy of surgical resection in laparoscopic versus open total gastrectomy for adenocarcinoma. *Surg Endosc*. 2008;22(4):980-984.
9. Kitano S, Shiraishi N, Uyama I, Sugihara K, Tanigawa N; Japanese Laparoscopic Surgery Study Group. A multicenter study on oncologic outcome of laparoscopic gastrectomy for early cancer in Japan. *Ann Surg*. 2007;245(1):68-72.
10. Sobin LH, Wittekind CH. *TNM Classification of Malignant Tumors*. 6th ed. Heidelberg, Germany: Springer-Verlag; 2002.
11. Huscher CG, Mingoli A, Sgarzini G, et al. Laparoscopic versus open subtotal gastrectomy for distal gastric cancer: five-year results of a randomized prospective trial. *Ann Surg*. 2005;241(2):232-237.
12. Griffith JP, Sue-Ling HM, Martin I, et al. Preservation of the spleen improves survival after radical surgery for gastric cancer. *Gut*. 1995;36(5):684-690.
13. Otsuji E, Yamaguchi T, Sawai K, Okamoto K, Takahashi T. Total gastrectomy with simultaneous pancreaticosplenectomy or splenectomy in patients with advanced gastric carcinoma. *Br J Cancer*. 1999;79(11-12):1789-1793.
14. Kasakura Y, Fujii M, Mochizuki F, Kochi M, Kaiga T. Is there a benefit of pancreaticosplenectomy with gastrectomy for advanced gastric cancer? *Am J Surg*. 2000;179(3):237-242.
15. Yu W, Choi GS, Chung HY. Randomized clinical trial of splenectomy versus splenic preservation in patients with proximal gastric cancer. *Br J Surg*. 2006;93(5):559-563.
16. Csendes A, Burdiles P, Rojas J, Braghetto I, Diaz JC, Maluenda F. A prospective randomized study comparing D2 total gastrectomy versus D2 total gastrectomy plus splenectomy in 187 patients with gastric carcinoma. *Surgery*. 2002;131(4):401-407.
17. Sasako M, McCulloch P, Kinoshita T, Maruyama K. New method to evaluate the therapeutic value of lymph node dissection for gastric cancer. *Br J Surg*. 1995;82(3):346-351.
18. Viste A, Haugstvedt T, Eide GE, Soreide O. Postoperative complications and mortality after surgery for gastric cancer. *Ann Surg*. 1988;207(1):7-13.
19. Bonenkamp JJ, Songun I, Hermans J, et al. Randomised comparison of mortality after D1 and D2 dissection for gastric cancer in 996 Dutch patients. *Lancet*. 1995;345(8952):745-748.
20. Cuschieri A, Fayers P, Fielding J, et al; Surgical Cooperative Group. Postoperative morbidity and mortality after D1 and D2 resections for gastric cancer: preliminary results of the MRC randomized controlled surgical trial. *Lancet*. 1996;347(9007):995-999.
21. Nakajima T. Gastric cancer treatment guidelines in Japan. *Gastric Cancer*. 2002;5(1):1-5.
22. Shchepotin IB, Chorny VA, Nauta RJ, Shabahang M, Buras RR, Evans SR. Extended surgical resection in T4 gastric cancer. *Am J Surg*. 1998;175(2):123-126.
23. Yeo CJ, Cameron JL, Lillemoe KD, et al. Does prophylactic octreotide decrease the rates of pancreatic fistula and other complications after pancreaticoduodenectomy? results of a prospective randomized placebo-controlled trial. *Ann Surg*. 2000;232(3):419-429.
24. Maruyama K, Gunven P, Okabayashi K, Sasako M, Kinoshita T. Lymph node metastases of gastric cancer: general pattern in 1931 patients. *Ann Surg*. 1989;210(5):596-602.
25. Smith DD, Schwarz RR, Schwarz RE. Impact of total lymph node count on staging and survival after gastrectomy for gastric cancer: data from a large US-population database. *J Clin Oncol*. 2005;23(28):7114-7124.
26. Zilling TL, Walther BS, Ranstam J. Intersecting staple lines and blood flow in oesophagojejunal anastomoses. *Br J Surg*. 1990;77(12):1375-1378.

©2009 American Medical Association. All rights reserved.
Downloaded From: http://archsurg.jamanetwork.com/ on 05/03/2015