ORIGINAL ARTICLE

Association of Increasing Burn Severity in Mice With Delayed Mobilization of Circulating Angiogenic Cells

Xianjie Zhang, MD, PhD; Xiaofei Wei, MD; Lixin Liu, PhD; Guy P. Marti, MD; Mohammed S. Ghanamah, MD; Muhammad J. Arshad, MD; Lori Strom, BS; Robert Spence, MD; James Jeng, MD; Stephen Milner, MD; John W. Harmon, MD; Gregg L. Semenza, MD, PhD

Objective: To perform a systematic exploration of the phenomenon of mobilization of circulating angiogenic cells (CACs) in an animal model. This phenomenon has been observed in patients with cutaneous burn wounds and may be an important mechanism for vasculogenesis in burn wound healing.

Design: We used a murine model, in which burn depth can be varied precisely, and a validated culture method for quantifying circulating CACs.

Setting: Michael D. Hendrix Burn Research Center, Baltimore, Maryland.

Participants: Male 129S1/SvImJ mice, aged 8 weeks, and 31 patients aged 19-59 years with burn injury on 1% to 64% of the body surface area and evidence of hemodynamic stability.

Main Outcome Measures: Burn wound histological features, including immunohistochemistry for blood vessels with CD31 and α-smooth muscle actin antibodies, blood flow measured with laser Doppler perfusion imaging, and mobilization of CACs into circulating blood measured with a validated culture technique.

Results: Increasing burn depth resulted in a progressive delay in the time to mobilization of circulating CACs and reduced mobilization of CACs. This delay and reduction in CAC mobilization was associated with reduced perfusion and vascularization of the burn wound tissue. Analysis of CACs in the peripheral blood of the human patients, using a similar culture assay, confirmed results previously obtained by flow cytometry, that CAC levels peak early after the burn wound.

Conclusion: If CAC mobilization and wound perfusion are important determinants of clinical outcome, then strategies designed to augment angiogenic responses may improve outcome in patients with severe burn wounds.

Trial Registration: clinicaltrials.gov Identifier: NCT00796627

Arch Surg. 2010;145(3):259-266

Author Affiliations: Section of Surgical Sciences, Beijing Tian Tan Hospital, Capital Medical University, Beijing, China (Dr Zhang); Section of Surgical Sciences and the Michael D. Hendrix Burn Research Center (Drs Zhang, Liu, Marti, Ghanamah, Arshad, Spence, Milner, and Harmon and Ms Strom), Vascular Program, Institute for Cell Engineering, Departments of Pediatrics, Medicine, Oncology, and Radiation Oncology, and McKusick-Nathans Institute of Genetic Medicine (Drs Wei and Semenza), The Johns Hopkins University School of Medicine, Baltimore, Maryland; and Burn Center, Washington Hospital Center, Washington DC (Dr Jeng).

BURN INJURIES REMAIN A MAjor public health problem in the United States and around the world. It is estimated that more than 1 million Americans require medical attention each year for burn injuries.[1-3] Superficial burns heal with minimal scarring. Deep third-degree burns usually require skin grafting to achieve wound closure, but the cosmetic and functional result is less than optimal because the grafted skin is thin and vulnerable to reinjury. Burns heal with variable results, and the factors that determine whether these burns will heal with skin regeneration rather than with a fibrous scar are currently unknown.[4-6]

See Invited Critique at end of article

As described in the classic report by Jackson,[7] the angiogenic response to thermal injury appears to be a critical determinant of outcome for these wounds. The central region of vascular coagulation proceeds to full-thickness tissue loss, and the outer region of hyperemia heals without scar. Between them is the zone of stasis where outcomes are variable and intervention might be beneficial. Injury and repair of the dermal vasculature seems to be a major determinant of whether burns heal promptly and primarily or whether the healing is delayed, leading to damaging scarring. Dermal blood flow is reduced in more severe burn wounds below the levels seen in more superficial first-degree burns, as determined by laser Doppler perfusion imaging (LDPI), which uses a near-infrared laser diode to measure subcutaneous blood flow as a function of light scattering (Doppler shift) by moving red blood cells.[5,8-13]

A recent advance in the understanding of the cellular mechanisms controlling vascularization in response to tissue injury has

©2010 American Medical Association. All rights reserved.
Downloaded From: http://archsurg.jamanetwork.com/ on 10/10/2015

been the discovery of endothelial progenitor cells[14] and other circulating angiogenic cells (CACs).[15] Angiogenic cytokines activate endogenous endothelial cells and also recruit CACs, a term used herein to denote a heterogeneous population of cells that have the potential to participate in various aspects of angiogenesis. They include endothelial progenitor cells, which are incorporated into the endothelium of new or remodeling vessels, and myeloid, mesenchymal, and hematopoietic stem cells, which promote vascular growth and remodeling through production of angiogenic cytokines. Circulating angiogenic cells are released from blood vessels, bone marrow, and other sites in response to the production of angiogenic cytokines at the site of tissue wounding. After mobilization into the circulation, CACs home to the wound, where they participate in angiogenesis.

Circulating angiogenic cells in peripheral blood are quantified by flow cytometric analysis, using antibodies against endothelial and progenitor cell surface proteins, or by culturing mononuclear cells (MNCs) in the presence of endothelial growth factors and scoring for cells with the ability to bind lectin and take up acetylated low-density lipoprotein (LDL).[14-17] Previous studies in humans have identified CACs in the peripheral blood of patients with thermal injuries and $VEGFR2^+/CD15^-$ cells in the peripheral blood of individuals with burns within 12 hours after injury.[18] Twenty-four hours after wounding, levels of $CD45^-/CD133^+/CD144^+/VEGFR2^+$ cells were significantly increased in the peripheral blood of patients with burns compared with those of healthy control subjects.[19]

A major limitation of the human studies is that an individual patient may manifest a wide range of tissue damage from superficial to severe, and it is difficult to determine the precise relationship between the degree of tissue damage and the presence or absence of reparative responses. To address this issue, we have used a murine model in which uniform, graded severity of thermal injury could reliably be produced. The branding-iron type of burn[9,20] was chosen rather than a scald or flame burn[21-23] because it allowed us to produce burns of graded severity. We have used this model to investigate the relationship between burn severity and angiogenesis as manifested by CAC mobilization, LDPI of wound tissue, and vascular morphometry.

METHODS

BURN WOUND PROTOCOL

Male 129S1/SvImJ mice aged 8 weeks were obtained from The Jackson Laboratory, Bar Harbor, Maine. All procedures were approved by The Johns Hopkins University Animal Care and Use Committee. Mice were anesthetized by intraperitoneal injection of ketamine hydrochloride and xylazine hydrochloride, shaved on the dorsum, and treated with a depilatory (Nair; Church & Dwight Co, Inc, Princeton, New Jersey). A burn wound protocol previously established in rats[9,20] was adapted for use in mice. A custom-made 220-g aluminum rod was heated in a 100°C water bath for 5 minutes. Two burns of 1.2-cm diameter each were produced on the dorsum of the animals. Contact time of 4, 6, or 8 seconds was measured with a standardized metronome. These contact times were chosen to produce burns of increasing severity. Fluid resuscitation was performed according to twice the Parkland formula (4 mL/kg × the percentage of body surface area wounded) by intraperitoneal injection of normal saline within 1 hour after burning (ie, 1.6 mL of normal saline was administered to a 25-g mouse with a burn covering 10% of body surface area). Buprenorphine hydrochloride was administered for analgesia. Blood samples for CAC analysis were obtained by cardiac puncture under ketamine-xylazine anesthesia.

HISTOLOGICAL ANALYSIS

Burn wounds were harvested with a rim of normal skin. Specimens from each site were bisected at the center and fixed in 10% buffered formalin solution overnight. Five-micrometer-thick paraffin-embedded sections were stained with hematoxylin-eosin and analyzed by light microscopy. Scar thickness was measured at its maximal dimension in the area laden with collagen fibers and granulation tissue immediately below the epithelium using a light microscope (CK2; Olympus, Tokyo, Japan) with a micrometer (WHK 12.5X/L-H; Olympus).

ANALYSIS OF CACs IN MICE

The CACs were analyzed as previously described.[24] Peripheral blood MNCs were isolated by means of polysucrose and sodium diatrizoate solution density-gradient centrifugation (Histopaque-1083; Sigma-Aldrich Corp, St Louis, Missouri). Residual red blood cells were lysed by addition of ammonium chloride solution (StemCell Technologies Inc, Vancouver, British Columbia, Canada). The MNCs were seeded on 96-well plates coated with rat vitronectin (Sigma-Aldrich Corp) at a concentration of 1.5×10^6 cells/cm^2 and cultured in endothelial basal medium 2 supplemented with EGM-2-MV SingleQuots (a proprietary mixture of 5% fetal bovine serum, human vascular endothelial growth factor, human fibroblast growth factor 2, human epidermal growth factor, insulinlike growth factor 1, ascorbic acid, and hydrocortisone; Lonza Inc, Allendale, New Jersey). After 4 days in culture, the cells were incubated with 1,1′-dioctadecyl-3,3,3′,3′-tetramethylindocarbocyanine (DiI)–labeled acetylated LDL (Invitrogen Corp, Carlsbad, California) in the media at a concentration of 10 µg/mL at 37°C for 2 hours. The cells were then fixed with 4% paraformaldehyde (Sigma-Aldrich Corp) for 10 minutes, and incubated with fluorescein isothiocyanate (FITC)–labeled lectin from *Bandeira simplicifolia* (Sigma-Aldrich Corp) at a concentration of 10 µg/mL for 1 hour, counterstained with 4,6-diamidino-2-phenylindole dihydrochloride (Invitrogen Corp), and DiI- and FITC-positive cells were counted under fluorescence microscopy.[17]

LASER DOPPLER PERFUSION IMAGING

Blood flow in wound areas was measured by 632.6-nm helium-neon scanning laser Doppler imaging (Lisca Development AB, Linköping, Sweden), which uses a near-infrared laser diode to measure subcutaneous blood flow as a function of light scattering by moving red blood cells. The imaging system uses a low-power (1 mW) helium laser beam to sequentially scan the tissue through several thousand measurement points. A photodiode in the tile scanner head detects back-scattered light that has been frequency shifted by moving red blood cells according to the Doppler principle. For each measurement point, a signal is generated that scales linearly with tissue perfusion defined as the product of the blood cell velocity and concentration. This signal, termed the *laser Doppler perfusion index*, was represented as a 2-dimensional color image on a computer screen. The colors produced illustrate the spectrum of perfusion in the wound: dark blue depicts the lowest level of perfusion and red the highest. A photo-

©2010 American Medical Association. All rights reserved.
Downloaded From: http://archsurg.jamanetwork.com/ on 10/10/2015

graphic image was produced simultaneously, which allowed for direct anatomical comparison of corresponding areas of burn. For each burn, the wound site was selected by drawing freehand around an area of interest after exporting the image into the software package used with the imaging system (LDISOFT; Lisca Development AB). Then, the mean LDPI value within this area of interest was computed. The scanner was positioned 50 cm above each animal, and scans were performed on days 3 and 7 to assess blood flow in the wound.

IMMUNOHISTOCHEMISTRY

Mouse wound tissues were fixed with formalin-free immunohistochemistry zinc fixative (BD Pharmingen, San Diego, California) for 24 hours, and 5-μm-thick paraffin sections were prepared. To prevent nonspecific binding, 100 μL of blocking solution containing 2% normal rabbit serum for CD31 immunohistochemistry or horse serum for α-smooth muscle actin (SMA) immunohistochemistry (Jackson ImmunoResearch Laboratories, Inc, West Grove, Pennsylvania) was applied for 30 minutes, and then 100 μL of primary anti-CD31 antibody (1:50 dilution; BD Pharmingen) or anti–α-SMA antibody (1:200 dilution; Sigma-Aldrich Corp) was applied to the sections for 1 hour at room temperature. The sections were further incubated with biotinylated secondary antibody (1:500 dilution; Vector Laboratories, Burlingame, California). Streptavidin-biotin-horseradish peroxidase was used for signal amplification and diaminobenzidine was used for staining (Vector Laboratories). Counterstaining was performed with hematoxylin and nuclear fast red for 30 seconds each, and 3% hydrogen peroxide (Thermo Fisher Scientific Inc, Fair Lawn, New Jersey) was used for blocking endogenous peroxidase activity. All slides were examined in a blinded manner.

WOUND AREA MEASUREMENT

On days 0, 3, 7, and 14, the wound borders were traced in situ on clear acetate paper. Images were digitized at 600 dpi (Paperport 6000, Visioneer, Fremont, California). Wound areas (in pixels) were calculated using National Institutes of Health imaging software (Scion Image, Frederick, Maryland).

HUMAN PATIENTS WITH BURNS

Patients in the Michael D. Hendrix Burn Research Center, Baltimore, Maryland, were enrolled in the study using an institutional review board–approved protocol. Inclusion criteria consisted of a burn injury to 1% to 70% of the body surface area, age of 18 to 75 years, and evidence of hemodynamic stability with normal blood pressure, pulse, and urine output. Written consent was obtained from each patient in accordance with the Declaration of Helsinki protocols. Clinical information related to the burn injury was collected. Venous blood was drawn at intervals after the burn injury with a maximum of 2 samples in a 7-day period.

ANALYSIS OF CACs IN HUMAN PATIENTS

The CACs were analyzed as previously described.[16] The MNCs were isolated from peripheral blood using a sterile density gradient centrifugation medium (Ficoll; Amersham Biosciences, Piscataway, New Jersey). Residual red blood cells were lysed by the addition of ammonium chloride solution (StemCell Technologies Inc). The MNCs were seeded on 24-well plates coated with human fibronectin at a concentration of 1.5×10^6 cells/well and cultured in endothelial basal medium 2 with EGM-2-MV SingleQuots (Lonza Inc). After 4 days in culture, the cells were incubated with DiI-labeled acetylated LDL (Invitrogen Corp), fixed with 4% paraformaldehyde (Sigma-Aldrich Corp), incubated with FITC-labeled lectin from *Ulex europaeus* (Sigma-Aldrich Corp) at a concentration of 10 μg/mL for 1 hour, and counterstained with 4,6-diamidino-2-phenylindole dihydrochloride (Invitrogen Corp), and DiI- and FITC-positive cells were counted under fluorescence microscopy.

STATISTICAL ANALYSIS

Results are presented as mean (SEM). Differences in means between groups were analyzed for significance by the unpaired *t* test or analysis of variance (ANOVA) as appropriate using Sigma Stat software (SYSTAT Software Inc, Point Richmond, California).

RESULTS

ESTABLISHMENT OF A MURINE BURN MODEL WITH UNIFORM, GRADED WOUND SEVERITY

To ensure burn uniformity, only the weight of the aluminum rod itself provided pressure to the skin surface. As burn contact time was increased from 4 to 8 seconds, the severity of burn injury increased, as determined by histological analysis on day 21. The presence of an eschar, composed of coagulated protein, indicates that the epithelial covering of the wound is not intact. The frequency with which an eschar was observed on the burn wound at day 21 tended to increase progressively as the burn contact time increased from 4 to 8 seconds (**Figure 1**A and B).

A superficial burn heals without fibrous scarring, whereas deeper burn wounds heal with thick fibrous scars, which can contract and distort surrounding tissues and result in a poor cosmetic and functional result. The thickness of the burn scar was measured in the center of the wound. With increasing burn duration, scar thickness on day 21 was found to increase significantly ($P = .02$, 1-way ANOVA with Tukey test; Figure 1C and D). The results in Figure 1 demonstrate the graded severity of burn wounds as a function of contact time in this mouse model.

EFFECT OF BURN SEVERITY ON CAC MOBILIZATION

Having established the quantitative nature of the model, we investigated the effect of burn wound severity on CAC mobilization. The MNCs were isolated from peripheral blood, cultured in the presence of endothelial growth factors for 4 days, and analyzed by fluorescence microscopy (**Figure 2**A) for the uptake of DiI-labeled acetylated LDL (red fluorescence) and the binding of FITC-labeled lectin (green fluorescence). The double-positive cells (yellow fluorescence) represent CACs.[17] The number of CACs that were present in the peripheral blood increased in all burn groups, but the kinetics of mobilization were dependent on the burn duration. The peak mobilization of CACs was on day 3 after a 4-second burn (Figure 2B), day 4 after a 6-second burn (Figure 2C), and day 6 after an 8-second burn (Figure 2D). In addition, the magnitude of the peak decreased with increasing burn duration. In all cases, the mobilization was remarkably transient.

©2010 American Medical Association. All rights reserved.
Downloaded From: http://archsurg.jamanetwork.com/ on 10/10/2015

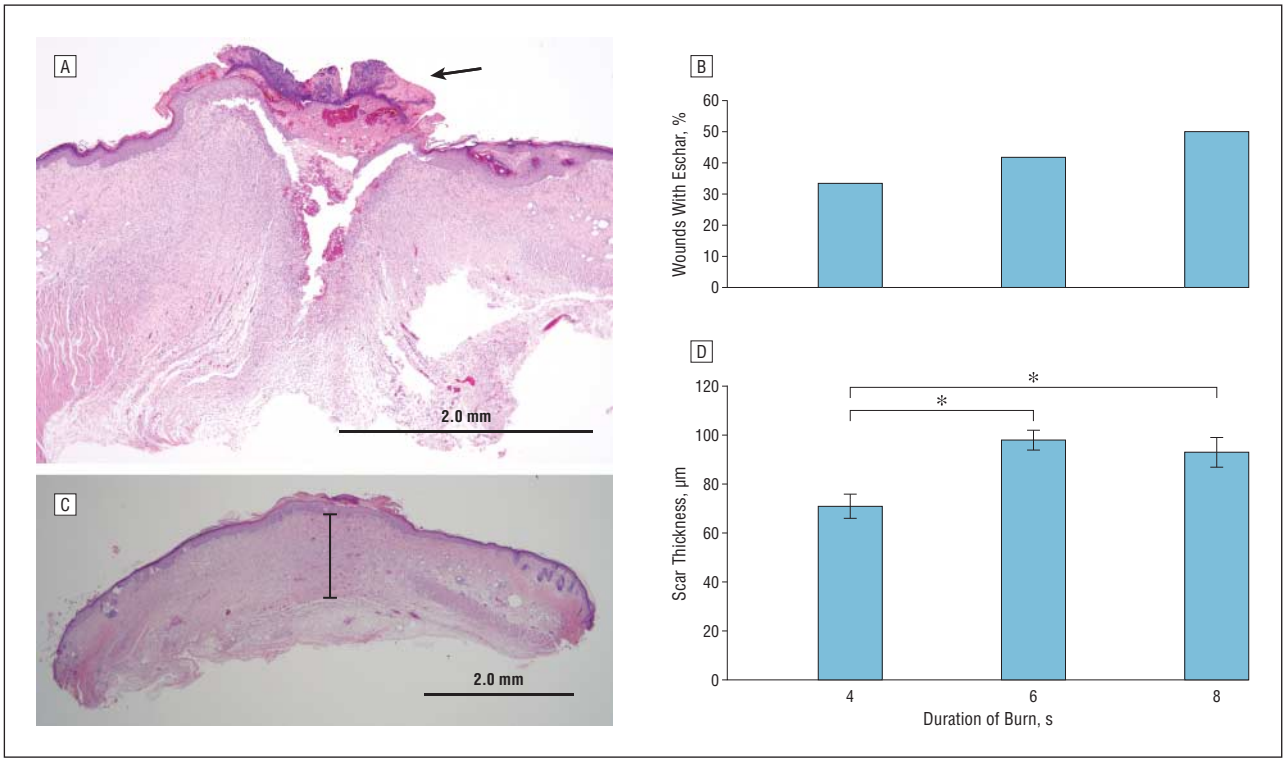

Figure 1. Histological analysis. A, An eschar (arrow) with inflammatory infiltrate at 21 days after burn wounding (hematoxylin-eosin). B, The percentage of wounds with eschar on day 21. C, Measurement of scar thickness in a hematoxylin-eosin–stained section. D, Mean (SEM) scar thickness on day 21. *$P<.05$ (analysis of variance with Tukey test) (n=12).

EFFECT OF BURN SEVERITY ON TISSUE PERFUSION

We reasoned that, if the mobilization of CACs played an important role in the increased tissue perfusion that is required for effective wound healing, then the delay in CAC mobilization should result in a delay in tissue perfusion. To test this hypothesis, blood flow was measured by LDPI on days 3, 7, and 14 after burn wounding. The increase in wound perfusion on day 7 was progressively impaired as the severity of the burn increased ($P<.01$, 2-way ANOVA with Tukey test; **Figure 3**). By day 14, when the wound areas were approximately 30% of their original size, tissue perfusion was returning to normal levels, and differences between groups were no longer observed. Thus, burn severity affected the magnitude of the increase in blood flow associated with wound healing.

EFFECT OF BURN SEVERITY ON WOUND VASCULARIZATION

We reasoned that the differences in perfusion reflected differences in tissue vascularization. To test this hypothesis, we performed vascular morphometry on sections of the excised wounds on day 21 by immunohistochemical staining for CD31 and SMA. The number of CD31- or SMA-positive vessels within a ×200-magnified field at the center of each wound was determined. There was a progressive decrease in the number of CD31-positive (**Figure 4**A-C) and SMA-positive (Figure 4D-F) vessels as burn duration increased from 4 to 8 seconds ($P<.01$, 1-way ANOVA with Tukey test, for both CD31 and SMA).

EFFECT OF BURN SEVERITY ON WOUND CLOSURE

We reasoned that impaired vascularization would lead to impaired wound closure. To test this hypothesis, we analyzed wound closure on day 21 by computerized planimetry. As burn duration increased, wound closure was significantly delayed ($P<.001$, 1-way ANOVA with Tukey test; **Figure 5**).

CAC MOBILIZATION AFTER THERMAL INJURY IN HUMAN PATIENTS

To investigate the clinical relevance of findings from the murine model, we analyzed CAC mobilization in patients with burn wounds using the same validated culture assay.[16] Thirty-one patients (24 men and 7 women) were enrolled for the study. The mean age was 39 (range, 19-59) years. The mean burn surface area was 13% (range, 1%-64%). One to 3 serial blood samples were obtained from each patient. Levels of CACs were increased at the earliest time point examined (between 12 and 24 hours) in all patients and remained elevated through 48 hours (**Figure 6**). On day 3, the number of CACs started to decline, and they reached a plateau that extended to greater than 6 weeks from the time of injury, suggesting a return to baseline levels.

©2010 American Medical Association. All rights reserved.
Downloaded From: http://archsurg.jamanetwork.com/ on 10/10/2015

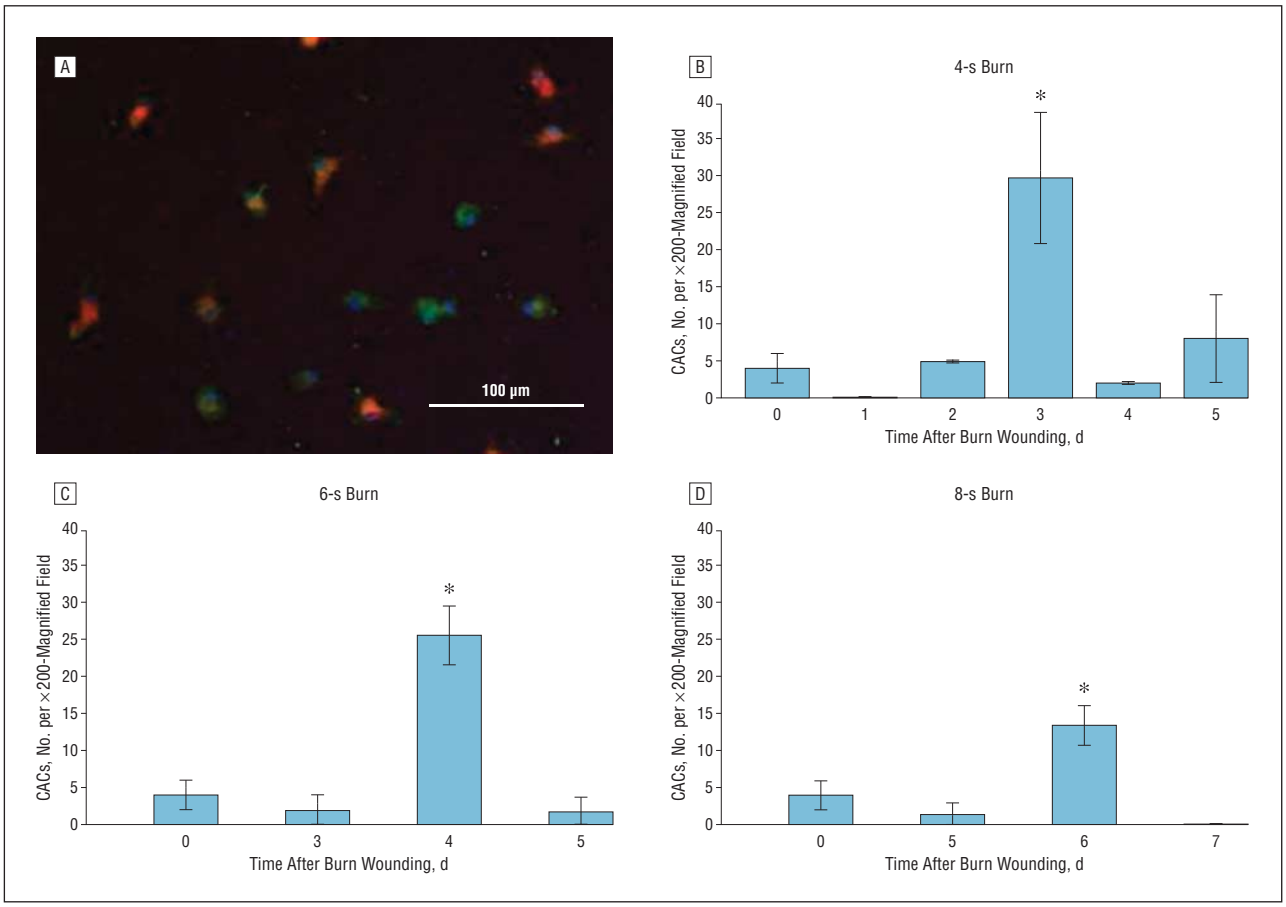

Figure 2. Analysis of circulating angiogenic cells (CACs) in the peripheral blood of mice subjected to burns of increasing duration. A, Mouse peripheral blood mononuclear cells cultured in the presence of endothelial growth factors were stained with fluorescein isothiocyanate–labeled lectin (green) and 1,1′-dioctadecyl-3,3,3′,3′-tetramethylindocarbocyanine–labeled acetylated low-density lipoprotein (red). B-D, Mice were subjected to 4-, 6-, and 8-second burns, respectively, and peripheral blood was analyzed for the presence of CACs on the indicated day after burn wounding (day 0, nonburned control subjects). *$P<.05$ compared with day 0 (unpaired *t* test).

COMMENT

Previous clinical studies have revealed increased numbers of CACs after burn wounding.[18,19] This study of the phenomenon in the murine model allows for a more systematic evaluation of the factors that influence the dynamics of mobilization of CACs than is possible within the constraints of a clinical study. Increased mobilization might result from increased tissue ischemia, resulting in increased production of angiogenic factors that induce CAC mobilization, as is seen in limb and cardiac ischemia models.[15,24] Alternatively, tissue destruction might result in the loss of cells capable of producing these factors.

To answer this question, we used a murine burn wound model, in which increasing duration of burn contact resulted in burn wounds of increasing severity. We have demonstrated that burns of increasing severity result in delayed and diminished mobilization of CACs. Impaired CAC mobilization and reduced blood flow were observed in wounds of increasing severity, which suggests that the progressive impairment of perfusion associated with increasing burn duration is caused not only by direct destruction of preexisting vasculature with more severe burns but also by impaired neovascularization resulting from the delay in CAC mobilization. Further studies are needed to test this hypothesis.

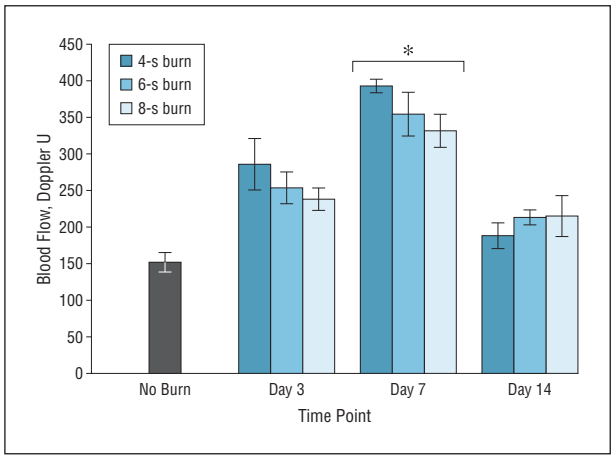

Figure 3. Analysis of wound blood flow. Laser Doppler perfusion imaging was performed on days 3, 7, and 14 after burning and is depicted as mean (SEM) blood flow. *$P<.01$ (analysis of variance with Tukey test) (n=8 for each group).

In contrast to the sharp peaks of CAC mobilization in the murine model, the clinical study showed a sustained increase in CAC levels during the first 48 hours after burn wounding. Extensive human burns include areas of superficial and deep wounding; thus, the sustained increase in CAC levels may represent integration

©2010 American Medical Association. All rights reserved.
Downloaded From: http://archsurg.jamanetwork.com/ on 10/10/2015

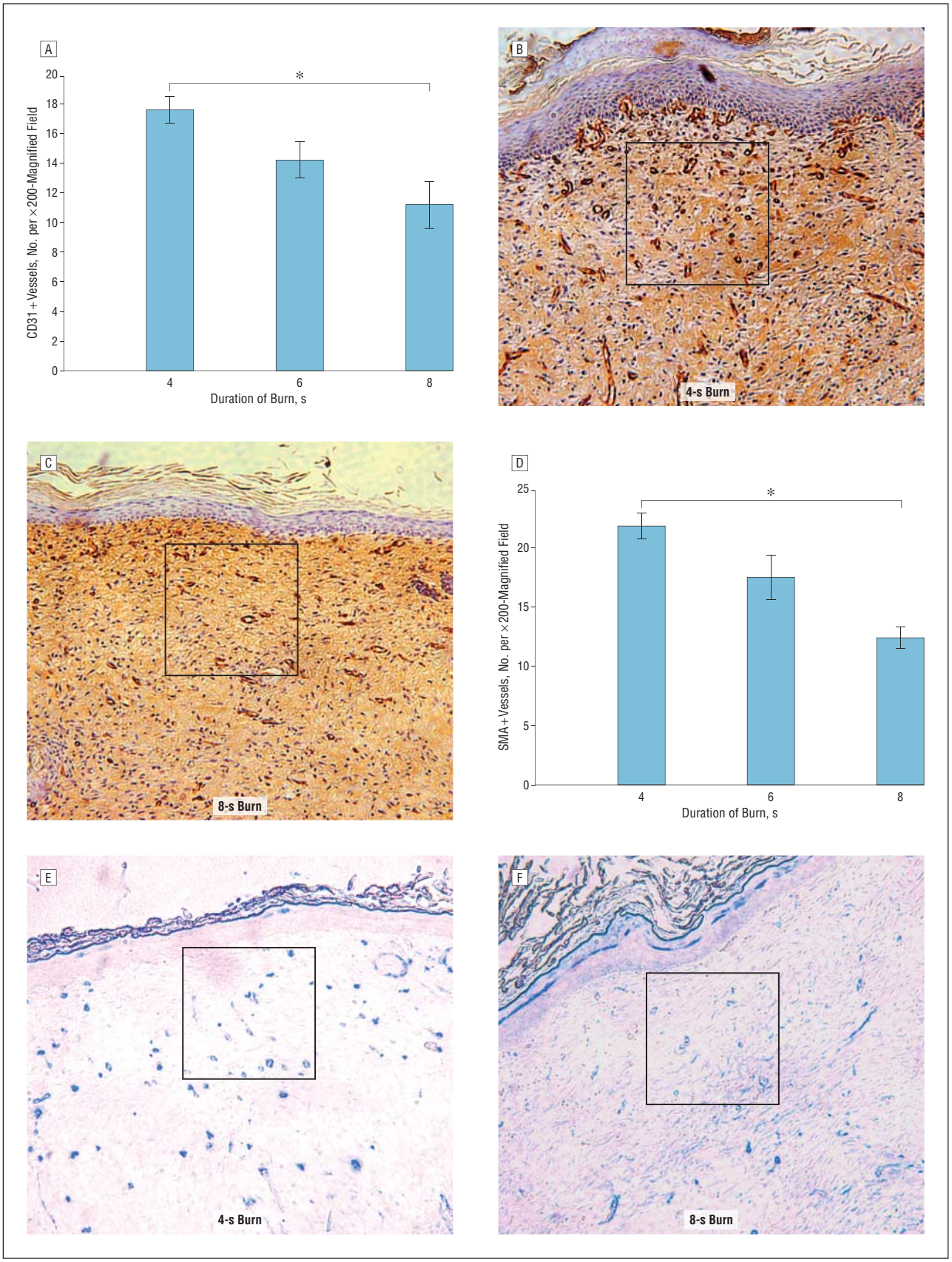

Figure 4. Immunohistochemical analysis of wound vascularization. A, Mean (SEM) vessel counts with CD31 staining per ×200-magnified field. *P=.009 (analysis of variance [ANOVA] with Tukey test) (8 samples for each group). B and C, The central portion of 4- and 8-second burn wounds, respectively, on day 21 stained with an antibody against CD31 (PECAM-1), which is expressed by vascular endothelial cells. D, Mean (SEM) number of vessels with smooth muscle actin (SMA) staining per ×200-magnified field. *P=.02 (ANOVA with Tukey test) (8 samples for each group). E and F, The central portion of 4- and 8-second burn wounds, respectively, on day 21 stained with an antibody against SMA, which is expressed by vascular pericytes and smooth muscle cells.

©2010 American Medical Association. All rights reserved.
Downloaded From: http://archsurg.jamanetwork.com/ on 10/10/2015

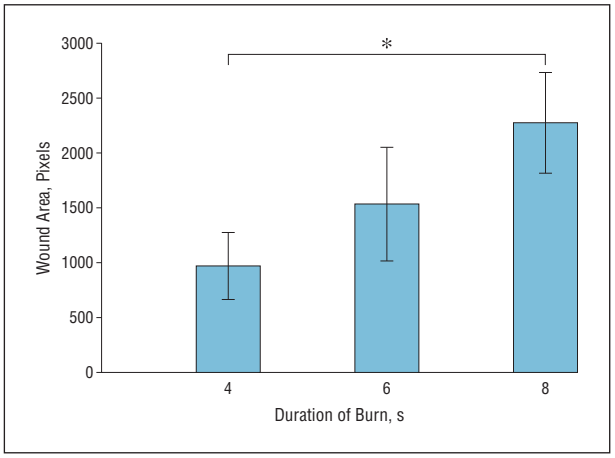

Figure 5. Analysis of burn wound closure. The wound area was measured by computer-assisted planimetry on day 21, and the mean (SEM) wound area is plotted. *$P<.001$ (analysis of variance with Tukey test) (8 samples for each group).

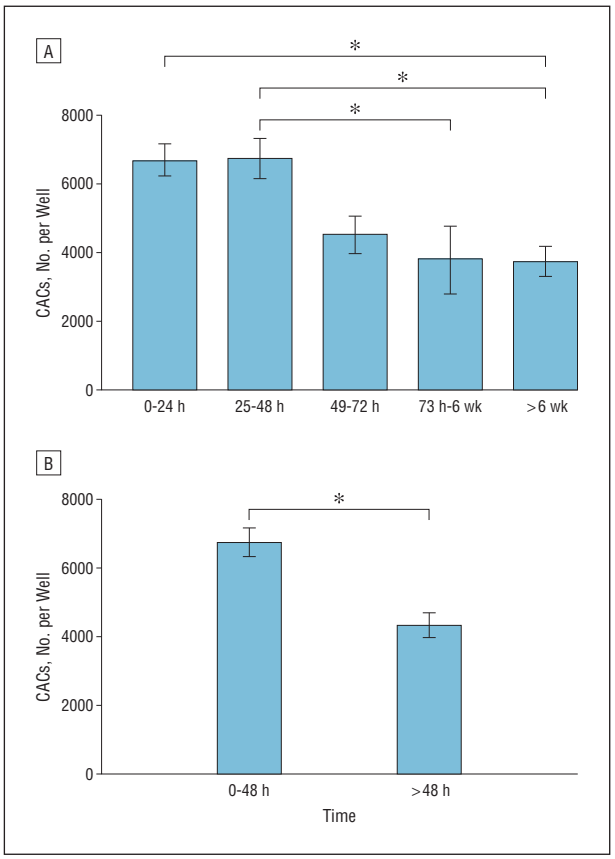

Figure 6. Mean (SEM) circulating angiogenic cell (CAC) levels in patients with burn injuries at intervals after injury. A, Serial analysis of CACs in the patients. Levels of CACs were quantified in blood samples (using 7, 15, 7, 5, and 8 samples for the sequential time periods studied). *$P<.05$ (analysis of variance). B, Comparison of samples drawn in the first 48 hours after injury with later samples. The data were pooled into 2 groups. *$P<.001$ (t test, using 22 samples at 0-48 hours and 20 samples at >48 hours).

of the early and delayed responses that were observed in the murine model. However, there are likely to be many other factors that contribute to differences between the experimental and clinical data. The reduced magnitude of CAC mobilization in the patients may reflect the effect of aging or cardiovascular disease risk factors.[16,17,24]

The mouse model will be useful for investigating the cellular and molecular mechanisms by which aging, genetic background, and chronic diseases such as diabetes influence burn wound healing. If CAC mobilization and wound perfusion are important determinants of clinical outcome, then strategies designed to augment angiogenic responses may improve outcome in patients with severe burn wounds. Further analysis of the molecular mechanisms regulating CAC mobilization and recruitment to burn wounds in the mouse model will provide a scientific foundation for the rational development of effective therapies.

Accepted for Publication: May 15, 2009.
Correspondence: John W. Harmon, MD, Section of Surgical Sciences, Room 5C, A Building, Johns Hopkins Bayview Medical Center, 4940 Eastern Ave, Baltimore, MD 21224 (jharmon2@jhmi.edu).
Author Contributions: Drs Zhang, Wei, and Liu contributed equally to this project. *Study concept and design:* Spence, Jeng, Milner, Harmon, and Semenza. *Acquisition of data:* Zhang, Wei, Liu, Marti, Ghanamah, Arshad, and Strom. *Analysis and interpretation of data:* Zhang, Marti, and Semenza. *Drafting of the manuscript:* Harmon. *Critical revision of the manuscript for important intellectual content*: Zhang, Wei, Liu, Marti, Ghanamah, Arshad, Strom, Spence, Jeng, Milner, and Semenza. *Obtained funding:* Milner, Harmon, and Semenza. *Administrative, technical, and material support:* Zhang, Wei, Liu, Marti, Ghanamah, Arshad, and Strom. *Study supervision:* Spence, Jeng, Milner, Harmon, and Semenza.
Financial Disclosure: None reported.
Funding/Support: This study was supported by Public Health Service grant P20-GM78494 from the National Institutes of Health; the Hendrix Burn Fund, Johns Hopkins Bayview Medical Center; Beijing Nova Star Plan grant 2004B29; funding from the China Scholarship Council; and the Johns Hopkins Institute for Cell Engineering.

REFERENCES

1. Brigham PA, McLoughlin E. Burn incidence and medical care use in the United States: estimates, trends, and data sources. *J Burn Care Rehabil.* 1996;17(2):95-107.
2. Kerby JD, McGwin G Jr, George RL, Cross JA, Chaudry IH, Rue LW III. Sex differences in mortality after burn injury: results of analysis of the National Burn Repository of the American Burn Association. *J Burn Care Res.* 2006;27(4):452-456.
3. Sheridan RL. Burn care: results of technical and organizational progress. *JAMA.* 2003;290(6):719-722.
4. Druecke D, Lamme EN, Hermann S, et al. Modulation of scar tissue formation using different dermal regeneration templates in the treatment of experimental full-thickness wounds. *Wound Repair Regen.* 2004;12(5):518-527.
5. Devgan L, Bhat S, Aylward S, Spence RJ. Modalities for the assessment of burn wound depth. *J Burns Wounds.* 2006;5:e2. http://www.ncbi.nlm.nih.gov/pmc/articles/PMC1687143/pdf/jobw05e2.pdf. Accessed April 22, 2008.
6. Tredget EE. The basis of fibrosis and wound healing disorders following thermal injury. *J Trauma.* 2007;62(6)(suppl):S69.
7. Jackson DM. The diagnosis of the depth of burning. *Br J Surg.* 1953;40(164):588-596.
8. O'Reilly TJ, Spence RJ, Taylor RM, Scheulen JJ. Laser Doppler flowmetry evaluation of burn wound depth. *J Burn Care Rehabil.* 1989;10(1):1-6.
9. Kim DE, Phillips TM, Jeng JC, et al. Microvascular assessment of burn depth conversion during varying resuscitation conditions. *J Burn Care Rehabil.* 2001;22(6):406-416.

©2010 American Medical Association. All rights reserved.
Downloaded From: http://archsurg.jamanetwork.com/ on 10/10/2015

10. Holland AJ, Martin HC, Cass DT. Laser Doppler imaging prediction of burn wound outcome in children. *Burns*. 2002;28(1):11-17.
11. Jeng JC, Bridgeman A, Shivnan L, et al. Laser Doppler imaging determines need for excision and grafting in advance of clinical judgment: a prospective blinded trial. *Burns*. 2003;29(7):665-670.
12. Barachini P, Vezzoni GM, Palombo C, Franzoni F, Bigalli G. Skin blood flow pattern in burns outcomes. *Burns*. 2004;30(4):312-316.
13. Hemington-Gorse SJ. A comparison of laser Doppler imaging with other measurement techniques to assess burn depth. *J Wound Care*. 2005;14(4):151-153.
14. Asahara T, Murohara T, Sullivan A, et al. Isolation of putative progenitor endothelial cells for angiogenesis. *Science*. 1997;275(5302):964-967.
15. Losordo DW, Dimmeler S. Therapeutic angiogenesis and vasculogenesis for ischemic disease, part II: cell-based therapies. *Circulation*. 2004;109(22):2692-2697.
16. Dimmeler S, Aicher A, Vasa M, et al. HMG-CoA reductase inhibitors (statins) increase endothelial progenitor cells via the PI 3-kinase/Akt pathway. *J Clin Invest*. 2001;108(3):391-397.
17. Vasa M, Fichtlscherer S, Aicher A, et al. Number and migratory activity of circulating endothelial progenitor cells inversely correlate with risk factors for coronary artery disease. *Circ Res*. 2001;89(1):e1-e7 doi:10.1161/hh1301.093953.
18. Gill M, Dias S, Hattori K, et al. Vascular trauma induces rapid but transient mobilization of VEGFR2$^+$AC133$^+$ endothelial precursor cells. *Circ Res*. 2001;88(2):167-174.
19. Fox A, Smythe J, Fisher N, et al. Mobilization of endothelial progenitor cells into the circulation in burned patients. *Br J Surg*. 2008;95(2):244-251.
20. Light TD, Jeng JC, Jain AK, et al. The 2003 Carl A. Moyer Award: real-time metabolic monitors, ischemia-reperfusion, titration endpoints, and ultraprecise burn resuscitation. *J Burn Care Rehabil*. 2004;25(1):33-44.
21. Hirsch T, von Peter S, Dubin G, et al. Adenoviral gene delivery to primary human cutaneous cells and burn wounds. *Mol Med*. 2006;12(9-10):199-207.
22. Kobayashi M, Yoshida T, Takeuchi D, et al. Gr-1$^+$CD11b$^+$ cells as an accelerator of sepsis stemming from *Pseudomonas aeruginosa* wound infection in thermally injured mice. *J Leukoc Biol*. 2008;83(6):1354-1362.
23. Mizutani A, Enkhbaatar P, Esechie A, et al. Pulmonary changes in a mouse model of combined burn and smoke inhalation–induced injury. *J Appl Physiol*. 2008;105(2):678-684.
24. Bosch-Marcé M, Okuyama H, Wesley JB, et al. Effects of aging and hypoxia-inducible factor-1 activity on angiogenic cell mobilization and recovery of perfusion after limb ischemia. *Circ Res*. 2007;101(12):1310-1318.

INVITED CRITIQUE

The Future of CACs in Wound Healing

This seminal article by Zhang et al demonstrates the crucial role of CACs in delayed healing in general and in burns in particular. This report advances research in the wound field in that it provides a unique model that demonstrates a similar physiologic response of CACs in burned mice and in human patients with burn injuries. Despite the dissimilarities in magnitude and duration of CAC mobilization between the 2 populations, the authors demonstrate the importance of the study of CAC mobilization in the experimental and human groups.

Zhang and colleagues have developed a superior burn wound–healing model that correlated angiogenic response to the depth of the burn. By precisely regulating burn depth, they found a delay in mobilization of CACs, exemplified by the progressive decrease in peak mobilization correlated with increasing burn duration. This model allows researchers in the field to investigate the contribution of injury not only to direct tissue destruction but also to its effect on wound angiogenesis. This is demonstrated by the significant immunohistochemical finding of decreased numbers of CD31- and SMA-positive vessels observed with increased burn duration.

Experimental models have previously demonstrated the contribution of CACs in the repair of endothelial function and reduced neointimal formation after arterial injury. In one study,[1] lipopolysaccharide-induced endothelial injury in rats demonstrated a 40% decrease in endothelial cells, which returned to normal after 24 hours. This finding was correlated with a 3-fold increase in the percentage of CACs, supporting the hypothesis that endothelial injury caused by inflammation activates CAC mobilization. Although the mechanisms of activation and mobilization have yet to be fully elucidated in humans, it is evident that CACs maintain a crucial role in the inflammatory response through their effect on angiogenesis and vascular repair.[2]

Although extensively studied in the cardiovascular and burn fields, the contribution of CAC advances has the potential to be applicable to multiple types of wounds in which decreased angiogenesis is present, such as diabetic[3] and ischemic[4] ulcers. Furthermore, no biological treatment is currently available for pressure ulcers in the United States. Because these wounds have been associated with ischemic injury and the subsequent cytokine response,[5] they may very well benefit clinically from CACs.

One unanswered question concerns the most optimal method for stimulating CAC mobilization at the site of the wound in patients to increase the angiogenic and healing response. Future work will be needed to bring angiogenic cell therapy to the clinic for burn-injured patients and potentially other patients with chronic wounds.

Jason Maggi, MD
Harold Brem, MD

Author Affiliations: Division of Wound Healing and Regenerative Medicine, Department of Surgery, New York University School of Medicine, New York.
Correspondence: Dr Brem, Division of Wound Healing and Regenerative Medicine, Helen L. and Martin S. Kimmel Wound Healing Center, Department of Surgery, New York University School of Medicine, 301 E 17th St, Room 1027, New York, NY 10003 (harold.brem@nyumc.org).
Financial Disclosure: None reported.
Additional Information: Dr Maggi is a Helen L. and Martin S. Kimmel Research Fellow.

1. Nogueras S, Merino A, Ojeda R, et al. Coupling of endothelial injury and repair: an analysis using an in vivo experimental model. *Am J Physiol Heart Circ Physiol*. 2008;294(2):H708-H713.
2. Real C, Caiado F, Dias S. Endothelial progenitors in vascular repair and angiogenesis: how many are needed and what to do? *Cardiovasc Hematol Disord Drug Targets*. 2008;8(3):185-193.
3. Liu ZJ, Velazquez OC. Hyperoxia, endothelial progenitor cell mobilization, and diabetic wound healing. *Antioxid Redox Signal*. 2008;10(11):1869-1882.
4. Westvik TS, Fitzgerald TN, Muto A, et al. Limb ischemia after iliac ligation in aged mice stimulates angiogenesis without arteriogenesis. *J Vasc Surg*. 2009;49(2):464-473.
5. Saito Y, Hasegawa M, Fujimoto M, et al. The loss of MCP-1 attenuates cutaneous ischemia-reperfusion injury in a mouse model of pressure ulcer. *J Invest Dermatol*. 2008;128(7):1838-1851.

©2010 American Medical Association. All rights reserved.
Downloaded From: http://archsurg.jamanetwork.com/ on 10/10/2015