Image of the Month

Matthew G. Stanwix, MD; Barish H. Edil, MD

A HEALTHY 53-YEAR-OLD WOMAN WITH chronic lower back pain and radicular pain from a known herniated disk underwent routine imaging by her primary care physician. Magnetic resonance imaging demonstrated a new retroperitoneal 2.1×3.0–cm mass at the crus of the diaphragm not identified in an identical study 1 year prior. Further investigation into her history disclosed some flushing and hot flashes. However, she experienced no urinary symptoms (dysuria and hematuria), fevers, abdominal pain, nausea, vomiting, changes in bowel patterns, weight fluctuation, or heart palpitations. Physical examination revealed a normotensive, mildly overweight woman with no pain or masses appreciated on abdominal palpation. No neurological deficit was noted in the thoracic distribution, but bilateral lower lumbar radicular pain to the mid-thigh was reproduced with supine straight leg raising. Results of urinary tests, hormonal workup for a functional retroperitoneal tumor, and standard blood tests were unremarkable.

Author Affiliations: Department of Surgery, Johns Hopkins School of Medicine, Baltimore, Maryland.

Further delineation of the mass via a multiphase 3-dimensional computed tomographic scan showed a nonenhancing 2.1×3.0–cm smooth dominant homogeneous mass (83 Hounsfield units) abutting the left diaphragmatic crus with no adjacent stranding or bony erosion, though it was distinct from the left kidney and adrenal gland (**Figure 1**). The patient underwent surgical resection of the paraspinal mass, which lacked attachment to surrounding structures, and diagnosis was established through histology of the specimen (**Figure 2**). She had an uneventful hospital course and was discharged on the third postoperative day.

What Is the Diagnosis?

A. Diaphragmatic leiomyoma
B. Thoracic nerve root schwannoma
C. Foregut cyst, bronchogenic type
D. Paraspinal neurofibroma

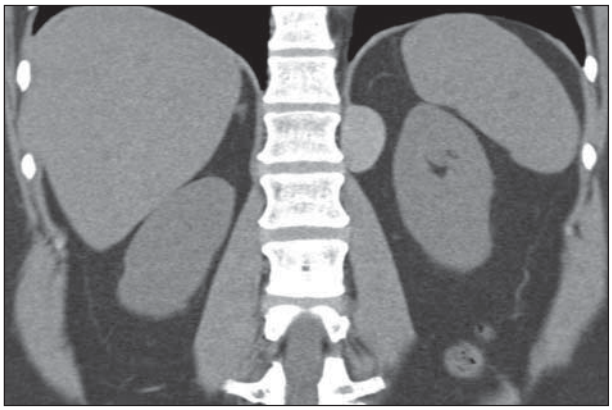

Figure 1. Coronal noncontrast computed tomography demonstrating a homogenous soft-tissue lesion intricately involved with the crus of the left diaphragm.

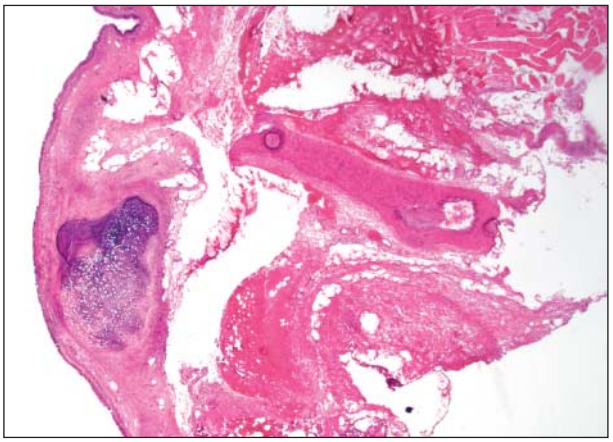

Figure 2. Cross-sectional histology of the specimen under low-power magnification (hematoxylin-eosin).

©2010 American Medical Association. All rights reserved.
Downloaded From: http://archsurg.jamanetwork.com/ on 09/22/2014