Image of the Month

David F. Schneider, MD; Francis J. Harford, MD; Joshua M. Eberhardt, MD

A 47-YEAR-OLD OBESE WOMAN PRESENTED TO the emergency department with an exacerbation of chronic, ill-defined, right lower quadrant and pelvic pain that radiated to the back and worsened with movement and defecation. She was afebrile, and physical examination was notable for mild tenderness to deep palpation in the lower quadrants. Rectal examination did not reveal any obvious abnormalities but she had a skin dimple just inferior to the coccyx. Computed tomography demonstrated a cystic fluid collection in the left ischiorectal fossa with a smaller cystic component extending superiomedially behind the rectum and inferior to the coccyx (**Figure 1**). Initially, the patient was treated via percutaneous drainage and intravenous antibiotics. Cultures of the aspirated fluid did not grow any organisms but her pain persisted, and colorectal surgery consultation was obtained. Further assessment included anoscopy and proctoscopy, which revealed no evidence of an internal opening, proctitis, or other intraluminal abnormality. Magnetic resonance imaging visualized the same lesion that persisted after percutaneous drainage. This study also confirmed that the mass did not connect with the spinal cord or sacrum. The patient was then scheduled for elective surgery, and the gross specimen is shown in **Figure 2**.

What Is the Diagnosis?

A. Chronic ischiorectal abscess.
B. Pilonidal cyst.
C. Presacral neoplasm.
D. Chordoma.

Author Affiliations: Loyola University Medical Center, Maywood, Illinois.

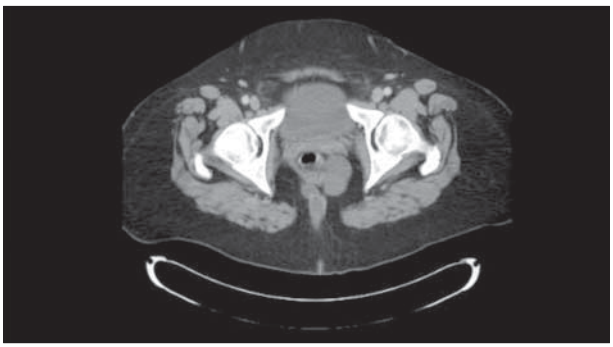

Figure 1. Cystic collection in left ischiorectal fossa with smaller component behind rectum and inferior to coccyx.

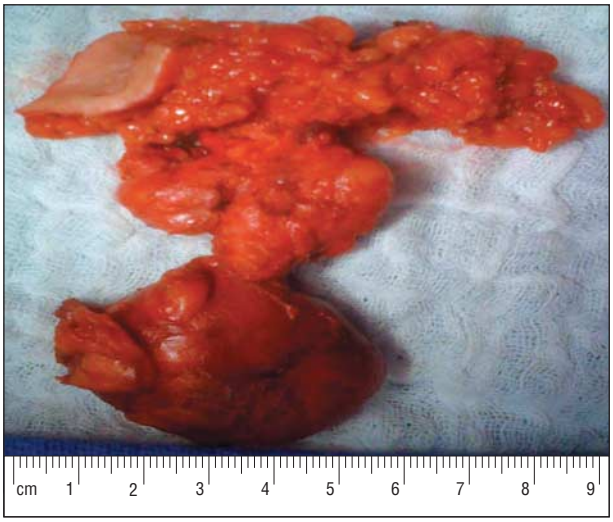

Figure 2. En bloc excision of dominant cystic component, attached satellite cyst, and overlying skin dimple.

©2010 American Medical Association. All rights reserved.
Downloaded From: http://archsurg.jamanetwork.com/ on 08/20/2014