Answer

Sister Mary Joseph Nodule

Histopathological examination of the skin biopsy specimen showed a cutaneous metastasis of an unknown primary adenocarcinoma. The patient was referred to the Department of Surgery, where a computed tomographic image was obtained. The image showed a large tumor of the sigmoid colon with metastasis to the abdominal wall (**Figure 2**). During the preoperative analysis, the patient developed an ileus for which surgical treatment was mandatory. The tumor was resected by one of us (B.A.B.) and included part of the visceral bladder, metastases of the peritoneum, and resection of the umbilical tumor.

Crohn disease is a granulomatous disease of the bowel that may affect other organs.[1] The skin is commonly involved, and the cutaneous manifestations may be nonspecific. Specific skin lesions of Crohn disease may be separated from the affected bowel by normal skin, a rare condition termed *metastatic Crohn disease*.

Infection of the umbilicus is a common skin finding because of the skin folds of the umbilicus, which in some cases are prone to intertriginous dermatitis and secondary impetigo. In this case, antibacterial therapy did not improve the lesion.

A primary umbilical adenocarcinoma is an extremely rare finding.[2] The differential diagnosis can also include benign skin tumors (eg, pyogenic granuloma and epidermal inclusion cysts) or primary malignant tumors (eg, nonmelanoma skin cancer and amelanotic melanoma), which are rare. In women, endometriosis can localize to the umbilicus.[3]

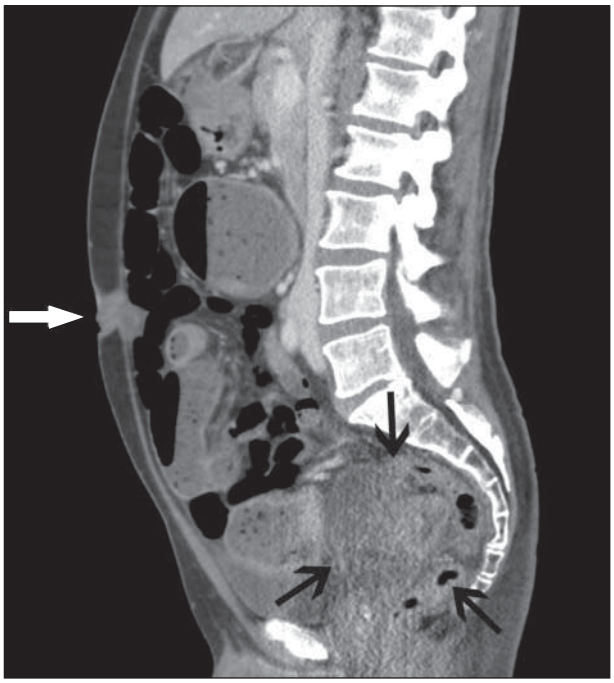

Figure 2. Sagittal computed tomographic image. The white arrow shows the Sister Mary Joseph nodule; the black arrows, a tumor mass in the sigmoid colon.

Metastatic cancer of the umbilicus is known as *Sister Mary Joseph nodule*, which is a rare physical sign encountered in 1% to 3% of patients with malignant neoplasms of the gastrointestinal tract and ovary. It presents as a firm, irregular nodule, 0.5 to 2 cm, that may ulcerate or become necrotic and is sometimes exudative with pus, blood, or serous fluid.[3] The nodule is named for Sister Mary Joseph (1856-1939), who was an assistant to William Mayo, the surgeon. She was the first to note the association between paraumbilical tumors observed during the preparation of the skin for surgery and metastatic intra-abdominal cancer confirmed at surgery. The umbilicus is a site of metastases (any of which is referred to as a *Sister Mary Joseph nodule*) for visceral tumors because of its generous vascular and embryologic connections.[4] Metastases occur via direct extension through the peritoneum by retrograde subserosal lymphatic spread or by venous vascular spread through anastomotic branches of the superficial epigastric, internal mammary, lateral thoracic, and portal veins. Embryologic remnants of the umbilical cord are the urachus; medial umbilical ligaments (obliterated umbilical arteries); ligamentum teres (obliterated left umbilical vein), which continues in the falciform ligament; and remnants of the omphalomesenteric duct. All these also represent possible routes for metastatic tumor cells.[5] The arterial blood supply is via the deep circumflex iliac artery and the inferior epigastric branches of the external iliac artery and the superior epigastric artery.[6] Sister Mary Joseph nodule is an ominous sign with a poor prognosis and denotes a life expectancy of less than 1 year.[3,5,6]

Accepted for Publication: December 4, 2009.
Correspondence: Roel E. Genders, MD, Department of Dermatology, Leiden University Medical Center, Albinusdreef 2, 2300 ZA Leiden, the Netherlands (r.e.genders@lumc.nl).
Author Contributions: *Study concept and design:* Genders, van der Molen, and Lavrijsen. *Acquisition of data:* Bonsing and van der Molen. *Analysis and interpretation of data:* Bonsing and van der Molen. *Drafting of the manuscript:* Genders. *Critical revision of the manuscript for important intellectual content:* Genders, Bonsing, van der Molen, and Lavrijsen. *Administrative, technical, and material support:* Genders. *Study supervision:* Lavrijsen.
Financial Disclosure: None reported.

REFERENCES

1. McLelland J, Griffin SM. Metastatic Crohn's disease of the umbilicus. *Clin Exp Dermatol.* 1996;21(4):318-319.
2. Alver O, Ersoy YE, Dogusoy G, Erguney S. Primary umbilical adenocarcinoma: case report and review of the literature. *Am Surg.* 2007;73(9):923-925.
3. Dubreuil A, Dompmartin A, Barjot P, Louvet S, Leroy D. Umbilical metastasis or Sister Mary Joseph's nodule. *Int J Dermatol.* 1998;37(1):7-13.
4. Abu-Hilal M, Newman JS. Sister Mary Joseph and her nodule: historical and clinical perspective. *Am J Med Sci.* 2009;337(4):271-273.
5. Gabriele R, Borghese M, Conte M, Basso L. Sister Mary Joseph's nodule as a first sign of cancer of the cecum: report of a case. *Dis Colon Rectum.* 2004;47(1):115-117.
6. Gabriele R, Conte M, Egidi F, Borghese M. Umbilical metastases: current viewpoint [published online February 21, 2005]. *World J Surg Oncol.* 2005;3(1):13. doi:10.1186/1477-7819-3-13.

©2011 American Medical Association. All rights reserved.
Downloaded From: http://archsurg.jamanetwork.com/ on 11/29/2014