PAPER

Critical Role of Identification of the Second Gland During Unilateral Parathyroid Surgery

A Prospective Review of 119 Patients With Concordant Localization

Nancy L. Cho, MD; Atul A. Gawande, MD, MPH; Eric G. Sheu, MD, DPhil; Francis D. Moore Jr, MD; Daniel T. Ruan, MD

Hypothesis: We aimed to validate the effectiveness of a protocol for primary hyperparathyroidism in which intraoperative parathyroid hormone measurement (IOPTH) was not routinely used during minimally invasive parathyroidectomy for patients with dual localization by technetium Tc 99m sestamibi (MIBI) and ultrasonography and hypothesized that our rate of surgical failure would be less than 3% for patients with concordant localization.

Design: Prospective cohort study.

Setting: Brigham and Women's Hospital, Boston, Massachusetts.

Patients: One hundred nineteen patients with primary hyperparathyroidism and dual localization.

Main Outcome Measures: Incidence of surgical cure following minimally invasive parathyroidectomy (MIP) without the use of IOPTH for patients with dual localization.

Results: A total of 324 patients with primary hyperparathyroidism underwent parathyroid exploration between October 1, 2005, and September 30, 2009. In 136 patients (42.0%), imaging was concordant by MIBI and ultrasonography, and 119 patients were scheduled for MIP. Our protocol for MIP without IOPTH was successful in 115 patients (97%), with 13 cases converted to bilateral exploration based on intraoperative suspicion of multiglandular disease. Eight of 13 conversions (62%) revealed multiglandular disease that was undetected on imaging, 6 of which were apparent from examination of the ipsilateral second parathyroid gland. Four of 136 patients (3%) had persistent postoperative hypercalcemia necessitating reoperation, and all 4 had an adjacent but unseen second adenoma. There was no significant difference in the surgical cure rate following MIP without IOPTH for this prospective study vs a previously published retrospective analysis by our group (97% vs 98%, $P=.47$).

Conclusions: Focused parathyroid gland exploration without IOPTH can be successfully performed in a select group of patients with dual localization by MIBI and ultrasonography. However, identification of the second ipsilateral gland may be critical to ruling out undetected multiglandular disease.

Arch Surg. 2011;146(5):512-516

Approximately 100 000 new cases of primary hyperparathyroidism (PHPT) are diagnosed in the United States each year.[1] Of these cases, most are caused by a single parathyroid adenoma (80%-87%), followed by 4-gland hyperplasia (10%-15%), multiple adenomas (2%-5%), and carcinoma (<1%). Recent advances in imaging modalities have enabled surgeons to offer a minimally invasive, or unilateral, approach for the surgical treatment of PHPT to patients with single-gland disease. A recent survey among members of the American Association of Endocrine Surgeons demonstrated a growing trend in the number of minimally invasive parathyroidectomies (MIPs) performed in 2008 (up to 92%).[2] Compared with traditional bilateral neck exploration, MIP allows surgeons to resect a single adenoma through a small incision without dissection on the contralateral side. As such, MIP offers patients the advantage of a smaller incision, decreased operative time, and fewer complications, such as nerve injury or permanent hypoparathyroidism.[3] In addition, many surgeons use intraoperative parathyroid hormone measurement (IOPTH) as an adjunct to MIP. However, the role of IOPTH in MIP remains controversial.

See Invited Critique at end of article

Our group previously published a retrospective study[4] investigating the role of IOPTH during MIP in cases of PHPT with concordant localization by technetium Tc 99m sestamibi (MIBI) and ultrasonography (US). Results showed that the surgical failure rate in patients with concor-

Author Affiliations:
Department of Surgery, Brigham and Women's Hospital, Boston, Massachusetts.

©2011 American Medical Association. All rights reserved.
Downloaded From: http://archsurg.jamanetwork.com/ on 10/10/2015

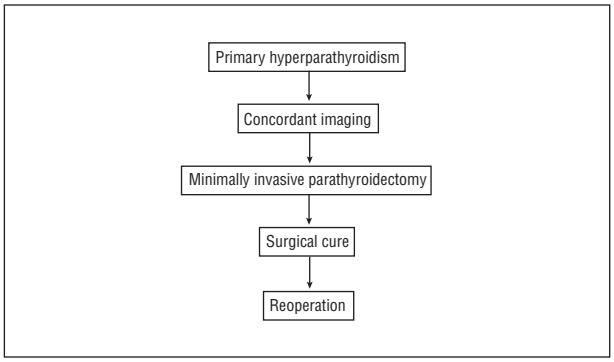

Figure 1. Flowchart of the study design.

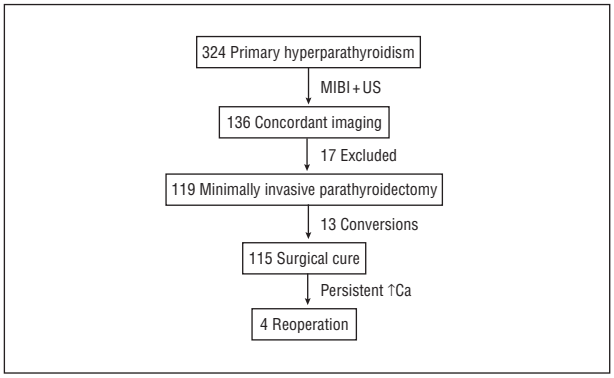

Figure 2. Summary of results. Our study protocol was implemented for all patients with primary hyperparathyroidism and concordant localization by technetium Tc 99m sestamibi (MIBI) and ultrasonography (US) undergoing minimally invasive parathyroidectomy without intraoperative parathyroid hormone level measurement. ↑Ca indicates elevated calcium level.

dant imaging was 1% with IOPTH vs 2% without IOPTH ($P = .50$), leading to the conclusion that the use of IOPTH does not significantly increase the success of MIP for patients with dual localization. Additional studies[5-8] have corroborated the findings. Overall, the literature suggests a surgical success rate of 95% to 97.5% without IOPTH vs 97% to 99% with IOPTH.[9-13]

Herein, we present our institution's prospective experience with unilateral parathyroid gland exploration since the original publication by our group. Based on the prior study, we designed a new protocol for performing MIP without IOPTH in patients with concordant localization by MIBI and US. We sought to validate the effectiveness of this new protocol through a prospective study and hypothesized that our rate of surgical failure would be less than 3% for patients with concordant localization. Because upper and lower parathyroid glands can be accessed through the same small incision, our protocol also included identification of the ipsilateral second parathyroid gland to avoid missing undetected multiglandular disease.

METHODS

Under a protocol approved by the institutional review board of the Brigham and Women's Hospital, Boston, Massachusetts, we collected clinical data on all patients with PHPT undergoing US, sestamibi imaging, and parathyroidectomy at the hospital between October 1, 2005, and September 30, 2009. Patients with recurrent disease were excluded. Recorded data included the site of localization (if any) in each of the 2 imaging studies, the findings at surgical exploration, and postoperative calcium and parathyroid hormone measurements. We implemented our protocol for all patients with PHPT and concordant localization who qualified for MIP. Our outcome measurement was the incidence of surgical cure following MIP without the use of IOPTH. A representative study design is shown in **Figure 1**.

Imaging by MIBI was performed by administering 16 to 20 milliCurie (mCi) of MIBI intravenously and by obtaining early and delayed planar images (at 15 minutes and at 2-3 hours). Ultrasonography was performed primarily by dedicated radiologists using color and power Doppler imaging. The radiologists performing either study were not blind to prior imaging results.

If findings for either study were at least suggestive of a possible site for a parathyroid adenoma, we regarded the study as positive for localization. We considered MIBI and US imaging concordant if they both localized a single adenoma on the same side of a patient's neck. They were discordant if one localized an adenoma and the other did not or if they localized disease on opposite sides of the neck. Patients with concordant localization who were scheduled for bilateral neck exploration because of a history of renal failure, prior lithium use, or substantially enlarged glands on preoperative US (>2.5 cm) were excluded from the concordant group.

If MIBI and US imaging results were concordant, we performed MIP without IOPTH focused on that site with limited incision and without contralateral exploration. For all patients scheduled for MIP, we also examined the ipsilateral normal parathyroid gland to avoid missing undetected multiglandular disease. Cases were converted to bilateral neck exploration based on criteria for intraoperative suspicion of multiglandular disease, including the finding of an enlarged gland exceeding 2 cm during surgery, obscure anatomy, or an abnormal-appearing second ipsilateral gland.

Calcium and parathyroid hormone measurements were obtained at postoperative follow-up visits, generally 2 to 4 weeks following surgery, and we recorded whether these confirmed the resolution of hypercalcemia. We routinely repeat calcium level measurements approximately 3 and 6 months following surgery, and these levels were documented if obtained. If the patient remained persistently hypercalcemic with an inappropriately elevated parathyroid hormone level after parathyroidectomy, despite correct localization, this was considered a surgical failure.

The rates of surgical failure between the previous retrospective study and this study were compared using the 2-tailed Fisher exact test. $P < .05$ was considered statistically significant.

RESULTS

A total of 324 parathyroid gland surgical explorations for PHPT were performed at the Brigham and Women's Hospital between October 1, 2005, and September 30, 2009, by 3 endocrine surgeons (A.A.G., F.D.M., and D.T.R.) (**Figure 2**). In 188 patients, imaging was discordant, negative, or not obtained, or only a single localization study was performed (**Table 1**). In 136 patients (42.0%), MIBI and US imaging identified the same single site of disease (imaging was concordant). Seventeen patients were not offered MIP because of exclusion criteria, including renal failure, prior lithium use, or enlarged glands exceeding 2.5 cm on US, which are predisposing factors for multiglandular disease. One hundred nineteen patients were then scheduled for MIP without IOPTH, and

©2011 American Medical Association. All rights reserved.
Downloaded From: http://archsurg.jamanetwork.com/ on 10/10/2015

Table 1. Imaging Among Patients With Primary Hyperparathyroidism

Imaging	Patients, No. (%)
MIBI and US positive for same site, concordant	136 (42.0)
MIBI and US discordant	96 (29.6)
MIBI and US negative, no localization	38 (11.7)
Only 1 mode of imaging, MIBI or US, used	32 (10.0)
No imaging obtained	22 (6.8)
Total	**324** (100.0)

Abbreviations: MIBI, technetium Tc 99m sestamibi; US, ultrasonography.

our protocol was successful in 115 patients, for a 96.6% surgical cure rate. Four patients had persistent postoperative hypercalcemia necessitating reoperation.

As part of our new protocol, we also examined the ipsilateral second parathyroid gland among all patients scheduled for MIP in an effort to detect multiglandular disease. Among 119 patients originally scheduled for MIP, 13 cases were converted to bilateral exploration based on criteria for intraoperative suspicion of multiglandular disease, including an enlarged gland, obscure anatomy, or an abnormal-appearing second ipsilateral gland. Eight of 13 conversions ultimately revealed multiglandular disease that was undetected on preoperative imaging. Six of these cases were apparent from examination of the ipsilateral second parathyroid gland alone. A summary of the characteristics among patients undergoing conversion to bilateral neck exploration is given in **Table 2**. Twelve of 13 patients who underwent conversion to bilateral neck exploration were cured following their surgery. Patient 6 had persistent postoperative hypercalcemia, and reoperation demonstrated an intrathymic parathyroid adenoma, suggesting the presence of a supernumerary gland or incomplete resection of a lower parathyroid adenoma during the original operation.

Finally, of 4 surgical failures, all 4 had a near adjacent but unseen second adenoma on reoperation, suggesting that visualization of the second ipsilateral gland was incorrectly identified during the original surgery. Final pathology reports confirmed the presence of dual ipsilateral adenomas, and all patients experienced resolution of their hypercalcemia following reoperation. There was no significant difference in the surgical cure rate following MIP without IOPTH for this prospective study compared with our previously published retrospective analysis (97% vs 98%, $P = .47$).[4]

COMMENT

Minimally invasive parathyroidectomy offers attractive advantages over conventional bilateral neck exploration, including shorter operative time, improved cosmesis, decreased hospitalization, less postoperative recovery time, and reduced morbidity from recurrent laryngeal nerve injury and hypoparathyroidism.[3] In addition, both operations have similar outcomes in terms of durable cure.[12-14] However, the role of IOPTH during MIP in patients with concordant localization remains controversial. A previously published retrospective study[4] by our group demonstrated that IOPTH adds only marginal benefit during parathyroidectomy for patients with concordant localization by MIBI and US. In the present study, we prospectively studied all parathyroidectomies performed at our institution after adjusting our protocol to exclude IOPTH for patients with concordant preoperative localization studies. Although our conclusions from this study serve to corroborate the previous findings, we also identified several differences between the 2 studies.

There was a pronounced difference in the number of patients with concordant localization for this study vs the prior retrospective analysis (42% vs 57%, respectively). The previous study[4] also included patients from Rhode Island Hospital, Providence, so it is possible that selection bias had a role in the present study, which was conducted only at the Brigham and Women's Hospital. In addition, we have increased our endocrine surgical volume over the past several years, resulting in a referral pattern that includes fewer straightforward PHPT cases with concordant localization and more cases with equivocal or negative imaging. For such cases, it is our practice pattern to use IOPTH, obtain a high-resolution 4-dimensional computed tomographic imaging scan of the neck, or proceed with bilateral neck exploration in an effort to avoid missing undetected multiglandular disease. Ultimately, MIP without IOPTH is used only for a select group of patients and is not the most common surgical procedure we perform for patients with PHPT at our institution.

Our surgical failure rate in this study was higher than that of the retrospective study (3% vs 2%), but this difference was not statistically significant. Our surgical failures were all due to missed ipsilateral adenomas that were not seen during visualization of the ipsilateral gland. It is possible that IOPTH might have prevented these surgical failures, although the literature reports a false-negative rate for IOPTH of approximately 6% to 9%,[7,12,15] which is higher than our rate of surgical failure for PHPT without IOPTH (3%). Ironically, the accuracy of IOPTH is suboptimal in cases of multiglandular disease, where it would be most useful in unmasking undetected disease.[16,17] Furthermore, the use of IOPTH can be disadvantageous with regard to extending patient exposure to anesthesia, prompting unnecessary neck exploration because of false-negative readings, and adding costs to operating room time and assay runs.

To address the issue of cost-effectiveness of IOPTH, Morris et al[18] published an analysis in 2010 examining the value of IOPTH in localized PHPT and concluded that IOPTH was cost saving only when the rate of unrecognized multiglandular disease exceeded 6% at a given institution or if the cost of reoperation exceeded $12 000. Although costs for surgery, complications, and IOPTH will vary among institutions, the overall findings of the study are that IOPTH increased the cure rate only marginally, while incurring approximately 4% additional cost. A study by Agarwal et al[15] examined the cost-effectiveness of performing IOPTH during MIP and demonstrated that the true cost of using IOPTH to avoid a failed operation was close to $20 000, with 8% of patients undergoing unnecessary conversion to bilateral neck exploration because of false-negative readings. Based on these data, IOPTH seems

©2011 American Medical Association. All rights reserved.
Downloaded From: http://archsurg.jamanetwork.com/ on 10/10/2015

Table 2. Characteristics of Patients Undergoing Conversion to Bilateral Neck Exploration

Patient No./Sex/Age, y	Calcium Level, mg/dL[a]	Parathyroid Hormone Level, pg/mL[a]	Abnormal Second Gland	Pathologic Findings
1/M/72	12.7	480	Yes	Double adenomas
2/F/53	12.0	284	No; enlarged gland, 2.1 cm	Single adenoma
3/F/36	12.6	254	No; obscure anatomy	Single adenoma
4/M/45	11.1	173	No; enlarged gland, 2.3 cm	Single adenoma
5/F/80	11.1	114	Yes	4-Gland hyperplasia
6/F/58	11.2	101	Yes	Double adenomas
7/F/54	11.3	93	Yes	4-Gland hyperplasia
8/F/53	11.5	108	No; enlarged gland, 1.3 cm (hemorrhagic)	Single adenoma
9/F/61	10.5	168	No; obscure anatomy	Double adenomas
10/F/48	12.3	257	No; enlarged gland, 2.4 cm	Double adenomas
11/F/62	10.8	90	No; obscure anatomy	Single adenoma
12/F/58	11.0	79	Yes	Double adenomas
13/F/53	11.3	91	Yes	Double adenomas

SI conversion factors: To convert calcium to millimoles per liter, multiply by 0.25; parathyroid hormone to nanograms per liter, multiply by 1.0.
[a] The calcium and parathyroid values shown are the highest levels recorded for each patient.

neither beneficial nor cost-effective for most patients having PHPT with concordant localization. The question remains: in which patients with dual localization is IOPTH warranted?

Siperstein et al[19] published the largest study to date investigating the prevalence of undetected multiglandular disease among patients who were candidates for MIP. They reported unsuspected multiglandular disease in 20% of their patient population with concordant localization by MIBI and US, which was identified on bilateral neck exploration. They also found that the use of IOPTH during these cases decreased the rate of undetected multiglandular disease to only 16%. However, it is important to note that controversy exists about the definition of multiglandular disease, in which some surgeons base their criteria on gland size or histopathologic findings, whereas others argue that neither factor correlates with secretory activity. As demonstrated by our data, identification of an abnormal second gland revealed the presence of double adenomas or multiglandular disease in 6 patients, despite dual localization. In this situation, IOPTH may have a useful role in guiding the appropriate excision of additional abnormal glands that are inadvertently discovered during surgery. Overall, we support the use of IOPTH in patients with PHPT who have dual localization and ambiguous or unexpected operative findings, all of which further supports the importance of correctly identifying the ipsilateral second gland.

As a result of our study, we concur with the prior conclusions of our group that IOPTH during unilateral parathyroid exploration provides no significant benefit for patients with dual localization uncovered by MIBI and US. However, we found that identification of the second ipsilateral gland has a critical role in ruling out undetected multiglandular disease when IOPTH is not used. Because our surgical failures were due to missed adjacent adenomas, despite intraoperative examination of the ipsilateral parathyroid gland, we have adjusted our current protocol to include a frozen section biopsy specimen of the ipsilateral gland to obtain pathological confirmation that the tissue in question is truly parathyroid rather than a lymph node or fatty tissue. We also recognize that, while not a perfect assay, IOPTH can have an important role in patients with equivocal imaging, obscure anatomy, or intraoperative suspicion for multiglandular disease.

Accepted for Publication: January 3, 2011.
Correspondence: Nancy L. Cho, MD, Department of Surgery, Brigham and Women's Hospital, 75 Francis St, Boston, MA 02115 (nlcho@partners.org).
Author Contributions: The authors had full access to all the data in the study and take responsibility for the integrity of the data and the accuracy of the data analysis. *Study concept and design:* Cho, Gawande, Moore, and Ruan. *Acquisition of data:* Cho, Gawande, Sheu, Moore, and Ruan. *Analysis and interpretation of data:* Cho, Gawande, Sheu, Moore, and Ruan. *Drafting of the manuscript:* Cho. *Critical revision of the manuscript for important intellectual content:* Cho, Gawande, Sheu, Moore, and Ruan. *Statistical analysis:* Cho and Gawande. *Study supervision:* Gawande, Moore, and Ruan.
Financial Disclosure: None reported.
Previous Presentations: This study was presented at the 91st Annual Meeting of the New England Surgical Society; October 29, 2010; Saratoga Springs, New York.

REFERENCES

1. Kebebew E, Clark OH. Parathyroid adenoma, hyperplasia, and carcinoma: localization, technical details of primary neck exploration, and treatment of hypercalcemic crisis. *Surg Oncol Clin N Am.* 1998;7(4):721-748.
2. Sackett WR, Barraclough B, Reeve TS, Delbridge LW. Worldwide trends in the surgical treatment of primary hyperparathyroidism in the era of minimally invasive parathyroidectomy. *Arch Surg.* 2002;137(9):1055-1059.
3. Norman J, Chheda H, Farrell C. Minimally invasive parathyroidectomy for primary hyperparathyroidism: decreasing operative time and potential complications while improving cosmetic results. *Am Surg.* 1998;64(5):391-396.
4. Gawande AA, Monchik JM, Abbruzzese TA, Iannuccilli JD, Ibrahim SI, Moore FD Jr. Reassessment of parathyroid hormone monitoring during parathyroidectomy for primary hyperparathyroidism after 2 preoperative localization studies. *Arch Surg.* 2006;141(4):381-384.
5. Smith N, Magnuson JS, Vidrine DM, Kulbersh B, Peters GE. Minimally invasive parathyroidectomy: use of intraoperative parathyroid hormone assays after 2 preoperative localization studies. *Arch Otolaryngol Head Neck Surg.* 2009;135(11):1108-1111.

©2011 American Medical Association. All rights reserved.
Downloaded From: http://archsurg.jamanetwork.com/ on 10/10/2015

6. Kebebew E, Hwang J, Reiff E, Duh QY, Clark OH. Predictors of single-gland vs multigland parathyroid disease in primary hyperparathyroidism: a simple and accurate scoring model. *Arch Surg*. 2006;141(8):777-782.
7. Stalberg P, Sidhu S, Sywak M, Robinson B, Wilkinson M, Delbridge L. Intraoperative parathyroid hormone measurement during minimally invasive parathyroidectomy: does it "value-add" to decision-making? *J Am Coll Surg*. 2006; 203(1):1-6.
8. Arici C, Cheah WK, Ituarte PHG, et al. Can localization studies be used to direct focused parathyroid operations? *Surgery*. 2001;129(6):720-729.
9. Chen H, Pruhs Z, Starling JR, Mack E. Intraoperative parathyroid hormone testing improves cure rates in patients undergoing minimally invasive parathyroidectomy. *Surgery*. 2005;138(4):583-590.
10. Mihai R, Palazzo FF, Gleeson FV, Sadler GP. Minimally invasive parathyroidectomy without intraoperative parathyroid hormone monitoring in patients with primary hyperparathyroidism. *Br J Surg*. 2007;94(1):42-47.
11. Pang T, Stalberg P, Sidhu S, et al. Minimally invasive parathyroidectomy using the lateral focused mini-incision technique without intraoperative parathyroid hormone monitoring. *Br J Surg*. 2007;94(3):315-319.
12. Udelsman R. Six hundred fifty-six consecutive explorations for primary hyperparathyroidism. *Ann Surg*. 2002;235(5):665-672.
13. Irvin GL III, Carneiro DM, Solorzano CC. Progress in the operative management of sporadic primary hyperparathyroidism over 34 years. *Ann Surg*. 2004;239 (5):704-711.
14. Grant CS, Thompson G, Farley D, van Heerden J. Primary hyperparathyroidism surgical management since the introduction of minimally invasive parathyroidectomy: Mayo Clinic experience. *Arch Surg*. 2005;140(5):472-479.
15. Agarwal G, Barakate MS, Robinson B, et al. Intraoperative quick parathyroid hormone versus same-day parathyroid hormone testing for minimally invasive parathyroidectomy: a cost-effectiveness study. *Surgery*. 2001;130(6):963-970.
16. Gauger PG, Agarwal G, England BG, et al. Intraoperative parathyroid hormone monitoring fails to detect double parathyroid adenomas: a 2-institution experience. *Surgery*. 2001;130(6):1005-1010.
17. Duh QY. What's new in general surgery: endocrine surgery. *J Am Coll Surg*. 2005; 201(5):746-753.
18. Morris LF, Zanocco K, Ituarte PHG, et al. The value of intraoperative parathyroid hormone monitoring in localized primary hyperparathyroidism: a cost analysis. *Ann Surg Oncol*. 2010;17(3):679-685.
19. Siperstein A, Berber E, Barbosa GF, et al. Predicting the success of limited exploration for primary hyperparathyroidism using ultrasound, sestamibi, and intraoperative parathyroid hormone: analysis of 1158 cases. *Ann Surg*. 2008; 248(3):420-428.

INVITED CRITIQUE

How Many Criteria Does It Take to Remove a Single Parathyroid Gland?

The traditional answer is 1 criterion, with 4-gland exploration finding a single adenoma and 3 normal glands. But over the last 20 to 30 years, there has been an increasing impetus to limit surgical exploration, fueled by a series of innovations. These methods to identify a single adenoma and to facilitate intraoperative decision making are MIBI imaging, high-resolution US, and rapid IOPTH. MIBI imaging is widely used, but IOPTH is not available at every institution, not all imaging systems are enhanced with single-photon emission computed tomography, and all ultrasonographers are not created equal, nor are all necks created equal in the eyes of the ultrasonographer.

How many items should a surgeon select from this menu to guide successful parathyroidectomy? The study by Cho et al in this issue of *Archives of Surgery* reports on the experience of the group at Brigham and Women's Hospital using only concordant MIBI and US imaging and the identification of a normal ipsilateral parathyroid gland to determine that the identified gland is indeed a solitary adenoma. Their group has previously shown that this approach yields a success rate similar to that achieved using IOPTH as an additional adjunct to decision making. The success rate in the present study was 96.6%, which is well within the accepted range quoted in the literature.

Discussions of how few or how many of the available adjuncts a surgeon should use are ongoing and I suspect will continue until other innovations supersede those available. However, I am concerned about accepting a gland imaged before surgery in conjunction with the identification of a normal ipsilateral gland as the sole determinants. Milas et al[1] found a 15.3% incidence of second adenomas, representing 127 of 828 patients studied. What was most concerning is that 82% of these second glands were on the opposite side of the neck. Preoperative imaging and identification of an ipsilateral gland alone do not offer the physiological components to success that a drop in parathyroid hormone level offers.

In the end, each surgeon must choose which adjuncts to use. MIBI imaging is well accepted, and US helps rule out thyroid nodules, which can cause false-positive MIBI imaging results. To me, the physiological reassurance of IOPTH is still valuable. The identification of a normal ipsilateral gland is yet another node in this complex equation, and I think it is a useful addition to the available factors in decision making.

Nicholas P. W. Coe, MD

Author Affiliation: Office of Surgical Education, Baystate Medical Center, Tufts University School of Medicine, Springfield, Massachusetts.
Correspondence: Dr Coe, Office of Surgical Education, Baystate Medical Center, Tufts University School of Medicine, 759 Chestnut St, Springfield, MA 01199 (nicholas.coe@bhs.org).
Financial Disclosure: None reported.

REFERENCE

1. Milas M, Wagner K, Easley KA, Siperstein A, Weber CJ. Double adenomas revisited: nonuniform distribution favors enlarged superior parathyroids (fourth pouch disease). *Surgery*. 2003;134(6):995-1004.

©2011 American Medical Association. All rights reserved.
Downloaded From: http://archsurg.jamanetwork.com/ on 10/10/2015