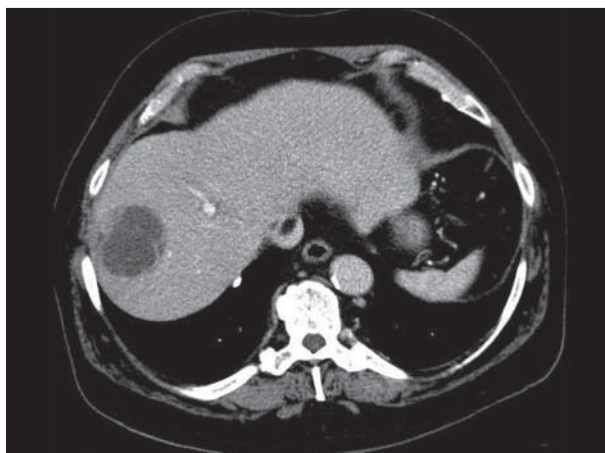


## Image of the Month

Ahmed Fouad Bouras Jr, MD; Stéphanie Truant, MD, PhD; Carlos Zerrweck, MD; Emmanuel Boleslawski, MD; François-René Pruvot, MD; Philippe Zerbib, MD, PhD

**A** 71-YEAR-OLD MAN WAS ADMITTED TO OUR hospital for a routine checkup, during which an incidental cystic mass in the liver was discovered. His past medical history included obesity (body mass index [calculated as weight in kilograms divided by height in meters squared], 34.7), 1.4 oz of daily alcohol consumption since adolescence, atrial fibrillation, and type 2 diabetes mellitus; past exposure to an endemic zone of hydatid disease was also documented. Blood analysis showed an elevated serum level of  $\gamma$ -glutamyl-transferase (90 U/L [to convert to microkatal per liter, multiply by 0.0167]), but the test results were within normal ranges; these included liver function tests, complete blood cell count, level of tumor markers, and serologic tests for amoebae and hydatid disease. Computed tomography revealed a dysmorphic liver and a 5-cm septated cystic mass of segment 8 with peripheral heterogeneous enhancement in portal and delayed phases, without enhancement in the arterial phase. There were internal septations but no calcifications in the wall (**Figure 1**). There was no portal hypertension on computed tomographic imaging, and a hepatic venous pressure gradient of 8 mmHg was reported. Also, magnetic resonance imaging was performed, not being contributory. Owing to an uncertain diagnosis, an exploratory laparotomy with complete cystic mass excision was con-



**Figure 1.** Cystic mass of segment 8 with peripheral enhancement in portal phase.

ducted. The operative findings were as follows: a cirrhotic liver and a cystic mass with a macroscopic benign aspect and a thick, black-colored fluid inside. Postoperative courses were uneventful.

### What Is the Diagnosis?

- A. Hydatid cyst
- B. Serous cystadenoma or cystadenocarcinoma
- C. Cystic hepatocellular carcinoma
- D. Liver abscess

**Author Affiliation:** Department of Digestive Surgery and Transplantations, Aile Ouest, Hopital Huriez, Lille, France.