ORIGINAL ARTICLE

Pancreatic Endocrine Tumors With Major Vascular Abutment, Involvement, or Encasement and Indication for Resection

Jeffrey A. Norton, MD; Edmund J. Harris, MD; Yijun Chen, MD; Brendan C. Visser, MD; George A. Poultsides, MD; Pamela C. Kunz, MD; George A. Fisher, MD; Robert T. Jensen, MD

Background: Surgery for pancreatic endocrine tumors (PETs) with blood vessel involvement is controversial.

Hypothesis: Resection of PETs with major blood vessel involvement can be beneficial.

Design: The combined databases of the National Institutes of Health and Stanford University hospitals were queried.

Main Outcome Measures: Operation, pathologic condition, complications, and disease-free and overall survival.

Results: Of 273 patients with PETs, 46 (17%) had preoperative computed tomography evidence of major vascular involvement. The mean size for the primary PET was 5.0 cm. The involved major vessel was as follows: portal vein (n=20), superior mesenteric vein or superior mesenteric artery (n=16), inferior vena cava (n=4), splenic vein (n=4), and heart (n=2). Forty-two of 46 patients had a PET removed: 12 (27%) primary only, 30 (68%) with lymph nodes, and 18 (41%) with liver metastases. PETs were removed by either enucleation (n=7) or resection (n=35). Resections included distal or subtotal pancreatectomy in 23, Whipple in 10, and total in 2. Eighteen patients had concomitant liver resection: 10 wedge resection and 8 anatomic resections. Nine patients had vascular reconstruction: each had reconstruction of the superior mesenteric vein and portal vein, and 1 had concomitant reconstruction of the superior mesenteric artery. There were no deaths, but 12 patients had complications. Eighteen patients (41%) were immediately disease free, and 5 recurred with follow-up, leaving 13 (30%) disease-free long term. The 10-year overall survival was 60%. Functional tumors were associated with a better overall survival ($P<.001$), and liver metastases decreased overall survival ($P<.001$).

Conclusion: These findings suggest that surgical resection of PETs with vascular abutment/invasion and nodal or distant metastases is indicated.

Arch Surg. 2011;146(6):724-732

Malignant pancreatic endocrine tumors (PETs) may have a good prognosis.[1-7] Unfortunately, a proportion present late with tumors that encase or invade adjacent major blood vessels.[8-10]

See Invited Critique at end of article

A number of studies have shown that vascular invasion in patients with both pancreatic adenocarcinomas and advanced PETs is associated with decreased survival.[2,4,11-15] The surgical approach to this group of patients is controversial. Based on analogies to pancreatic adenocarcinoma and limited experience with attempted surgical resection of patients with advanced PETs, for many, involvement of the superior mesenteric vein (SMV), inferior vena cava (IVC), portal vein (PV), splenic vein with extensive varices, superior mesenteric artery (SMA), aorta, or heart is considered a contraindication to surgery.[11,14,16]

Recent surgical series in pancreatic adenocarcinoma question this approach.[11,14,17-19] The operability of pancreatic tumors is usually defined by the results of computed tomography (CT).[9-11,14,20,21] However, these studies may not always accurately determine operability.[14] For example, in patients with adenocarcinoma of the pancreas, when preoperative CT suggests that the tumor involves the SMV, SMA, or PV, many surgeons say that it is inoperable.[11,14,17] However, recent studies dispute this thinking and suggest that these locally advanced tumors may

Author Affiliations: Stanford University Medical Center, Stanford, California (Drs Norton, Harris, Chen, Visser, Poultsides, Kunz, and Fisher); and National Institutes of Health, Bethesda, Maryland (Dr Jensen).

©2011 American Medical Association. All rights reserved.
Downloaded From: http://archsurg.jamanetwork.com/ on 07/29/2015

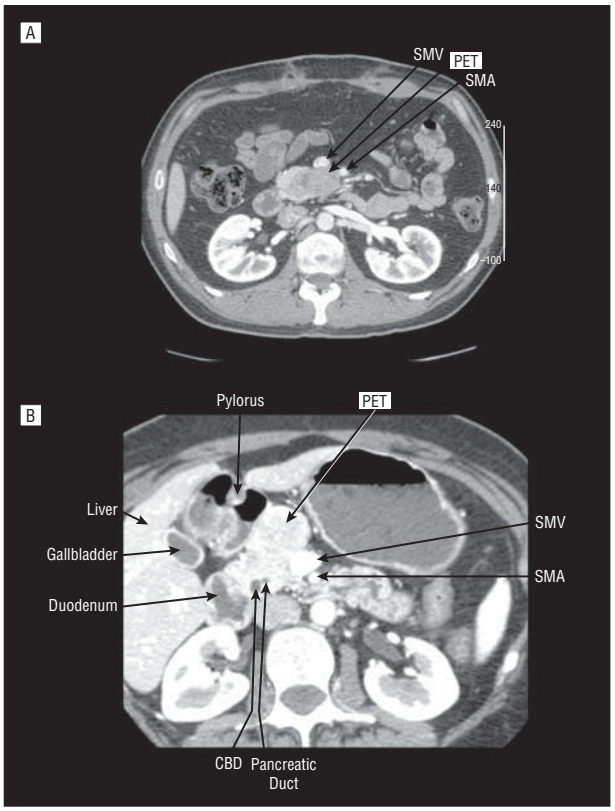

Figure 1. Computed tomography scans of 2 patients with pancreatic endocrine tumor (PET) in the head of the pancreas abutting the mesenteric vessels. A, The PET is in the uncinate portion of the pancreatic head and lies abutting the posterior surface of the superior mesenteric vein (SMV) and superior mesenteric artery (SMA); B, The PET is in the anterior portion of the head of the pancreas abutting the anterior and lateral wall of the SMV. These patients could have the PET dissected off the SMV. CBD indicates common bile duct.

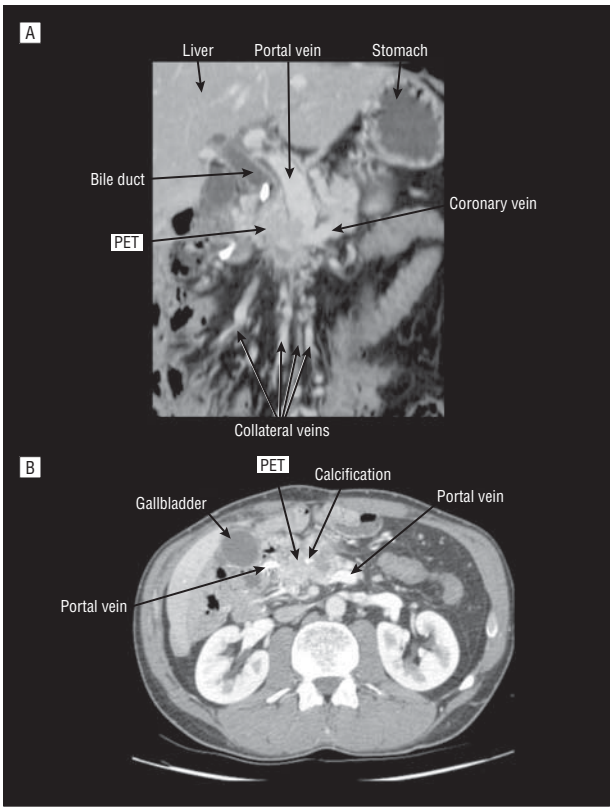

Figure 2. Coronal planar reformation (A) and axial tomogram (B) of a computed tomogram of the same patient with a locally invasive nonmetastatic pancreatic endocrine tumor (PET) obstructing the proximal portal vein. The PET has calcifications. There are extensive collateral veins because of the portal vein obstruction. This patient had the portal vein resected and reconstructed with autologous femoral vein.

be resectable for benefit.[11,14,17,22-24] Sarcomas involving blood vessels that were previously thought to be inoperable have been recently resected with acceptable morbidity and good survival.[25] Because PETs are rare, there have been no systematic studies of the ability to surgically resect malignant PETs thought to abut or involve major vascular structures, with most reports involving only a few PET patients.[9,10,26-33] In this study, we report our long-term results with PETs that abut or involve major vascular structures, including the PV, SMV, SMA, IVC, splenic vein with large collaterals, and the heart (interventricular septum). The findings suggest that possible/definite major vascular involvement on preoperative imaging studies should not be a contraindication to PET resection.

METHODS

Since 1982 at the National Institutes of Health and since 2004 at Stanford University hospitals, 195 patients with Zollinger-Ellison syndrome and 78 patients with either functional or nonfunctional pancreatic PETs were involved in a prospective plan to perform surgical exploration for cure as described elsewhere.[34-41] All patients at the National Institutes of Health, after confirmation of the diagnosis, underwent detailed imaging studies to determine operability.[34,36,42-46] Patients at Stanford University School of Medicine underwent CT. Patients were counseled to undergo surgery if they had no medical contraindication and appeared operable, and if multiple endocrine neoplasia type 1 was present and they had a tumor 2½ cm or greater in diameter.[35-37,40,47-49] Patients were included with limited liver metastases.[38,39,50] Forty-six patients (17%) were identified on CT or magnetic resonance imaging or both to have a PET that involved a major vascular structure. This included patients in whom the PET involved the heart[51] or the IVC either abutted (**Figure 1**) or encased the SMV or PV (**Figure 2** and **Figure 3**) or the SMA or invaded the splenic vein with large short gastric collateral vessels. Abutted means that the PET appeared to touch the vessel on CT and encased means that it surrounded the vessel. Criteria for diagnosis of Zollinger-Ellison syndrome and glucagonoma have been described elsewhere.[52-58] A detailed past history of disease was taken.[52,58] Time from onset of the disease to exploration was determined.[35,59,60] Multiple endocrine neoplasia type 1 was established by assessing plasma hormone levels and family history.[37,48,58,61]

Forty-four of 46 patients underwent surgical exploration. The operative techniques have been described elsewhere.[35,36,47,62,63] We did not use the cell saver, octreotide, or any other blood conservation measures. We did not perform frozen section on pancreatic or vascular margins. Tumors in the pancreatic head were enucleated, and body and tail were resected. If large pancreatic head tumors were present and could not be enucleated, a pancreaticoduodenectomy was performed.[64] A detailed inspection for lymph nodes was performed, and these were routinely removed.[34,65] If liver metastases were present and localized, they were wedge resected with a 1-cm margin, if possible; if this was not possible, a segmental resection or lobectomy was performed.[38,39,50] If the SMV was resected and reconstructed, it was

©2011 American Medical Association. All rights reserved.
Downloaded From: http://archsurg.jamanetwork.com/ on 07/29/2015

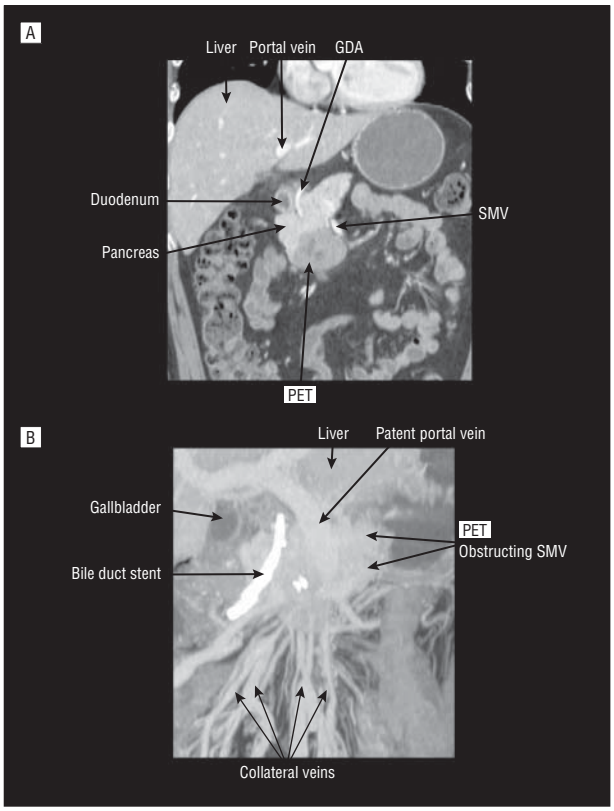

Figure 3. Coronal plane computed tomogram of 2 different pancreatic endocrine tumors (PETs). A, A large tumor is in the uncinate portion of the pancreatic head that is abutting the superior mesenteric vein (SMV). The PET is compressing the SMV and altering its course. The gastroduodenal artery (GDA) is also labeled. B, A locally advanced PET is in the pancreatic head that is obstructing both the SMV and common bile duct. The patient presented with jaundice and had a stent placed in the common bile duct. The PET is blocking the SMV, and one can see extensive collateral veins in the tributaries proximal to the SMV blockage that are returning blood from the gut to the liver.

performed with either the proximal femoral vein or the jugular vein.[25,39] The SMA was reconstructed with the saphenous vein.[25,39] After surgery, patients underwent evaluation for disease-free status (ie, 2 weeks after resection, within 3 to 6 months after resection, and then yearly).[35,43,59,62] Disease-free status was defined as no evidence of tumor on conventional imaging studies, usually CT. For patients with functional PETs (gastrinoma or glucagonoma), complete disease-free status was also assessed by plasma hormone levels.[35,36,59] A recurrence after resection was defined as loss of disease-free status on follow-up evaluation by developing positive imaging studies (nonfunctional PETs or functional PETs) and/or recurrent elevations of fasting hormone test results.[35,36,59,66] Recurrent disease was treated with chemotherapy or somatostatin analogues with or without alpha interferon, as described elsewhere.[67-69]

The Fisher exact test was used for 2-group comparisons. All continuous variables were reported as mean (SEM). The probabilities of survival were calculated and plotted according to the Kaplan-Meier method.[70]

RESULTS

DEMOGRAPHICS

Forty-six patients (17%) were identified on preoperative imaging studies as having pancreatic PETs either involving the IVC, heart, or PV or abutting or encasing the SMV (Figures 1-3), SMA, or splenic vein with extensive collateral veins (**Table 1** and **Table 2**). Thirty functional PET patients presented with symptoms related to Zollinger-Ellison syndrome (peptic ulcer disease, gastroesophageal reflux disease, and diarrhea), and 2 glucagonoma patients presented with a rash that was later called necrolytic migratory erythema. Although the nonfunctional PET patients each presented with pain, 6 functional PET patients also had pain as a presenting symptom (Table 1). For the patients with functional PETs, symptoms were present for approximately 5 years before the diagnosis was made. The median gastrin increase for the Zollinger-Ellison syndrome patients was 12-fold (Table 1).

Table 1. Preoperative Demographic and Clinical Characteristics of 46 Patients

Characteristic	Value
Male sex, No. (%)	21 (46)
White race, No. (%)	39 (85)
Age at diagnosis, mean (SEM) [range], y	41.7 (2.1) [24-76]
Type of PET, No. (%)	
Nonfunctional	14 (30)
Functional	32 (70)
Gastrinoma	30[a]
Glucagonoma	2
Presenting symptom, No. (%)	
Due to functional PET[b]	32 (70)
Due to pain	20 (43)
Presence of MEN-1, No. (%)	12 (26)
Duration of symptoms before diagnosis of functional PETs, mean (SEM) [range], y	5.0 (0.9) [0.25-17.9]
Hormone elevation[c]	
Median fold increase	12[d]
Mean (SEM)	292 (213)
Range	[3-5500]

Abbreviations: MEN-1, multiple endocrine neoplasia type 1; PET, pancreatic endocrine tumor.
[a] Six patients with gastrinomas with MEN-1 also had nonfunctional PETs identified preoperatively.
[b] All patients with functional PETs presented with symptoms due to hormone excess.
[c] Gastrin elevation in the 30 patients with gastrinomas preoperatively.
[d] Fold increase over 100 pg/mL (multiply 100 × 12 to obtain gastrin level).

PREOPERATIVE IMAGING

Table 2 presents preoperative tumoral features assessed by imaging studies. Three primary tumors were ectopic: 2 in the interventricular septum of the heart and the other within the wall of the right hepatic duct abutting the right PV (**Figure 4**).

SURGICAL FINDINGS AND RESULTS

Forty-four of the 46 patients (96%) underwent surgery (2 refused surgery), and in 42 patients the primary tumor was resected (**Table 3**). Fifteen patients had vascular encasement located in the heart (n = 1), the IVC (n = 1), the SMA (n = 1), and the PV or SMV (n = 12) (Figures 2 and 3B and Table 3).

Resections included partial pancreatectomy (either distal or subtotal pancreatectomy) in 23 patients, Whipple

©2011 American Medical Association. All rights reserved.
Downloaded From: http://archsurg.jamanetwork.com/ on 07/29/2015

Table 2. Preoperative Tumoral Features of 46 Patients Assessed by Imaging Studies[a]

Feature	Value
Primary tumor	
Largest size, mean (SEM) [range], cm	5.8 (0.5) [2-13]
No. of primary tumors, mean (SEM) [range][b]	1.5 (0.2) [1-5]
Preoperative primary location	
Pancreatic head/duodenum[c]	27 (59)
Pancreatic body	9 (20)
Pancreatic tail	8 (17)
Other	2 (4)
Presence of metastases	35 (76)
Lymph node	27 (59)
Liver (limited)[d]	14 (30)
Vessels involved/abutted	46 (100)
Portal vein or tributary	20 (43)
SMV/SMA	16 (35)
Inferior vena cava	4 (9)
Splenic vein	4 (9)
Heart	2 (4)

Abbreviation: SMV/SMA, superior mesenteric vein/artery.
[a] Data are given as number (percentage) of patients unless otherwise indicated.
[b] Six patients with multiple endocrine neoplasia type 1 had multiple primary gastrinoma and other pancreatic endocrine tumors identified preoperatively.
[c] Imaging studies could not clearly differentiate locations in the pancreatic head or duodenum.
[d] Limited liver metastases refer to patients without diffuse liver metastases and with liver metastatic disease thought to be completely resectable.

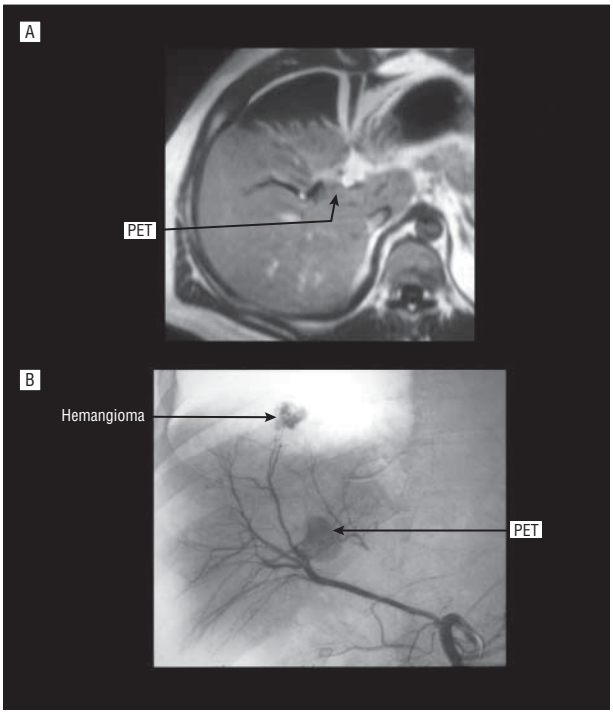

Figure 4. Gadolinium-enhanced magnetic resonance imaging (A) and selective arteriogram (B) of a pancreatic endocrine tumor (PET) that was in the wall of the right hepatic duct. The tumor was abutting the right portal vein. There is a second liver tumor shown on the hepatic arteriogram (B) as a liver hemangioma. The PET was locally resected with the right hepatic duct. The tumor was dissected off the portal vein.

proximal pancreaticoduodenectomy in 10, and total pancreatectomy in 2 (**Table 4**). Eighteen patients (41%) had concomitant liver resection: 10 (23%) had wedge resections and 8 (18%) had anatomic resections (Table 4). Nine patients (20%) had vascular reconstruction: each had reconstruction of the SMV and PV, whereas 1 patient had concomitant reconstruction of the SMA. The median (range) operative blood loss was 500 mL (200 mL-6.2 L). The median (range) hospital stay was 9 (7-33) days.

FOLLOW-UP AND OUTCOME

Table 4 presents the type and results of surgery, follow-up, and complications. The 10-year actuarial overall survival is 60%, and the disease-free survival is 30% (**Figure 5**). Possible prognostic factors were examined to determine whether they affected overall and disease-free survival. Most variables did not affect disease-free survival (**Table 5**). Patients with functional tumors had a greater long-term overall survival than those with nonfunctional tumors, but the disease-free survival was similar ($P<.001$) (**Figure 6**). The presence of lymph node metastases did not decrease disease-free survival. However, disease-free survival was decreased from 66% to 10% by the presence of liver metastases ($P=.002$) as well as by the use of liver resection ($P=.007$). The use of vascular reconstruction did not affect disease-free survival (Table 5). The use of other anti-tumor treatment following surgery significantly decreased disease-free survival (Table 5).

Table 3. Surgical Findings in 44 Patients[a]

Characteristic	Value
Tumor resected, No. (%)[b]	42 (95)
Age at surgery, mean (SEM) [range], y	49 (2) [27.5-81.0]
Interval from diagnosis to surgery, mean (SEM) [range], y	5.3 (1.1) [0.1-18.8]
Primary PET, No. (%)	
Location	
Pancreas	30 (68)
Duodenum	12 (27)
Other[c]	5 (11)
Largest size, mean (SEM) [range], cm	5 (0.6) [0.4-15.0]
Metastases found at surgery, No. (%)	
Lymph node involvement	30 (68)
Liver metastases[d]	18 (41)
Tumor extent at surgery, No. (%)	
Primary only	12 (27)
Primary plus lymph node involvement	30 (68)
With liver involvement[d]	18 (41)
Invasion/encasement of major vessel, No. (%)[e]	15 (34)

Abbreviation: PET, pancreatic endocrine tumor.
[a] Of 46 patients enrolled in the study, 2 refused surgery.
[b] Two patients with gastrinomas had unresectable disease: 1 with diffuse peritoneal implants/diffuse small liver metastases and 1 with complete encasement of the inferior vena cava/portal vein with arterial invasion with bleeding.
[c] Other refers to 1 patient with a primary gastrinoma in the bile duct (n=1), liver (n=2), heart (n=1), and lymph node (n=1).
[d] Two patients had primary gastrinoma of the liver.
[e] One patient had invasion of the heart by a gastrinoma, 12 had encasement of the superior mesenteric vein or portal vein, 1 had encasement of the superior mesenteric artery, and 1 had involvement of the inferior vena cava.

©2011 American Medical Association. All rights reserved.
Downloaded From: http://archsurg.jamanetwork.com/ on 07/29/2015

Table 4. Types of Surgery, Complications, and Follow-Up[a]

Variable	Value
Tumor resection	42 (95)[a]
Primary only	12 (27)
With lymph node metastases	30 (68)
With liver metastases	18 (41)
Type of primary surgery	
Enucleation	7 (16)
Resection	35 (80)
Partial pancreatectomy	23 (52)
Whipple resection	10 (23)
Total pancreatectomy	2 (5)
Liver resection	18 (41)
Wedge resection	10 (23)
Lobectomy[b]	8 (18)
Vascular reconstruction	9 (20)
SMV-portal vein	9 (20)
SMA	1 (2)
Surgical complications	
Surgical death	0
Complications[c]	12 (27)
Surgical result[d]	
Immediately tumor free	18 (41)
Recurrence	5 (11)
Time to recurrence, mean (SEM) [range], y	1.7 (0.6) [0.5-3]
Long-term disease free	13 (30)
Status at most recent follow-up	
Alive	34 (77)
Dead	10 (23)
Time from surgery to death, mean (SEM) [range], y	5.5 (0.3) [3-8]
Duration of follow-up, y	
After surgery, mean (SEM) [range]	5.7 (1.0) [1.3-21.2]
After diagnosis, mean (SEM) [range]	12.7 (1.2) [3.9-25.8]
Other antitumor treatment	18 (41)
Chemotherapy	12 (27)
Other[e]	10 (23)

Abbreviations: SMA, superior mesenteric artery; SMV, superior mesenteric vein.

[a] Data are given as number (percentage) of 44 patients who underwent surgical exploration unless otherwise indicated. Two patients had unresectable disease. See footnote b in Table 3.

[b] Includes trisegmentectomy (n=1), hepatic lobe resection (n=4), and segmentectomy (n=3).

[c] Include postoperative pancreatitis (n=1), abscess (n=4), wound infection (n=3), bile duct injury (n=1), leak at pancreaticojejunostomy (n=2), and ischemic bowel (n=1).

[d] Disease-free status and recurrence based on serial imaging studies as described in the "Methods" section.

[e] Patients treated with interferon alfa (n=2), somatostatin analogues (n=9), or peptide-receptor radionuclide therapy (n=1). Two patients who received interferon alfa also received somatostatin analogues.

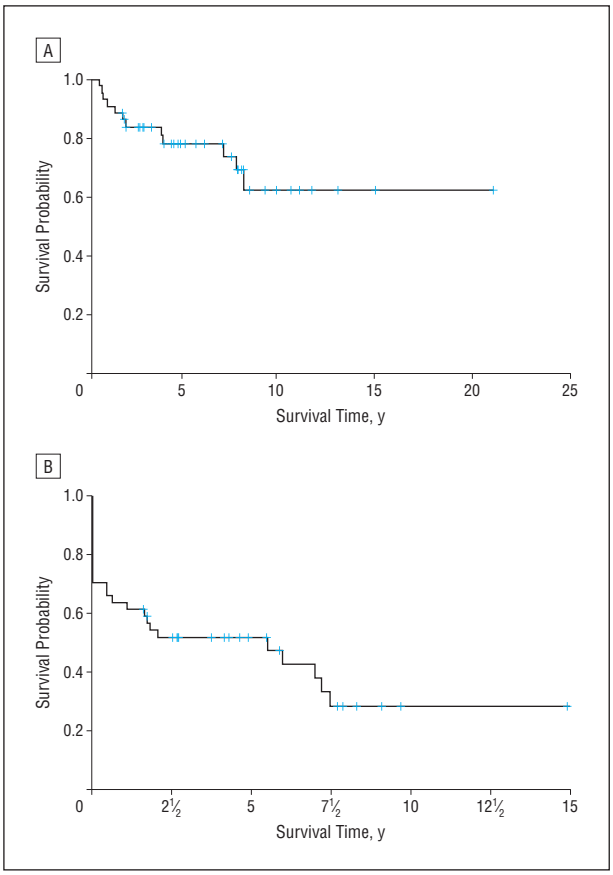

Figure 5. Kaplan-Meier plot of total survival (A) and disease-free survival (B) of the 44 patients with pancreatic endocrine tumors involving major vascular structures who had the tumor removed surgically. The actuarial 10-year overall survival was 60%, and the 10-year disease-free survival was 30%.

COMMENT

This article focuses on the role of surgery in removing PETs abutting, invading, or encasing a major blood vessel, usually the SMV or PV (Figures 1-3), as well as removing the primary tumor, lymph nodes, and any limited liver metastases in these patients. This study was undertaken for a number of reasons. First, a proportion of PETs show aggressive, malignant growth, which is associated with decreased survival, and the medical treatment of these large, advanced tumors is generally only marginally effective.[67,71-73] Second, a number of studies have shown that vascular invasion in patients with pancreatic adenocarcinomas and those with advanced PETs is associated with decreased survival.[2,4,11-15] Third, there are a number of surgical reports by different groups that resection of distant metastatic PETs, including those within the liver, may improve survival.[38,50,74-77] A recent consensus statement recommended that patients with limited liver metastases be considered for resection.[3,38,50,71,74,75,78] Fourth, recent studies in patients with exocrine adenocarcinoma of the pancreas—similar to PETs—suggest that these tumors, even when invading venous structures, may be resected with acceptable morbidity and benefit.[11,14,17-19] Similarly, resection of invasive sarcomas of the extremity and retroperitoneum that involve major blood vessels, resulting in the complete removal of tumors previously thought to be inoperable, has been recently reported with favorable outcomes.[27] Furthermore, numerous series suggested a similar approach might be feasible and perhaps beneficial in patients with advanced functional[9,28,79-81] and nonfunctional PETs.[9,29,30,33,82-84] Fifth, an aggressive PET can also cause dramatic life-threatening complications, such as massive bleeding, because of the formation of vascular shunts[27] or short gastric varices in the setting of splenic vein occlusion by tumor.[80,83-86] Successful resection of these primary PETs, even in cases of early vascular involvement, may significantly delay or prevent the occurrence of such complications.

©2011 American Medical Association. All rights reserved.
Downloaded From: http://archsurg.jamanetwork.com/ on 07/29/2015

Table 5. Univariant Analysis of Possible Prognostic Factors for Disease-Free Survival After Resection

Variable	Disease Free at Most Recent Follow-up, No. (% of Category)		P Value[a]
	Yes (n=20)	No (n=24)	
General features			
Male sex	10 (50)	10 (42)	NS
White race	19 (95)	19 (79)	NS
Presence of NF-PET	9 (45)	7 (29)	NS
Presence of MEN-1	5 (25)	7 (29)	NS
Hormone elevation >11.6-fold	8 (40)	8 (33)	NS
Preoperative imaging			
Primary tumor size >3.7 cm	11 (55)	17 (71)	NS
Location in pancreatic head/duodenum	13 (65)	17 (71)	NS
Possible portal vein involvement	14 (70)	20 (83)	NS
Possible presence of liver metastases	6 (30)	12 (50)	NS
Surgical findings			
Age at surgery >47 y	14 (70)	11 (46)	NS
Primary tumor in pancreas	14 (70)	16 (67)	NS
Primary tumor size >3 cm	11 (55)	15 (62)	NS
Presence of lymph node metastases	14 (70)	19 (79)	NS
Finding of liver metastases	2 (10)	16 (67)	<.001
Invasion/encasement of vessel	7 (35)	8 (33)	NS
Surgical treatment/result			
Liver resection	2 (10)	16 (67)	.01
Vascular reconstruction	5 (25)	4 (17)	NS
Immediately tumor free	20 (100)	11 (46)	.01
Surgical follow-up			
Alive at most recent follow-up	20 (100)	14 (58)	<.001
Most recent follow-up >7.5 y after surgery	6 (30)	11 (46)	NS
Other postoperative antitumor treatment	0	16 (67)	<.001

Abbreviations: MEN-1, multiple endocrine neoplasia type 1; NF-PET, nonfunctional pancreatic endocrine tumor; NS, not significant.
[a] Proportions compared by Fisher exact test.

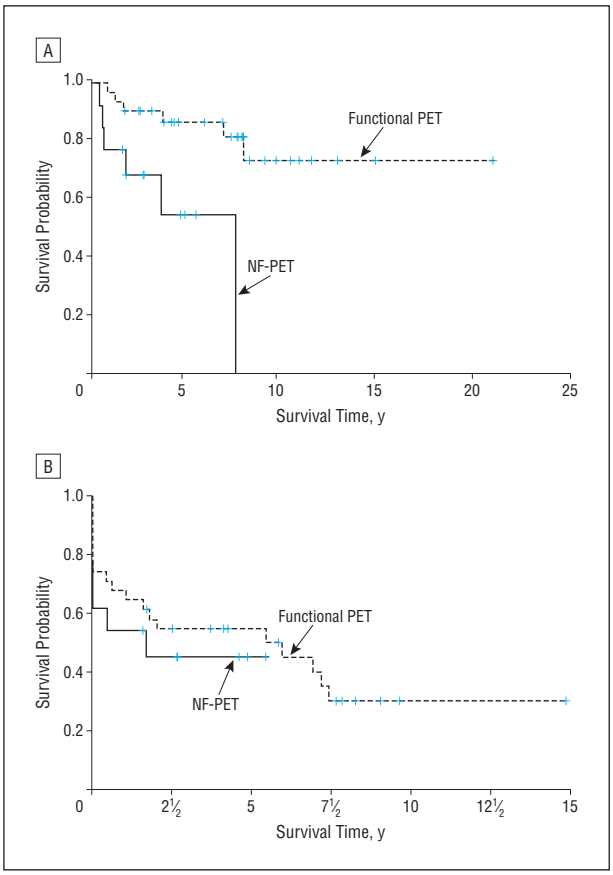

Figure 6. Kaplan-Meier plot of total survival (A) and disease-free survival (B) based on the clinical production of a hormone (gastrin and glucagon); that is, defined as functional pancreatic endocrine tumor (PET) vs nonfunctional PET (NF-PET). Functional PET had a significantly better overall survival than NF-PET (A; $P<.001$), but there was no difference in disease-free survival (B).

In our study, we found that resections were feasible, safe, and associated with long-term survival, even though the tumors were usually large (mean size, 5.0 cm) with metastatic disease. One important observation in this study is that tumor invaded and/or encased a major vascular structure in less than half the patients (34%), and in the remaining patients, the PET had only partial vascular involvement or vascular abutment without encasement and/or invasion of a major vascular structure. This result is similar to that in a study[9] of patients with advanced large PETs: 50% of the patients thought to have vascular involvement from preoperative studies were found at surgery not to have vascular encasement and/or invasion of major vessels. Computed tomography and magnetic resonance imaging are reported to have excellent sensitivity for detecting vascular involvement and are the standard imaging modalities used to determine vascular involvement in patients with either pancreatic exocrine adenocarcinomas or PETs.[3,9-11,14] In the present study, both modalities were used in the gastrinoma patients and CT in the nonfunctional PET patients. Our current preference is CT over magnetic resonance imaging because with thin slicing, timed intravenous contrast, and reconstruction, the images with CT allow the surgeon to see the disease and to plan the surgery effectively. With pancreatic adenocarcinomas, preoperative CT is reported to have excellent sensitivity for identifying involvement of major vessels; however, similar to our results in PETs, it can also have false-positive results in pancreatic adenocarcinoma, with specificity as low as 50% in some studies.[11,14] Our results demonstrate that with PETs, radiologic abutment or even possible vascular involvement is frequently not synonymous with vascular involvement at surgery. The PET was found frequently to be encroaching, abutting, or distorting the major vascular structure, without encasing it and/or invading it. In other studies, in a small number of patients with PETs, there have been reports that CT may falsely suggest vessel involvement.[9,87] The quality and technique of imaging with CT has improved during the 22 years of this study, allowing clearer imaging of vessels with fewer false-positive results. Endoscopic ultrasound is another potentially useful study for assessing major vascular involvement; however, it was not used in this study, so we are unable to comment on its utility. In our study, only 9 of the 44 patients (20%) undergoing PET resections required vascular reconstruction, demonstrating that in most patients, the PET can be removed with careful dis-

©2011 American Medical Association. All rights reserved.
Downloaded From: http://archsurg.jamanetwork.com/ on 07/29/2015

section without requiring vascular reconstruction. These results differ from those of pancreatic adenocarcinoma, in which venous resection is usually required with tumor involvement and in which the percentage of the patients with potentially resectable disease having major vascular involvement is much lower.[14,17,23,24]

In our study, despite the extensive tumor involvement, patients who underwent resection of PETs had impressive actuarial overall and disease-free survival rates at 5 years, 60% and 30%, respectively. An important prognostic factor associated with a decreased disease-free survival was the presence of liver metastases, which has been described elsewhere.[4-7,71,88] In contrast, disease-free survival was not affected by either the extent or type of vascular involvement or by the presence of other factors that have prognostic significance for disease-free or total survival in other studies of PET patients.[2,4,6,7,71,88] In our study, patients with nonfunctional PETs with possible vascular involvement had a significantly decreased ($P < .001$) survival compared with the survival of similar patients with functional PETs. In previous reports, patients with nonfunctional PETs have poorer survival than patients with functional PETs.[1,4,5,7,89] The decreased survival of patients with nonfunctional PETs is reported to be likely due to their more aggressive behavior or more advanced disease.[1,7] In our study, the extent of disease in the patients with functional and nonfunctional tumors was comparable, which supports the proposal that these patients have more aggressive tumors.[1,7]

Unfortunately, our study, like many other surgical series of patients with advanced PETs, including those with liver metastases, does not clearly establish the value of the surgical approach taken.[76-78,90] Nevertheless, a number of findings in our study are suggestive of surgical benefit. First, despite the decreased survival of patients with vascular involvement and/or liver metastases with malignant PETs,[2,4,12,13,71,72] the overall survival rate was 60% at 5 years and 30% of patients remained disease free. These data are encouraging because, in historic controls, patients with metastatic PETs with vascular involvement who did not undergo surgery had a 5-year survival rate of 30% to 40%.[89,91] Second, in our study, these results were obtained in the setting of major pancreatic resection (79%), plus liver resection in 41%, vascular dissection in all, and reconstruction in 20%. Despite this extent of surgical dissection, there was no surgical mortality, and the surgical complication rate (27%) was well within the range of that reported in previous studies with PET resections by means of lesser procedures.[1,92,93] Third, in the present study, 5 patients presented with upper gastrointestinal hemorrhage from gastric varices secondary to splenic vein occlusion by the PET, and the bleeding was totally ameliorated by removal of the tumor with the spleen. This experience is similar to that reported in a small number of case reports.[8,83,85-87,94-96] These results suggest that the resection of the PET despite vascular involvement is of particular benefit in this group of PET patients. Fourth, medical therapies of advanced PETs have provided only modest benefits, with many studies reporting short-term disease stabilization and a small percentage of partial responses.[71-73,97] Therefore, it has generally not been possible to downsize extensive disease in a patient with a malignant PET to make it surgically resectable, as has been performed in some other tumors.[71-73,98,99] Our data suggest that major vascular involvement is not a contraindication to surgery. Because radiographic evidence of vascular involvement represented 20% of our PET population, these findings apply to a significant number of PET patients seen in the community, and such patients should be referred to a tertiary care facility where multidisciplinary expertise is available.

Accepted for Publication: May 20, 2010.
Correspondence: Jeffrey A. Norton, MD, Department of Surgery, Stanford University Medical Center, 300 Pasteur Dr, Room H-3591, Stanford, CA 94305-5641 (janorton@stanford.edu).
Author Contributions: *Study concept and design:* Norton, Harris, Chen, and Jensen. *Acquisition of data:* Norton, Harris, Chen, Visser, and Jensen. *Analysis and interpretation of data:* Norton, Chen, Poultsides, Kunz, Fisher, and Jensen. *Drafting of the manuscript:* Norton and Jensen. *Critical revision of the manuscript for important intellectual content:* Norton, Harris, Chen, Visser, Poultsides, Kunz, Fisher, and Jensen. *Statistical analysis:* Norton, Chen, Fisher, and Jensen. *Obtained funding:* Norton and Jensen. *Administrative, technical, and material support:* Norton, Harris, Chen, and Visser. *Study supervision:* Norton and Kunz.
Financial Disclosure: None reported.
Funding/Support: This study was partially supported by intramural funds of the National Institute of Diabetes and Digestive and Kidney Diseases, National Institutes of Health.

REFERENCES

1. Phan GQ, Yeo CJ, Hruban RH, Lillemoe KD, Pitt HA, Cameron JL. Surgical experience with pancreatic and peripancreatic neuroendocrine tumors: review of 125 patients. *J Gastrointest Surg*. 1998;2(5):472-482.
2. Hochwald SN, Zee S, Conlon KC, et al. Prognostic factors in pancreatic endocrine neoplasms: an analysis of 136 cases with a proposal for low-grade and intermediate-grade groups. *J Clin Oncol*. 2002;20(11):2633-2642.
3. Norton JA, Jensen RT. Resolved and unresolved controversies in the surgical management of patients with Zollinger-Ellison syndrome. *Ann Surg*. 2004;240(5):757-773.
4. Jensen RT. Natural history of digestive endocrine tumors. In: Mignon M, Colombel JF, eds. *Recent Advances in Pathophysiology and Management of Inflammatory Bowel Diseases and Digestive Endocrine Tumors*. Paris, France: John Libbey Eurotext Publishing Co; 1999:192-219.
5. Madeira I, Terris B, Voss M, et al. Prognostic factors in patients with endocrine tumours of the duodenopancreatic area. *Gut*. 1998;43(3):422-427.
6. Panzuto F, Nasoni S, Falconi M, et al. Prognostic factors and survival in endocrine tumor patients: comparison between gastrointestinal and pancreatic localization. *Endocr Relat Cancer*. 2005;12(4):1083-1092.
7. Ekeblad S, Skogseid B, Dunder K, Oberg K, Eriksson B. Prognostic factors and survival in 324 patients with pancreatic endocrine tumor treated at a single institution. *Clin Cancer Res*. 2008;14(23):7798-7803.
8. Bok EJ, Cho KJ, Williams DM, Brady TM, Weiss CA, Forrest ME. Venous involvement in islet cell tumors of the pancreas. *AJR Am J Roentgenol*. 1984;142(2):319-322.
9. Hellman P, Andersson M, Rastad J, et al. Surgical strategy for large or malignant endocrine pancreatic tumors. *World J Surg*. 2000;24(11):1353-1360.
10. Stafford Johnson DB, Francis IR, Eckhauser FE, Knol JA, Chang AE. Dual-phase helical CT of nonfunctioning islet cell tumors. *J Comput Assist Tomogr*. 1998;22(1):59-63.
11. Wray CJ, Ahmad SA, Matthews JB, Lowy AM. Surgery for pancreatic cancer: recent controversies and current practice. *Gastroenterology*. 2005;128(6):1626-1641.
12. La Rosa S, Rigoli E, Uccella S, Novario R, Capella C. Prognostic and biological significance of cytokeratin 19 in pancreatic endocrine tumours. *Histopathology*. 2007;50(5):597-606.

©2011 American Medical Association. All rights reserved.
Downloaded From: http://archsurg.jamanetwork.com/ on 07/29/2015

13. Deshpande V, Fernandez-del Castillo C, Muzikansky A, et al. Cytokeratin 19 is a powerful predictor of survival in pancreatic endocrine tumors. *Am J Surg Pathol*. 2004;28(9):1145-1153.
14. Buchs NC, Chilcott M, Poletti PA, Buhler LH, Morel P. Vascular invasion in pancreatic cancer: imaging modalities, preoperative diagnosis and surgical management. *World J Gastroenterol*. 2010;16(7):818-831.
15. Ballian N, Loeffler AG, Rajamanickam V, Norstedt PA, Weber SM, Cho CS. A simplified prognostic system for resected pancreatic neuroendocrine neoplasms. *HPB (Oxford)*. 2009;11(5):422-428.
16. Evans DB, Skibber JM, Lee JE, et al. Nonfunctioning islet cell carcinoma of the pancreas. *Surgery*. 1993;114(6):1175-1182..
17. Martin RC II, Scoggins CR, Egnatashvili V, Staley CA, McMasters KM, Kooby DA. Arterial and venous resection for pancreatic adenocarcinoma: operative and long-term outcomes. *Arch Surg*. 2009;144(2):154-159.
18. Glanemann M, Shi B, Liang F, et al. Surgical strategies for treatment of malignant pancreatic tumors: extended, standard or local surgery? *World J Surg Oncol*. 2008;6:123. doi:10.1186/1477-7819-6-123.
19. Siriwardana HP, Siriwardena AK. Systematic review of outcome of synchronous portal-superior mesenteric vein resection during pancreatectomy for cancer. *Br J Surg*. 2006;93(6):662-673.
20. Zhao WY, Luo M, Sun YW, et al. Computed tomography in diagnosing vascular invasion in pancreatic and periampullary cancers: a systematic review and meta-analysis. *Hepatobiliary Pancreat Dis Int*. 2009;8(5):457-464.
21. Noone TC, Hosey J, Firat Z, Semelka RC. Imaging and localization of islet-cell tumours of the pancreas on CT and MRI. *Best Pract Res Clin Endocrinol Metab*. 2005;19(2):195-211.
22. Harrison LE, Klimstra DS, Brennan MF. Isolated portal vein involvement in pancreatic adenocarcinoma: a contraindication for resection? *Ann Surg*. 1996; 224(3):342-349.
23. Tseng JF, Tamm EP, Lee JE, Pisters PW, Evans DB. Venous resection in pancreatic cancer surgery. *Best Pract Res Clin Gastroenterol*. 2006;20(2):349-364.
24. Ramacciato G, Mercantini P, Petrucciani N, et al. Does portal-superior mesenteric vein invasion still indicate irresectability for pancreatic carcinoma? *Ann Surg Oncol*. 2009;16(4):817-825.
25. Song TK, Harris EJ Jr, Raghavan S, Norton JA. Major blood vessel reconstruction during sarcoma surgery. *Arch Surg*. 2009;144(9):817-822.
26. Obuz F, Bora S, Sarioğlu S. Malignant islet cell tumor of the pancreas associated with portal venous thrombus. *Eur Radiol*. 2001;11(9):1642-1644.
27. Handa M, Nakada T, Kajitsuka S, Hirose M, Sato Y. Portosystemic A-V fistula and portal hypertension associated with islet-cell tumor of the pancreas [in Japanese]. *Nippon Geka Gakkai Zasshi*. 1985;86(8):953-958.
28. Rusher AH, Henson K. Metastatic malignant insulinoma: debulking for palliation of symptoms. *J Ark Med Soc*. 1991;88(6):267-269.
29. Sakamoto E, Hasegawa H, Ogiso S, et al. Curative resection for a pancreatic endocrine carcinoma involving the portal vein. *Hepatogastroenterology*. 2004; 51(60):1849-1851.
30. Kawakami H, Kuwatani M, Hirano S, et al. Pancreatic endocrine tumors with intraductal growth into the main pancreatic duct and tumor thrombus within the portal vein: a case report and review of the literature. *Intern Med*. 2007;46(6): 273-277.
31. Akatsu T, Aiura K, Shimazu M, et al. Successful pancreatectomy with en-bloc resection of the celiac artery and portal vein for pancreatic endocrine carcinoma. *Hepatogastroenterology*. 2007;54(76):1269-1271.
32. Yamato H, Kawakami H, Kuwatani M, et al. Pancreatic carcinoma associated with portal vein tumor thrombus: three case reports. *Intern Med*. 2009;48(3):143-150.
33. Bedirli A, Patiroglu TE, Sakrak O, Aritas Y. Portal vein resection for a portal vein thrombus caused by nonfunctioning islet cell carcinoma: report of a case. *Surg Today*. 2004;34(9):802-804.
34. Norton JA, Alexander HR, Fraker DL, Venzon DJ, Gibril F, Jensen RT. Possible primary lymph node gastrinoma: occurrence, natural history, and predictive factors: a prospective study. *Ann Surg*. 2003;237(5):650-659.
35. Norton JA, Fraker DL, Alexander HR, et al. Surgery to cure the Zollinger-Ellison syndrome. *N Engl J Med*. 1999;341(9):635-644.
36. Norton JA, Alexander HR, Fraker DL, Venzon DJ, Gibril F, Jensen RT. Does the use of routine duodenotomy (DUODX) affect rate of cure, development of liver metastases, or survival in patients with Zollinger-Ellison syndrome? *Ann Surg*. 2004;239(5):617-625.
37. Norton JA, Alexander HR, Fraker DL, Venzon DJ, Gibril F, Jensen RT. Comparison of surgical results in patients with advanced and limited disease with multiple endocrine neoplasia type 1 and Zollinger-Ellison syndrome. *Ann Surg*. 2001; 234(4):495-506.
38. Norton JA, Doherty GM, Fraker DL, et al. Surgical treatment of localized gastrinoma within the liver: a prospective study. *Surgery*. 1998;124(6):1145-1152.
39. Norton JA, Kivlen M, Li M, Schneider D, Chuter T, Jensen RT. Morbidity and mortality of aggressive resection in patients with advanced neuroendocrine tumors. *Arch Surg*. 2003;138(8):859-866.
40. Fraker DL, Norton JA, Alexander HR, Venzon DJ, Jensen RT. Surgery in Zollinger-Ellison syndrome alters the natural history of gastrinoma. *Ann Surg*. 1994; 220(3):320-330.
41. Norton JA. Surgical treatment and prognosis of gastrinoma. *Best Pract Res Clin Gastroenterol*. 2005;19(5):799-805.
42. Termanini B, Gibril F, Reynolds JC, et al. Value of somatostatin receptor scintigraphy: a prospective study in gastrinoma of its effect on clinical management. *Gastroenterology*. 1997;112(2):335-347.
43. Alexander HR, Fraker DL, Norton JA, et al. Prospective study of somatostatin receptor scintigraphy and its effect on operative outcome in patients with Zollinger-Ellison syndrome. *Ann Surg*. 1998;228(2):228-238.
44. Gibril F, Reynolds JC, Chen CC, et al. Specificity of somatostatin receptor scintigraphy: a prospective study and effects of false-positive localizations on management in patients with gastrinomas. *J Nucl Med*. 1999;40(4):539-553.
45. Krudy AG, Doppman JL, Jensen RT, et al. Localization of islet cell tumors by dynamic CT: comparison with plain CT, arteriography, sonography, and venous sampling. *AJR Am J Roentgenol*. 1984;143(3):585-589.
46. Termanini B, Gibril F, Doppman JL, et al. Distinguishing small hepatic hemangiomas from vascular liver metastases in gastrinoma: use of a somatostatin-receptor scintigraphic agent. *Radiology*. 1997;202(1):151-158.
47. Sugg SL, Norton JA, Fraker DL, et al. A prospective study of intraoperative methods to diagnose and resect duodenal gastrinomas. *Ann Surg*. 1993;218(2): 138-144.
48. MacFarlane MP, Fraker DL, Alexander HR, Norton JA, Lubensky I, Jensen RT. Prospective study of surgical resection of duodenal and pancreatic gastrinomas in multiple endocrine neoplasia type 1. *Surgery*. 1995;118(6):973-980.
49. Norton JA, Fraker DL, Alexander HR, et al. Surgery increases survival in patients with gastrinoma. *Ann Surg*. 2006;244(3):410-419.
50. Norton JA, Warren RS, Kelly MG, Zuraek MB, Jensen RT. Aggressive surgery for metastatic liver neuroendocrine tumors. *Surgery*. 2003;134(6):1057-1065.
51. Noda S, Norton JA, Jensen RT, Gay WA Jr. Surgical resection of intracardiac gastrinoma. *Ann Thorac Surg*. 1999;67(2):532-533.
52. Roy PK, Venzon DJ, Shojamanesh H, et al. Zollinger-Ellison syndrome: clinical presentation in 261 patients. *Medicine (Baltimore)*. 2000;79(6):379-411.
53. Roy PK, Venzon DJ, Feigenbaum KM, et al. Gastric secretion in Zollinger-Ellison syndrome: correlation with clinical expression, tumor extent and role in diagnosis—a prospective NIH study of 235 patients and review of the literature in 984 cases. *Medicine (Baltimore)*. 2001;80(3):189-222.
54. Raufman JP, Collins SM, Pandol SJ, et al. Reliability of symptoms in assessing control of gastric acid secretion in patients with Zollinger-Ellison syndrome. *Gastroenterology*. 1983;84(1):108-113.
55. Jensen RT, Niederle B, Mitry E, et al; Frascati Consensus Conference; European Neuroendocrine Tumor Society. Gastrinoma (duodenal and pancreatic). *Neuroendocrinology*. 2006;84(3):173-182.
56. Termanini B, Gibril F, Sutliff VE III, Yu F, Venzon DJ, Jensen RT. Effect of long-term gastric acid suppressive therapy on serum vitamin B_{12} levels in patients with Zollinger-Ellison syndrome. *Am J Med*. 1998;104(5):422-430.
57. Norton JA, Kahn CR, Schiebinger R, Gorschboth C, Brennan MF. Amino acid deficiency and the skin rash associated with glucagonoma. *Ann Intern Med*. 1979; 91(2):213-215.
58. Gibril F, Schumann M, Pace A, Jensen RT. Multiple endocrine neoplasia type 1 and Zollinger-Ellison syndrome: a prospective study of 107 cases and comparison with 1009 cases from the literature. *Medicine (Baltimore)*. 2004;83(1):43-83.
59. Fishbeyn VA, Norton JA, Benya RV, et al. Assessment and prediction of long-term cure in patients with the Zollinger-Ellison syndrome: the best approach. *Ann Intern Med*. 1993;119(3):199-206.
60. Weber HC, Venzon DJ, Lin JT, et al. Determinants of metastatic rate and survival in patients with Zollinger-Ellison syndrome: a prospective long-term study. *Gastroenterology*. 1995;108(6):1637-1649.
61. Benya RV, Metz DC, Venzon DJ, et al. Zollinger-Ellison syndrome can be the initial endocrine manifestation in patients with multiple endocrine neoplasia-type I. *Am J Med*. 1994;97(5):436-444.
62. Norton JA, Doppman JL, Jensen RT. Curative resection in Zollinger-Ellison syndrome: results of a 10-year prospective study. *Ann Surg*. 1992;215(1):8-18.
63. Norton JA. Intraoperative methods to stage and localize pancreatic and duodenal tumors. *Ann Oncol*. 1999;10(suppl 4):182-184.
64. Norton JA. Endocrine tumours of the gastrointestinal tract: surgical treatment of neuroendocrine metastases. *Best Pract Res Clin Gastroenterol*. 2005;19 (4):577-583.
65. Arnold WS, Fraker DL, Alexander HR, Weber HC, Norton JA, Jensen RT. Apparent lymph node primary gastrinoma. *Surgery*. 1994;116(6):1123-1129.
66. Jaskowiak NT, Fraker DL, Alexander HR, Norton JA, Doppman JL, Jensen RT.

©2011 American Medical Association. All rights reserved.
Downloaded From: http://archsurg.jamanetwork.com/ on 07/29/2015

Is reoperation for gastrinoma excision indicated in Zollinger-Ellison syndrome? *Surgery*. 1996;120(6):1055-1062.
67. von Schrenck T, Howard JM, Doppman JL, et al. Prospective study of chemotherapy in patients with metastatic gastrinoma. *Gastroenterology*. 1988;94 (6):1326-1334.
68. Shojamanesh H, Gibril F, Louie A, et al. Prospective study of the antitumor efficacy of long-term octreotide treatment in patients with progressive metastatic gastrinoma. *Cancer*. 2002;94(2):331-343.
69. Pisegna JR, Slimak GG, Doppman JL, et al. An evaluation of human recombinant alpha interferon in patients with metastatic gastrinoma. *Gastroenterology*. 1993;105(4):1179-1183.
70. Kaplan EL, Meier P. Nonparametric estimation from incomplete observations. *J Am Stat Assoc*. 1958;53:457-481.
71. Metz DC, Jensen RT. Gastrointestinal neuroendocrine tumors: pancreatic endocrine tumors. *Gastroenterology*. 2008;135(5):1469-1492.
72. Yu F, Venzon DJ, Serrano J, et al. Prospective study of the clinical course, prognostic factors, causes of death, and survival in patients with long-standing Zollinger-Ellison syndrome. *J Clin Oncol*. 1999;17(2):615-630.
73. Strosberg JR, Kvols LK. A review of the current clinical trials for gastroenteropancreatic neuroendocrine tumours. *Expert Opin Investig Drugs*. 2007;16(2): 219-224.
74. Eriksson J, Stålberg P, Nilsson A, et al. Surgery and radiofrequency ablation for treatment of liver metastases from midgut and foregut carcinoids and endocrine pancreatic tumors. *World J Surg*. 2008;32(5):930-938.
75. Sarmiento JM, Que FG. Hepatic surgery for metastases from neuroendocrine tumors. *Surg Oncol Clin N Am*. 2003;12(1):231-242.
76. Sarmiento JM, Heywood G, Rubin J, Ilstrup DM, Nagorney DM, Que FG. Surgical treatment of neuroendocrine metastases to the liver: a plea for resection to increase survival. *J Am Coll Surg*. 2003;197(1):29-37.
77. Steinmüller T, Kianmanesh R, Falconi M, et al; Frascati Consensus Conference participants. Consensus guidelines for the management of patients with liver metastases from digestive (neuro)endocrine tumors: foregut, midgut, hindgut, and unknown primary. *Neuroendocrinology*. 2008;87(1):47-62.
78. Gurusamy KS, Ramamoorthy R, Sharma D, Davidson BR. Liver resection versus other treatments for neuroendocrine tumours in patients with resectable liver metastases. *Cochrane Database Syst Rev*. 2009;(2):CD007060.
79. Pachera S, Yokoyama Y, Nishio H, et al. A rare surgical case of multiple liver resections for recurrent liver metastases from pancreatic gastrinoma: liver and vena cava resection. *J Hepatobiliary Pancreat Surg*. 2009;16(5):692-698.
80. Geehan DM, Kapcala LP, Saberinia M, Scovill WA. Intravascular tumor: a previously unreported finding of glucagonoma. *South Med J*. 1997;90(7):743-747.
81. Gold RP, Black TJ, Rotterdam H, Casarella WJ. Radiologic and pathologic characteristics of the WDHA syndrome. *AJR Am J Roentgenol*. 1976;127(3):397-401.
82. Fortner JG, Kim DK, Cubilla A, Turnbull A, Pahnke LD, Shils ME. Regional pancreatectomy: en bloc pancreatic, portal vein and lymph node resection. *Ann Surg*. 1977;186(1):42-50.
83. Metz DC, Benjamin SB. Islet cell carcinoma of the pancreas presenting as bleeding from isolated gastric varices: report of a case and review of the literature. *Dig Dis Sci*. 1991;36(2):241-244.
84. Ait-Ali A, Sall I, El-Kaoui H, et al. Medial pancreatectomy for a neuroendocrine tumor invading the splenic artery and vein. *JOP*. 2010;11(1):75-77.
85. Okuno M, Sakaguchi S, Nagayama M, et al. Nonfunctioning islet cell carcinoma presenting bleeding gastric varices and splenomegaly. *Jpn J Surg*. 1984;14(3): 244-247.
86. Yamaguchi T, Takahashi H, Kagawa R, et al. Nonfunctioning pancreatic endocrine tumor presenting with hemorrhage from isolated gastric varices. *Am Surg*. 2005;71(12):1027-1030.
87. Chellappa M, Yee CK, Gill DS. Left-sided portal hypertension from malignant islet cell tumour of the pancrease: review with a case report. *J R Coll Surg Edinb*. 1986;31(4):251-252.
88. Bettini R, Boninsegna L, Mantovani W, et al. Prognostic factors at diagnosis and value of WHO classification in a mono-institutional series of 180 non-functioning pancreatic endocrine tumours. *Ann Oncol*. 2008;19(5):903-908.
89. Thompson GB, van Heerden JA, Grant CS, Carney JA, Ilstrup DM. Islet cell carcinomas of the pancreas: a twenty-year experience. *Surgery*. 1988;104(6):1011-1017.
90. Fendrich V, Waldmann J, Bartsch DK, Langer P. Surgical management of pancreatic endocrine tumors. *Nat Rev Clin Oncol*. 2009;6(7):419-428.
91. Moertel CG. Karnofsky memorial lecture: an odyssey in the land of small tumors. *J Clin Oncol*. 1987;5(10):1502-1522.
92. Fendrich V, Langer P, Celik I, et al. An aggressive surgical approach leads to long-term survival in patients with pancreatic endocrine tumors. *Ann Surg*. 2006; 244(6):845-853.
93. Kazanjian KK, Reber HA, Hines OJ. Resection of pancreatic neuroendocrine tumors: results of 70 cases. *Arch Surg*. 2006;141(8):765-770.
94. Wolf JH, Long RJ, Miller FJ Jr, Jeffries GH. Pancreatic islet cell tumor presenting as bleeding gastric varices secondary to splenic vein occlusion. *Am J Dig Dis*. 1977;22(7):652-655.
95. Maclean N, Falconer CW, Gilmour IE, Webb FN. Islet cell tumours of the pancreas with portal varices and gastrointestinal haemorrhage. *J R Coll Surg Edinb*. 1970;15(4):206-212.
96. Watase M, Sakon M, Monden M, et al. A case of splenic vein occlusion caused by the intravenous tumor thrombus of nonfunctioning islet cell carcinoma. *Surg Today*. 1992;22(1):62-65.
97. Modlin IM, Oberg K, Chung DC, et al. Gastroenteropancreatic neuroendocrine tumours. *Lancet Oncol*. 2008;9(1):61-72.
98. Folprecht G, Gruenberger T, Bechstein WO, et al. Tumour response and secondary resectability of colorectal liver metastases following neoadjuvant chemotherapy with cetuximab: the CELIM randomised phase 2 trial. *Lancet Oncol*. 2010; 11(1):38-47.
99. Thomas AA, Rini BI, Stephenson AJ, et al. Surgical resection of renal cell carcinoma after targeted therapy. *J Urol*. 2009;182(3):881-886.

INVITED CRITIQUE

Especially Dangerous and Therefore Anxious Operations

In the summer of 1904, Sir Frederick Treves, the most famous surgeon of his time, wrote to King Edward seeking approval of the decision to retire from surgical practice. "I am anxious to retire from active practice," Treves wrote, "and I trust Your Royal Highness will approve of my doing so. I have had 25 years of incessant and exacting work, and of late years I have been almost exclusively concerned with specially dangerous–and therefore anxious–operations."[1] Norton and his colleagues at the National Institutes of Health and Stanford University hospitals report their quarter of a century of incessant and exacting work with the dangerous and anxious operative treatment of PETs with major vascular involvement. The operations are dangerous because these tumors may be large and associated with pancreatic and peripancreatic fibrosis. Despite well-formulated and safe surgical techniques of vascular resection and reconstruction, these operations carry extra physical and emotional work, and the postoperative morbidity is worse than that of operations without vascular involvement. Anxious debate rattles the surgeon because the clinical course of PETs is capricious. Many advanced tumors pursue an indolent course, and long-term survival with advanced disease is possible. Other ostensibly early and small tumors seem to spread quickly and widely to the liver. The pancreatic surgeon worries whether the risk of resect-

©2011 American Medical Association. All rights reserved.
Downloaded From: http://archsurg.jamanetwork.com/ on 07/29/2015