Original Investigation | PACIFIC COAST SURGICAL ASSOCIATION

Prospective Evaluation of the Role of Computed Tomography in the Assessment of Abdominal Stab Wounds

Kenji Inaba, MD; Obi T. Okoye, MD; Rachel Rosenheck, MD; Nicolas Melo, MD; Bernardino C. Branco, MD; Peep Talving, MD, PhD; Lydia Lam, MD; Sravanthi Reddy, MD; Ali Salim, MD; Demetrios Demetriades, MD, PhD

Invited Commentary page 816

CME Quiz at jamanetworkcme.com

IMPORTANCE An important adjunct in the management of abdominal gunshot wounds, the role of computed tomography (CT) in the diagnostic workup of abdominal stab wounds remains controversial.

OBJECTIVE To prospectively compare CT against serial physical examination in the evaluation of patients who have sustained a stab wound to the abdomen.

DESIGN, SETTING, AND PATIENTS Prospective single-center observational study of all patients sustaining abdominal stab wounds from March 1, 2009, through March 31, 2011. Patients who were hemodynamically unstable, unevaluable, peritonitic, or eviscerated proceeded directly to laparotomy (n = 249). The remainder underwent CT evaluation. The impact of CT findings and physical examination on the decision to operate was analyzed.

MAIN OUTCOMES AND MEASURES Diagnostic accuracy of CT vs physical examination in determining the need for therapeutic laparotomy.

RESULTS A total of 249 patients were enrolled (94% male; mean [SD]: age, 30.8 [12.9] years [range, 16-87 years]; systolic blood pressure, 128 [28] mm Hg; Glasgow Coma Scale score, 14 [2]; Injury Severity Score, 6.8 [6.5]). Forty-five patients (18.1%) underwent immediate laparotomy, 27 (10.8%) had superficial injuries allowing immediate discharge, and the remaining 177 (71.1%) underwent CT. Of these, 154 (87.0%) were successfully observed, with 20 (11.3%) requiring laparotomy, 2 (1.1%) thoracotomy, and 1 (0.6%) sternotomy. Of the 20 laparotomies, 16 (80.0%) were therapeutic. All patients who underwent therapeutic laparotomy did so based on their physical examination. The most common finding leading to laparotomy was the development of peritonitis in 70%. The CT scan findings did not alter clinical decision making. The sensitivity and specificity of physical examination were 100.0% and 98.7%, respectively, while those of CT were 31.3% and 84.2%, respectively.

CONCLUSIONS AND RELEVANCE In this prospective evaluation of abdominal stab wound management, serial physical examination was able to discriminate between patients requiring a therapeutic laparotomy and those who could be safely observed. A physical examination–based diagnostic algorithm was effective and decreased radiation burden in the management of abdominal stab wounds.

JAMA Surg. 2013;148(9):810-816. doi:10.1001/jamasurg.2013.2521
Published online July 3, 2013.

Author Affiliations: Division of Trauma and Surgical Critical Care, University of Southern California, Los Angeles, California (Inaba, Okoye, Rosenheck, Melo, Branco, Talving, Lam, Demetriades); Department of Radiology, Los Angeles County + University of Southern California Medical Center, Los Angeles, California (Reddy); Department of Surgery, Cedars-Sinai Hospital Center, Los Angeles, California (Salim).

Corresponding Author: Kenji Inaba, MD, Division of Trauma and Surgical Critical Care, University of Southern California, 2051 Marengo St, IPT C5L100, Los Angeles, CA 90033 (kinaba@surgery.usc.edu).

Downloaded From: http://archsurg.jamanetwork.com/ on 07/08/2015

For patients who have sustained a penetrating injury to the abdomen, nonoperative management remains a safe treatment option.[1-5] Unevaluable patients, or those presenting with hemodynamic instability, peritonitis, or evisceration, are not candidates and should undergo immediate exploration. For the remainder, imaging is often used as a diagnostic adjunct. If the injury mechanism is an abdominal gunshot wound, computed tomography (CT) has been demonstrated to effectively delineate patients into 3 groups: those who have an injury requiring laparotomy, those with trajectories that are clear of any intra-abdominal contents, and those with questionable injuries requiring further clinical observation.[6,7] However, for stab wounds, the optimal management plan, and in particular the role of CT, is unclear. Unlike with gunshot wounds where bullet trajectories can be tracked through the soft tissue, for stab wounds, the lack of soft tissue disruption makes visualizing the tract of the stab wound and any associated injuries difficult. In this era of increased awareness of radiation burden and the ever-increasing accessibility and use of CT,[8] the value of this extra imaging in the diagnostic workup of abdominal stab wounds remains a practical unanswered question.

Therefore, the purpose of this study was to evaluate the diagnostic contribution made by CT in patients who have sustained an abdominal stab wound and to compare this with the physical examination. Our hypothesis was that compared with a carefully performed physical examination, CT would not impact clinical management.

Methods

After institutional review board approval, all patients who sustained abdominal stab wounds presenting to the Los Angeles County + University of Southern California Medical Center between March 1, 2009, and March 31, 2011 (25 months) were prospectively screened for inclusion in this study. The inclusion criteria for enrollment were: (1) age 16 years or older; (2) stab wound; and (3) injury site bounded above by a line joining the internipple line anteriorly and inferior tips of the scapula posteriorly, and below by the inguinal ligaments anteriorly and the iliac crests posteriorly. All patients with an extraabdominal injury requiring intervention were excluded.

During the study, all patients meeting inclusion criteria were evaluated by an in-house attending trauma surgeon and managed according to the study algorithm. Patients underwent a structured clinical examination, with prospective documentation of hemodynamic status, neurological status, and abdominal examination findings using a standardized checklist. Patients who were unevaluable owing to head injury or intoxicants, those with hemodynamic instability not responsive to fluid resuscitation, those with peritonitis on examination, and those with bowel or omental evisceration underwent immediate surgical exploration. Those with superficial skin and soft-tissue injuries only underwent local wound care and were discharged from the emergency department. The remaining patients underwent a standardized CT examination and were admitted for a minimum of 24 hours of observation in a dedicated observation area.

After this period of observation, all patients with a stab wound to the left thoracoabdominal region underwent a diagnostic laparoscopy prior to discharge to rule out diaphragmatic injury.[9]

A standardized CT protocol was used (Toshiba Aquilion 64 CFX multislice CT scanner; Toshiba Medical Systems Corp). The following parameters were used: 120 kVp, 200-500 mAs (depending on the size of the patient and using dose modulation), gantry revolution speed of 0.5 seconds, beam pitch of 0.828, beam collimation of 64 mm × 0.5 mm, variable field of view (depending on the size of the patient), and standard body kernel. Through a line suitable for power contrast injection (18- or 20-gauge peripheral intravenous line in the antecubital fossa or a central venous catheter that has been approved by the manufacturer for power injection), 75-100 cc of Iohexol-iodinated intravenous contrast material (Omnipaque 350; GE Healthcare) was injected at a rate of 4 mL/s followed by a 40-cc saline flush by a Medrad power injector (Stellant; Medrad). Imaging was performed in the portal venous phase 90 seconds after injection. Reconstruction was routinely performed with section thickness of 3 mm in the axial, coronal, and sagittal planes. The final reading by an attending radiologist was used for all the analyses.

Admission data collected included age, sex, injury mechanism, systolic blood pressure, Glasgow Coma Scale score, and location of external wound. Findings from the structured physical examination performed by the attending surgeon at admission were documented for each patient. This included the location of all stab wounds, the presence of peritonitis, and the location and content of any intra-abdominal evisceration. All patients included in the study were followed up throughout their hospital stay. All operative procedures and imaging results were documented. Injury Severity Score, hospital length of stay, intensive care unit length of stay, and mortality were recorded.

Descriptive statistics were applied. Values were reported as mean (standard deviation [SD]); median (range) for continuous variables; and percentage for categorical variables. Continuous variables were dichotomized using the following clinically relevant cut points: age (≥55 years vs <55 years), systolic blood pressure at admission (≤90 mm Hg vs >90 mm Hg), Glasgow Coma Scale score at admission (≤8 vs >8), and Injury Severity Score (≥25 vs <25).

Continuous variables were compared using analysis of variance with post hoc comparisons performed using Bonferroni corrections. Categorical variables were compared using the Fisher exact test, with Freeman-Halton extensions where applicable.

All analyses were performed using the Statistical Package for Social Sciences (SPSS for Windows) version 17.0 (SPSS Inc).

Results

During the study, a total of 249 patients with stab wounds isolated to the abdomen were prospectively identified and enrolled in the study. Forty-five patients (18.1%) required emergent surgery, while 27 (10.8%) with superficial injuries

Downloaded From: http://archsurg.jamanetwork.com/ on 07/08/2015

Figure. Management of Patients With Abdominal Stab Wounds

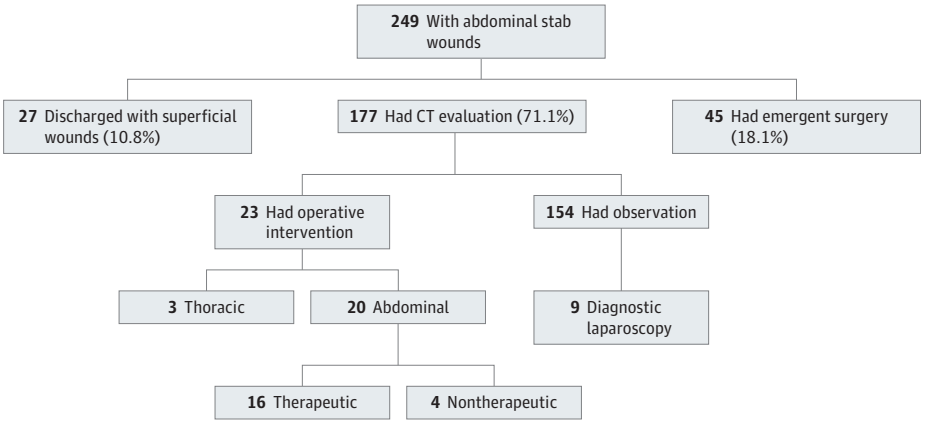

CT indicates computed tomography.

Table 1. Demographics, Clinical Data, and Outcomes for Patients With Abdominal Stab Wounds

	No./No. (%)				
	All Patients (N = 249)	Observation Only (n = 27)	Emergent Laparotomy (n = 45)	Computed Tomography Evaluation (n = 177)	*P* Value
Demographics					
Age, mean (SD), y	30.8 (12.9)	28.0 (11.4)	34.8 (14.6)	30.3 (12.5)	.06
Age ≥55 y	12/249 (4.8)	0/27 (0)	4/45 (8.9)	8/177 (4.5)	.22
Male	234/249 (94.0)	25/27 (92.6)	43/45 (95.6)	166/177 (93.8)	.86
SBP on admission, mean (SD)	127.6 (27.7)	135.2 (22.5)	102.6 (44.7)	131.2 (19.8)	<.001
SBP ≤ 90 mm Hg on admission	15/249 (6.0)	0/27 (0)	10/45 (22.2)	5/177 (2.8)	<.001
HR > 100 bpm	95/249 (38.2)	10/27 (37.0)	16/45 (35.6)	69/177 (39.0)	.93
GCS score on admission, mean (SD)	14.5 (2.2)	15.0 (0.2)	12.2 (4.6)	14.9 (0.6)	<.001
GCS score ≤ 8	8/249 (3.2)	0/27 (0)	8/45 (17.8)	0/177 (0)	<.001
Stab wound pattern					
Multiple sites	81/249 (32.5)	6/27 (22.2)	16/45 (35.6)	59/177 (33.4)	.46
Anterior	123/249 (49.4)	11/27 (40.7)	31/45 (68.9)	81/177 (45.8)	.01
Thoracoabdominal	78/249 (31.3)	8/27 (29.6)	16/45 (35.6)	54/177 (30.4)	.79
Flank	62/249 (24.9)	5/27 (18.5)	8/45 (17.8)	49/177 (27.7)	.28
Posterior	56/249 (22.5)	9/27 (33.3)	6/45 (13.3)	41/177(23.2)	.13
Injury severity indices					
Head AIS ≥ 3	5/249 (2.0)	1/27 (3.7)	1/45 (2.2)	3/177 (1.7)	.78
Chest AIS ≥ 3	74/249 (29.7)	1/27 (3.7)	14/45 (31.1)	59/177 (33.3)	.007
Abdomen AIS ≥ 3	34/249 (13.7)	0/27 (0)	13/45 (28.9)	21/177 (11.9)	.001
Extremity AIS ≥ 3	2/249 (0.8)	0/27 (0)	1/45 (2.2)	1/177 (0.6)	.48
ISS, mean (SD)	6.8 (6.5)	2.4 (3.5)	10.5 (7.2)	6.5 (6.2)	<.001
ISS ≥ 25	8/249 (3.2)	0/27 (0)	4/45 (8.9)	4/177 (2.3)	.05
Outcomes					
Mortality	8/249 (3.2)	0/27 (0)	7/45 (15.6)	1/177 (0.6)	<.001
HLOS, mean (SD)	5.3 (15.2)	2.2 (1.6)	13.8 (33.9)	3.6 (3.7)	<.001

Abbreviations: AIS, Abbreviated Injury Score; GCS, Glasgow Coma Scale; HLOS, hospital length of stay; HR, heart rate; ISS, Injury Severity Score; SBP, systolic blood pressure.

underwent local wound care and were discharged home from the emergency department (**Figure**). The remaining 177 (71.1%) underwent CT and observation for 24 hours in a dedicated observation unit.

The patients were predominantly male (94%) with a mean (SD) age of 30.8 (12.9) years (range, 16-87 years). Approximately two-thirds of the patients (67.5%) had a single stab wound. In the remainder, the number of wounds ranged from 2 to 6 stab injuries. Half had anterior abdominal wounds (49.4%), with the remainder localized to the flank, back, and thoracoabdominal regions. The mean (SD) Injury Severity Score was 6.8 (6.5), with most of the injuries localized to the ante-

Downloaded From: http://archsurg.jamanetwork.com/ on 07/08/2015

Table 2. Clinical Examination Findings

	No./No. (%)				
	All Patients (N = 249)	Observation Only (n = 27)	Emergent Surgery (n = 45)	Computed Tomography Evaluation (n = 177)	*P* Value
Hemodynamic status					<.001
Stable	225/249 (90.4)	27/27 (100)	26/45 (57.8)	172/177 (97.2)	
Unstable, responded to fluids	7/249 (2.8)	0/27 (0)	2/45 (4.4)	5/177 (2.8)	
Unstable, transient response	2/249 (0.8)	0/27 (0)	2/45 (4.4)	0/177 (0)	
Unstable, no response	15/249 (6.0)	0/27 (0)	15/45 (33.3)	0/177 (0)	
Clinical evaluation					<.001
Alert and oriented	220/249 (91.3)	24/27 (96.0)	26/45 (65.0)	170/177 (96.6)	
Intoxicated, but evaluable	16/249 (3.3)	3/27 (4.0)	6/45 (0)	7/177 (4.0)	
Unevaluable	13/249 (5.0)	0/27 (0)	13/45 (30.0)	0/177 (0)	
Abdominal examination					<.001
Diffuse peritonitis/tenderness	27/249 (10.8)	0/27 (0)	27/45 (60.0)	0/177 (0)	
Evisceration	10/249 (4.0)	0/27 (0)	10/45 (22.2)	0/177 (0)	
Localized tenderness	87/249 (34.9)	6/27 (22.2)	4/45 (8.9)	77/177 (43.5)	
No tenderness	125/249 (50.2)	21/27 (77.8)	4/45 (8.9)	100/177 (56.5)	

rior abdomen (49.4%). The mean (SD) admission systolic blood pressure was 128 [28] mm Hg, with 6% arriving hypotensive with a systolic blood pressure of 90 mm Hg or greater (**Table 1**).

Of the initial study cohort, 45 (18.1%) underwent emergent laparotomy for a combination of the following: peritonitis (60.0%), hemodynamic instability (37.8%), unevaluable examination (30.0%), and evisceration (22.2%) (**Table 2**). At laparotomy, 43 (95.6%) were found to have a clinically significant injury. Of these 45 patients who underwent emergent surgery, 8 (17.8%) presented in arrest, requiring resuscitative thoracotomies in the emergency department. The overall survival rate in this group was 84.4%, with all of the deaths occurring in the group requiring resuscitative thoracotomy.

From the original cohort, 27 (10.8%) patients arrived in the emergency department after sustaining a superficial stab wound without full-thickness breech of the skin. These patients did not undergo CT and were sent home directly from the emergency department.

For the remaining 177 patients (71.1%) who underwent a trial of nonoperative management and CT, 154 patients (87.0%) had successful nonoperative management with a 24-hour period of observation and no requirement for laparotomy. Nine of these patients (5.8%) underwent diagnostic laparoscopy, all of which were negative for diaphragm injury. Of these 154 patients, 30 (19.5%) had a solid organ injury detected on their CT that was managed nonoperatively. This included 17 liver, 8 renal, and 6 splenic injuries, all of which were low grade. None required any percutaneous or endovascular interventions, and all 154 patients were successfully discharged home within 48 hours.

Of these 177 patients who underwent nonoperative management and CT, 23 (13.0%) underwent delayed operation. Three of these patients had thoracic procedures. The first patient had a hemothorax on chest x-ray with persistent thoracostomy output in excess of 1.5 L and went on to have a right thoracotomy and resection of a lung laceration. The other 2 patients had a diagnosis of hemopericardium made on CT. In both cases, the cardiac window on the initial focused assessment with sonography for trauma was negative. Both were brought to the operating room. One of the patients went into cardiac arrest on intubation owing to anesthetic complications, requiring a resuscitative thoracotomy prior to the planned sternotomy. There was no pericardial fluid observed at thoracotomy. The second patient had a sternotomy, with no cardiac injury found. No abdominal exploration was required in these 3 patients and all survived to discharge.

Twenty patients (11.3%) failed nonoperative management and underwent abdominal exploration during their observation period. All patients did so based on deterioration of their physical examination. The most common indication for abdominal exploration was peritonitis (70%), followed by hemodynamic instability (40%). Of the patients who underwent exploration, 80% had a therapeutic laparotomy; a detailed list of findings is provided in **Table 3**. Two patients (10.0%) underwent laparotomy solely based on CT findings, despite a normal clinical examination. Both resulted in negative laparotomies. For clinically significant injuries, the sensitivity and specificity of the physical examination were 100.0% and 98.7%, respectively, while for CT these were only 31.3% and 84.2%, respectively. The positive and negative likelihood ratios for CT imaging were 1.98 and 0.81, respectively.

Discussion

Patients with a penetrating injury to the abdomen, hemodynamic instability, an unevaluable examination, peritonitis, or evisceration all mandate operative exploration. For patients not meeting these criteria, one treatment option is nonoperative management, which uses a combination of imaging and clinical examination to discriminate between those who re-

Downloaded From: http://archsurg.jamanetwork.com/ on 07/08/2015

Table 3. Indications for Surgery in Patients Evaluated by CT Imaging

Patient No./ Age, y/Sex	Stab Wound Site	Indication for Surgery	Injuries Identified	Time to OR
1/26/M	RUQ, LUQ, RTA, LTA	Hemodynamic instability	Hepatic and splenic arteries	1 h 10 min
2/27/M	LLQ	CT findings: intra-abdominal hematoma	Negative laparotomy	1 h 20 min
3/21/M	LUQ	Hemodynamic instability	Colon injury	1 h 10 min
4/24/M	LUQ	Hemodynamic instability	Small bowel and colon injuries	37 min
5/26/M	RUQ, RF, LF	Hemodynamic instability, peritonitis	Small bowel injury	2 h 17 min
6/20/M	RUQ	Increase in WBC count, peritonitis	Gastric injury	6 h 20 min
7/47/M	RUQ, LUQ, RLQ, LLQ	Increase in WBC count, peritonitis, hemodynamic instability	Small bowel injury	5 h 46 min
8/23/M	LLQ, LLB	Hemodynamic instability, peritonitis	Diaphragm injury	31 min
9/51/M	LLQ	Peritonitis	Colon injury	1 h 55 min
10/36/M	LLQ	CT findings: free fluid around bladder	Negative laparotomy	4 h 10 min
11/22/M	LTA	Decrease in hemoglobin, hemodynamic instability, peritonitis	Liver and diaphragm injury	1 h 5 min
12/18/M	LLB, LF	Peritonitis	Negative laparotomy	1 h 23 min
13/24/M	LTA, LLB, LB	Increased WBC count, peritonitis	Diaphragm injury	6 h 35 min
14/17/M	RTA, LF	Peritonitis	Liver and diaphragm injury	37 min
15/21/M	LTA	Peritonitis	Gastric and diaphragm injury	1 h
16/17/M	RUQ, LLQ, RF	Peritonitis	Small bowel injury, infrarenal IVC injury	48 min
17/52/M	LUQ, LF	Hemodynamic instability	Spleen injury	50 min
18/49/M	LLQ	Peritonitis	Negative laparotomy	21 h 56 min
19/26/M	RUQ	Peritonitis	Gall bladder, liver and diaphragm injuries	4 h 1 min
20/19/M	LLQ	Peritonitis	Colon injury	3 h 7 min

Abbreviations: CT, computed tomography; IVC, inferior vena cava; LB, left buttock; LF, left flank; LLB, left lower back; LLQ, left lower quadrant; LTA; left thoracoabdominal; LUQ, left upper quadrant; M, male; OR, operating room; RF, right flank; RLQ, right lower quadrant; RTA, right thoracoabdominal; RUQ, right upper quadrant; WBC, white blood cell.

quire an operation and those who can safely be managed nonoperatively. For those patients who sustain an abdominal gunshot wound, attempted nonoperative management begins with a CT.[1,2] Because the trail of soft-tissue destruction left by the bullet is well delineated on CT, the course of the bullet and any collateral hollow viscus or solid-organ injury can be reliably diagnosed. This allows separation of patients into those with an injury requiring repair, those with a bullet trajectory clear of any intra-abdominal contents that can be sent home, and finally those with an equivocal CT requiring further observation. However, for stab wounds, blade entry is associated with far less kinetic energy and tissue disruption, resulting in a path that is often difficult to visualize. Consequently, the role of CT in the acute evaluation of patients with an abdominal stab wound has remained unclear.[10,11] In a previous analysis of anterior abdominal stab wounds from this center,[12] a small series of 67 patients was examined, demonstrating promise for CT. Subsequently, a series of important multicenter studies performed by the Western Trauma Association trials group demonstrated that CT had become the most commonly performed diagnostic adjunct.[2,8] Direct comparison to this current study is difficult as only anterior abdominal stab wounds were examined and not all patients underwent CT. However, the findings are complementary and although CT was not directly compared with serial clinical examination, the group's work clearly demonstrated a significant false-negative rate associated with the use of this imaging modality.[13] This current study was designed to prospectively compare CT against physical examination for all abdominal stab wounds including those to the flank and back. After excluding patients requiring immediate surgery and those with superficial injuries, approximately 71% of patients were candidates for nonoperative management and underwent CT evaluation. In comparison, for gunshot injuries, in a recent prospective evaluation of nonoperative management,[7] far less, approximately 53%, met criteria for nonoperative management and underwent CT. For these gunshot injuries, approximately 30% had an injury found on CT and underwent operation, with all having a clinically significant intra-abdominal injury. In addition, 34% had negative CT findings and could have been discharged home without laparotomy, leaving only 36% that required observation. Therefore, for gunshot injuries, the CT directly impacted clinical management, effectively delineating those who required operation from those who could be safely sent home and those who required observation. However, in this examination of the role of CT for stab wounds, all patients who required a lapa-

Downloaded From: http://archsurg.jamanetwork.com/ on 07/08/2015

rotomy for a clinically significant injury requiring repair did so based on a deterioration in their physical examination and not based on their CT findings. Computed tomography did not improve the diagnostic yield or the time to diagnosis. In fact, 2 patients had a positive CT finding but no change in their physical examination, and they were brought to the operating room based on the CT findings alone. Both of the laparotomies were nontherapeutic.

One of the other arguments for performing a CT is the ability to discharge patients home earlier without the need for serial clinical examination. Computed tomography was only able to detect 5 of the clinically significant injuries for a sensitivity of 31.3%. If CT were used to exclude injures and discharge patients home without observation, 68.8% of the injuries would have been missed and inappropriately sent home. Thus, even with a negative CT scan finding and with the possibility of an occult but clinically significant injury, clinical observation remains mandatory. Therefore, CT would not save time.

Finally, the role of CT for those patients who are ultimately sent home warrants discussion. Approximately 20% of these patients had a finding on their CT; all were low-grade solid-organ injuries not requiring treatment.[14,15] For these minor injuries, none required endovascular or percutaneous or open interventions and the duration of observation was not altered. All of the clinically significant solid-organ injuries were diagnosed on clinical grounds and underwent laparotomy. Thus, the clinical significance of knowing about these minor solid-organ injuries not requiring treatment is unknown.

Although this was a prospective evaluation, with a standardized clinical examination being directly compared with CT, there are several potential limitations. The patients who underwent nonoperative management were observed for a minimum of 24 hours; however, it is conceivable that a patient was sent home with a clinically significant injury resulting in death or presentation to a different medical center. This would apply equally to both physical examination and CT. Because of the population demographic enrolled in this study, it is also likely that any further follow-up care would have been conducted at our center, minimizing the chance of this attrition. The choice of 24 hours as a minimum observation period was based on previous work conducted on gunshot injuries,[7] which is double the observation time advocated for stab wounds undergoing nonoperative management.[16] The major strengths of this data set included the prospective patient identification and accrual with a standardized clinical examination and the use of CT in all patients included in the study. This provided a critical evaluation of the role of both CT and physical examination in the same patient, allowing a direct comparison of their ability to detect clinically relevant injuries detected at operation as the primary outcome measure.

As our understanding of the importance of radiation burden increases,[17] whenever possible, the use of imaging must be reviewed so as to not unnecessarily increase radiation exposure. With the increasing availability and access to CT, as well as the desire to not miss an injury, our threshold for using CT for the evaluation of injured patients is progressively becoming lower. In this prospective evaluation of patients who sustained an abdominal stab wound, all clinically significant injuries were detected by clinical examination alone. Computed tomography did not improve the diagnostic yield or shorten the time to diagnosis. However, CT did result in an increase in nontherapeutic laparotomies. Likewise, CT was not able to facilitate earlier discharge and did not improve overall clinical outcomes.

In conclusion, in this prospective evaluation of abdominal stab wound management, serial physical examination was able to discriminate between patients requiring a therapeutic laparotomy and those who could be safely observed. A physical examination–based diagnostic algorithm was effective and decreased radiation burden in the management of abdominal stab wounds.

ARTICLE INFORMATION

Accepted for Publication: March 12, 2013.

Published Online: July 3, 2013. doi:10.1001/jamasurg.2013.2521.

Author Contributions: Dr Okoye had full access to all the data used in the study and takes responsibility for the integrity of the data and accuracy of the data analysis.
Study concept and design: Inaba, Branco, Lam.
Acquisition of data: Inaba, Okoye, Rosenheck, Melo, Branco, Talving, Lam.
Analysis and interpretation of data: Okoye, Reddy, Salim, Demetriades.
Drafting of the manuscript: Inaba, Okoye, Branco.
Critical revision of the manuscript for important intellectual content: Inaba, Rosenheck, Melo, Talving, Lam, Reddy, Salim, Demetriades.
Statistical analysis: Okoye, Branco.
Administrative, technical, and material support: Inaba, Rosenheck, Lam, Salim, Demetriades.
Study supervision: Inaba, Melo, Talving.

Conflict of Interest Disclosures: None reported.

Previous Presentation: This study was presented at the 84th Annual Meeting of the Pacific Coast Surgical Association; February 17, 2013; Kauai, Hawaii, and is published after peer review and revision.

REFERENCES

1. Inaba K, Demetriades D. The nonoperative management of penetrating abdominal trauma. *Adv Surg*. 2007;41:51-62.

2. Biffl WL, Moore EE. Management guidelines for penetrating abdominal trauma. *Curr Opin Crit Care*. 2010;16(6):609-617.

3. Como JJ, Bokhari F, Chiu WC, et al. Practice management guidelines for selective nonoperative management of penetrating abdominal trauma. *J Trauma*. 2010;68(3):721-733.

4. Zafar SN, Rushing A, Haut ER, et al. Outcome of selective non-operative management of penetrating abdominal injuries from the North American National Trauma Database [published correction appears in *Br J Surg*. 2012;99(7):1023]. *Br J Surg*. 2012;99(suppl 1):155-164.

5. Jansen JO, Inaba K, Rizoli SB, Boffard KD, Demetriades D. Selective non-operative management of penetrating abdominal injury in Great Britain and Ireland: survey of practice. *Injury*. 2012;43(11):1799-1804.

6. Velmahos GC, Constantinou C, Tillou A, Brown CV, Salim A, Demetriades D. Abdominal computed tomographic scan for patients with gunshot wounds to the abdomen selected for nonoperative management. *J Trauma*. 2005;59(5):1155-1160; discussion 1160-1161.

7. Inaba K, Branco BC, Moe D, et al. Prospective evaluation of selective nonoperative management of torso gunshot wounds: when is it safe to discharge? *J Trauma Acute Care Surg*. 2012;72(4):884-891.

8. Biffl WL, Kaups KL, Pham TN, et al. Validating the Western Trauma Association algorithm for managing patients with anterior abdominal stab wounds: a Western Trauma Association multicenter trial. *J Trauma*. 2011;71(6):1494-1502.

9. Murray JA, Demetriades D, Asensio JA, et al. Occult injuries to the diaphragm: prospective evaluation of laparoscopy in penetrating injuries to the left lower chest. *J Am Coll Surg*. 1998;187(6):626-630.

10. Berardoni NE, Kopelman TR, O'Neill PJ, et al. Use of computed tomography in the initial

Downloaded From: http://archsurg.jamanetwork.com/ on 07/08/2015

evaluation of anterior abdominal stab wounds. *Am J Surg*. 2011;202(6):690-695; discussion 695-696.

11. Chiu WC, Shanmuganathan K, Mirvis SE, Scalea TM. Determining the need for laparotomy in penetrating torso trauma: a prospective study using triple-contrast enhanced abdominopelvic computed tomography. *J Trauma*. 2001;51(5):860-868; discussion 868-869.

12. Salim A, Sangthong B, Martin M, et al. Use of computed tomography in anterior abdominal stab wounds: results of a prospective study. *Arch Surg*. 2006;141(8):745-750; discussion 750-752.

13. Biffl WL, Cothren CC, Moore EE, et al. Western Trauma Association critical decisions in trauma: screening for and treatment of blunt cerebrovascular injuries. *J Trauma*. 2009;67(6):1150-1153.

14. Demetriades D, Hadjizacharia P, Constantinou C, et al. Selective nonoperative management of penetrating abdominal solid organ injuries. *Ann Surg*. 2006;244(4):620-628.

15. DuBose J, Inaba K, Teixeira PG, Pepe A, Dunham MB, McKenney M. Selective non-operative management of solid organ injury following abdominal gunshot wounds. *Injury*. 2007;38(9):1084-1090.

16. Alzamel HA, Cohn SM. When is it safe to discharge asymptomatic patients with abdominal stab wounds? *J Trauma*. 2005;58(3):523-525.

17. Inaba K, Branco BC, Lim G, et al. The increasing burden of radiation exposure in the management of trauma patients. *J Trauma*. 2011;70(6):1366-1370.

Invited Commentary

Evaluating the Role of Computed Tomography
Have They Gone Far Enough?

Martin A. Schreiber, MD

Inaba and colleagues[1] performed a prospective evaluation of their algorithm for the management of asymptomatic abdominal stab wounds. They have shown that routine computed tomographic scanning adds nothing to the evaluation and, in fact, physical examination is more accurate than computed tomography in predicting the need for a therapeutic laparotomy. I would like to commend the authors on objectively evaluating the way they manage patients and coming to the conclusion that their algorithm is not supported by their findings. There are other aspects of their data that suggest that further change in management may be indicated.

Related article page 810

For instance, in their algorithm, patients who are intoxicated or otherwise unexaminable go directly to the operating room. This is owing to the inability to perform serial examinations. It would be helpful if the authors provided data on the negative laparotomy rate in the patients who had no objective evidence of intraabdominal injury. It is possible that allowing intoxication to resolve or performing computed tomography or serial examinations in stable patients would also be a reasonable approach.

The authors also stated that they observe patients with thoracoabdominal wounds for the development of peritonitis. If peritonitis does not develop, they routinely perform laparoscopy to rule out diaphragm injuries. However, in this series, all of the results of thoracoscopies performed for this indication were negative for diaphragm injuries. This finding suggests that the algorithm could be modified.

The authors' algorithm also did not include local wound exploration. When local wound exploration conclusively excludes fascial penetration, patients can usually be discharged without an observation period.[2] This would further facilitate careful observation of the patients who need it and expedite discharge of those who do not.

Finally, the authors did not provide important details concerning how the patients are observed. It is not clear who is examining these patients, how frequently, and in what setting. Many level 1 trauma centers routinely have periods when all manpower is focused on critically injured patients. Also in light of the 80-hour work week and increasing frequency of shift work, it is possible that subtle changes in the physical examination could be missed. It is important to realize that observation of stable stab wound patients may not be feasible in all settings because it is resource intensive.

Although the University of Southern California group is not the first to report the success of observing patients with anterior abdominal stab wounds,[3] this contribution remains important because it represents an example of how critically analyzing an established center's data can change practices. The question remains: have they changed enough?

ARTICLE INFORMATION

Author Affiliation: Division of Trauma, Critical Care, and Acute Care Surgery, Department of Surgery, Oregon Health & Science University, Portland, Oregon.

Corresponding Author: Martin A. Schreiber, MD, Division of Trauma, Critical Care, and Acute Care Surgery, Department of Surgery, Oregon Health & Science University, 3181 Sam Jackson Rd SW, Mail Code L-611, Portland, OR 97035 (schreibm@ohsu.edu).

Published Online: July 3, 2013. doi:10.1001/jamasurg.2013.2538.

Conflict of Interest Disclosures: None reported.

REFERENCES

1. Inaba K, Okoye OT, Rosenheck R, et al. Prospective evaluation of the role of computed tomography in the assessment of abdominal stab wounds [published online July 3, 2013]. *JAMA Surg*. doi:10.1001/jamasurg.2013.2521.

2. Cothren CC, Moore EE, Warren FA, Kashuk JL, Biffl WL, Johnson JL. Local wound exploration remains a valuable triage tool for the evaluation of anterior abdominal stab wounds. *Am J Surg*. 2009;198(2):223-226.

3. Biffl WL, Kaups KL, Pham TN, et al. Validating the Western Trauma Association algorithm for managing patients with anterior abdominal stab wounds: a Western Trauma Association multicenter trial. *J Trauma*. 2011;71(6):1494-1502.

Downloaded From: http://archsurg.jamanetwork.com/ on 07/08/2015